

# Asian Journal of OPHTHALMOLOGY

open access journal  est. 1998

Volume 15 • Issue 3 • 2017 • 1560-2133

# Asian Journal of OPHTHALMOLOGY

Submit your article now to the  
Asian Journal of OPTHALMOLOGY  
a peer-reviewed online open access journal.

There are **no** publication costs, hidden fees or charges.

Chief editor: Paul Chew

The objectives of Asian Journal of Ophthalmology are as follows:

- To provide a platform for the publication of information with a focus on Ophthalmology in Asia
- To disseminate information that will improve the care of patients with all types of ophthalmological disorders, with a special focus on glaucoma
- To increase the understanding of such disorders through reporting of educational activities
- To publish the results of research programmes to expand knowledge about the causes, prevention, and treatment of ophthalmological disorders
- To work closely with Asian and international researchers to achieve these aims
- To provide a forum for young and relatively inexperienced researchers to present their research results as Original Articles via an international platform
- To maintain and promote relationships with any organisation with similar goals.

For more information, an article template and submission guidelines, see [www.asianjo.com](http://www.asianjo.com)

# Asian Journal of OPHTHALMOLOGY

open access journal  est. 1998

**Asian Journal of Ophthalmology** is the peer-reviewed journal for The Asian Pacific Glaucoma Society (APGS), The Asia Pacific Ophthalmic Trauma Society (APOTS) and all others with an interest in Ophthalmology.

## Advertising inquiries

The Asian Journal of Ophthalmology offers many sponsorship and advertising opportunities, both online and in print. Please mail us at [info@asianjo.com](mailto:info@asianjo.com) to access the media kit or for queries.

## Copyright

Authors who publish with this journal agree to the following terms:

- a. Authors retain copyright and grant the journal right of first publication, with the work twelve (12) months after publication simultaneously licensed under a Creative Commons Attribution License that allows others to share the work with an acknowledgement of the work's authorship and initial publication in this journal.
- b. Authors are able to enter into separate, additional contractual arrangements for the non-exclusive distribution of the journal's published version of the work (e.g., post it to an institutional repository or publish it in a book), with an acknowledgement of its initial publication in this journal.
- c. Authors are permitted and encouraged to post their work online (e.g., in institutional repositories or on their website) prior to and during the submission process, as it can lead to productive exchanges, as well as earlier and greater citation of published work.

## Disclaimers

All articles published, including editorials and letters, represent the opinions of the authors and do not reflect the official policy of Asian Journal of Ophthalmology, the APGS, APOTS, its sponsors, the publisher or the institution with which the author is affiliated, unless this is clearly specified. Although every effort has been made to ensure the technical accuracy of the contents of Asian Journal of Ophthalmology, no responsibility for errors or omissions is accepted.

Asian Journal of Ophthalmology, APGS, APOTS, and the publisher do not endorse or guarantee, directly or indirectly, the quality or efficacy of any product or service described the advertisements or other material that is commercial in nature in any issue. All advertising is expected to conform to ethical and medical standards. No responsibility is assumed by the APGS, APOTS or the publisher for any injury and/or damage to persons or property as a matter of products liability, negligence or otherwise, or from any use or operation of any methods, products, instructions, or ideas contained in the material herein. Because of rapid advances in the medical Sciences, independent verification of diagnoses and drug dosages should be made.

## Chief editor:

Paul Chew,  
[paul\\_chew@nuhs.edu.sg](mailto:paul_chew@nuhs.edu.sg)

## Managing editor:

Keith Ong

## Editorial office:

Asian Journal of Ophthalmology/  
Kugler Publications,  
P.O. Box 20538,  
1001 NM Amsterdam,  
The Netherlands.  
[info@asianjo.com](mailto:info@asianjo.com)

## Publisher:

Kugler Publications,  
P.O. Box 20538,  
1001 NM Amsterdam,  
The Netherlands.  
[info@kuglerpublications.com](mailto:info@kuglerpublications.com)  
[www.kuglerpublications.com](http://www.kuglerpublications.com)

## Manuscript submissions:

Information for authors is available via the website ([www.asianjo.com](http://www.asianjo.com)), through which all manuscripts should be submitted. For inquiries please contact us at: [info@asianjo.com](mailto:info@asianjo.com).

## Peer-review manager:

Kayoko Welsh,  
[Kayoko.Welsh@asianjo.com](mailto:Kayoko.Welsh@asianjo.com)

## Publication frequency

The Asian Journal of Ophthalmology is published four issues per year (quarterly) electronically. Each issues will consist of approximately 48 pages. A selection of the best papers is published in print twice a year and distributed free of charge at congresses through Kugler Publications or partners.

## Open access policy

The Asian Journal of Ophthalmology provides immediate open access to its content after (free) registration, on the principle that making research freely available to the public supports a greater global exchange of knowledge. There are no fees required to publish in the journal.

## **BOARD OF EDITORS**

### **AUSTRALIA**

Ivan Goldberg

Paul Healey

### **CHINA**

Ning Li Wang

### **HONG KONG (SAR)**

Clement Tham

### **INDIA**

Garudadri Chandra Sekhar

Kulin Kothari

Lingam Vijaya

### **JAPAN**

Yoshiaki Kitazawa

Tetsuya Yamamoto

### **KOREA**

Michael S. Kook

Ki Ho Park

### **MALAYSIA**

Seng Kheong Fang

### **NEW ZEALAND**

Stephen Best

### **SINGAPORE**

Tin Aung

Chelvin C.A. SNG

Lennard Thean

### **TAIWAN**

Jen Chia Tsai

Da Wen Lu

### **THAILAND**

Vilavun Puangsrichareern

Prin Rojanapongpun

### **THE PHILIPPINES**

Manuel Agulto

Mario Aquino

Alejandro Chung

### **UNITED KINGDOM**

Paul Foster

Winnie Nolan

### **USA**

Robert Ritch

## **Focus and scope**

As new technologies and therapeutic interventions are continually being developed, Ophthalmology has become a field of rapid change, particularly in the Asia-Pacific region, where disease patterns and health care delivery differ greatly from those seen in the West. Asian Journal of Ophthalmology was established in 1998 with the aim of disseminating information relevant to Ophthalmology and glaucoma throughout Asia and to interested groups worldwide.

The objectives of Asian Journal of Ophthalmology are as follows:

- To provide a platform for the publication of information with a focus on Ophthalmology in Asia.
- To disseminate information that will improve the care of patients with all types of ophthalmological disorders, with a special focus on glaucoma.
- To increase the understanding of such disorders through reporting of educational activities.
- To publish the results of research programmes to expand knowledge about the causes, prevention, and treatment of ophthalmological disorders.
- To work closely with Asian and international researchers to achieve these aims.
- To provide a forum for young and relatively inexperienced researchers to present their research results as Original Articles via an international platform.
- To maintain and promote relationships with any organization with similar goals.

Although the focus of Asian Journal of Ophthalmology mainly was on glaucoma with close ties to the South-East Asian Glaucoma Interest Group (SEAGIG) in the past, the journal now focuses on the entire spectrum of Ophthalmology. This resulted in collaboration with the Asia Pacific Ophthalmic Trauma Society (APOTS).

The Asian Journal of Ophthalmology and Kugler Publications have started to collaborate since mid 2012 on the publication of the journal. A new website has been launched ([www.asianjo.com](http://www.asianjo.com)), which facilitates all aspects of the peer-review and publication process, from manuscript submission to publication.

**For further information and manuscript submissions  
please visit our website: [www.asianjo.com](http://www.asianjo.com).**

## Table of contents

<b>Internal carotid artery velocities in patients with unilateral non-arteritic anterior ischemic optic neuropathy</b>	<b>129</b>
Karen B. Reyes, Andrew C. Hilado II, James F. Cullen	
<b>The results of therapeutic keratoplasties performed in severely thinned or perforated corneas</b>	<b>135</b>
Bora Yuksel, Menekse Binzet, Umut Duygu Uzunel, Tuncay Kusbeci	
<b>Functional outcome in primary nasolacrimal duct obstruction after successful external dacryocystorhinostomy surgery</b>	<b>143</b>
Syed Ali Raza Rizvi, Mohammad Saquib, Yogesh Gupta, Rakesh Maheshwari, Puneet Maheshwari	
<b>Retinal nerve fiber layer thickness in chronic obstructive pulmonary disease: An optical coherence tomography study</b>	<b>151</b>
Yeap Thye Ghee, Mushawiahti Mustapha, Roslan Harun, Syed Zulkifli Syed Zakaria, Jemaima Che Hamzah, Hairul Nizam Harun, Faridah Hanom Annuar	
<b>The Malaysian Cataract Surgery Registry: Surgically induced astigmatism in phacoemulsification cataract surgery</b>	<b>159</b>
Ming-Yueh Lee, Tasha Hilda, Mariam Ismail, Pik-Pin Goh	
<b>Ocular myiasis in a glioma</b>	<b>173</b>
David Mathew, Satheesh Solomon Selvin, Shilpa Kuruvilla, Thomas Kuriakose	
<b>Combined Möbius syndrome and tarsal kink syndrome — A unique presentation</b>	<b>177</b>
Anuradha Raj, R.C. Nagpal, Renu Dhasmana, Amit Maitreya	
<b>Bilateral lightning induced electric cataract and optic neuropathy</b>	<b>183</b>
David Mathew, Saurabh Kumar Sarma, Jennifer Basaiawmoit	

# NOW AVAILABLE!

## ASIA PACIFIC Glaucoma Guidelines



ASIA-PACIFIC GLAUCOMA SOCIETY

THIRD EDITION

**APGS**  
Asia-Pacific Glaucoma Society

**APGS**  
Asia-Pacific Glaucoma Society

ASIA-PACIFIC GLAUCOMA SOCIETY

# Internal carotid artery velocities in patients with unilateral non-arteritic anterior ischemic optic neuropathy

Karen B. Reyes<sup>1,2</sup>, Andrew C. Hilado II<sup>1</sup>, James F. Cullen<sup>3</sup>

<sup>1</sup>Department of Ophthalmology, Ospital ng Makati; <sup>2</sup>Department of Ophthalmology, Cardinal Santos Medical Center; <sup>3</sup>Singapore National Eye Center

## Abstract

**Aim or Purpose:** This study aims to evaluate and compare the proximal, medial, and distal segments of internal carotid artery (ICA) peak systolic velocities (PSV) in patients with non-arteritic anterior ischemic optic neuropathy (NA-AION) in one eye against the contralateral side with normal eye findings using Doppler ultrasound.

**Methods:** This is a single-center, cross-sectional study of five patients with unilateral NA-AION. The peak systolic velocity (PSV) of the proximal, medial, and distal segments of the ICAs on both sides, one side with NA-AION while the contralateral side had normal eye findings, were compared and analyzed.

**Results:** Four females and one male with a mean age of 59 years (SD = 17 years) were included. PSV of the ICA was measured in three segments: Proximal (PICA), Medial (MICA), and Distal (DICA). Mean PSV of eyes with NA-AION was 143 cm/sec (SD = 177 cm/sec), 159 cm/sec (SD = 189 cm/sec), 98 cm/sec (SD = 34 cm/sec) for PICA, MICA and DICA respectively. Mean PSV of contralateral side without NA-AION was 95 cm/sec (SD = 72 cm/sec), 101 cm/sec (SD = 53 cm/sec), 140 cm/sec (SD = 60 cm/sec) for PICA, MICA and DICA respectively. There was no statistically significant difference between the two groups along the three segments (T-test PICAp = 0.369, MICAp = 0.402, DICAp = 0.112).

**Conclusion:** Mean PSV was higher in eyes with NA-AION at the proximal and medial segments of the ICA, while it was lower at the distal segments compared to the contralateral non-NA-AION side.

**Keywords:** NA-AION, carotid ultrasound, internal carotid artery, peak flow velocity  
The authors have no financial interest in this study.

## Introduction

Anterior ischemic optic neuropathy (AION) is the most common acute optic neuropathy in middle-aged patients, reflecting ischemic damage to the optic nerve head.<sup>1</sup> AION is classified as either arteritic or non-arteritic. The non-arteritic form (NA-AION) is more common and occurs at a mean age of sixty years.

A region-wide census in the Philippines has been reported on the etiologies of optic neuropathies and showed that ischemia is one of the most common cause (50 cases out of 350).<sup>2</sup> In addition, a neuro-ophthalmology census done in Makati City<sup>3</sup> also reported that ischemic optic neuropathy is one of the most common diseases seen in the neuro-ophthalmology clinic and NA-AION accounts for seven out of 28 cases of optic neuropathies for the year 2011. Clinically, patients with NA-AION are

**Correspondence:** Karen B. Reyes

E-mail: [kurr\\_b\\_reyes@yahoo.com](mailto:kurr_b_reyes@yahoo.com)

described to have sudden, painless, loss of vision in one or rarely in both eyes with a hyperemic swollen disc at outset.

The etiology of NA-AION is now accepted as perfusion defect in the optic nerve head blood supply which is via the posterior ciliary arteries which are branches of the internal carotid artery (ICA). An evaluation of the ICA may be helpful in our further understanding of NA-AION. Carotid Doppler Imaging is one of the most common and non-invasive method used to assess the carotid artery,<sup>4,5</sup> particularly in patients suspected to have stenosis where peak systolic velocities (PSV) of the ICA are elevated.<sup>6</sup> Published reports showed a link between stenosis and other ophthalmic disorders such as glaucoma and ocular ischemic syndromes but studies on the relation between NA-AION and carotid artery stenosis have been limited as to date.<sup>7-9</sup> Due to the scarcity of knowledge on the exact mechanism of NA-AION, further studies on the blood supply of the optic nerve head may contribute additional information on this condition.

The purpose of this study is to evaluate and compare the proximal, medial, and distal segments of the cervical internal carotid artery (ICA) peak systolic velocities (PSV) in patients with NA-AION in one eye against the contralateral side with normal eye findings using Doppler ultrasound.

## Patients and methods

This is a single-center cross-sectional study of five patients with unilateral NA-AION at Ospital Ng Makati performed over the course of six months. The peak systolic velocities (PSV) of the proximal, medial, and distal segments of the ICAs on both sides, one side with NA-AION while the contralateral side had normal findings, were compared and analyzed.

Ethics approval was obtained from the local ethics review board. Informed consent was obtained from all subjects. The study was done in accordance with the World Medical Association's Declaration of Helsinki.

Included in the study were consecutive patients clinically diagnosed with NA-AION in one eye by the in-house neuro-ophthalmologist. For this study, NA-AION was diagnosed with the following clinical presentation: patients aged 40 years and above with ischemic risk factors (systemic hypertension, diabetes mellitus, hyperlipidemia) presenting with acute painless loss of vision, dyschromatopsia, a positive relative afferent papillary defect (RAPD) and hyperemic disc edema on the affected eye with a contralateral 'disk at risk' characteristics and visual fields defects on the affected eye showing an altitudinal or nasal defect.<sup>10-12</sup>

Exclusion criteria were patients who had bilateral NA-AION, and those who did not follow the typical clinical presentation of NA-AION such as patients younger than 40 years old, and those with chronic or gradually progressive visual loss. Also excluded were patients with underlying systemic disorders that can cause compressive, toxic, or nutritional optic neuropathies.



## Clinical evaluation

All patients underwent a complete clinical history and neuro-ophthalmologic examination namely: best-corrected visual acuity (BCVA), Ishihara color plates, confrontation visual fields, red-dot perimetry test, ocular motility test, Goldmann applanation tonometry, gonioscopy, anterior and posterior segment examination, cranial nerve examination and automated visual fields examination.

Once a diagnosis of unilateral NA-AION was established, the affected eye with its ipsilateral ICA was labelled as the NA-AION side while the contralateral ICA labelled as the non-NA-AION side.

All patients were fully informed of the nature and details of the procedure, including the benefits and risks involved.

## Carotid Doppler Ultrasound Technique

Carotid Doppler was performed using the the Acuson X300® (Siemens, Erlangen, Germany). Patients were placed on a supine position with the head turned contralateral to the side to be examined. Acoustic coupling gel was applied over the neck and the scan in grayscale B-mode started from the proximal common carotid artery and moved distally. After identifying the carotid artery, color flow information was superimposed on the gray scale image to identify flow within the artery and potential areas of high velocity. Blood going towards the probe was designated as color red and blood going away the probe as color blue. Peak systolic velocities of the proximal ICA (PICA), medial ICA (MICA), distal ICA (DICA) and the presence or absence of plaque and/or turbulence were obtained. The same procedure was repeated on the opposite carotid artery. A hard copy of the examination was taken.

## Data analysis

Statistical analysis was performed using the IBM® SPSS® Statistics Version 20. Mean and standard deviations were calculated. Paired student T-test was used to compare means with the level of significance set at  $P < 0.05$ .

## Results

Five patients were included in the study: four females and one male, with a mean age of 59.6 years ( $SD \pm 17.3$  years). All patients had at least one poorly-controlled ischemic risk factor at the time of NA-ION diagnosis (Table 1). All patients underwent Carotid Doppler examination within two weeks after initial diagnosis.

Table 1. Baseline characteristics of patients included in the study.

Patient	Age	Sex	Onset of symptoms prior to NA-ION diagnosis (weeks)	Blood Pressure (mmHg)	FBS* (mmol/L)	Total Cholesterol (mmol/L)	Medications
1	50	F	4	130/80	25.00	2.99	Losartan 50mg + hydro-chlorothiazide 12.5 mg/ tab OD Aspirin 80mg/tab Clopidogrel 75mg tab, OD Glipizide 5 mg tab OD Metformin 500mg/tab BID Atorvastatin 40mg tab OD
2	50	F	1	120/80	9.00	5.50	No maintenance medication
3	74	F	3	130/80	5.10	7.47	Rosuvastatin 20mg/tab OD
4	42	F	2	130/80	5.00	5.52	Losartan 50mg + hydro-chlorothiazide 12.5 mg/ tab BID Aspirin 80mg/tab OD
5	82	M	4	120/80	8.40	5.53	Enalapril 5mg/tab OD Amlodipine 10mg/tab OD Aspirin 80mg/tab OD Atorvastatin 40 mg/tab OD

Laboratory Values Normal Range: Fasting Blood Sugar\*: 4.11-5.49 mmol/L; Cholesterol: 0.00-5.20 mmol/L

*Presence/absence of turbulence and plaques*

All ICAs evaluated from both sides did not show any turbulence or plaques.

*Proximal internal carotid peak flow velocity*

Mean PSV of the PICA on the NA-AION side was 143 cm/sec with a standard deviation (SD) of 177 cm/sec, while the mean PSV of the PICA on the non-NA-AION side was 95cm/sec with a SD of 72 cm/sec. The mean PSV was higher on the NA-AION side, but was not statistically significant (P = 0.369, Table 2).

*Medial internal carotid peak flow velocity*

Mean PSV of the MICA on the NA-AION side was 159 cm/sec with a standard deviation (SD) of 189 cm/sec while the mean PSV of the MICA on the non-NA-AION side was 101 cm/sec with a SD of 53cm/sec. The mean PSV of the MICA was also higher on the NA-AION side, but was also not statistically significant (P = 0.402, Table 2).

*Distal internal carotid peak flow velocity*

Mean PSV of the DICA on the NA-AION side was 98 cm/sec with a standard deviation (SD) of 34 cm/sec, while the mean PSV of the DICA on the non-NA-AION side was 140 cm/sec with a SD of 60 cm/sec. The mean PSV of the DICA was lower on the NA-AION side, but was not statistically significant (P = 0.112, Table 2).

**Table 2. Comparison of Internal carotid artery peak systolic velocity of unilateral NA-AION.**

		Mean PSV	p-value
Proximal ICA	NA-AION side	143 cm/sec	0.369
	Non-NA-AION side	95 cm/sec	
Medial ICA	NA-AION side	159 cm/sec	0.402
	Non-NA-AION side	101 cm/sec	
Distal ICA	NA-AION side	98 cm/sec	0.112
	Non-NA-AION side	140 cm/sec	

P < 0.05 = level of significance, two-tailed.

**Discussion**

In the few studies concerning the relationship between the ICA and ischemic optic neuropathy, all stated that there was no association between carotid stenosis and the said condition.<sup>13-15</sup> The results were similar in our study, although PICA and MICA PSVs were higher (143 cm/sec and 159 cm/sec respectively) on the NA-AION side, but no turbulence was seen, thus the criteria for stenosis were not fulfilled.

A study evaluating peak flow velocity (PFV) of the ophthalmic artery using transcranial Doppler showed a decreased PFV on the NA-AION side.<sup>7</sup> In another study comparing blood flow velocities of the ophthalmic artery, central retinal artery and posterior ciliary arteries of patients with NA-AION against age-matched controls showed a decreased velocity in the central retinal artery and the nasal posterior ciliary artery in patients with NA-AION.<sup>16</sup>

Assessing the ICA along the neck is easier and more accessible compared to performing a transcranial Doppler. In our study, we found a higher PSV in the proximal and medial ICA of the NA-AION patients but not in their distal ICA. The PSV of the DICA in the NA-AION group was found to be lower. This finding coincides with the above-mentioned studies<sup>7,16</sup> where the PSV of the ophthalmic artery,<sup>7</sup> the central retinal artery and posterior ciliary artery<sup>19</sup> of eyes with NA-AION were lower. The results from our study and from others, although similar, are not statistically significant.

The findings of our research contradict Bernoulli's equation which states that flow velocities increase as a result of constriction or narrowing of a vessel lumen.<sup>7,17</sup> And a failure in autoregulation may also explain why flow velocities are lower in eyes with NA-AION. Furthermore a malfunction in the autoregulatory process has

been reported to occur in vaso-occlusive diseases bringing about compensatory blood flow from other vessels thereby lowering the flow velocity.<sup>7,18-19</sup>

In conclusion, our study has demonstrated that the mean PSV is higher in eyes with NA-AION at the proximal and medial segments of the ICA, while it is lower at the distal segments compared to that on the contralateral non-NA-AION side.

## References

1. Arnold AC. Ischemic optic neuropathy. In: Miller NR, Newman NJ, Biousse V, Kerrison JB (eds.), Walsh and Hoyt's Clinical Neuro-Ophthalmology. 6<sup>th</sup> ed., Vol. I, pp. 349-384. Philadelphia: Lippincott Williams & Wilkins 2005.
2. Garganta RG, Tamesis JM, Ang LT. Common Etiologies of Optic Neuropathies among Filipinos seen in Metro Manila, Philippines: A One-year Retrospective Study. *J Neuroophthalmol* 2012;36(Suppl 1):12.
3. Reyes KB, Dimayuga WA. Incidence of neuro-ophthalmic cases in Makati City, Philippines Neuro-Ophthalmology. *J Neuroophthalmol* 2012;36(Suppl 1):18.
4. Society of Radiologists in Ultrasound. Carotid Artery Stenosis: Gray-Scale and Doppler US Diagnosis – Society of Radiologists in Ultrasound Consensus Conference. *Radiology* 2003;229:340-346.
5. Gerhard-Herman M, Beckman JA, Creager MA. Vascular laboratory testing. In: Creager MA, Beckman JA, Loscalzo J (eds.), *Vascular Medicine A companion to Braunwald's Heart Disease*, 2<sup>nd</sup> ed., pp. 148-155. Philadelphia: Saunders 2013.
6. Gonzales-Tanque M (compiled by). Philippine Society of Vascular Medicine – Philippine Heart Association. Vascular Ultrasound Consensus Workshop 2011.
7. Sanjari MS, Falavarjani KG, Mehrabani M, Ghiasian L, Zamani B. Retrobulbar hemodynamics and carotid wall thickness in patients with non-arteritic anterior ischemic optic neuropathy. *Br J Ophthalmol* 2009;93(5):638-640.
8. Lyons Wait VA, Anderson SF, Townsend JC, *et al*. Ocular and systemic findings and their correlation with hemodynamically significant carotid artery stenosis: a retrospective study. *Optom Vis Sci* 2002;79:353-362.
9. Barkana Y, Harris A, Hefez L, *et al*. Unrecordable pulsatile ocular blood flow may signify severe stenosis of the ipsilateral internal carotid artery. *Br J Ophthalmol* 2003;87:1478-1480.
10. Kerr NM, Chew SS, Danesh-Meyer HV. Non-arteritic anterior ischaemic optic neuropathy: a review and update. *J Clin Neurosci* 2009;16(8):994-1000.
11. Hayreh SS, Zmerman B. Visual field abnormalities in nonarteritic anterior ischemic optic neuropathy: their pattern and prevalence at initial examination. *Arch Ophthalmol* 2005;123:1554-1562.
12. Chua D, Cullen JF. Incipient non-arteritic anterior ischemic optic neuropathy: a distinct clinical entity, the Singapore scene 3. *Singapore Med J* 2014;55(9):473-475.
13. Arnold AC. Pathogenesis of Nonarteritic Anterior Ischemic Optic Neuropathy. *J Neuroophthalmol* 2003;23:157-163.
14. Fry CL, Carter JE, Kanter MC, Tegeler CH, Tuley MR. Anterior ischemic optic neuropathy is not associated with carotid artery atherosclerosis. *Stroke* 1993;24:539-542.
15. Muller M, Kessler C, Wessel K, *et al*. Low-tension glaucoma: a comparative study with retinal ischemic syndromes and anterior ischemic optic neuropathy. *Ophthalmic Surg* 1993;24:835-838.
16. Kaup M, Plange N, Arend KO, *et al*. Retrobulbar hemodynamics in nonarteritic anterior ischemic optic neuropathy. *Br J Ophthalmol* 2006;90:1350-1353.
17. Kagemann L, Harris A, Chung HS, *et al*. Basics and limitations of CDI. In: Pillunat LE, Harris A, Anderson DR, *et al*. (eds.), *Current concepts on ocular blood flow in glaucoma*, pp. 103-110. The Hague: Kugler Publications 1999.
18. Muller M, Schimrigk K. Vasomotor reactivity and pattern of collateral blood flow in severe occlusive carotid artery disease. *Stroke* 1996;27:296-299.
19. Costa VP, Kuzniec S, Molnar LJ, *et al*. Collateral blood supply through the ophthalmic artery: a steal phenomenon analyzed by color Doppler imaging. *Ophthalmology* 1998;105:689-693.

# The results of therapeutic keratoplasties performed in severely thinned or perforated corneas

Bora Yuksel, Menekse Binzet, Umut Duygu Uzunel, Tuncay Kusbeci

Department of Ophthalmology, Izmir Bozyaka Education and Research Hospital, Turkey

## Abstract

**Purpose:** To report the visual and anatomic outcomes of therapeutic keratoplasties performed in severely thinned or perforated corneas.

**Methods:** Medical records of 32 eyes of 32 patients operated between 2000 to 2014 were reviewed retrospectively. Indications, preoperative findings, surgical procedures, donor size, post-operative graft clarity, visual improvement, globe integrity and follow-up periods were analyzed. Main outcome measures were anatomical success, graft clarity and visual acuity.

**Results:** Mean age was 57,3 (20-85). Sixteen patients were male and 16 female. Mean follow-up was 28.9 (14-132) months. Surgical indication was infectious in 17 (53.1%) and non-infectious in 15 eyes (46.9%). Infectious causes were bacterial ulcer 8 (25.0%), herpes simplex 7 (21.9%) and fungus in two (6.3%) eyes. Non-infectious causes were traumatic in five (15.6%), Stevens-Johnson syndrome in two (6.3%), desmatocele in one (3.1%) other causes (bullous keratopathy, interstitial keratitis and lagophthalmos). The underlying cause of corneal melting was unknown in three eyes (9.3%). Combined PK was performed in 18 of 32 eyes (56.3%), PK alone in 14 (43.8%). Clear graft rate was 25/32 (78.1%) at 14th month. Anatomical integrity was restored in 19 (90.4%) of 21 perforated corneas. PK anatomical success was evaluated by the Kaplan-Meier survival analysis. Mean estimated graft survival was  $46.3 \pm 9.8$  (27.2-65.5) months and median  $30.0 \pm 8.0$  (14.3-45.7) months. Visual improvement was obtained in 23 eyes (71.9%). Visual acuity was  $\geq 0.05$  in five eyes (15.6%) preoperatively, it increased to 20 eyes (62.5%) post-operatively.

**Conclusion:** Therapeutic PK is an viable treatment option in the management of corneal thinning and perforation in the management of corneal melting and perforations due to varying aetiologies. It preserves the globe integrity and provide useful vision in majority of the cases.

**Keywords:** Corneal thinning, perforation, penetrating keratoplasty, therapeutic

## Introduction

Corneal melting and perforation may occur in infections, inflammatory conditions, ocular surface disorders, long term use of steroids and trauma.<sup>1</sup> It may lead to complicated cataract, secondary glaucoma, scleritis or endophthalmitis that may be reversed by prompt intervention, otherwise phthisis bulbi can occur. Recalcitrant bacterial or fungal keratitis unresponsive to medical treatment are usually

**Correspondence:** Bora Yuksel, Department of Ophthalmology, Izmir Bozyaka Education and Research Hospital, Turkey.

E-mail: [drborayuksel@gmail.com](mailto:drborayuksel@gmail.com)

progressive and may cause scleral invasion or corneal perforation. Corneal perforation is an emergency situation which may result in irreversible visual loss, thus early intervention to restore the anatomical integrity of the globe is mandatory. Prompt surgical intervention performed before actual corneal perforation arises is technically easier and reduces the risk of post-operative complications such as endophthalmitis, peripheral anterior synechia and secondary angle closure.<sup>2</sup>

In addition to nonsurgical treatments such as bandage contact lenses or tissue adhesives, surgical interventions including simple suturing, amniotic membrane transplantation (AMT), penetrating keratoplasty (PK) anterior lamellar keratoplasty (ALK) and lamellar or full thickness patch grafting may be utilized.<sup>1</sup> Developments in surgical techniques and tissue adhesives reduced the enucleation rate in corneal perforations.<sup>3</sup> Treatment preference is determined by the size and localization of the perforation as well as the underlying cause.<sup>1,4</sup> Therapeutic keratoplasty is a surgical procedure whose primary purpose is either to restore the structural integrity of the eye (tectonic keratoplasty) or to resolve an infectious or inflammatory keratitis. It is indicated in severely thinned, ectatic or perforated corneas, as well as corneal tissue loss, fistula and melting due to autoimmune diseases. It may also provide visual improvement in certain cases.<sup>5,6</sup> Aim of this retrospective study is to report the outcomes of 15 years of therapeutic PKs performed in a tertiary referral hospital in Turkey.

## Material and methods

This study was approved by the ethical committee of our hospital and followed the tenets of the Declaration of Helsinki. Thirty-two eyes of 32 patients who underwent therapeutic PK between 2000 and 2014 were reviewed retrospectively. Small perforations treated with non-surgical methods such as bandage contact lens and tissue adhesive or minor surgeries like primary suturation, AMT, conjunctival flap as well as tectonic patch grafts were excluded. Indications, preoperative findings, surgical procedures, donor size, postoperative corneal graft clarity, visual acuity, globe integrity and follow-up periods were analyzed. Main outcome measures were the anatomical success, graft clarity and visual acuity.

All sutures were removed at one year. Post-operative best spectacle corrected visual acuity (BSCVA) was measured one month after suture removal which corresponds to 14th postoperative month. The percentage of the eyes showing visual improvement and with a BSCVA  $\geq 0.05$  were analyzed. Percentage of anatomical success and graft clarity were also evaluated at this time point, since it contains full data for all cases. Transparent or semi-transparent corneal grafts with no sign of infection were defined as clear. If there is no melting or perforation in the graft, globe integrity has been saved and complete eradication of primary infection has been achieved, it was defined as anatomical success, yet the graft is not clear. The survival time for both PK anatomical success and optical clarity through follow-up were evaluated by Kaplan-Meier survival analysis. Cox regression model for survival analysis was performed to determine the factors that may have effect on graft survival.

After a detailed history, BCVA and slit lamp biomicroscopy was performed, intraocular pressure (IOP) was measured with Goldmann applanation tonometry at baseline and follow-up visits. Visual acuity was measured with a Snellen chart at six meters and given in decimal scores. Fundus examination was performed with a 90-D lens. If the fundus is not visible, ocular ultrasonography was utilized. In eyes with keratitis, culture material was taken via corneal scrapings or from the recipient corneal buttons during surgery. Samples were sent to microbiology laboratory for also direct microscopy, Gram and Giemsa staining. Previous surgeries were noted in patients with chronic anterior segment disease. Systemic and topical antimicrobial treatment was given in patients with keratitis. The treatment continued until the corneal infiltration and anterior segment inflammation subside. All surgeries were performed under general anesthesia within one to seven days of hospitalization. A Hessburg-Barron vacuum trephine was used for recipient trephination. Donor corneas were cut from the endothelial side with a disposable donor punch. In two cases with corneal melting extending to the sclera, a manual dissection was carried out by using a caliper and corneal scissors. The donor corneas were also trimmed to fit the recipient opening in these cases.

Concurrent procedures performed during PK were as follows: Open-sky extracapsular cataract extraction and intraocular lens (IOL) implantation, transsclerally fixated IOL implantation, removal of anterior chamber IOL, lateral tarsoraphy in eyes with decreased corneal sensitivity like in herpetic keratitis, synechiotomy in eyes with anterior or posterior synechiae, pupilloplasty in ectopic pupils and anterior vitrectomy in aphakic eyes. A single running 10-0 nylon suture was used for PK. Interrupted sutures were used in large PKs performed by manual preparation of both the donor and the recipient. A subconjunctival gentamycin and dexamethasone was injected in all patients at the end of surgery. Prophylactic oral acyclovir was used for one year following PK in patients with herpetic keratitis.

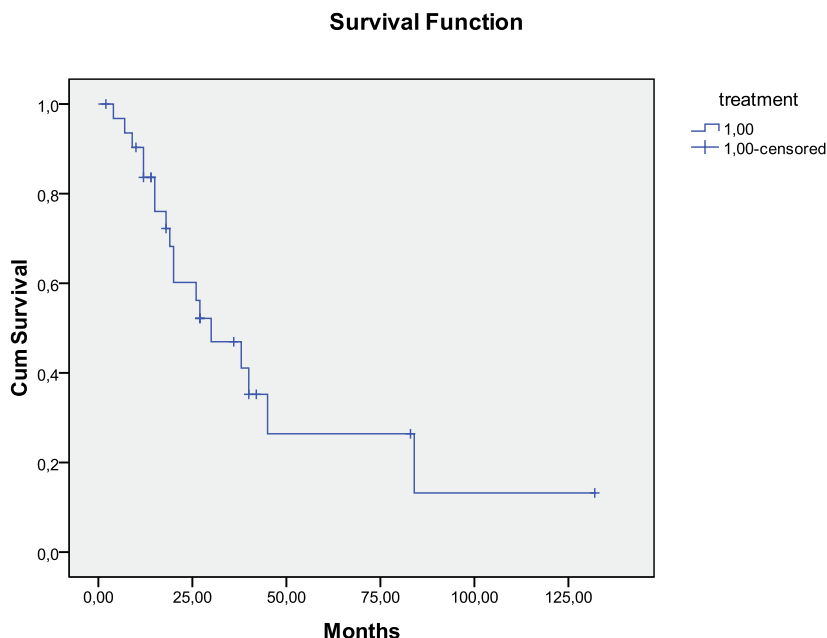
## Results

Mean age was 57,3 (20-85). Sixteen patients were male and 16 female. Mean follow-up was 28.9 (14-132) months. Surgical indications were split into two groups; infectious and non-infectious. Seventeen (53.1%) of 32 eyes were infectious and 15 (46.9%) were non-infectious. Infectious causes were bacterial ulcer eight (25.0%), herpes simplex seven (21.9%) and fungus in two (6.3%) eyes. Non-infectious causes were traumatic in five (15.6%), Stevens-Johnson syndrome two (6.3%), desmatocele due to long-term topical steroid use one (3.1%), other causes three (bullous keratopathy, interstitial keratitis and lagophthalmos). The underlying cause was unknown in three of non-infectious corneal melt.

On initial examination, corneal perforation was present in 21 of 32 eyes (65.6%). Other biomicroscopic findings were superficial/deep neovascularization 12 (37.5%), cataract nine (28.1%), iris prolapse five (15.6%), anterior/posterior synechiae five (15.6%), symblepharon two (6.3%), aphakia two (6.3%) and Fuch's dystrophy one (3.1%). Previous surgeries, attempted to alleviate the corneal problems, included AMT in 14 eyes (43.8%), lateral tarsoraphy six (18.8%), PK in five (15.6%), conjunctival

flap two (6.3%), tissue adhesive two (6.3%), primary suturation one (3.1%) and limbal autograft in one eye (3.1%).

Surgical techniques performed on patients with corneal thinning or perforation are as follows: Combined PK (with aforementioned procedures) in 18 eyes (56.3%) and PK alone in 14 (43.7%). The donor corneal diameter varied between 7.50-7.75 mm in six eyes (18.7%) and 8.0-11.0 mm in 26 eyes (81.3%). The anatomical integrity was preserved in 19 (90.4%) of 21 eyes with corneal perforation. Overall PK anatomic success rate was 96.8% and graft clarity rate was 78.1% at postoperative 14th month. The survival time for PK anatomical success was evaluated by the Kaplan-Meier survival analysis (Fig. 1). Mean estimated graft survival time was found as  $46.3 \pm 9.8$  (27.2-65.5) months and median  $30.0 \pm 8.0$  (14.3-45.7) months. The survival time for PK optical clarity was also evaluated by the Kaplan-Meier survival analysis. Mean estimated survival time for optical clarity was found as  $31.3 \pm 5.1$  months and median  $26.0 \pm 3.0$  months.



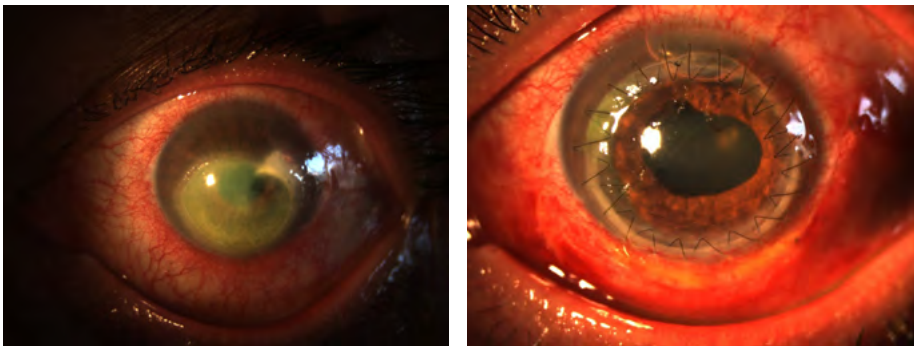
**Fig. 1. Kaplan-Meier analysis for cumulative survival for PK anatomical success.**

Cox regression model for survival analysis was performed to determine the factors which may affect the graft survival (clarity). It revealed no association between age, gender, presence of infection, previous surgical procedure or corneal perforation with graft survival ( $p = 0.268$ ;  $p = 0.270$ ;  $p = 0.296$ ;  $p = 0.065$ ;  $p = 0.238$  respectively), whereas presence of postoperative complications showed a negative effect on graft survival ( $p = 0.031$ ).



Visual improvement was achieved in 23 of 32 eyes (71.9%). While BSCVA was 0.05 or better in only five eyes (15.6%) preoperatively, this rate increased to 20 eyes (62.5%) postoperatively. Postoperative complications are summarized in Table 1. None of the eyes were lost. Postoperative IOP elevation was controlled with topical antiglaucomatous medication in all cases. In three eyes with low postoperative vision, indirect ophthalmoscopy revealed total glaucomatous atrophy, retinal detachment and primary optic atrophy. Graft rejection was successfully treated with intravenous and topical steroids in two eyes, whereas a repeat PK was performed in another two eyes. AMT was performed in two of six eyes with postoperative persistent epithelial defect, one eye required repeat PK. Re-grafting was carried out overall in five eyes including two graft rejections, one descematocele, one graft melting and one fungal keratitis recurrence.

Graft melting occurred in a 29-year-old female with Stevens-Johnson syndrome. Postoperative persistent epithelial defect and recurrent trichiasis were the main causes for failure in this patient. Vigorous treatment of trichiasis and permanent use of a soft bandage contact lens provided the second graft to be successful. Fungal keratitis recurrence occurred in a 51-year-old male at two months of surgery. Patient presented with keratitis recurrence at wound margin and graft infiltration. Early suture loosening and fungal activation were the main causes for failure. A re-graft resulted in complete cure in this patient. Full recovery was achieved in remaining eyes with keratitis by means of a single therapeutic PK (Fig. 2).



**Fig. 2.** 67-year-old male. Therapeutic PK for the treatment of a recalcitrant corneal ulcer resistant to medical therapy. Visual acuity was counting fingers at presentation (left). One week after surgery, visual acuity improved to 0.1 with complete cure (right).

## Discussion

Despite the developments in medical treatment, surgical intervention is usually necessary in patients with severely thinned or perforated corneas.<sup>7,8</sup> In the current study, therapeutic PK was used to treat these conditions and anatomical integrity of the globe was preserved in 19 (90.4%) of 21 corneal perforations. Likewise, Sharma *et al.* reported an anatomical success in 89.7% of 506 therapeutic PKs for the treatment of refractory keratitis.<sup>9</sup> In another series, anatomical integrity was restored

in 91.3% of 23 corneal perforations.<sup>2</sup> Sukhija *et al.* reported that rate as 90.0%.<sup>10</sup> Although the primary goal of therapeutic PK is to restore the anatomical integrity of the globe, a visual improvement may also be achieved.<sup>11</sup> Visual acuity improved in 71.9% of our patients. Postoperative BCVA was over 0.05 in 62.5%. Jonas *et al.* reported visual gain in 90.0% (8). Hanada *et al.* reported a visual improvement in 85.0% and a graft survival in 67.0% of 20 cases.<sup>12</sup> Killingsworth *et al.* reported 70.0% graft survival rate and visual acuity over 0.3 in 43.0% in their series of PK for infectious keratitis.<sup>5</sup> In our study, PK anatomic success rate was 96.8% and graft clarity rate was 78.1% at postoperative 14th month.

Recurrence is an important problem after PK for fungal keratitis. In Ti *et al.*'s series of 92 therapeutic PK for infectious keratitis, the treatment was unsuccessful in 15 eyes that showed progression to endophthalmitis or evisceration. Of these 15 eyes, 11 were fungal keratitis.<sup>13</sup> Li *et al.* reported recurrence in 11.2% of 116 patients who had PK for fungal keratitis and four of these eyes were enucleated.<sup>14</sup> In our study, recurrence occurred in one of two fungal keratitis and full recovery was achieved by repeat PK. Acanthamoeba keratitis is associated with even higher recurrence rates.<sup>15</sup> In their series of therapeutic PK for keratitis, Chen *et al.* achieved a clear graft rate at one year in 68.8% of 32 bacterial keratitis, 51.3% of 39 fungal keratitis and 78.6% of 14 acanthamoeba keratitis.<sup>16</sup> The results were worse in fungal keratitis in terms of eradication of the infection, graft clarity and anatomical integrity. Graft rejection occurred in four eyes (12.5%) of our study. Three of these were herpes simplex keratitis patients already using prophylactic acyclovir.<sup>17</sup>

Preferred surgical technique is closely related with anatomical and functional results. In a series of 31 eyes, lamellar keratoplasty was used in seven eyes, PK in ten, patch graft in seven and AMT in seven eyes. Anatomical integrity was achieved in all and visual improvement in 25 of these eyes.<sup>4</sup> In another series of 41 eyes including 24 tectonic PK and nine lamellar keratoplasty, anatomical success was reported as 85.4%.<sup>18</sup> Soong *et al.* performed lamellar keratoplasty in 80 eyes with corneal thinning and suggested that lamellar surgery was superior to the full thickness grafting.<sup>19</sup> Lamellary keratoplasty may be preferred in non-perforated descemetocoeles and infective lesions not involving deeper stromal layers.<sup>13</sup> However, interface haze may limit the visual improvement in some cases.<sup>4</sup> Surgical preference usually depends on clinical practise. Some surgeons prefer to attempt lamellar or patch grafts first to tide over the initial bout of inflammation, before a definitive graft to improve the chances of survival and reduce the complications.

The major complications of PK are peripheral anterior synechiae, secondary glaucoma and graft rejection. Larger donor size used in therapeutic PK may adversely affect the graft survival and IOP control.<sup>14</sup> In addition to 9.0 mm or larger donor, active inflammation, ocular surface disorder, corneal vascularization, lid deformities and corneal perforation are also reported as negative prognostic factors.<sup>6</sup> In our study, the graft diameter was between 8.0 to 11.0 mm in 81.3% of the eyes and it was  $\geq 8.0$  mm in four eyes with graft rejection. The most frequent complication observed in our patients was IOP elevation (18.9%) that was controlled with medication. Ang *et al.* reported epitheliopathy as the most often complication

followed by glaucoma, recurrence of bacterial or fungal keratitis and cataract.<sup>6</sup>

Limitations of the current study are its retrospective and single center nature with relatively few number of cases. Also our series include no lamellar keratoplasties which may be used in predescemetic lesions. Our study included PK cases with therapeutic indication in a relatively mixed patient group including perforated corneas in which a tectonic support has also been provided. However, purely tectonic patch grafts were excluded from the study to ensure patient homogeneity.

In conclusion, therapeutic PK is a viable treatment option in the management of corneal thinning and perforation. If used in proper indication, it can restore the anatomical integrity of the eye and provide visual improvement in majority of the cases.

**Table 1. Postoperative complications in 32 study eyes.**

Postoperative condition	No of eyes	Percentage (%)	Mean time of occurrence (months $\pm$ SD)
IOP elevation	7	21.9	22.3 $\pm$ 5.2
Persistent epithelial defect	6	18.8	13.4 $\pm$ 8.6
Graft rejection episode	4	12.5	20.7 $\pm$ 7.0
Corneal vascularization	3	9.4	23.0 $\pm$ 4.2
Posterior synechiae	3	9.4	5.3 $\pm$ 5.2
Cataract	2	6.3	8.0 $\pm$ 4.2
Descematocele	2	6.3	63.0 $\pm$ 66.5
Graft melting	1	3.1	27.0
Fungal keratitis recurrence	1	3.1	2.0

IOP: Intraocular pressure.

## Acknowledgement

Authors are thankful to Esra Erikmen from our eye bank staff for her efforts in data collection.

## References

1. Jhanji V, Young AL, Mehta JS, Sharma N, Agarwal T, Vajpayee RB. Management of corneal perforation. *Surv Ophthalmol* 2011;56:522-538.
2. Nurözler AB, Salvarli S, Budak K, Onat M, Duman S. Results of therapeutic penetrating keratoplasty. *Jpn J Ophthalmol* 2004;48:368-371.
3. Bernauer W, Ficker LA, Watson PG, Dart JK. The management of corneal perforations associated with rheumatoid arthritis: an analysis of 32 eyes. *Ophthalmology* 1995;102:1325-1337.
4. Yokogawa H, Kobayashi A, Yamazaki N, Masaki T, Sugiyama K. Surgical therapies for corneal perforations: 10 years of cases in a tertiary referral hospital. *Clin Ophthalmol* 2014;8 2165-2170.
5. Killingsworth DW, Stern GA, Driebe WT, Knapp A, Dragon DM. Results of therapeutic penetrating keratoplasty. *Ophthalmology* 1993;100(4):534-541.

6. Ang M, Mehta JS, Sng CCA, Htoon HM, Tan DTH. Indications, outcomes and risk factors for failure in tectonic keratoplasty. *Ophthalmology* 2012;119(7):1311-1319.
7. Rana M, Savant V. A brief review of techniques used to seal corneal perforation using cyanoacrylate tissue adhesive. *Cont Lens Anterior Eye* 2013;36(4):156-158.
8. Jonas JB, Rank RM, Budde WM. Tectonic sclerokeratoplasty and tectonic penetrating keratoplasty as treatment for perforated or predecemetal corneal ulcers. *Am J Ophthalmol* 2001;132:14-18.
9. Sharma N, Jain M, Sehra SV, *et al.* Outcomes of therapeutic penetrating keratoplasty from a tertiary eye care centre in northern India. *Cornea* 2014;33(2):114-118.
10. Sukhija J, Jain AK. Outcome of therapeutic penetrating keratoplasty in infectious keratitis. *Ophthalmic Surg Lasers Imaging* 2005;36(4):303-309.
11. Sony P, Sharma N, Vajpayee RB, Ray M. Therapeutic keratoplasty for infectious keratitis: a review of the literature. *CLAOJ* 2002;28:111-118.
12. Hanada K, Igarashi S, Muramatsu O, Yoshida A. Therapeutic keratoplasty for corneal perforation; clinical results and complications. *Cornea* 2008;27(2):156-160.
13. Ti SE, Scott JA, Janardhanan P, Tan DT. Therapeutic keratoplasty for advanced suppurative keratitis. *Am J Ophthalmol* 2007;143(5):755-762.
14. Li C, Zhao GQ, Che CY, *et al.* Effect of corneal graft diameter on therapeutic penetrating keratoplasty for fungal keratitis. *Int J Ophthalmol* 2012;5(6):698-703.
15. Robaei D, Carnt N, Minassian DC, Dart JK. Therapeutic and optical keratoplasty in the management of *Acanthamoeba* keratitis: risk factors, outcomes, and summary of the literature. *Ophthalmology* 2015;122(1):17-24.
16. Chen WL, Wu CY, Hu FR, Wang IJ. Therapeutic penetrating keratoplasty for microbial keratitis in Taiwan from 1987 to 2001. *Am J Ophthalmol* 2004;137(4):736-743.
17. Garcia DD, Farjo Q, Musch DC, Sugar A. Effect of prophylactic oral acyclovir after penetrating keratoplasty for herpes simplex keratitis. *Cornea* 2007;26(8):930-934.
18. Vanathi M, Sharma N, Titiyal JS, *et al.* Tectonic grafts for corneal thinning and perforations. *Cornea* 2002;21:792-797.
19. Soong HK, Farjo AA, Katz D, *et al.* Lamellar corneal patch grafts in the management of corneal melting. *Cornea* 2000;19:126-134.

# Functional outcome in primary nasolacrimal duct obstruction after successful external dacryocystorhinostomy surgery

Syed Ali Raza Rizvi<sup>1</sup>, Mohammad Saquib<sup>1</sup>, Yogesh Gupta<sup>1</sup>,  
Rakesh Maheshwari<sup>1</sup>, Puneet Maheshwari<sup>2</sup>

<sup>1</sup>Institute of Ophthalmology, Jawaharlal Nehru Medical College, AMU, Aligarh UP, India; <sup>2</sup>Department of Oto-Rhino-Laryngology, Era's Lucknow Medical College and Hospital, Lucknow, UP, India

## Abstract

**Aim:** To assess the functional outcomes of external dacryocystorhinostomy (DCR) surgery in symptomatic patient with primary nasolacrimal duct obstruction.

**Design:** Prospective, clinical interventional study.

**Methods:** This study was conducted in initially 57 consecutive (57 eyes) patients and ultimately 50 consecutive (50 eyes) patients with primary acquired nasolacrimal duct obstruction admitted in a tertiary eye care center. Functional outcome comprises of symptom improvement which includes absence of epiphora, improvement in vision, routine work, occupational work, mood, embarrassment. Assessment was done by pre- and postoperative questionnaires at two, six and 12 months postoperatively. Anatomic success was assessed by lacrimal syringing, fluorescein dye disappearance test (FDDT) and endoscopic view of osteotomy. Statistical significance between preoperative and postoperative symptoms (functional outcome assessment) was analyzed using the McNemar's test.

**Results:** Postoperatively, marked improvement in subjective symptoms, i.e., difficulty in vision (93.5%), routine work (95.6%), occupational work (95.8%), mood (95%) and embarrassment (94%) was seen with an anatomic success of 96%.

**Conclusions:** In primary acquired nasolacrimal duct obstruction (PANDO) patients, symptoms bother the patient significantly. However, successful DCR surgery has a beneficial effect on the patient's physical and social health, thereby changing the quality of life of patients markedly.

**Keywords:** External dacryocystorhinostomy, PANDO, functional outcomes, anatomic success

## Introduction

Primary acquired nasolacrimal duct obstruction (PANDO) is a common cause of epiphora in adults.<sup>1,2</sup> Epiphora is a common, annoying symptom, embarrassing the patient both socially and functionally and it may even endanger the eye. It is interesting to note that nasolacrimal duct obstruction is a disorder in which the subjective problem does not always correlate with the objective findings. Patients also frequently complain of visual blur, difficulty in occupational work, routine work,

**Correspondence:** Syed Ali Raza Rizvi, Ophthalmic Plastic Surgery and Ocular Oncology Service, Institute of Ophthalmology, Jawaharlal Nehru Medical College, AMU, Aligarh. UP.202002. India.  
E-mail: [dralirazal2@hotmail.com](mailto:dralirazal2@hotmail.com)

embarrassment, and poor mood due to nasolacrimal duct obstruction.

Anatomical success of DCR surgery based on patient's symptoms and severity of tearing may not always correlate.<sup>3</sup> Evaluation of watering following surgery and professional and social impact are necessary to address objective successful surgery.

Until now, DCR has had objective anatomical measures of success. Previously published studies about DCR have shown that patient satisfaction may not necessarily correlate with objective success rates.<sup>4,5</sup> It is felt that an evaluation of a broader range of symptoms related to watery eye was necessary to address the issue of whether patients had actually improved in real life terms following objectively successful surgery. Thus, the main aim of this study is to evaluate the functional outcomes (symptom improvement) in patients with nasolacrimal duct obstruction, evaluated prospectively before and after successful DCR surgery.

## Methods

This prospective, clinical interventional study was conducted on 57 consecutive (57 eyes) in-patients of PANDO admitted in a tertiary eye care center. Informed consent was taken from all the patients who were included in the study. The purpose, method and basis of the study were conveyed to all of the patients recruited. The study was approved by the Institutional Ethics and Research Advisory Committee of the Institute and is according to the declaration of Helsinki.

All consecutive cases of PANDO admitted for surgery were included in the study. Exclusion criteria were children less than 12 years of age, canalicular or common canalicular block, failed DCR surgery, secondary nasolacrimal duct obstruction and patients unwilling to participate in the study.

All patients were subjected to detailed clinical evaluation which includes visual acuity measurement, Schirmer's test, lacrimal syringing, fluorescein dye disappearance test (FDDT) and nasal examination to rule out any contra-indication for DCR surgery.

A questionnaire was given to all the preoperative patients included in the study. Patients were asked about difficulty in vision, routine work, professional work, mood and embarrassment. The overall severity of this symptomology was graded as no symptoms at all (grade 0), mild (grade 1), moderate (grade 2) or severe symptoms (grade 3) (Table 1).<sup>6</sup>

Table 1.<sup>6</sup> Questionnaire for Subjective Assessment.

<b>Does your watery-eye problem bother you?</b>		Y	N
<b>If it does bother you, does it interfere with your:</b>	Vision?	Y	N
	Routine work?	Y	N
	Occupational work?	Y	N
	Mood?	Y	N
<b>If it does interfere, is it: (choose one)</b>	A little? (mild)		
	A moderate amount?		
	A great deal? (severe)		
<b>Does your watery eye become embarrassing?</b>		Y	N
<b>If it does become embarrassing, is it: (choose one)</b>	A little? (mild)		
	A moderate amount?		
	A great deal? (severe)		

(Y- YES, N- NO)

Grading system: No symptoms – Grade 0; Mild symptoms – Grade 1; Moderate symptoms – Grade 2; Severe symptoms – Grade 3.

After informed consent, the patients underwent DCR surgery by external approach. All surgeries were performed under infratrochlear block with I.V sedation, by a single surgeon. External DCR were performed by a short ten-mm straight incision, positioned at half the distance between the medial canthus and mid-point of the nasal bridge and not extending above the level of the medial canthus.

A skin flap was raised, then orbicularis fibers were divided to reach the medial canthal tendon. The periosteum anterior to the medial canthal tendon was incised and reflected to expose the lacrimal fossa. The lacrimal sac was encountered and carefully reflected laterally exposing the fossa. A large osteotomy of 15 x 15 sq. mm was created. Nasal mucosal and lacrimal mucosal flaps were fashioned, the posterior flaps were sacrificed, and the anterior flaps were sutured using 6-0 Vicryl sutures. The medial canthal tendon was repositioned. To give subcutaneous sutures, 6-0 Vicryl was used as well and the skin was closed with fine 6-0 Prolene subcuticular sutures. Anatomic success include a patent lacrimal drainage system as determined by lacrimal syringing, fluorescein dye disappearance test, and endoscopic view of the osteotomy site.

Functional outcomes of surgery include absence of epiphora, decrease difficulty in vision, improved performance of routine and occupational work, better mood, and reduced embarrassment, which were assessed by post-operative questionnaires, conducted at two, six and 12 months following surgery. Seven patients were lost to follow-up, so ultimately the study was conducted on 50 (50 eyes) patients.

Statistical significance between preoperative and postoperative symptoms

(functional outcome assessment) was analyzed using McNemar's test. Data were analyzed using SPSS version 20. P-value  $\leq 0.05$  was considered statistically significant.

## Results

Out of 57 cases who underwent DCR, seven patients did not turn up for follow-up and were excluded from our study. In our study, the majority of the patients [16 (32%)] were in age group of 41- 50 years. Of the total number of patients, there were 39 females (78%) and 11 males (22%). Nineteen (38%) cases concerned the right side, 31 (62%) cases the left side.

Out of 50 cases of PANDO, 31 (62%) cases had difficulty in vision. Difficulty in routine work, occupational work and embarrassment in social gathering was seen in 23 (46%), 24 (48%) and 19 (38%) cases respectively. Mood disorder was the major problem in most of the cases of PANDO, namely 44 (88%) (Table 2).

Although anatomic and functional success was assessed at different time intervals, the final outcome of success was measured at 12 months postoperatively to get unbiased results. Delayed assessment helped us to rule out early objective success and to include cases of late failure if there were any. Anatomic success in our study was seen in 48 (96%) of cases 12 months postoperatively. After successful DCR surgery marked improvement was seen in subjective symptoms, *i.e.*, difficulty in vision (93.5%), routine work (95.6%), occupational work (95.8%), embarrassment (94%) and mood (95%) (Table 2). It was seen that symptoms of patient decreased significantly ( $P < 0.05$ ) indicating that successful external dacryocystorhinostomy changed quality of life markedly in these patients (Fig. 1). Similarly, functional grading also improved significantly 12 months postoperatively ( $P < 0.05$ ) (Table 3).

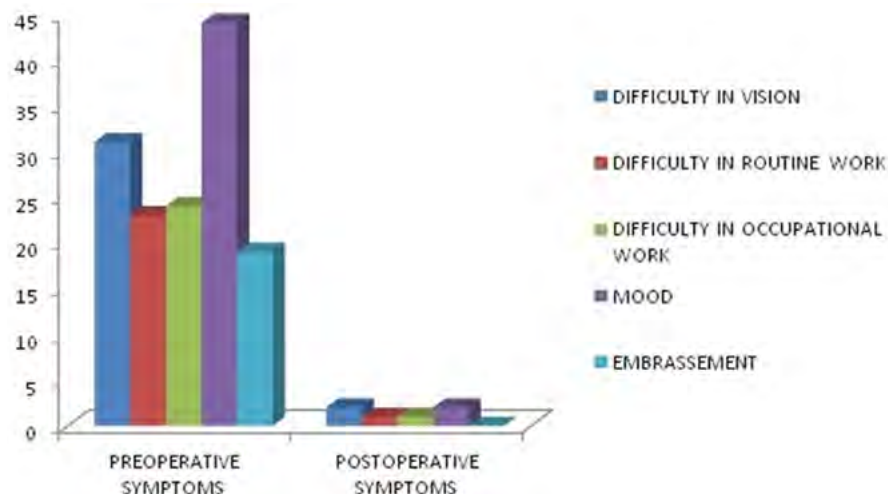


Fig. 1. Showing subjective symptoms preoperatively and 12 months postoperatively.



Table 2. Effect of DCR surgery on symptoms of PANDO (functional outcome assessment).

	Difficulty in vision	Difficulty in routine work	Difficulty in occupational work	Mood	Embarrassment
<b>Preoperative</b>	31 (62%)	23 (46%)	24 (48%)	44 (88%)	19 (38%)
<b>Postoperative (12 months)</b>	2 (6.5%)	1 (4.4%)	1 (4.2%)	2 (5%)	1 (6%)
<b>Postoperative improvement in symptoms</b>	29 (93.5%)	22 (95.6%)	23 (95.8%)	42 (95%)	18 (94%)
<b>P value</b>	< 0.006	< 0.01	< 0.01	< 0.0001	< 0.05

Table 3. Grading of preoperative and postoperative symptoms at 12 months.

Preoperative symptoms	Vision	Routine work	Occupational work	Mood	Embarrassment
<b>Grade 0</b>	19 (38%)	27 (54%)	26 (52%)	6 (12%)	31 (62%)
<b>Grade 1</b>	22 (44%)	14 (28%)	13 (26%)	27 (54%)	9 (18%)
<b>Grade 2</b>	6 (12%)	5 (10%)	8 (16%)	12 (24%)	8 (16%)
<b>Grade 3</b>	3 (6%)	4 (8%)	3 (6%)	5 (10%)	2 (4%)
Postoperative symptoms	Vision	Routine work	Occupational work	Mood	Embarrassment
<b>Grade 0</b>	48 (96%)	49 (98%)	49 (98%)	48 (96%)	49 (98%)
<b>Grade 1</b>	1 (2%)	1 (2%)	1 (2%)	1 (2%)	1 (2%)
<b>Grade 2</b>	1 (2%)	-----	-----	1 (2%)	-----
<b>Grade 3</b>	-----	-----	-----	-----	-----
<b>P value</b>	< 0.05	< 0.05	< 0.05	< 0.05	< 0.05

## Discussion

External DCR is the gold standard treatment for nasolacrimal duct obstruction because of patient acceptance, low cost, and high success rate. It can be performed safely under local anesthesia, on an outpatient basis, in elderly individuals.<sup>7-12</sup>

The outcome of external DCR surgery can be measured by both anatomical and functional indicators. It is being increasingly recognized that anatomical patency does not always translate into good functional outcome. Some patients with an anatomically patent nasolacrimal system still have subjective symptoms.<sup>13</sup> Hence,

both objective and subjective outcome should be assessed for the success of DCR surgery.

Olver<sup>14</sup> in 2003 suggested that success rates should be measured and compared using strict outcome criteria taking in account both functional and anatomical success and an adequate length of follow-up. We have used the similar criteria to gauge the objective and subjective success after an eventful DCR surgery.

Rose<sup>15</sup> describes the lacrimal paradox, where anatomical success may not correlate with success in control of symptoms and vice versa. He describes the signs and symptoms of drainage disorders to be either volume related or flow related. Volume-related backwash from the lacrimal sac can in most cases be treated with appropriate surgery. However, flow-related characteristics are largely due to limitation or tear conductance from the lateral canthus to the nose. Symptom relief of flow-related symptoms is not achievable in every patient.

Mansour *et al.*<sup>16</sup> found that in 139 patients with PANDO who had external DCR, the subjective rate based on a retrospective symptom score was 89% after one year. They stated that anatomic patency does not always translate into good functional outcome, hence the functional outcome alone provide good pictures regarding DCR outcome. Lester<sup>17</sup> took a sample size of 49 cases and nine months follow-up and concluded a functional success of 41 (83.7%).

Mathew *et al.*<sup>18</sup> described 'patient satisfaction' in a retrospective study and telephone questionnaire comparing non-laser endoscopic DCR and external DCR, and found no significant difference between the two for patient satisfaction (75% vs 86%, respectively). Tripathi *et al.*<sup>19</sup> assessed the success of laser endonasal endoscopic DCR using both subjective (questionnaire) and objective (sac washout) measures.<sup>15</sup> The questionnaire asked to what degree the watering was cured, with 65% of patients declaring a complete cure, compared with 91% of patients with objective success.

Moore *et al.*<sup>20</sup> evaluated mechanical and laser endoscopic DCR in 62 patients with PANDO including subjective reporting of tearing as an outcome measure. There was a 71% and 83% subjective success rate, respectively, but tearing alone was measured.

Cheung *et al.*<sup>6</sup> evaluated a wide range of symptoms in patients with functional (FNLDO) and primary acquired nasolacrimal duct obstruction, before and after successful DCR surgery. Overall symptoms were significantly reduced following successful DCR surgery in FNLDO patients ( $P < 0.05$ ) but remained unchanged in PANDO patients ( $P = 0.05$ ). However, embarrassment was the only individual symptom to reduce significantly (in frequency) following surgery both in FNLDO ( $P < 0.005$ ) and PANDO ( $P < 0.001$ ). Also, there was a small but not statistically significant reduction in the frequency of the visual symptoms in both FNLDO and PANDO.

Similarly, our study has shown PANDO affects patients in relation to visual tasks, routine work, occupational work, mood and embarrassment.

In our study, 31 (62%) cases had difficulty in vision. Raised tear meniscus of nasolacrimal duct obstruction particularly in down-gaze may be the cause of visual distortion.

However, in our study marked improvement in all subjective symptoms, *i.e.*, difficulty in vision, routine work, occupational work, mood and embarrassment, was seen and was found to be statistically significant ( $P < 0.05$ ). Although 48 (96%) patients had anatomical success in our study but symptomatic success in relation to routine work, occupational work and embarrassment was seen in 49 (98%) cases (Table 3). This was attributed to the fact that out of the two patients who did not have a successful outcome after DCR surgery, one patient had much decreased epiphora with no complaints of discharge as compared to the preoperative status leading to decrease in these symptoms. So it was seen that the symptoms of the patients decreased significantly postoperatively, indicating that successful dacryocystorhinostomy changed quality of life markedly in our study.

Good anatomical success of DCR in our study depends on meticulous surgical steps, taut anterior flaps of lacrimal sac mucosa and nasal mucosa after suturing so that they do not sag down postoperatively and cover the osteotomy site, proper location of the osteotomy site, as well as large osteotomy which is the most important step in preventing failure of DCR, as larger osteotomies created during external DCR lead to larger postoperative ostia.<sup>21</sup>

We concluded that external DCR is a highly effective and safe procedure. In PANDO patients, symptoms may bother the patient significantly and successful DCR surgery has a positive effect on the patient's physical and psychological well-being.

## References

1. Maini S, Raghava N, Youngs R, *et al.* Endoscopic endonasal laser versus endonasal surgical dacryocystorhinostomy for epiphora due to nasolacrimal duct obstruction: prospective, randomised, controlled trial. *J Laryngol Otol* 2007;121(12):1170-1176.
2. Walker RA, Al-Ghoul A, Conlon MR. Comparison of nonlaser nonendoscopic endonasal dacryocystorhinostomy with external dacryocystorhinostomy. *Can J Ophthalmol* 2011;46(2):191-195.
3. Sahlin S, Rose GE. Lacrimal drainage capacity and symptomatic improvement after dacryocystorhinostomy in adults presenting with patent lacrimal drainage systems. *Orbit* 2001;20:173-179.
4. Ibrahim HA, Batterbury M, Banhegyi G, McGalliard J. Endonasal laser dacryocystorhinostomy and external dacryocystorhinostomy outcome profile in a general ophthalmic service unit: a comparative retrospective study. *Ophthal Surg Lasers* 2001;32: 220-227.
5. Rosen N, Ashkenazi I, Rosner M. Patient dissatisfaction after functionally successful conjunctivodacryocystorhinostomy with Jones tube. *Am J Ophthalmol* 1994;117:636-642.
6. Cheung LM, Francis IC, Stapleton F, Wilcsek G. Symptom assessment in patients with functional and primary acquired nasolacrimal duct obstruction before and after successful dacryocystorhinostomy surgery: a prospective study. *Br J Ophthalmol* 2007;91(12):1671-1674.
7. Maini S, Raghava N, Youngs R, *et al.* Endoscopic endonasal laser versus endonasal surgical dacryocystorhinostomy for epiphora due to nasolacrimal duct obstruction: prospective, randomised, controlled trial. *J Laryngol Otol* 2007;121(12):1170-1176.
8. Walker RA, Al-Ghoul A, Conlon MR. Comparison of nonlaser nonendoscopic endonasal dacryocystorhinostomy with external dacryocystorhinostomy. *Can J Ophthalmol* 2011;46(2):191-195.
9. Jha KN, Ramalingam WVBS. External Versus Endoscopic Dacryocystorhinostomy: A Retrospective Study. *MJAFI* 2009;65(1):23-25.
10. Romanes GJ. Dacryocystorhinostomy. Clinical report of fifty cases. *Br J Ophthalmol* 1955;39:237-240.

11. McPherson SD, Egleston D. Dacryocystorhinostomy: a review of 106 patients. *Am J Ophthalmol* 1959;47:328-331.
12. Pico G. A modified technique of external dacryocystorhinostomy. *Am J Ophthalmol* 1971;72:679-689.
13. Groessl SA, Sires BS, Lemke BN. An anatomical basis for primary acquired nasolacrimal duct obstruction. *Arch Ophthalmol* 1997;115(1):71-74. Erratum in *Arch Ophthalmol* 1997;115(5):655.
14. Olver JM. Tips on how to avoid the DCR scar. *Orbit* 2005;24:63-66.
15. Rose GE. The lacrimal paradox: towards a greater understanding of success in lacrimal surgery. *Ophthal Plast Reconstr Surg* 2004;20:262-265.
16. Mansour K, Sere M, Oey AG, *et al.* Long-term patient satisfaction of external dacryocystorhinostomy. *Ophthalmologica* 2005;219:97-100.
17. Lester SE, Robson AK, Bearn M. Endoscopic 'cold steel' versus laser dacryocystorhinostomy: completing the audit cycle. *J Laryngol Otol* 2008;122:924-927.
18. Mathew MR, McGuinness R, Webb LA, *et al.* Patient satisfaction in our initial experience with endonasal endoscopic non-laser dacryocystorhinostomy. *Orbit* 2004;23:77-2385.
19. Tripathi A, Lesse THJ, O'Donnel NP, *et al.* Local anaesthetic endonasal endoscopic laser dacryocystorhinostomy: analysis of patients' acceptability and various factors affecting the success of this procedure. *Eye* 2002;16:146-149.
20. Moore WMH, Bentley CR, Olver JM. Functional and anatomic results after two types of endoscopic endonasal dacryocystorhinostomy: Surgical and holmium laser. *Ophthalmology* 2002;109:1575-1582.
21. Simon GJB, Brown C, McNab AA. Larger Osteotomies Result in Larger Ostia in External Dacryocystorhinostomies. *Arch Facia Plast Surg* 2012;14(2):127-131.

# Retinal nerve fiber layer thickness in chronic obstructive pulmonary disease: An optical coherence tomography study

Yeap Thye Ghee<sup>1</sup>, Mushawiahti Mustapha<sup>1</sup>, Roslan Harun<sup>2</sup>, Syed Zulkifli Syed Zakaria<sup>3</sup>, Jemaima Che Hamzah<sup>2</sup>, Hairul Nizam Harun<sup>2</sup>, Faridah Hanom Annuar<sup>2</sup>

<sup>1</sup>Department of Ophthalmology, Universiti Kebangsaan Malaysia Medical Centre, Kuala Lumpur, Malaysia; <sup>2</sup>Department of Medicine, Universiti Kebangsaan Malaysia Medical Centre, Kuala Lumpur, Malaysia; <sup>3</sup>Department of Paediatric, Universiti Kebangsaan Malaysia Medical Centre, Kuala Lumpur, Malaysia

## Abstract

**Background:** To evaluate changes in the retinal nerve fiber layer (RNFL) thickness in patients with chronic obstructive pulmonary disease (COPD) using optical coherence tomography (OCT).

**Methods:** In this case-controlled study, COPD subjects with various disease durations and severity were recruited. The standard global initiative for chronic obstructive lung disease (GOLD) criteria was used to determine the severity of COPD in the subjects. Healthy individuals were recruited as the control group. Peripapillary RNFL thickness was measured using spectral domain OCT.

**Results:** Seventy-one eyes of 71 COPD patients and 71 eyes of healthy controls were examined. The RNFL in all quadrants and the average RNFL were significantly thinner in patients with COPD compared to the control group ( $p < 0.05$ ). There were significant correlations between severity of COPD and RNFL thickness ( $p < 0.05$ ) for the average RNFL ( $r = 0.831$ ) and RNFL in all quadrants (superior RNFL  $r = 0.736$ , inferior RNFL  $r = 0.681$ , nasal RNFL  $r = 0.600$ , and temporal RNFL  $r = 0.353$ ). Similar significant correlations were found between RNFL thickness and duration of COPD ( $p < 0.005$ ) for the average RNFL ( $r = -0.674$ ) and RNFL in all quadrants (superior  $r = -0.615$ , inferior  $r = -0.472$ , nasal  $r = -0.484$ , and temporal  $r = -0.323$ ). The risk of having a thin RNFL (odds ratio) was 13-fold higher in patients with COPD.

**Conclusions:** These results suggest that COPD causes thinning of the RNFL, and severe retinal nerve fiber injury occurs more frequently in advanced COPD.

**Keywords:** glaucoma; chronic obstructive pulmonary disease; optical coherence tomography; retinal ganglion cells; optic neuropathy

## Introduction

Chronic obstructive pulmonary disease (COPD) is a global health concern with a significant economic and social burden.<sup>1</sup> The prevalence of moderate to severe COPD in Malaysia in 2003 was estimated by the regional COPD working group to be

**Correspondence:** Mushawiahti Mustapha, Department of Ophthalmology, Universiti Kebangsaan Malaysia Medical Centre, Jalan Yaacob Latif, 56000 Cheras, Kuala Lumpur, Malaysia.

E-mail: [drmusha@yahoo.com](mailto:drmusha@yahoo.com) or [drmusha@gmail.com](mailto:drmusha@gmail.com)

4.7%.<sup>2</sup> COPD is characterized by progressive and persistent airflow limitation that is not fully reversible.<sup>3</sup> It is associated with a chronic inflammatory response in the airways and lung parenchyma to noxious particles or gases particularly cigarette smoking. Although COPD primarily affects the lung, it is also associated with other significant systemic consequences such as hypertension, diabetes, coronary artery disease, congestive heart failure and stroke.<sup>3</sup>

The systemic changes in COPD are attributed to oxidative stress resulting in altered circulating levels of inflammatory mediators and acute phase proteins such as endothelin-1 (ET-1).<sup>4</sup> ET-1 is produced by the oxidative stress and increased levels have been reported in the plasma and urine of COPD patients.<sup>5</sup> ET-1 is a potent vasoconstrictor causing systemic vascular effects.<sup>1</sup> Ozer *et al.*<sup>6</sup> reported high resistance indices in most orbital arteries in COPD patients, including the ophthalmic and posterior ciliary arteries, probably due to the increased circulating plasma ET-1 enzymes. Such disturbances in the retrobulbar hemodynamic circulation increase the risk of optic nerve head hypoperfusion and eventually lead to retinal ganglion cell loss.<sup>7</sup>

Optic nerve abnormality in COPD has been indirectly evaluated by many authors.<sup>8</sup> Ozge *et al.*<sup>8</sup> found significant abnormalities in the optic nerves in 82.1% of COPD patients compared to healthy controls using visual evoked potential (VEP). They observed prolonged latency and reduced amplitude of P<sub>100</sub>, which represents axonal and demyelinating dysfunction of the peripheral field of the optic nerve.<sup>8</sup> Similarly, Gupta *et al.*<sup>9</sup> reported prolonged latency and decreased amplitude of P<sub>100</sub> in both eyes in patients with stable COPD with no clinical evidence of visual impairment or peripheral neuropathy.

To the best of our knowledge, direct and objective evaluation of the retinal nerve fiber layer (RNFL) in COPD patients has not been reported. We aimed to objectively demonstrate the possible damaging effect of COPD on the RNFL using optical coherence tomography (OCT), the human bio-microscope. We also investigated a possible association between the severity of airflow limitation and the degree of injury to the RNFL, which has not yet been reported.

## Methods

This case-controlled study was conducted in Universiti Kebangsaan Malaysia Medical Centre (UKMMC), Kuala Lumpur. Patients with COPD were recruited from the respiratory clinic who attended their usual follow-up. The control group consisted of healthy volunteers from the hospital staff and relatives accompanying the COPD patients. The study was conducted from March 2013 until March 2014.

Inclusion criteria for the COPD study group were: (i) age of 18 years and older; (ii) diagnosed with COPD by respiratory physician with post-bronchodilator forced expiratory volume in one second to forced vital capacity (FEV1/FVC) ratio of less than 0.70; (iii) intraocular pressure (IOP)  $\leq$  21 mmHg; (iv) open angles on gonioscopic examination; and (v) good OCT signal strength. The healthy individuals in the control group had no significant medical history, an IOP  $\leq$  21 mmHg and normal angles on gonioscopy. Exclusion criteria for both groups included: (i) glaucoma

diagnosis; (ii) a previous history of ocular trauma; (iii) myopia > 6.00 diopter; (iv) previous intracranial injury; and (v) presence of obstructive sleep apnea, diabetes or hypertension.

Written informed consents were obtained from all subjects. The severity of COPD was based on post-bronchodilator FEV1 % predicted values and classified according to the Global Initiative for Chronic Obstructive Lung Disease (GOLD) staging. In patients with FEV1/FVC ratio < 70%, GOLD 1 (mild COPD) the FEV1 is equal or more than 80% normal, GOLD 2 (moderate COPD) FEV1 50-79% normal, GOLD 3 (severe COPD) FEV1 30-49% normal and GOLD 4 (very severe COPD) FEV1 less than 30% normal.<sup>10</sup> A higher GOLD classification suggests an increased risk of exacerbation, hospitalization and death as airflow becomes more limited. As COPD is a systemic disease, both eyes were expected to be affected equally, and therefore, only the right eye was selected for evaluation and analysis. In cases where the right eye was not available, the left eye was used. The participants' demographic data, past medical and ocular history were recorded. Visual acuity of each eye was measured using Snellen Chart and complete ocular examination was performed. Dilated fundus examination was performed using condensing lens. Peripapillary RNFL (3 mm around the disc) was measured using spectral domain OCT (Heidelberg Engineering, Heidelberg, Germany).

Statistical analysis was performed using IBM SPSS Statistics for Windows, version 22.0. (IBM Corp, Armonk, NY). Comparisons between the RNFL measurements for COPD and healthy individuals were analyzed using paired t-tests. The associations between the RNFL thickness and severity as well as duration of COPD were analyzed using the Spearman's test.

## Results

### *Demographic and clinical characteristics of the study group*

A total of 142 subjects were recruited (71 patients with COPD and 71 subjects for the control group). Seventy-six (53.5%) subjects were Malay, 59 (41.5%) were Chinese and seven (5%) were Indian (Table 1). A total of 108 (76.1%) subjects were male, and 34 (23.9%) were female. There were no significant differences in the age, gender, ethnicity and baseline intraocular pressure between the control and COPD group (Table 1). The mean duration of disease was  $8.01 \pm 4.46$  years, and ranged from one to 20 years.

Classification was based on the severity of COPD and used the GOLD staging. Sixteen (22.4%) patients were classified as GOLD 1, 27 (38.0%) patients as GOLD 2, 21 (29.6%) patients as GOLD 3 and only seven (9.9%) patients were classified as the GOLD 4 (Table 1).

Table 1. Demographic and clinical descriptive statistics

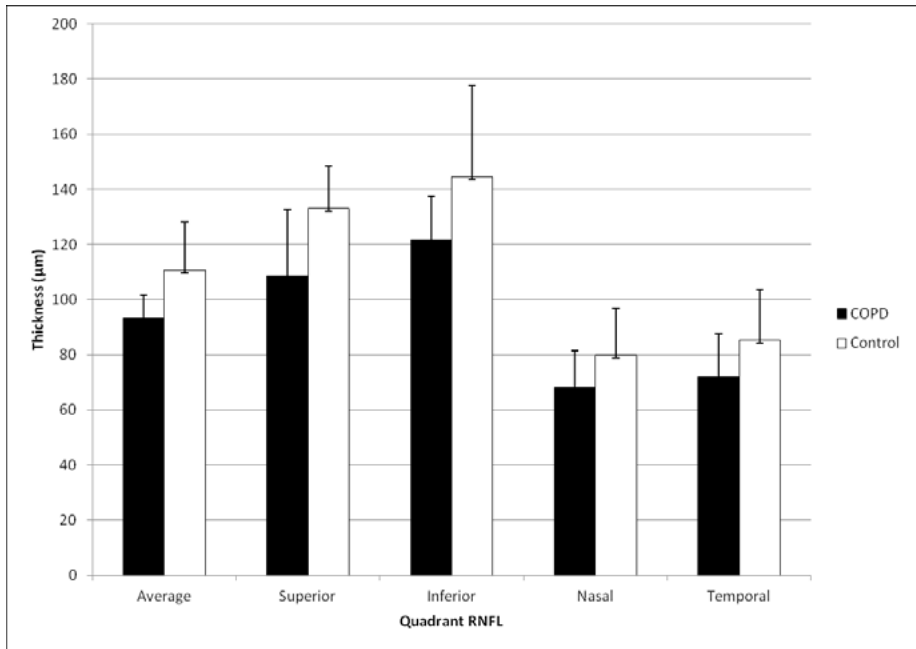
Characteristics	COPD n=71	Control n=71	p Value
<b>Age (years)</b>			
Mean ± SD	68.27 ±6.62	69.73 ±5.14	0.143*
<b>Gender</b>			
Male, n(%)	55(77.5)	53 (74.6)	0.844 <sup>‡</sup>
Female , n (%)	16 (22.5)	18 (25.4)	
<b>Ethnicity</b>			
Malay	38 (53.5)	38 (53.5)	0.923 <sup>‡</sup>
Chinese	30 (42.3)	29 (40.8)	
Indian	3(4.2)	4 (5.6)	
<b>IOP, mmHG</b>			
Mean ±SD	15.58 ±1.79	15.11 ± 1.78	0.064 <sup>‡</sup>
Duration of COPD (years),	8.01 ± 4.46		
mean ±SD (range)	(1-20)		
<b>GOLD staging of COPD, n(%)</b>			
GOLD 1	16 (22.5)		
GOLD 2	27(38.0)		
GOLD 3	21 (29.6)		
GOLD 4	7 (9.9)		

\*t-test, <sup>‡</sup>Chi-square, <sup>‡</sup>Mann-Whitney U-test

*Peripapillary RNFL was thinner in COPD patients compared to controls*

In general, the RNFL was significantly thinner in patients with COPD compared to the controls (p < 0.05; Fig. 1). The RNFL was significantly thicker in the control group compared to the COPD group in the average RNFL and RNFL in all quadrants: average RNFL (110.73 ± 8.47 mm vs 93.27 ± 17.41 mm; p < 0.05); superior RNFL (108.56 ± 24.17 mm vs 133.17 ± 15.27 mm; p < 0.05); inferior RNFL (144.66 ± 15.81 mm vs. 121.76 ± 33.05 mm; p < 0.05); nasal RNFL (80.03 ± 13.12 mm vs 68.21 ± 16.80 mm; p < 0.05); and temporal RNFL (85.25 ± 15.95 mm vs 71.82 ± 18.47mm; p < 0.05).





**Fig. 1.** Peripapillary retinal nerve fiber layer (RNFL) thickness between COPD patients and healthy controls. The average and all quadrant RNFLs are significantly thinner in COPD patients compared to controls.

### *RNFL thickness and severity of COPD*

The severity of COPD was based on the GOLD staging as determined by the post bronchodilator FEV1. RNFL was significantly thinner in the more severe forms of COPD ( $p < 0.05$ ; Fig. 1). The average RNFL thickness for the control group was  $110.73 \pm 8.47$  mm. The average RNFL thickness was  $105.75 \pm 7.74$  mm for GOLD 1 ( $p = 0.01$ ),  $101.52 \pm 8.73$  mm for GOLD 2,  $83.86 \pm 13.91$  mm for GOLD 3, and  $61.14 \pm 13.28$  mm for GOLD 4 COPD patients.

Looking at the individual quadrants, the thickness of superior quadrant RNFL in the control group was  $133.17 \pm 15.27$  mm. Compared to controls, the superior quadrant RNFL thickness in patients with GOLD 1 was  $124.94 \pm 13.96$  mm ( $p = 0.02$ ), GOLD 2,  $118.30 \pm 13.90$  mm ( $p < 0.05$ ), GOLD 3,  $95.29 \pm 23.98$  mm ( $p < 0.05$ ) and GOLD 4,  $73.43 \pm 19.40$  mm ( $p < 0.05$ ). The inferior quadrant RNFL thickness for the control group was  $144.66 \pm 15.82$  mm. Compared to controls, the inferior RNFL thickness for GOLD 1 was  $137.19 \pm 29.08$  mm ( $p = 0.463$ ); GOLD 2,  $132.78 \pm 29.28$  mm ( $p = 0.054$ ); GOLD 3,  $112.10 \pm 26.20$  mm ( $p < 0.05$ ) and GOLD 4,  $73.00 \pm 18.50$  mm ( $p < 0.05$ ). The nasal RNFL thickness for the control group was  $80.03 \pm 13.12$  mm. The same quadrant in GOLD 1 patients was  $77.56 \pm 8.94$  mm ( $p = 0.408$ ); GOLD 2,  $73.63 \pm 10.54$  mm ( $p = 0.041$ ); GOLD 3,  $63.86 \pm 14.16$  ( $p < 0.005$ ) and GOLD 4,  $39.00 \pm 22.72$  mm ( $p < 0.05$ ). Finally, in the temporal quadrant the RNFL thickness

in the control group was  $85.25 \pm 15.95$  mm. The same quadrant in GOLD 1 patients was  $77.13 \pm 9.55$  mm ( $p = 0.043$ ); GOLD 2,  $78.22 \pm 10.30$  mm ( $p = 0.049$ ); GOLD 3,  $63.76 \pm 20.69$  mm ( $p < 0.05$ ) and GOLD 4,  $59.14 \pm 34.50$  mm ( $p = 0.033$ ).

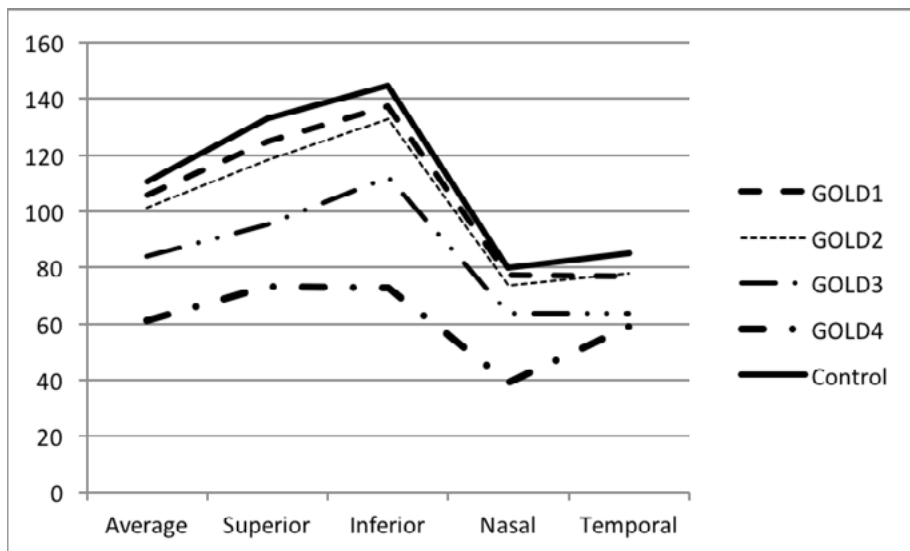


Fig. 2. Retinal nerve fiber layer (RNFL) thickness and COPD severity based on the GOLD staging system (GOLD1 is the least severe form and GOLD4 is the most severe form of COPD). RNFL becomes thinner with increasing severity of COPD.

### Correlation between RNFL thickness and duration of COPD

We also found significant correlations between duration of COPD and RNFL thickness in all quadrants, including average RNFL ( $p < 0.05$ ). Longer duration of COPD was associated with thinner RNFL. Average RNFL thickness demonstrated the strongest correlation ( $r = -0.674$ ), followed by superior RNFL ( $r = -0.615$ ), inferior RNFL ( $r = -0.472$ ) and nasal RNFL ( $r = -0.323$ ) thickness. Thickness of the temporal quadrant RNFL showed the lowest level of correlation ( $r = -0.323$ ) with duration of COPD.

The odds ratio for COPD patients was calculated based on average RNFL. Thin RNFL was defined as 25% of the average RNFL value (*i.e.*, 94 mm). The risk of having a thin retina was 13-fold higher in patients with COPD (OR 13.7, 95% CI: 4.5, 41.8), and this was statistically significant.

## Discussion

COPD is a systemic disorder that is frequently associated with significant extra-pulmonary manifestations, which impair the patient's quality of life.<sup>3</sup> Polyneuropathy has been widely studied as a common systemic disorder in COPD.<sup>8,9</sup> However, this is the first study to evaluate changes in the retinal nerve fiber layer (RNFL) in

COPD patients.

The results of our study demonstrated significant thinning of RNFL in COPD patients compared to healthy individuals. Reduction of RNFL thickness was generally present in all peripapillary quadrants and the average RNFL thickness was also reduced. This strengthens the results reported in previous studies.<sup>8</sup> Thinning of RNFL indicates diffuse axonal and retinal ganglion cell loss, most likely due to systemic hypoxemia. Peripheral airway obstruction, parenchymal destruction and pulmonary abnormalities in COPD reduce the lung's capacity for gas exchange and result in chronic systemic hypoxemia and hypercapnia. Retinal ganglion cells are highly sensitive to hypoxemia; even a mild decrease in arterial blood oxygen causes retinal ganglion cells to be impaired.<sup>11,12</sup> Similarly, systemic chronic hypoxemia has previously been shown to cause direct and indirect anoxic damage to the optic nervehead.<sup>11</sup>

While previous studies have shown that hypoxemia in obstructive apnea was associated with normotensive glaucoma (NTG),<sup>11</sup> the RNFL was found to be diminished in our COPD patients without a diagnosis of glaucoma. There are two current theories to explain the mechanisms leading to open angle glaucoma: a mechanical theory relating to intraocular pressure, and a vascular theory relating to a reduction in ocular blood flow.<sup>13</sup> As ET-1 is a potent vasoconstrictor, the high systemic levels of ET-1 observed in COPD patients may simultaneously reduce ocular blood flow and increase ocular perfusion pressure, leading to progressive damage of the optic nerve.<sup>5,6,14</sup> Therefore, it is worth considering COPD as an important risk factor for glaucoma and subsequent optic nerve damage.

In this particular study, an experienced respiratory physician performed the clinical COPD diagnosis, and the severity of disease was classified based on the post bronchodilator FEV1 or the standard GOLD spirometric grading systems (GOLD 1-4). GOLD 1 is the least severe form of the disease, while GOLD 4 denotes the most severe form of airflow limitation. We found a strong association between GOLD severity stage and thinning of peripapillary RNFL. Increased resistance in the peripheral airway as the disease advances further compromises the ocular blood flow, which in turn damages the RNFL. While increased duration of the disease also correlated with reduced thickness of the RNFL, the strongest predictor of RNFL thickness was the severity of COPD based on post bronchodilator FEV1 readings.

During the early stages of COPD, a deficiency in relative oxygen levels may provoke a compensatory effect and blood flow velocity will increase to meet the metabolic demand.<sup>15</sup> This efficient auto-regulation mechanism may protect the retina from early damage. Therefore, the insignificant thinning of inferior and nasal RNFL during the early stages of COPD observed in our study may be due to this auto-regulation mechanism. However, with advancement of disease and time, retinal vascular auto-regulation might fail to compensate for the severe hypoxemic conditions, and eventually the optic nerve head will be damaged.

A limitation of this study was its cross-sectional design, which did not allow us to directly demonstrate causation. Therefore, a larger cohort study in the future would better demonstrate a causal relationship between COPD and thinning of the

RNFL. Secondly, visual field was not evaluated in our subjects. Clinical screening was used to exclude subjects with possible glaucoma. However, incorporating visual field assessment would have been useful, especially for those with severe COPD who are prone to having a thin RNFL. In the future, it would be interesting to look at pre-perimetric changes before the optic disc changes become evident. Such studies would also provide a more comprehensive assessment of optic nerve head damage in COPD patients.

In conclusion, COPD causes retinal nerve fiber injury and the retinal nerve fiber layer becomes thinner over time. The severity of COPD is a strong predictor for the degree of thinning of the RNFL. As smoking is a major cause of COPD, and we found that COPD increases the risk of optic nerve damage. Indirectly, the results of this study further support the disastrous effect of cigarette smoking to the eye. Our findings are also relevant for ophthalmologists dealing with optic neuropathy. In these cases, we suggest that COPD should be considered as an important risk factor for abnormal optic disc.

## References

1. Halldin CN, Doney BC, Hnizdo E. Changes in prevalence of chronic obstructive pulmonary disease and asthma in the US population and associated risk factors. *Chron Respir Dis* 2015;12(1):47-60.
2. Regional COPD Working Group. COPD prevalence in 12 Asia-Pacific countries and regions: projections based on the COPD prevalence estimation model. *Respirology* 2003;8(2):192-198.
3. Agusti AG, Noguera A, Sauleda J, *et al.* Systemic effects of chronic obstructive pulmonary disease. *Eur Respir J* 2003;21(2):347-360.
4. Wouters EF, Creutzberg EC, Schols AM. Systemic effects in COPD. *Chest* 2002;121(5 Suppl):127S-130S.
5. Roland M, Bhowmik A, Sapsford RJ, *et al.* Sputum and plasma endothelin-1 levels in exacerbations of chronic obstructive pulmonary disease. *Thorax* 2006;56(1):30-35.
6. Ozer T, Altin R, Ugurbas SH, *et al.* Color Doppler evaluation of the ocular arterial flow changes in chronic obstructive pulmonary disease. *Eur J Radiol* 2006;57(1):63-68.
7. Yanagi M, Kawasaki R, Wang JJ, *et al.* Vascular risk factors in glaucoma: a review. *Clin Experiment Ophthalmol* 2011;39(3):252-258.
8. Ozge C, Ozge A, Yilmaz A, Yalcinkaya DE, Calikoglu M. Cranial optic nerve involvement in patients with severe COPD. *Respirology* 2005;10(5):666-672.
9. Gupta PP, Sood S, Atreja A, Agarwal D. Assessment of visual evoked potentials in stable COPD patients with no visual impairment. *Ann Thorac Med* 2010;5(4):222-227.
10. Global Initiative for Chronic Obstructive Lung Disease (revised 2011). [www.goldcopd.org/uploads/users/files/GOLD\\_Report\\_2011\\_Feb21.pdf](http://www.goldcopd.org/uploads/users/files/GOLD_Report_2011_Feb21.pdf)
11. Tsang CS, Chong SL, Ho CK, Li MF. Moderate to severe obstructive sleep apnea patients is associated with a higher incidence of visual field defect. *Eye (Lond)* 2006;20:38-42.
12. Kergoat H, Herard ME, Lemay M. RGC sensitivity to mild systemic hypoxia. *Invest Ophthalmol Vis Sci* 2006;47(12):5423-5427.
13. Flammer J. The vascular concept of glaucoma. *Surv Ophthalmol* 1994;38 suppl:S3-6.
14. Satilimis M, Orgul S, Doubler B, Flammer J. Rate of progression of glaucoma correlates with retrobulbar circulation and intraocular pressure. *Am J Ophthalmol* 2003;135(5):664-669.
15. Delaey C, Van De Voorde J. Regulatory mechanisms in the retinal and choroidal circulation. *Ophthalmic Res* 2000;32(6):249-256.

# The Malaysian Cataract Surgery Registry: Surgically induced astigmatism in phacoemulsification cataract surgery

Ming-Yueh Lee, Tasha Hilda, Mariam Ismail<sup>1</sup>, Pik-Pin Goh  
Clinical Research Centre, Ministry of Health, Kuala Lumpur, Malaysia

## Abstract

**Purpose:** Surgically induced astigmatism is an often-neglected issue in phacoemulsification cataract surgery. It is a significant problem resulting in poor refractive outcome and patients' dissatisfaction. The objective of this study was to describe the preoperative astigmatism and the postoperative surgically induced astigmatism and its contributing factors.

**Design:** Retrospective study on the Malaysian Cataract Surgery Registry between 2008 and 2011.

**Method:** Data on phacoemulsification cataract surgery from 37 ophthalmology units were studied and filtered. Patients > 50 year-old with complete refractive assessment results and with no ocular comorbidity were included. Contributing factors, namely patients' age, race, gender, laterality of the operated eyes, surgeon's status and intraoperative complications, were analyzed.

**Results:** The mean age of the 5350 patients was 68.0 years; the majority of patients were Chinese. The mean postoperative cylinder was 1.19 Diopter (D) (SD = 0.91) compared to the preoperative mean cylinder of 0.88 D (SD = 0.83D). Multivariate regression analysis on postoperative data revealed statistically significant high cylinder power (> 1.0 D) for older patients, Chinese race, operated left eyes ( $p < 0.001$ ), surgery performed by trainee ophthalmologists ( $p < 0.001$ ), and eyes with intraoperative complications ( $p < 0.001$ ). The overall difference of cylinder power before and after phacoemulsification cataract surgery was high; signifying high degree of surgically induced astigmatism.

**Conclusion:** Surgically induced astigmatism could result in significant postoperative astigmatism with poor refractive outcome. The contributing factors are old age, Chinese race, operated left eyes, surgery by trainee ophthalmologists and eyes with intraoperative complications.

## Introduction

The trend in cataract surgery today has moved from mere lens extraction towards achieving the best refractive outcome. Although the outcome of cataract surgery has improved significantly over the years with marked advances in surgical technique, surgical instruments and intraocular lens technology, there are still issues that need to be addressed. Pre-existing astigmatism and SIA are two often neglected but important factors that compromise the visual outcome after phacoemulsification cataract surgery.

With cataract surgery and intraocular lens implantation, the most pronounced

**Correspondence:** Pik-Pin Goh, Clinical Research Centre, Ministry of Health, Kuala Lumpur, Malaysia.  
E-mail: [gohpp@crc.gov.my](mailto:gohpp@crc.gov.my)

effect is a change in spherocylindrical power. Spherical power is a single variable, which could be calculated and achieved quite accurately; whereas astigmatism power is a complex entity characterized by magnitude and meridian that could change significantly after cataract surgery. Surgical incision for cataract surgery induces a flattening effect on the cornea surface and this is termed surgically induced astigmatism (SIA).<sup>1</sup> SIA would alter and worsen the pre-existing astigmatism of a patient if it is not taken into consideration in the planning of cataract surgery.

Extracapsular cataract extraction (ECCE) and intracapsular cataract extraction (ICCE) commonly produce high SIA due to the size of the cornea or limbal wound.<sup>2</sup> Phacoemulsification cataract surgery had since gained popularity over the old technique mainly because of the most significant advantage it offers in the form of a small incision wound with less SIA. Nevertheless, the hidden problem that compromises the refractive outcome of phacoemulsification cataract surgery in many cataract centers today is still the failure to modulate the preexisting astigmatism and failure to recognize the issue of SIA.

The objective of this study was to describe pre-existing/preoperative astigmatism among patients who underwent phacoemulsification cataract surgery registered in the Cataract Surgery Registry (CSR) under Ministry of Health (MOH) from year 2008 to 2011, and to assess the magnitude of SIA postoperatively. Possible factors contributing to SIA were analyzed.

## Material and method

This is a retrospective study on cataract surgery data derived from the Cataract Surgery Registry of the Ministry of Health Malaysia from year 2008 to 2011. It is a web-based registry hosted in ([www.acrm.org.my/ned](http://www.acrm.org.my/ned)).<sup>3</sup> All cataract surgery data entry was done by designated staff in 37 hospitals under the Ministry of Health Malaysia. It was performed under the supervision of on-site coordinators and optometrists to ensure a complete, updated and standardized method of data collection and entry. Data were entered consecutively for each cataract surgery performed into preoperative, operative and postoperative outcome forms. Data on postoperative complications and visual acuity were collected up to 12 weeks during follow-up visits.

The available data was then filtered to include only patients who had undergone phacoemulsification cataract surgery with successful intraocular lens implantation. Patients aged 50 year-old and above with no ocular co-morbidity at the time of surgery and had complete data entry on preoperative and postoperative refractive assessment results were included. This age group was chosen based on a population study where patients below that age limit shared a similar trend in their refractive pattern.<sup>2</sup>

The main outcome measures in this study were preoperative astigmatism and postoperative astigmatism in cylinder power. Preoperative and postoperative refractive assessment was performed by qualified optometrists in the respective participating ophthalmology units. Postoperative refractive assessment was done

within 12 weeks postoperatively. SIA was calculated as cylinder power difference between preoperative and postoperative as recorded in the postoperative refractive assessment forms. Other possible contributing factors namely age group, gender, race, laterality of the operated eyes, surgeon status and intraoperative complications were analyzed.

The study protocol was reviewed and approved by the Medical Research and Ethics Committees of the Ministry of Health Malaysia.

## Statistical analysis

Statistical analysis was conducted using IBM SPSS for Windows version 20 (IBM SPSS Statistics, Armonk, NY). The analysis was performed on the available data in the Cataract Surgery Registry from year 2008 to 2011.

All numerical data was expressed as mean and standard deviation, or median and inter-quartile range (IQR). Categorical data was described in the form of frequency and percentage. The dependent variable is cylinder power measurement and the independent variables (factors) included patient's age group, gender, race, and laterality of the operated eyes, surgeon status and intraoperative complications. Kruskal-Wallis and Mann-Whitney U test were performed to determine the difference of the cylinder measurement between each group in the independent variables at both preoperative and postoperative state of cataract surgery. Multiple logistic regression were then carried out at preoperative and postoperative to identify factors associated with cylinder category and to estimate odds ratios (OR) and its 95% confidence intervals (CI) for the association between the dependent variable (cylinder power measurement of more than 1.0 D) and the independent variables. The regression was also carried out to determine the association between visual acuity and cylinder power after cataract surgery. McNemar's Chi-squared test was used to compare proportionality in cylinder category between the preoperative and postoperative state. All reported values are two-sided and p-value of less than 0.05 was considered as statistically significant.

## Results

There were 5350 patients included in this study. Patients' demographic features are summarized in Table 1. Patients' refractive assessment data before and after phacoemulsification cataract surgery are shown in Table 2.

Table 1. Characteristics of cataract surgery patient year 2008 – 2011 (N = 5350).

Characteristics	
<b>Age</b>	
Mean (SD)	68.0 (7.7)
Median (IQR)	69 (62-74)
Min, max	50, 99
<b>Gender; n (%)</b>	
Male	2521 (47.1)
Female	2829 (52.9)
<b>Race; n (%)</b>	
Malay	1932 (36.1)
Chinese	2602 (48.6)
Indian	643 (12.0)
Others*	89 (1.7)
<b>Surgeon status; n (%)</b>	
Specialist	4398 (82.2)
Trainee**	566 (10.6)
<b>Intra-operative complications; n (%)</b>	
Yes	157 (2.9)
No	5193 (97.1)
<b>Operative eye; n (%)</b>	
Right eye	2671 (49.9)
Left eye	2679 (50.1)

\*Others including Melanau, Kadazan/Murut/Bajau, Iban and other Malaysian.

\*\*Trainee including gazetted specialist and medical officer.

IQR = interquartile range

The frequency is based on available information.



Table 2. Refractive assessment pre- and postoperatively (N = 5350).

	Preoperatively	Postoperatively
<b>Visual acuity, n (%)</b>		
6/5 – 6/12	1097 (20.5)	4632 (86.6)
6/18 – 3/60	2530 (47.3)	291 (5.4)
2/60 – NPL	414 (7.7)	13 (0.2)
<b>Cylinder</b>		
Mean (SD)	0.88 (0.83)	1.19 (0.91)
Median (IQR)	0.75 (0.00 – 1.25)	1.00 (0.50 – 1.50)
Min, max	0.00, 6.00	0.00, 12.00
<b>Spherical Equivalent (SE)</b>		
Mean (SD)	-1.16 (2.47)	-0.67 (0.87)
Median (IQR)	-0.62 (-2.25 – +0.00)	-0.62 (-1.12 – -0.25)
Min, max	-22.75, +15.62	-10.00, +13.00

The frequency is based on available information.

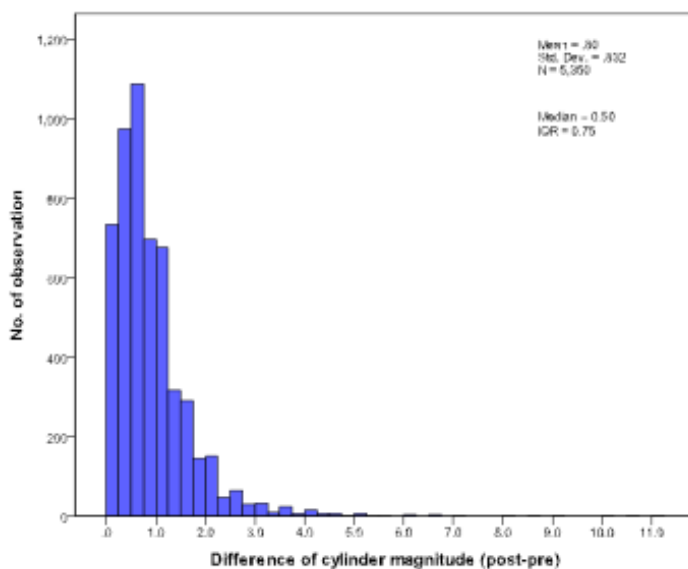


Fig. 1. Difference in cylinder power – pre- and postoperative phacoemulsification cataract surgery.

Figure 1 shows the overall data on difference of cylinder power between preoperative and postoperative was skewed to the right. This signifies a very high degree of SIA in a significant number of cases in the study population.

Preoperatively, there were no significant differences in cylinder power for patients of different gender, right or left eyes, assigned surgeons and intraoperative complications grouping. However, all patients aged 70 years and above had median of 1 D cylinder preoperatively. Also, the Chinese patients were found to have a significantly higher preoperative cylinder power compared to other races. Postoperatively, a significantly high cylinder power was found in older patients, Chinese, surgeries performed by trainee ophthalmologists, surgery done in the left eyes and for those encountered with intraoperative complications (Table 3).

Multiple logistic regression analysis revealed significant high postoperative cylinder power in Chinese ( $p < 0.001$ ), in the left eyes ( $p < 0.001$ ), surgery performed by trainee ophthalmologists ( $p = 0.001$ ), and for those encountered intraoperative complications ( $p < 0.001$ ). Chinese patients had the highest astigmatism among all races both pre- and postoperatively. The cylinder power also increased with age same as their preoperative state. There was no significant difference in cylinder power by gender. The insignificant results for the age group of 90-99 both preoperative and postoperatively was probably due to small sample size (Table 4). McNemar test showed overall significant changes of cylinder power ( $p < 0.001$ ) following phacoemulsification cataract surgery.

Logistic regression analysis adjusted for intraoperative complications and surgeon status showed significant association between high cylinder power and poor visual acuity (Snellen 6/18-3/60) (Table 5).

Table 3. The difference of cylinder power pre- and postoperatively.

Variable	n	Preoperatively			Postoperatively		
		Median (IQR)	Test-statistic (df)	P-value	Median (IQR)	Test-statistic (df)	P-value
Age group (years)							
50 – 59	815	0.50 (0.00 – 1.01)	49.28 (4) <sup>a</sup>	< 0.001 <sup>a</sup>	0.75 (0.50 – 1.25)	260.16 (4) <sup>a</sup>	< 0.001 <sup>a</sup>
60 – 69	2075	0.75 (0.00 – 1.25)			1.00 (0.50 – 1.50)		
70 – 79	2167	1.00 (0.00 – 1.50)			1.25 (0.75 – 1.75)		
80 – 89	286	1.00 (0.25 – 1.50)			1.25 (0.75 – 2.00)		
90 – 99	7	1.00 (0.00 – 3.50)			1.75 (1.00 – 4.75)		
Gender							
Male	2521	1.00 (0.00 – 1.25)	-1.20 <sup>b</sup>	0.230 <sup>b</sup>	1.00 (0.50 – 1.50)	-1.09 <sup>b</sup>	0.276 <sup>b</sup>
Female	2829	0.75 (0.00 – 1.25)			1.00 (0.50 – 1.50)		
Race							
Malay	1932	0.75 (0.00 – 1.25)	43.30 (3) <sup>a</sup>	< 0.001 <sup>a</sup>	1.00 (0.50 – 1.50)	51.66 (3) <sup>a</sup>	< 0.001 <sup>a</sup>
Chinese	2602	1.00 (0.00 – 1.50)			1.00 (0.75 – 1.50)		
Indian	643	0.75 (0.00 – 1.25)			1.00 (0.50 – 1.50)		
Others	89	1.00 (0.50 – 1.50)			1.00 (0.50 – 1.50)		
Operative eye							
Right eye	2671	0.75 (0.00 – 1.25)	-1.98 <sup>b</sup>	0.047 <sup>b</sup>	1.00 (0.50 – 1.50)	-4.84 <sup>b</sup>	< 0.001 <sup>b</sup>
Left eye	2679	1.00 (0.00 – 1.25)			1.00 (0.75 – 1.50)		
Surgeon status							
Specialist	4398	0.75 (0.00 – 1.25)	-0.49 <sup>b</sup>	0.624 <sup>b</sup>	1.00 (0.50 – 1.50)	-3.31 <sup>b</sup>	0.001 <sup>b</sup>
Trainee	566	1.00 (0.00 – 1.25)			1.25 (0.75 – 1.50)		
Intraoperative complication							
Yes	157	0.75 (0.00 – 1.25)	-1.53 <sup>b</sup>	0.127 <sup>b</sup>	1.50 (0.75 – 2.50)	-6.40 <sup>b</sup>	< 0.001 <sup>b</sup>
No	5193	0.75 (0.00 – 1.25)			1.00 (0.50 – 1.50)		

<sup>a</sup> Kruskal-Wallis test <sup>b</sup> Mann-Whitney U test  
df = degree of freedom

Table 4. Distribution of cylinder power using logistic regression.

	Preoperatively						Postoperatively					
	Cylinder ≤ 1.0 (n = 3747)		Cylinder > 1.0 (n = 1603)		Multivariable analysis (n = 4882)		Cylinder ≤ 1.0 (n = 3077)		Cylinder > 1.0 (n = 2273)		Multivariable analysis (n = 4882)	
	n	%	n	%	Adj. OR (95% CI)	P-value <sup>a</sup>	n	%	n	%	Adj. OR (95% CI)	P-value <sup>a</sup>
Age group (years)						<0.001						< 0.001
50 – 59	611	16.3	204	12.7	1.00		587	19.1	228	10.0	1.00	
60 – 69	1503	40.1	572	35.7	1.10 (0.90, 1.34)	0.344	1302	42.3	773	34.0	1.57 (1.30, 1.89)	< 0.001
70 – 79	1443	38.5	724	45.2	1.45 (1.19, 1.76)	< 0.001	1059	34.4	1108	48.7	2.77 (2.29, 3.34)	< 0.001
80 – 89	185	4.9	101	6.3	1.61 (1.18, 2.18)	0.002	127	4.1	159	7.0	3.35 (2.49, 4.51)	< 0.001
90 – 99	5	0.1	2	0.1	1.18 (0.22, 6.19)	0.849	2	0.1	5	0.2	6.42 (1.20, 34.19)	0.029
Gender												
Male	1743	46.5	778	48.5	1.09 (0.96, 1.23)	0.172	1433	46.6	1088	47.9	1.06 (0.94, 1.19)	0.361
Female	2004	53.5	825	51.5	1.00		1644	53.4	1185	52.1	1.00	
Race						< 0.001						<0.001
Malay	1427	38.6	505	32.1	1.00		1176	38.9	756	33.7	1.00	
Chinese	1763	47.7	839	53.4	1.35 (1.18, 1.55)	< 0.001	1374	45.5	1228	54.7	1.33 (1.17, 1.52)	< 0.001
Indian	448	12.1	195	12.4	1.33 (1.08, 1.63)	0.007	422	14.0	221	9.8	0.89 (0.72, 1.08)	0.229
Others	56	1.5	33	2.1	1.99 (1.23, 3.22)	0.005	50	1.7	39	1.7	1.25 (0.77, 2.03)	0.366

Table 4 continued.

	Preoperatively						Postoperatively					
Operative eye												
Right eye	1870	49.9	801	50.0	1.00		1593	51.8	1078	47.4	1.00	
Left eye	1877	50.1	802	50.0	0.98 (0.87, 1.11)	0.797	1484	48.2	1195	52.6	1.23 (1.09, 1.38)	0.001
Surgeon status												
Specialist	3080	88.8	1318	88.2	1.03 (0.85, 1.25)	0.743	2570	90.2	1828	86.4	1.44 (1.20, 1.73)	< 0.001
Trainee	390	11.2	176	11.8	1.00		278	9.8	288	13.6	1.00	
Intraoperative complication												
Yes	111	3.0	46	2.9	0.92 (0.64, 1.34)	0.675	57	1.9	100	4.4	2.84 (1.98, 4.08)	< 0.001
No	3636	97.0	1557	97.1	1.00		3020	98.1	2173	95.6	1.00	

Adj. OR = Adjusted odds ratio.  
Number and percentage are based on available information.  
<sup>a</sup>Wald statistic.

Table 5. The association between visual acuity and cylinder power postoperatively.

	Cylinder ≤ 1.0 (n = 3077)		Cylinder > 1.0 (n = 2273)		Multivariable analysis (n = 4935)	
	n	%	n	%	Adj. OR (95% CI)	P-value <sup>a</sup>
Postoperative visual acuity						< 0.001
6/5 – 6/12	2706	95.4	1926	91.7	1.00	
6/18 – 3/60	123	4.3	168	8.0	1.81 (1.42, 2.31)	< 0.001
2/60 – NPL	7	0.2	6	0.3	1.16 (0.39, 3.50)	0.787

\*Logistic regression was adjusted for intraoperative complication and surgeon status.

Adj. OR = Adjusted odds ratio.

Number and percentage are based on available information.

<sup>a</sup>Wald statistic.

Discussion

Cataract surgery today aims not only to restore vision; but also to minimize patients’ pre-existing astigmatism and SIA for better refractive outcome and visual quality. Optimal visual acuity (6/12 and better) could only be achieved with accurate intraocular lens (IOL) power calculation and minimization of astigmatism.

Astigmatism is defined as unequal radius of curvature of the refractive surface of the eye with resultant failure to focus point source of light on the retina. The image is thus not sharp as it is being spread over a diffuse area.<sup>2</sup> Correction of pre-existing astigmatism and minimization of SIA is crucial in modern day cataract surgery, particularly with the popularization of toric IOL and multifocal IOL. The success in effectively reducing astigmatism with toric IOL is very much affected by SIA,<sup>4</sup> while implantation of multifocal IOL with significant SIA impairs both near and distance visual acuity. Significant SIA impairs quality of vision by causing blur vision, image distortion and difficulty in binocular vision. It also defeats the benefits of spectacle independence.

SIA contributing factors like patients’ preexisting astigmatism, cornea optical power, axial length, intraocular pressure, patients age and gender had been evaluated in some studies.<sup>5,6</sup> In this study, we studied other possible contributing factors namely patients’ age, gender and race, laterality of the operated eye, surgeon status and intraoperative complications.

Our study revealed significant high pre-existing astigmatism among the Chinese population. This finding is similar to a population-based study done on the clinical Chinese population in Hong Kong where 41.8% in the > 60 years age group had refractive astigmatism of more than 1 D cylinder.<sup>7</sup> According to a study done by Matsumoto and colleagues,<sup>8</sup> eyes with pre-existing astigmatism have higher chance of getting residual astigmatism after cataract surgery. Our finding is in total agreement with this study as the Chinese patients were also noted to have

high astigmatism preoperatively. We also found that all patients aged 60 years and above had significant high postoperative cylinder power of more than 1.0 D. The rising trend of astigmatism power with age also corresponded with their preoperative status.

Besides age and race, we concluded that the laterality of the operated eye had significant influence on the SIA. The operated left eyes had significantly higher SIA compared to the right eyes. This is probably due to the fact that majority of our surgeons are right-handed and they normally perform cataract surgery sitting in their comfortable superior position. Thus, the most commonly cited location of the main incision on the cornea in our settings is superotemporal for the right eye and superonasal for the left eye. When a surgeon sits superior to a patient; a high nasal bridge makes a peripheral cornea incision on the left eye difficult to achieve. A more central cornea incision closer to the pupillary axis is usually made and this induces more cornea astigmatism. Phacoemulsification cataract surgeries performed by qualified surgeons were noted to have lower SIA compared to those operated by the trainees. This could be explained by the overall better surgical technique, better wound construction and less incidence of intraoperative complications. Cornea wound extension is required in the event of intraoperative complications and this ultimately results in more SIA compared to the uneventful cases.

The finding of a significant increase in mean cylinder power after phacoemulsification cataract surgery in all age groups, genders, races, by all surgeons including qualified ophthalmologists and trainees, in both right and left eyes, and cases with or without intraoperative complications is pretty alarming. The insignificant differences among the variables noted in preoperative statistical analysis clearly pointed to a significant SIA in all phacoemulsification cataract surgeries performed within the study period.

The majority of the cataract surgeries were performed with small limbal or cornea incision wound less than three mm in size. Limbal relaxing incisions are rarely performed due to the lack of surgical skills and surgical tools in the government hospital settings here. The variability in the degree of SIA among the surgeons could be due to type of incision either scleral, limbal or cornea; location of cornea wound (distance from the optical zone), length of cornea tunnel and different technique in wound construction.<sup>9,10</sup>

This important finding should alert us clinician to be more cautious with the issue of astigmatism in cataract surgery. Attempts should be made to rectify the pre-existing astigmatism and effort to minimize it by various surgical techniques should be sought after. It is very important on the surgeon's part to identify his own degree of SIA and to attempt modulating the preexisting astigmatism during cataract surgery.

We also noted that the percentage of patients with against-the-rule astigmatism increased from 57.4% preoperatively to 71.3% postoperatively. It is worthwhile to investigate if this could be due to natural course of wound healing in phacoemulsification cataract surgery; or could it be due to a shift of astigmatism axis postoperatively.

The strength of this study is the large sample size and complete preoperative and postoperative data. However, keratometry-reading, which is the better means of measuring SIA, is not incorporated in this study. We did not have data on the actual location of main incisions either scleral, limbal or cornea including their axis of entry to the eye. We should also consider variability in the elastic property of the cornea, variability in response of cornea to incision and the individual variation in wound healing as factors reducing the predictability of surgical and refractive outcome.<sup>11</sup> A longer follow-up period is recommended as SIA is a dynamic feature which may show changes in axis and magnitude up to months and even years.<sup>9,10</sup>

In conclusion, SIA is an important issue compromising the refractive outcome and quality of vision following phacoemulsification cataract surgery. A large majority of patients in this study had been shifted from the insignificant astigmatism category (Cylinder power  $\leq 1$  D) into the spectacle-dependent category (Cylinder power  $> 1$  D) due to significant SIA. The shift is contributed by factors like patients' old age, operated left eyes, operations by trainee ophthalmologists and occurrence of intraoperative complications. The need for spectacle corrections for significant astigmatism inevitably results in patients' dissatisfaction and poses a hefty toll on the technical support and healthcare expenses. Minimization of SIA in phacoemulsification cataract surgery should not be overlooked in our continuous quest in targeting a good postoperative vision, good refractive outcome and spectacle independency.

## Acknowledgement

The authors wish to thank the Director General, Ministry of Health Malaysia for the permission to conduct the study and for providing the research grant. We would also like to thank the participating hospitals, the optometrists who conducted the preoperative and postoperative refractive assessment for this study, the site coordinators, and the paramedics for data entry.

**Ethics Approval:** Ethic approval was obtained from Medical Research Ethic Committee, Ministry of Health Malaysia

**Licence for Publication:** The Corresponding Author has the right to grant on behalf of all authors an exclusive licence (or non-exclusive for government employees) on a worldwide basis to the publisher, Kugler Publications, Asian Journal of Ophthalmology Ltd to permit this article (if accepted) to be published in Asian Journal of Ophthalmology and any other products and sub-licences such use and exploit all subsidiary rights, as set out in our licence.

**Competing Interest:** None declared

## References

1. Ernest P, Hill W, Potvin R. Minimizing Surgically Induced Astigmatism at the Time of Cataract Surgery Using a Square Posterior Limbal Incision. *J Ophthalmol* 2011. Doi:10.1155/2011/243170.
2. Adio AO, Aruotu N. Induced astigmatism after cataract surgery – a retrospective analysis of cases from the University of Port Harcourt Teaching Hospital, Nigeria. *S Afr Optom* 2011;70:75-80.



3. Goh PP, Elias H, Nor Fariza N, Mariam I. National Eye Database – A Web Based Surveillance System. *Med J Malaysia* 2008;63(Supp):20-23.
4. Hill W, Potvin R. Monte Carlo simulation of expected outcomes with the AcrySof toric intraocular lens. *BMC Ophthalmology* 2008;8:22.
5. Ninn-Pedersen K. Relationship between preoperative astigmatism and cornea optical power, axial length, intraocular pressure, gender and patient age. *J Cataract Refract Surg* 1996;12:472-478.
6. Storr-Paulsen A, Madsen H, Perriard A. Possible factors modifying the surgically induced astigmatism in cataract surgery. *Acta Ophthalmol Scand* 1999;77:548-551.
7. Leung TW, Lam AK, Deng L, Kee CS. Characteristic of Astigmatism as a function of age in Hong Kong clinical population. *Optom Vis Sci* 2012;89(7):984-992.
8. Matsumoto Y, Hara T, Chiba K, Chikuda M. Optimal incision sites to obtain an astigmatism free cornea after cataract surgery with a 3.2mm sutureless incision. *J Cataract Refract Surg* 2001;27(10):1615-1619.
9. Neuman AC, McCarty GR, Sander DR, Raanan MG. Small incision to control astigmatism during cataract surgery. *J Cataract Refract Surg* 1989;15:78-84.
10. Cho YK, Kim MS. Perioperative modulating factors on astigmatism in sutured cataract surgery. *Korean J Ophthalmol* 2009;23(4):240-248.
11. Tejedor J, Murube J. Choosing the location of corneal incision based on preexisting astigmatism in phacoemulsification. *Am J Ophthalmol* 2005;139(5):767-776.

# MARK YOUR CALENDAR

JUNE 28–JULY 1, 2017



Please save the date for the 7<sup>th</sup>  
**WORLD GLAUCOMA CONGRESS**  
JUNE 28–JULY 1, 2017  
**HELSINKI**

THE GLOBAL GLAUCOMA NETWORK  
[www.worldglaucoma.org](http://www.worldglaucoma.org)

# Ocular myiasis in a glioma

David Mathew<sup>1</sup>, Satheesh Solomon Selvin<sup>2</sup>, Shilpa Kuruvilla<sup>3</sup>, Thomas Kuriakose<sup>4</sup>

<sup>1</sup>Department of Ophthalmology, Bansara Eye Care Centre, Shillong, India;

<sup>2</sup>Department of Ophthalmology, Christian Medical College, Vellore, India;

<sup>3</sup>Department of Ophthalmology, Flinders Medical Centre, Australia; <sup>4</sup>Department of Ophthalmology, Christian Medical College, Vellore, India

## Abstract

*Ocular myiasis, though rare, is usually found in association with basal cell carcinoma. It is rarer still in tumors other than basal cell carcinoma. We report a case of ocular myiasis in a glioma which is hitherto unreported to the best of our knowledge. A 50-year old male presented with bleeding and maggots emanating from a tumorous outgrowth which had replaced his right eye. He complained of swelling and pain in his right eye for the last two years. Manual removal of maggots was carried out after which he underwent total excision of the mass and local debridement. Biopsy of the mass was consistent with astrocytoma. Myiasis, although rare, should be suspected in long-standing neglected lesions with suggestive history. Infection, ischemic necrosis and malignancy coupled with overcrowding, poor living conditions, presence of excessive arthropods in the locality and low levels of hygiene drastically increase the risk of myiasis.*

**Keywords:** myiasis, glioma, ophthalmomyiasis, tumor

## Introduction

Infestation of any part of the body by the larvae of flies (maggots) is termed myiasis. Ophthalmomyiasis is termed ophthalmomyiasis externa if only the eyelid or conjunctiva is involved, and ophthalmomyiasis interna if there is intraocular entry of the larvae.<sup>1</sup> Orbital myiasis is the most severe form, resulting in infestation of the orbital cavity. It has been reported in the past especially in association with basal cell carcinoma in developing countries.<sup>2,3</sup> Ocular myiasis in tumors other than basal cell carcinoma is rarer still. To the best of our knowledge, this is the first report of ocular myiasis in a glioma.

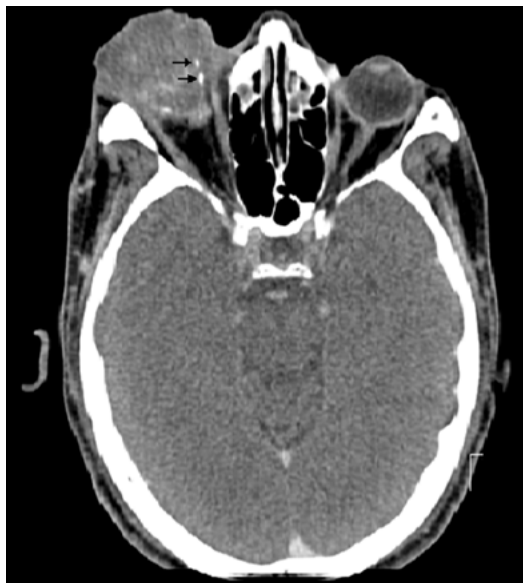## Case Report

A 50-year-old male presented with 'worms' coming out of his right eye associated with bleeding for two days following an accidental injury with a stick. His right eye was reportedly small in size with no functional vision from childhood. He also complained of swelling and minimal discomfort of the eye for the last two years. There was no history of loss of weight or appetite. He did not have any other systemic complaints at the time of presentation.

On examination, the right eye had no perception of light and was replaced by a

**Correspondence:** David Mathew, Bansara Eye Care Centre, Lady Veronica Lane, Laitumkhrh, Shillong 793003, India.  
E-mail: [davidmathew123@gmail.com](mailto:davidmathew123@gmail.com)

tumor-like outgrowth with surface ulceration with associated areas of keratinization (Fig. 1). The tumorous outgrowth was friable and bled easily, with live maggots visible over the surface. The best corrected visual acuity in the left eye was 20/60 and the examination was within normal limits except for an immature cataract which accounted for the vision. There was no significant regional enlargement of lymph nodes. Despite the inflammation, the patient did not complain of pain.



**Fig. 1.** The right eye of the patient was blind with no perception of light, with a tumor-like outgrowth with surface ulceration with associated areas of keratinisation.

The maggots were removed manually using forceps under topical anesthesia (Proparacaine 0.5%) under the microscope. Manual removal of the maggots was continued over the next five days and over 100 maggots, three to five mm in size, were removed. All the maggots could not be removed in a single sitting as they kept burrowing deep into the ocular tissues. Solvent ether (Hydroquinone 0.002% weight/volume) was used to force the maggots to come to the surface. Concurrently, the patient was started on systemic antibiotics to treat secondary infection of the orbital tissues.

Computed Tomography of the orbit showed a heterogeneous lesion replacing the eyeball completely with few calcific foci within, causing proptosis of the right eye (Fig. 2). A small nodular part of the lesion was seen invading the optic nerve. The optic nerve appeared thin when compared to the other side. The lesion was seen to abut the proximal part of the recti. There was no intracranial extension. Cavernous sinus and superior ophthalmic vein were normal. There was no bony erosion.

After five days, the patient underwent right eye enucleation for total eradication of the maggots with local debridement.

The gross pathological examination showed a hemorrhagic tumor involving



Fig. 2. Computed Tomography of the orbit showing a heterogeneous lesion replacing the eyeball completely with few calcific foci within (black arrows), causing proptosis of the right eye.

the entire globe extending from the retina to the anterior chamber. Histopathological examination showed sheets and lobules of Glial Fibrillary Acidic Protein (GFAP) positive neoplastic astrocytes displaying mild nuclear pleomorphism. The tumor cells ranged from spindle shaped to polygonal and the latter had abundant glassy cytoplasm. The tumor was richly vascular with foci of tumor cells forming pseudo-rosettes around vascular channels. There were large areas of hemorrhage and perivascular hyalinization. The cornea showed extensive ulceration with microbial colonization. Focal discrete granulomas composed of multinucleate giant cells, histiocytes, lymphocytes, plasma cells and eosinophils. Immuno-histochemical staining of the tumor cells showed immunopositivity for S-100 and Vimentin. A diagnosis of a low grade glial neoplasm consistent with Astrocytoma (WHO Grade 2) was made.

Postoperatively, the patient was given regular socket care with dressings and he was discharged with protective glasses and education on personal hygiene. The patient was kept on periodic follow-up for the last three years and has not had any recurrences or repeat infestations until the last follow-up visit.

## Discussion

Myiasis is a frequent occurrence in the tropics but only up to 14% are associated with infestation of ocular tissues.<sup>1,4</sup> It is caused by flies which lay eggs in dead or decaying tissue and open wounds, most commonly in animals. Humans are considered an accidental host.<sup>4</sup> Diptera flies are considered responsible for ophthalmomyiasis. The species of the larva in this case was not established, but a good majority of ophthalmomyiasis cases are caused by *Oestrus ovis* (sheep nose botfly), *Dermatobia hominis* (human botfly), *Cochliomyia hominivorax* (screw worm), *Hypoderma bovis* (ox warble fly) and *Lucilia sericata* (greenbottle fly).<sup>5,6</sup>non-comparative, interventional case series. Participants consisted of patients (n = 9)

Mechanical removal of maggots is an important step in the management of patients with myiasis. The use of ether to narcotize the larvae is the most common reported maneuver. Manual removal of maggots can also be aided by the use of turpentine, ethanol, topical chloroform, petroleum jelly or hydrogen peroxide. Four-percent xylocaine has also been tried to immobilize the larvae.<sup>7</sup> Antibiotics and Ivermectin as a 0.2 mg/kg oral single dose have also been advocated.<sup>8</sup> Hot water is used to kill the larvae. This preserves the shape of the body of the larvae as the posterior spiracles are important for species identification.<sup>9</sup>

Destructive ocular myiasis is almost exclusively found in debilitated and emaciated patients. A rural background, crowded conditions and poor personal hygiene are other predisposing factors. Trauma, as in this case, is thought to be an important risk factor leading to maggot infestation.<sup>4</sup> Flies are attracted to the wounds to the foul smell of the focal necrosis secondary to the ulcer, which then lay eggs directly at the affected site. The eggs may also be transferred by the patient as a result of scratching. Although our patient did not have any predisposing debilitating systemic disease, he had a long-standing tumor, the focal necrosis of which could have acted as an attractant for flies. The trauma he sustained could have been an additional insult leading to further tissue necrosis.

Ocular myiasis can assume clinical presentations of varying severity which can range from isolated infestation to a rapid and total destruction of the orbital tissues with a cavern filled with crawling maggots. Infection, ischemic necrosis and malignancy coupled with overcrowding, poor living conditions, presence of excessive arthropods in the locality and low levels of hygiene drastically increase the risk of myiasis.<sup>8</sup> Patients who have neglected long-standing lesions should be informed of the rare possibility of myiasis, especially if wound care is inadequate.

## References

1. Ziemianski MC, Lee K y, Sabates FN. Ophthalmomyiasis interna. Arch Ophthalmol 1980;98(9):1588-1589.
2. Rocha EM, Yvanoff JL, Silva LM, Prado AP, Caldato R. Massive orbital myiasis infestation. Arch Ophthalmol 1999;117(10):1436-1437.
3. Radmanesh M, Khataminia G, Eliasi P, Korai MK, Ebrahimi A. Chrysomya bezziana-infested basal cell carcinoma destroying the eye. Int J Dermatol 2000;39(6):455-457.
4. Puthran N, Hegde V, Anupama B, Andrew S. Ivermectin treatment for massive orbital myiasis in an empty socket with concomitant scalp pediculosis. Indian J Ophthalmol 2012;60(3):225-227.
5. Denion E, Dalens P-H, Couppié P, et al. External ophthalmomyiasis caused by Dermatobia hominis. A retrospective study of nine cases and a review of the literature. Acta Ophthalmologica Scandinavica 2004;82(5):576-584.
6. Thakur K, Singh G, Chauhan S, Sood A. Vidi, vini, vinci: External ophthalmomyiasis infection that occurred, and was diagnosed and treated in a single day: A rare case report. Oman J Ophthalmol 2009;2(3):130-132.
7. Sardesai VR, Omchery AS, Trasi SS. Ocular Myiasis with Basal Cell Carcinoma. Indian J Dermatol 2014;59(3):308-309.
8. Costa DC, Pierre-Filho P de TP, Medina FMC, Mota RG, Carrera CRL. Use of oral ivermectin in a patient with destructive rhino-orbital myiasis. Eye (Lond). 2005;19(9):1018-1020.
9. Mathur SP, Makhija JM. Invasion of the orbit by maggots. Br J Ophthalmol. 1967;51(6):406-407.



# Combined Möbius syndrome and tarsal kink syndrome — A unique presentation

Anuradha Raj, R.C. Nagpal, Renu Dhasmana, Amit Maitreya

Department of Ophthalmology, Himalayan Institute of Medical Sciences,  
Swami Rama Himalayan University, Swami Ram Nagar, Jolly Grant, Dehradun,  
Uttarakhand

## Abstract

A two-year-old girl presented with complaints of watering from the left eye since birth. On examination the child had entropion of both lids of the left eye. She was unable to close her lids firmly besides limitation in abduction in both eyes. On the basis of clinical examination it was opined to be a case of Möbius syndrome with its association of tarsal kink syndrome — an extremely rare presentation. The surgery was performed for the left upper and lower lids comprising of tarsotomy, marginal rotation and levator suturing with tarsal plate for upper lid and strengthening the inferior lid retractors by its advancement to the lower tarsal plate for lower lid entropion.

**Keywords:** Möbius syndrome, tarsal kink syndrome, congenital entropion

## Introduction

The tarsal kink syndrome (TKS), a rare and severe form of congenital upper eyelid entropion with a marked kink in the entire horizontal length of the upper tarsal plate with resultant inversion of the eyelid margin, was described in 1948.<sup>1</sup>

The etiology of tarsal kink may be attributed to overacting orbicularis fibers, an aponeurotic defect, a primary tarsal defect or an exogenous mechanical force *in utero*.<sup>2</sup> Secondary blepharospasm and an absent eyelid crease are landmark features of this syndrome. The folded edge of the upper tarsus or the inturned eyelashes may traumatize the cornea and cause corneal abrasion, ulceration, keratitis and stromal opacification. Surgery is usually required to prevent corneal damage.

Paul Julius Möbius, a German neurologist, in 1888 first described a clinical entity of bilateral combined palsies of the 6<sup>th</sup> and 7<sup>th</sup> cranial nerves that subsequently carried his name.<sup>3</sup> Möbius syndrome (MS) results due to underdevelopment of the abducent and facial cranial nerves.<sup>4</sup> The etiology of MS is multifactorial with most supported factor of transient ischemic or hypoxic insult to the fetus.<sup>8</sup> Infectious, genetic etiologies and the use of misoprostol, a prostaglandin-E1 analog and abortifacient during pregnancy has also been implicated.<sup>5</sup> We report a case of unilateral TKS of the upper eyelid and entropion of both lids in a case of MS which has not been reported in literature yet.

**Correspondence:** Dr. Anuradha Raj, Assistant Professor, Department of Ophthalmology, Himalayan Institute of Medical Sciences, Swami Rama Himalayan University, Swami Ram Nagar, Jolly Grant, Dehradun, Uttarakhand.  
E-mail: [dranuradha\\_sagar@yahoo.com](mailto:dranuradha_sagar@yahoo.com)

## Case Report

A two-year-old girl presented with tearing from left eye since birth and found to have inturned lashes in both upper and lower lids. She was unable to move her eye laterally and could not close the eye completely. The child was born at full term by Caesarian section after an uncomplicated pregnancy. There was no family history of muscular or neurological disease and no consanguinity. Pediatric examination showed dysmorphic facial features, flat left hemifacies with delayed milestones.

She had a history of difficulty in sucking the milk from bottle or swallow food but could feed from the breast. On facial examination her upper lip was stiff and retracted and she was not able to smile or wrinkle her face. She had mask like facies. She was unable to close her eyes fully, smile, frown or raise her eyebrows. Bell's phenomenon was good. The mouth opening was very small with a normal-sized tongue which could not be protruded. The lower jaw had micrognathia or retrognathia. The front teeth were touching the lower lip while closing the mouth because of incomplete formation of the maxilla, which is called an anterior open bite (Fig. 1). No evidence of a high arched palate or cleft palate was seen. On ophthalmological examination, the child had esotropia of 40 prism dioptre and extraocular movement examination revealed limitation of abduction of  $-4$  on either side. Retinoscopy was  $-5\text{DSph}/-1.75\text{D cyl } 180^\circ$  and  $+0.75\text{DSph}/-4.0\text{D cyl } 75^\circ$  for the right and left eye respectively. She was turning her head to see the objects in temporal fields. Dolls-eye movements were absent and no nystagmus was observed. The left eye had entropion with mild ptosis, epicanthal fold with inturned cilia of both upper and lower lids (Fig. 2). On palpation a ridge was felt three mm away from the upper lid margin. On eversion of upper lid tarsal kink was seen as a concavity of the tarsus beneath the conjunctiva. Superficial punctate keratopathy was seen in the central part of cornea as a result of entropion of both lids.

The rest of the anterior and posterior segment examination was unremarkable. The nasolacrimal duct was patent on syringing. MRI brain, echocardiography and auditory examination were unremarkable.

Diagnosis of MS with unilateral TKS and lower lid entropion oculus sinister was established. Surgical management was planned in view of corneal involvement as described by Dilek *et al.*<sup>6</sup>

The surgery was performed under general anesthesia. The procedure adopted for upper lid entropion and tarsal kink was as follows: A horizontal skin incision was made at the symmetrical level of the fellow eye. The tarsal plate was exposed and a horizontal half-thickness incision was made over the tarsal kink. The wound was closed with three double-armed Vicryl 6-0 sutures.

Firstly, the levator aponeurosis was anchored to the tarsal plate involving both edges of the tarsotomy and the sutures were tied firmly. Secondly, these needles were taken out through full thickness of skin incision and tied in a fashion so as to relieve the entropion.

For lower lid entropion, a horizontal incision was made in the skin of the lid about four mm below the upper border of the lower tarsal plate. Inferior retractors were identified and strengthened by anchoring them to the tarsal plate just below its




upper border. Skin sutures were tied in a fashion to make the lids slightly everted.

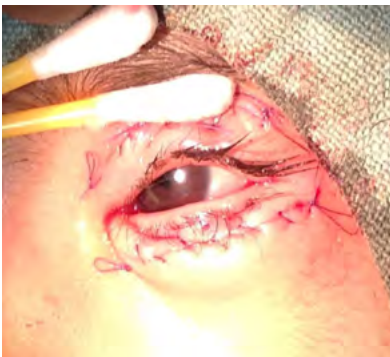Correction of entropion of both lids was achieved on the table (Fig. 3). Topical broad spectrum antibiotic ointment and lubricating eye drops were used postoperatively. Follow-up was done the tenth day and the third month. The child was relieved of both lids entropion and its problems of watering, irritation and pain (Fig. 4).



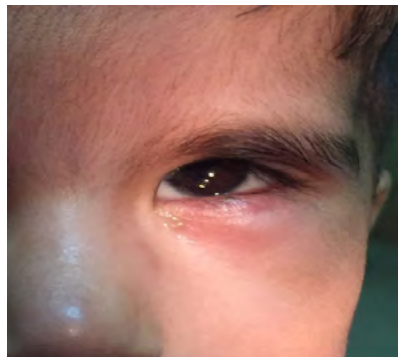**Fig. 1.** Image showing left facial palsy, bilateral esotropia, retrognathia, upper lip retraction, anterior open bite with right head turn.



**Fig. 2.** Image showing Left upper and lower lid entropion with epicanthal fold.



**Fig. 3.** Close-up image showing corrected both lids entropion on table.



**Fig. 4.** Postoperative follow up after three months

## Discussion

MS is a rare condition characterized by sixth and seventh nerve palsies. Although it is often diagnosed later, it can be recognized in infants with 'mask-like' expressionless facies noticed during crying and by an inability to suck while nursing because of seventh cranial nerve palsy. Due to sixth nerve palsy, the patient cannot follow objects by moving their eyes outwards. Instead, they turn their head. Abramson *et al.*<sup>8</sup> actually classified and graded the MS on the basis of the clinical findings of cranial nerve palsies and musculoskeletal anomalies by using the acronym CLUFT (cranial nerve, lower limb, upper limb, face and thorax). This grading system included cranial nerve features of either partial or complete sixth or seventh nerve palsies or both; lower extremity findings of talipes equinovarus, ankylosis, longitudinal or transverse deficits; upper extremity involvement with digital hypoplasia or failure of formation; structural facial findings of cleft palate, micrognathia or microtia and thoracic findings of scoliosis, pectoral hypoplasia or other chest wall deformity. CT and MR imaging findings include pons hypoplasia, depression of the fourth ventricle, absence of the medial colliculus at the level of the pons, hypoglossal nuclei hypoplasia, calcification in the pons in the region of the abducens nuclei and cerebellar hypoplasia.<sup>9</sup>

Congenital horizontal tarsal kink as described by Callahan is a rare form of upper eyelid entropion characterized by a horizontal kink within the upper tarsal plate.<sup>7</sup> Early recognition and appropriate management of congenital horizontal tarsal kink by the pediatrician or primary ophthalmologist are important as permanent corneal scarring in newborns can lead to amblyopia. Congenital entropion with tarsal kink can easily be overlooked because of tightly closed lids and difficult eversion of the upper lid in the crying infants. Corneal opacity at birth, absence of upper eyelid crease and lack of visibility of the upper eyelid margin are important clues. Corneal infiltrates were noted in 50% of cases in the collective analysis of prior reports.<sup>2</sup>

Congenital tarsal kink observed in the neonatal period is more severe than at later age as reported by Naik *et al.*<sup>10</sup> It is assumed that the tarsal kink flattens with time.

Zak *et al.*<sup>11</sup> observed multiple cardiovascular, musculoskeletal, and central nervous system abnormalities in a child with congenital primary upper eyelid entropion.

The surgical goal involves weakening the kink with margin rotation and eyelid crease formation which can be corrected by partial thickness horizontal tarsal incision with marginal rotation and strengthening the levator muscle by reattaching it to the tarsal plate and skin edges.<sup>6</sup>

In the present case, upper lid tarsal kink with both lids entropion was corrected in order to prevent corneal pathology and subsequent amblyopia. Its association with MS made this case a unique presentation. In the present available literature, no such case has been reported yet. Physical, occupational and speech therapy will be planned for improving her motor skills and coordination which will lead to better control of speaking and eating abilities. Amblyopia therapy will soon be started and subsequently surgery for esotropia will be planned. The relationship between the congenital entropion of both lids of one eye with tarsal kink of upper lid and MS

is hypothetical issue which could be due to the musculoskeletal involvement. The lower lid entropion can be due to imbalance between orbicularis oculi and lower lid retractors due to facial palsy.<sup>12</sup>

## Conclusion

MS, TKS and lower lid entropion are different in their genesis and their coexistence is unique. In future, such reports may frame some clue in regard to the genesis of this unique combination.

## References

1. Kettesy A. Entropion in infancy caused by folding of the tarsus: report of a case. *Arch Ophthalmol* 1948;39:640-642.
2. Sires BS. Congenital horizontal tarsal kink: clinical characteristics from a large series. *Ophthal Plast Reconstr Surg* 1999;15:355-359.
3. Möbius PJ. Ueber angeborene doppelseitige Abducens-Facialis-Lähmung. *Münchener Medizinische Wochenschrift* 1988;35:91-94.
4. Briegel W. Neuropsychiatric findings of Möbius sequence - a review. *Clin Genet* 2006;70(2):91-97.
5. Pastuszak AL, Schuler L, Speck-Martins CE, *et al.* Use of misoprostol during pregnancy and Möbius syndrome in infants. *N Engl J Med* 1998;19:1553-1554.
6. Yuksel D, Kosker M. The Surgical Treatment of Congenital Tarsal Kink Syndrome Associated With Corneal Ulcer. *Ophthalmic Surg Lasers Imaging* 2011;42:e126-128.
7. Callahan A. *Reconstructive Surgery of the Eyelids and Ocular Adnexa*, pp. 37-40. Birmingham, AL: Aesculapius 1966.
8. Abramson DL, Cohen M, Mulliken JB. Möbius syndrome: classification and grading system. *Plast Reconstr Surg* 1998;102:961-967.
9. Pedraza S, Gamez J, Rovira A, *et al.* MRI findings in Möbius syndrome: correlation with clinical features. *Neurology* 2000;55:1058-1060.
10. Naik MN, Honavar SG, Bhaduri A, Linberg JV. Congenital horizontal tarsal kink - a single-center experience with 6 cases. *Ophthalmology* 2007;114:1564-1568.
11. Zak TA. Congenital primary upper eyelid entropion. *J Pediatr Ophthalmol Strabismus* 1984;21:69-73.
12. Pasco NY, Kikkawa DO, Korn BS, *et al.* Facial nerve paralysis: an unrecognized cause of lower eyelid entropion in the pediatric population. *Ophthal Plast Reconstr Surg* 2007;23(2):126-129.

new concepts  
IN GLAUCOMA

VOLUME 1

# GLAUCOMA RESEARCH AND CLINICAL ADVANCES 2016 TO 2018



Edited by  
**Paul A. Knepper**  
**John R. Samples**

ISBN: 978-90-6299-247-8  
2016. x+326 pages 11x8.5 inch  
(approx. 280x216 mm) Hardbound

List price: € 80.00 / US \$ 100.00\*

**Discount price: € 72.00 / US \$ 90.00\***

\* excl. 6% VAT (only applicable for EU customers) and shipping costs

This first volume of the **new concepts in glaucoma** series was conceived as a platform to express new ideas and approaches to understanding and solving primary open-angle glaucoma. The authors have attempted to expand levels of knowledge, present new ideas and challenge existing theories. Although the authors have painted a broad picture, the central theme of the book is to ask the right questions and seek the answers for patients with primary open-angle glaucoma.

Please use discount code **EYE2016** when ordering at  
[www.kuglerpublications.com](http://www.kuglerpublications.com) for a 10% discount.



Order online at [www.kuglerpublications.com](http://www.kuglerpublications.com)

# Bilateral lightning induced electric cataract and optic neuropathy

David Mathew<sup>1</sup>, Saurabh Kumar Sarma<sup>1</sup>, Jennifer Basaiawmoit<sup>1</sup>

<sup>1</sup>Bansara Eye Care Centre, Laitumkhrah, Shillong, India

## Abstract

*We report the case of a 17-year-old male with decreased vision in both eyes for one month. He had sustained a lightning-related injury two months back while he was operating a charging mobile phone. On examination, he had bilateral cataract and secondary optic atrophy. He underwent cataract surgery in both eyes with good immediate visual outcome. Later, he required laser posterior capsulotomy for significant posterior capsular opacification in both eyes. Electric cataracts can progress quickly and may be prone to developing PCO postoperatively. The surgeon should keep in mind the possibility of posterior segment changes and their implications on the final visual outcome while managing such cataracts.*

**Keywords:** *electric cataracts, lightning injury, Nd:YAG capsulotomy, posterior capsular opacification*

## Introduction

Electric cataracts are rare and lightning-related cataracts and optic neuropathy are rarer still. Visual prognosis in such cataracts depends on the extent of posterior segment involvement, if any. Not infrequently, a total cataract can preclude visualization of the fundus thus affecting prognostication. Postoperatively, there may be a higher incidence of posterior capsular opacification (PCO). We present a case of bilateral electric cataract exploring its progression over time. Management included cataract surgery and post-operative Neodymium: Yttrium Aluminium Garnet (Nd:YAG) laser posterior capsulotomy.

## Case description

A 17-year-old male student presented with decreased vision in both eyes for one month. He had sustained a lightning-related injury two months back while he was operating a charging mobile phone. The mobile phone was in his left hand at the time of the incident. He subsequently fell backwards on the floor with minimal scalp injury. He received treatment from a local hospital for the scalp injury and hand burns.

On examination, best corrected visual acuity was 6/12 N6 in the right eye and 6/24 N36 in the left eye. Pupils were reacting well to light but the pupillary reaction was less brisk on the right. There was no relative afferent pupillary defect. He had a faint anterior subcapsular (Fig. 1A) and thick posterior subcapsular cataract

**Correspondence:** David J Mathew, Bansara Eye Care Centre, Lady Veronica Lane, Laitumkhrah, Shillong 793003, India  
E-mail: [davidmathew123@gmail.com](mailto:davidmathew123@gmail.com)

(Fig. 1B), which was more in the left eye. Fundus revealed optic disc pallor with irregular margins and arteriolar attenuation with sheathing at the peripapillary region suggestive of secondary optic atrophy. The fundus changes were more marked in the right eye (Fig. 2).

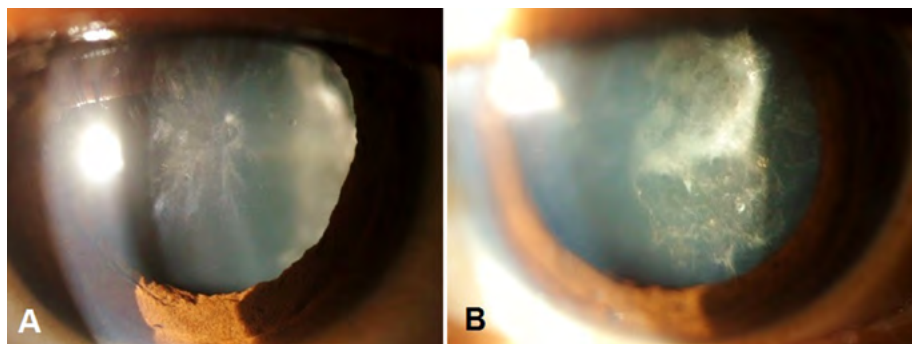


Fig. 1. (A) Slit lamp beam focused on the anterior capsule showing a faint anterior subcapsular cataract in the right eye. (B) Thick, roughly stellate posterior subcapsular cataract in the left eye.

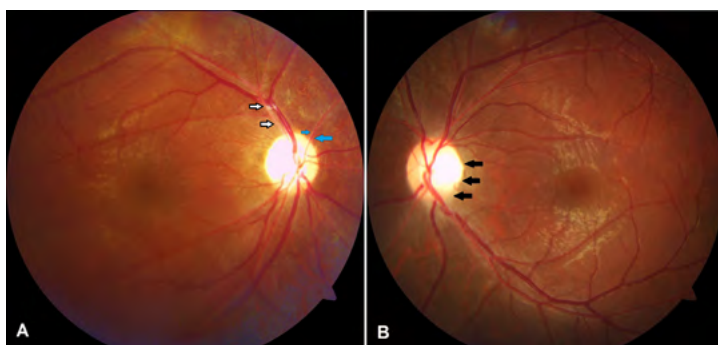


Fig. 2. (A and B) Optic disc pallor with slightly irregular margins (black arrows) and arteriolar attenuation (white arrows) with sheathing at the peripapillary region (blue arrows) suggestive of secondary optic atrophy. The fundus changes were more marked in the right eye.

Color vision was assessed using the Ishihara pseudo-isochromatic plates. The patient could identify all the plates but took longer than normal. Identification of the plates using the right eye was slower than the left. Visual fields were highly unreliable. He underwent cataract surgery in the left eye. He A continuous curvilinear capsulorrhexis was done with difficulty as the anterior capsule was very elastic. Lens matter aspiration was then carried out. A thick plaque was present at the posterior subcapsular region which had to be mechanically lifted and peeled gently off the posterior capsule. A foldable hydrophobic intraocular lens was implanted in the capsular bag. Unaided visual acuity improved to 6/9 and near vision to N6 with correction in the left eye. He was subsequently lost to follow-up till five months later when he presented with a vision of counting fingers close

to the face in the right eye. Left eye vision was stable at 6/9. The cataract in the right eye had increased with a dense posterior subcapsular cataract with no view to the fundus. There was minimal posterior capsular opacification in the left eye. He underwent cataract surgery in the right eye with foldable intraocular lens implantation. Post-operatively, best corrected visual acuity was 6/12 N6 in the right eye. The patient required Nd:YAG laser capsulotomy in both eyes three months later to clear significant PCO. The energy settings used were 1.0 to 1.8 mJ. The number of laser applications was 15 and ten in the right and left eye respectively.

The postoperative target was emmetropia for distance in both eyes after a discussion with the patient. He was amenable to using glasses after surgery for reading. However, the postoperative refraction turned out to be +1.50 DS in the right eye and -0.50 D at 100 degrees in the left eye. The best corrected visual acuity stabilized at 6/12 N6 in the right eye and 6/9 N6 in the left eye.

## Discussion

Lightning-related injuries are more common in the developing countries. Use of mobile phones per se during a lightning storm is deemed safe if the user is not outdoors. However, the use of a charging mobile phone during a lightning storm carries the same risk as using a corded phone. Lightning shocks can be considered as high-current electric shocks. When lightning hits a building, it can take more than one path to reach the ground. As it branches, it prefers the electrical lines and the pipes of the building. It can even pass through air between two of its paths (side flash). Talking on a corded phone or a charging phone can put a person at high risk of electric injury as he or she is in the path of the current. As the electric current passes through the body, the amount of damage inflicted depends mainly on the duration of exposure, intensity of the electric current and the resistance offered by the tissue. Nerves, blood, mucous membranes and muscles offer the least resistance, dry skin offers intermediate resistance and tendon, fat and bone offer the maximum resistance. The thermal damage caused by electric current is directly proportional to the resistance offered.<sup>1</sup>

The onset of decreased vision due to cataract is often a month after the injury. Presentations as late as two years after the injury have also been reported.<sup>2</sup> Lightning related cataracts are usually asymmetric at presentation. Apart from cataract, other ocular damage can include corneal injury, chorioretinal atrophy, optic neuritis, optic atrophy, choroidal rupture, macular cyst, macular hole and retinal detachment to name some.<sup>1</sup> Patients are expected to regain good vision after cataract surgery provided there is no other ocular involvement. Hence, a thorough ocular evaluation is mandatory before commenting on the visual outcome.

The pathogenesis of cataract following electric injury has been attributed to decreased permeability of the capsule, coagulation of lens proteins, concussion due to excessive contraction of ciliary muscle and scar tissue formation with hyaloid deposition in the anterior capsule leading to disturbed lens nutrition.<sup>3</sup> These cataracts generally progress to maturity quickly. Rarely, they can remain stable for up to two years.<sup>4</sup> It is not surprising that many cases present as total cataracts, thus



preventing the care giver from examining the fundus. In such cases, it is prudent to perform a B-scan pre-operatively to rule out retinal detachment and do the cataract surgery under guarded visual prognosis.

Optic neuropathy may be secondary to coagulative necrosis, injury to its vascular supply, damage to myelin sheath and progressive edema leading to compartment syndrome.<sup>1</sup> In our case, secondary optic atrophy could have resulted from optic disc edema which is known to occur in electric ocular injury.<sup>5</sup>

There is no current literature to the best of our knowledge which explores the development of PCO following surgery for electric cataract. However, the role of electric fields in the migration and proliferation of lens epithelial cells has been well-documented.<sup>6</sup> Younger age of the patient in this case may also have contributed to the development of PCO.

In summary, we report a case of bilateral electric cataract and secondary optic atrophy with a satisfactory visual outcome after cataract surgery and Nd:YAG laser posterior capsulotomy. Electric cataracts can progress quickly and may be prone to developing PCO postoperatively. The surgeon should keep in mind the possibility of posterior segment changes and their implications on the final visual outcome while managing such cataracts.

## References

1. Price T, Cooper MA. Electrical and Lightning Injuries. In: Rosen's Emergency Medicine, Concepts and Clinical Practices, 6th ed. Philadelphia: Elsevier Saunders 2006.
2. Hanna C, Fraunfelder FT. Electric cataracts. II. Ultrastructural lens changes. *Arch Ophthalmol* 1972;87(2):184-191.
3. Hashemi H, Jabbarvand M, Mohammadpour M. Bilateral electric cataracts: Clinicopathologic report. *J Cataract Refract Surg* 2008;34:1409-1412. doi:10.1016/j.jcrs.2008.03.044.
4. Duke-Elder S, MacFaul PA. Injuries; Non-Mechanical Injuries. In: Duke-Elder (Ed.), *System of Ophthalmology*, Vol XIV, Part 2, pp. 813-835. London: Henry Kimpton and the C.V. Mosby Co. 1972.
5. Izzy S, Deeb W, Peters GB, Mitchell A. Isolated optic nerve oedema as unusual presentation of electric injury. *BMJ Case Rep* 2014;2014. doi:10.1136/bcr-2014-205016.
6. Zhao M, Chalmers L, Cao L, Viera AC, Mannis M, Reid B. Electrical signaling in control of ocular cell behaviors. *Prog Retin Eye Res* 2012;31:65-88. doi:10.1016/j.preteyeres.2011.10.001.



# Asian Journal of OPHTHALMOLOGY

Volume 15 • Issue 3 • 2017 • 1560-2133

[www.asianjo.com](http://www.asianjo.com)  
[www.kuglerpublications.com](http://www.kuglerpublications.com)