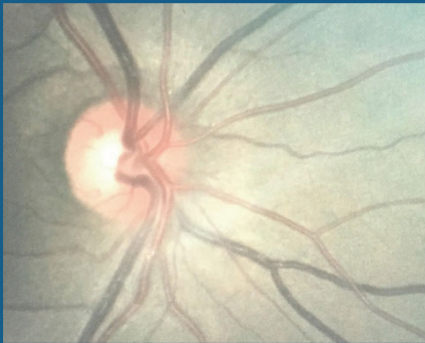



Fundus photograph of amiodarone-induced vortex keratopathy.

# Asian Journal of OPHTHALMOLOGY

open access journal  est. 1998

Volume 17 • Issue 2 • 2020 • 1560-2133



**9th WORLD GLAUCOMA CONGRESS**

MARCH 24 - 27, 2021 KYOTO, JAPAN



[www.worldglaucomacongress.org](http://www.worldglaucomacongress.org)

# Asian Journal of OPHTHALMOLOGY

open access journal  est. 1998

**Asian Journal of Ophthalmology** is the peer-reviewed journal for The Asian Pacific Glaucoma Society (APGS) and The Asia Pacific Ophthalmic Trauma Society (APOTS) and all others with an interest in Ophthalmology.

## Advertising inquiries

The Asian Journal of Ophthalmology offers many sponsorship and advertising opportunities, both online and in print. Please mail us at [info@asianjo.com](mailto:info@asianjo.com) to access the media kit or for queries.

## Copyright

Authors who publish with this journal agree to the following terms:

- Authors retain copyright and grant the journal right of first publication, with the work twelve (12) months after publication simultaneously licensed under a Creative Commons Attribution License that allows others to share the work with an acknowledgement of the work's authorship and initial publication in this journal.
- Authors are able to enter into separate, additional contractual arrangements for the non-exclusive distribution of the journal's published version of the work (e.g., post it to an institutional repository or publish it in a book), with an acknowledgement of its initial publication in this journal.
- Authors are permitted and encouraged to post their work online (e.g., in institutional repositories or on their website) prior to and during the submission process, as it can lead to productive exchanges, as well as earlier and greater citation of published work.

## Disclaimers

All articles published, including editorials and letters, represent the opinions of the authors and do not reflect the official policy of Asian Journal of Ophthalmology, the APGS, its sponsors, the publisher or the institution with which the author is affiliated, unless this is clearly specified. Although every effort has been made to ensure the technical accuracy of the contents of Asian Journal of Ophthalmology, no responsibility for errors or omissions is accepted.

Asian Journal of Ophthalmology, APGS, and the publisher do not endorse or guarantee, directly or indirectly, the quality or efficacy of any product or service described in the advertisements or other material that is commercial in nature in any issue. All advertising is expected to conform to ethical and medical standards. No responsibility is assumed by the APGS, or the publisher for any injury and/or damage to persons or property as a matter of products liability, negligence or otherwise, or from any use or operation of any methods, products, instructions, or ideas contained in the material herein. Because of rapid advances in the medical sciences, independent verification of diagnoses and drug dosages should be made.

## Chief editors

Paul Chew, Singapore  
Keith Ong, Australia

## Editorial office

Asian Journal of  
Ophthalmology/  
Kugler Publications,  
P.O. Box 20538,  
1001 NM Amsterdam,  
The Netherlands.  
[info@asianjo.com](mailto:info@asianjo.com)

## Publisher

Kugler Publications,  
P.O. Box 20538,  
1001 NM Amsterdam,  
The Netherlands.  
[info@kuglerpublications.com](mailto:info@kuglerpublications.com)  
[www.kuglerpublications.com](http://www.kuglerpublications.com)

## Manuscript submissions

Information for authors is available via the website ([www.asianjo.com](http://www.asianjo.com)), through which all manuscripts should be submitted. For inquiries please contact us at: [info@asianjo.com](mailto:info@asianjo.com).

## Peer-review manager

Edmund Ong,  
[edmundong@asianjo.com](mailto:edmundong@asianjo.com)

## Publication frequency

The Asian Journal of Ophthalmology is published four issues per year (quarterly) electronically. Each issue will consist of approximately 48 pages. A selection of the best papers is published in print twice a year and distributed free of charge at congresses through Kugler Publications or partners.

## Open access policy

The Asian Journal of Ophthalmology provides immediate open access to its content after (free) registration, on the principle that making research freely available to the public supports a greater global exchange of knowledge. There are no fees required to publish in the journal.

## BOARD OF EDITORS

### AUSTRALIA

Ivan Goldberg

Paul Healey

### CHINA

Ning Li Wang

### HONG KONG (SAR)

Clement Tham

### INDIA

Garudadri Chandra Sekhar

Kulin Kothari

Lingam Vijaya

### JAPAN

Yoshiaki Kitazawa

Tetsuya Yamamoto

### KOREA

Michael S. Kook

Ki Ho Park

### MALAYSIA

Seng Kheong Fang

### NEW ZEALAND

Stephen Best

### SINGAPORE

Tin Aung

Chelvin C.A. SNG

Lennard Thean

### TAIWAN

Jen Chia Tsai

Da Wen Lu

### THAILAND

Vilavun Puangsricharern

Prin Rojanapongpun

### THE PHILIPPINES

Manuel Agulto

Mario Aquino

Alejandro Chung

### UNITED KINGDOM

Paul Foster

Winnie Nolan

### USA

Robert Ritch

## Focus and scope

As new technologies and therapeutic interventions are continually being developed, Ophthalmology has become a field of rapid change, particularly in the Asia-Pacific region, where disease patterns and health care delivery differ greatly from those seen in the West. Asian Journal of Ophthalmology was established in 1998 with the aim of disseminating information relevant to Ophthalmology and glaucoma throughout Asia and to interested groups worldwide.

The objectives of Asian Journal of Ophthalmology are as follows:

- To provide a platform for the publication of information with a focus on Ophthalmology in Asia.
- To disseminate information that will improve the care of patients with all types of ophthalmological disorders, with a special focus on glaucoma.
- To increase the understanding of such disorders through reporting of educational activities.
- To publish the results of research programmes to expand knowledge about the causes, prevention, and treatment of ophthalmological disorders.
- To work closely with Asian and international researchers to achieve these aims.
- To provide a forum for young and relatively inexperienced researchers to present their research results as Original Articles via an international platform.
- To maintain and promote relationships with any organization with similar goals.

Although the focus of Asian Journal of Ophthalmology mainly was on glaucoma with close ties to the South-East Asian Glaucoma Interest Group (SEAGIG) in the past, the journal now focuses on the entire spectrum of Ophthalmology.

The Asian Journal of Ophthalmology and Kugler Publications have started to collaborate since mid 2012 on the publication of the journal. A new website has been launched ([www.asianjo.com](http://www.asianjo.com)), which facilitates all aspects of the peer-review and publication process, from manuscript submission to publication.

## Table of contents

<b>Editorial</b> Keith Ong	<b>136</b>
<b>Arachnoid cyst of the optic nerve: therapeutic management and progress</b> Irene Temblador-Barba, Carlos Gálvez-Prieto-Moreno, María Martínez-Jiménez	<b>137</b>
<b>Secondary glaucoma due to thrombosis of sigmoid and transverse sinus</b> Matta Rudhira Reddy, Vijaya Pai H.	<b>142</b>
<b>In vitro study on the effect of antibiotic combinations on <i>Staphylococcus epidermidis</i> biofilms</b> Bhupinder Pal Kaur, Shamim Ahmad, Humayoun Ashraf, Giby Thachil	<b>147</b>
<b>Retinal thickness among normal myopic Filipinos using spectral domain optical coherence tomography</b> Camille Elaine Zabala, Jubaida Mangondato-Aquino, Jose Ma. Martinez, John Mark de Leon	<b>156</b>
<b>Amiodarone-induced vortex keratopathy at a low maintenance dose</b> Deepti Mahajan, Anil Verma, Rajesh Sharma	<b>170</b>
<b>Differences of tear film osmolarity between two time-points of the day in healthy subjects</b> Hugo Pena-Verdeal, Covadonga Vazquez-Sanchez, Jacobo Garcia-Queiruga, Carlos Garcia-Resua	<b>173</b>
<b>Ocular surface squamous neoplasia: a case series</b> Gholamhossein Yaghoobi, Abbas Hosseini Rad, Saeed Reza Heydari, Malihe Nikandish	<b>182</b>
<b>The repair of canalicular lacerations with an annular silicone tube and round-tipped pigtail probe</b> Fatih Mehmet Adibelli, Sevim Söker Çakmak	<b>188</b>
<b>Deep anterior lamellar keratoplasty with manual small-incision cataract surgery: a modification of the triple procedure</b> Pawan Prasher	<b>196</b>
<b>Asymptomatic chronic hypotony due to subclinical choroidal effusion after blunt trauma</b> John Mark S. de Leon, Ronald Steven Medalle II	<b>203</b>

<b>Safety and efficacy of reconstituted atropine 0.01% eye drops for Indian children with myopic progression</b> Vidhya C., Kaushik Murali, Sowmya R.	<b>209</b>
<b>Successful management of intralenticular Ozurdex injection causing cataract and intractable glaucoma</b> Kalpa Negiloni, Ronnie Jacob George, Sridharan Sudharshan, Shweta Tripathi	<b>216</b>
<b>Fish hook injury to the eye and its management</b> Sangeetha Jeganathan, Suneetha Nithyanandam, Reji K. Thomas, Shubashree Karat	<b>222</b>
<b>Pterygium excision with suture-less and glue-free conjunctival autograft</b> Fariha S. Wali, Muhammad Jawed, Rafeen Talpur, Naeemullah Shaikh, Shehnilla Shujaat, Khalid I. Talpur	<b>227</b>
<b>Improving the prediction of effective lens position for intraocular lens power calculations</b> Juanita N. Chui, Keith Ong	<b>233</b>



Dear Readers,

We would like to announce that Asian Journal of Ophthalmology (Asian JO) is now a fully online, open-access journal, without the registration requirements for readers. Although Asian JO is not listed on MEDLINE'S PubMed yet, it is indexed in Scopus and Google Scholar. Articles can be found either through those services or through our extensive archive: <https://asianjo.com/index.php/AsianJO/issue/archive>.

Asian JO was the official journal of the Southeast Asian Glaucoma Interest Group (SEAGIG). It was initially published in 1998 and, at that time, was one of the few journals in Asia for authors to publish in. Asian JO is now an international journal serving authors and readers around the world with a publishing team in three continents.

The first publisher of Asian JO was Scientific Communications, based in Hong Kong, which later relocated to New Zealand. When the publisher retired, it became inactive. Fortunately, Professor Paul Chew along with his team at National University of Singapore managed to keep it afloat until Kugler Publications of the Netherlands became its official publisher. Paul asked me to join him in the role as Chief Editor as he needed to devote more time to develop his inventions, which include the micropulse transcleral laser therapy for glaucoma and the Paul Glaucoma Implant shunt. I was introduced to Asian JO when I asked Paul for advice on which journal to publish an article on the Ong Eye Speculum for glaucoma surgery.

Asian JO promotes the publication of novel ideas and surgical techniques. Brief reports and case reports can convey clinical gems that will improve the management of ophthalmology patients. Some journals reject papers describing innovative ideas because they may not conform to the standard research presentation format, but we believe this is a crucial part of the process of scientific discovery.

We have also re-established our role as the official journal of Asia-Pacific Glaucoma Society. For this reason, the next issue of Asian JO will be dedicated to abstracts for the Asia-Pacific Glaucoma Congress (APGC), to be held in Kuala Lumpur on August 14-16, 2020. Hence, Kugler Publications and Asian JO will be present at this conference, and we hope to meet readers and authors to discuss how we can improve the journal.

With kind regards,

Dr. Keith Ong  
Chief Editor

# Arachnoid cyst of the optic nerve: therapeutic management and progress

Irene Temblador-Barba, Carlos Gálvez-Prieto-Moreno,  
María Martínez-Jiménez

Department of Ophthalmology, Hospital Universitario Virgen de las Nieves  
(Complejo Hospitalario), Granada, Spain

## Abstract

**Purpose:** To describe the management of a case of an arachnoid cyst of the optic nerve.

**Methods:** Here, we report a 27-year-old female patient who was diagnosed with arachnoid cyst of the left sheath optic nerve, drained in several occasions, and came to our service because of progressive blurring in the left eye.

**Outcomes:** Due to the location of the lesion, excision could not be performed; so we performed a microsurgical incision with drain by nasal superior transconjunctival approach. After that, the visual acuity (VA) was 0.7, and we could observe that the size of the cyst was smaller than previous examinations with magnetic resonance imaging (MRI). Nowadays, the patient keeps the same asymptomatic VA. So medical appointments are planned to closely follow-up, and periodically, we perform new scan images and visual fields.

**Conclusions:** Arachnoid cysts of the optic nerve are rare, benign, slowly progressive conditions. They can be asymptomatic lesions, especially smaller ones, or may result in proptosis and loss of vision because of the compression. The best imaging examination for their follow-up is MRI. They should be differentiated from optic nerve sheath meningioma and other conditions.

**Keywords:** arachnoid cyst, drain, incision, magnetic resonance imaging, transconjunctival approach

## Introduction

Arachnoid cyst of the optic nerve is a rare benign entity, which is a proliferation of normal fibrovascular tissue that comprises the leptomeninges in the location they are found. These cysts may reveal an appearance similar to optic nerve neoplasm, principally meningiomas,<sup>1</sup> although they also resemble gliomas.<sup>2</sup>

## Case report

Here, we report a 27-year-old female patient who was diagnosed with arachnoid cyst of the left optic nerve, drained in several occasions, and came to our service

**Correspondence:** Irene Temblador-Barba, Department of Ophthalmology, Hospital Universitario Virgen de las Nieves (Complejo Hospitalario), Granada, Spain.  
E-mail: [irenetemblador@gmail.com](mailto:irenetemblador@gmail.com)



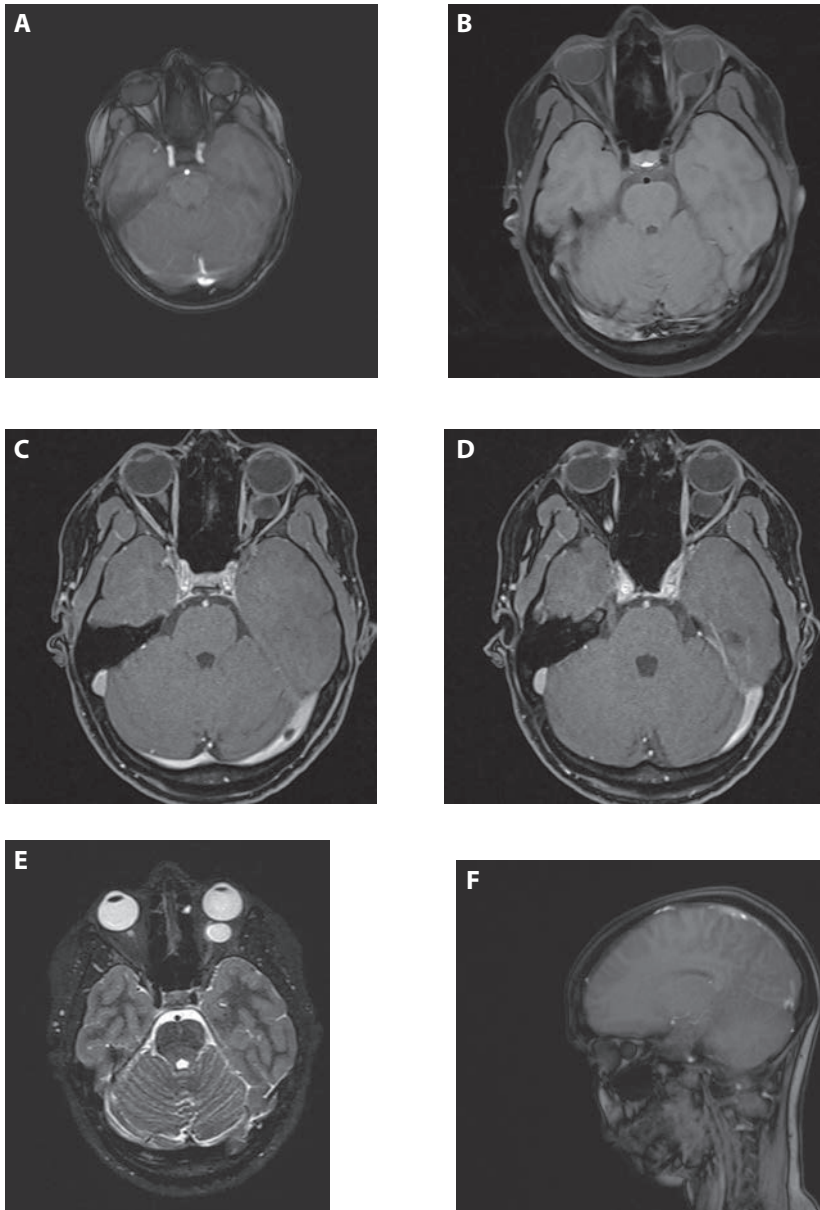


Fig. 1. Preoperative axial MRI scans of the patient. (A) Arachnoid cyst of the left optic nerve. (B) MRI shows enlargement of the left optic nerve. (C) More details about the enlargement of the optic nerve because of the cyst. (D) The whole extension of the cyst. (E) MRI with contrast.

because of progressive blurring in this eye. The visual acuity (VA) was one with the right eye and counting fingers with the left eye. Intraocular tensions were 14 mmHg in both eyes. The pupils and slit-lamp examination were normal. She did not present with exophthalmos. Her ocular fundus showed normality in the right eye, and in the left eye, we could observe transparent papilla at the level of the excavation, where there was liquid behind a hyperpigmented zone. Magnetic resonance imaging (MRI) with and without contrast was performed, and both demonstrated that this cyst was bigger in size than a previous examination done two years earlier in another medical centre (Figs. 1 to 3). Computed tomography showed no calcifications in the orbital/optic nerve mass.

Due to the location of the lesion, excision could not be performed; so we performed a microsurgical incision with drain by nasal superior transconjunctival approach. The incision was perpendicular to the nerve, and its size was about 5 to 6 mm. After that, the VA was 0.7 and the rest of the examination was normal. We could observe that the size of the cyst was smaller than previous examinations with MRI. The fundus examination revealed lower level of liquid, although it was really a very subtle change. The cyst had smaller size than in previous examinations, with diameters of  $13 \times 18$  mm and  $1.7 \text{ cm}^3$  currently compared with previous ones of  $14 \times 19$  mm and  $2.0 \text{ cm}^3$  (both measurements taken in the same plane and sequence for better correlation). It kept the same aspect by image, without pathological enhancement (Figs. 4 and 5). Despite the slight decrease in the size, nowadays, the patient keeps the same asymptomatic VA. So medical appointments are planned to closely follow-up, and periodically, we perform new scan images and visual fields. The visual fields remain stable and a specific pattern has

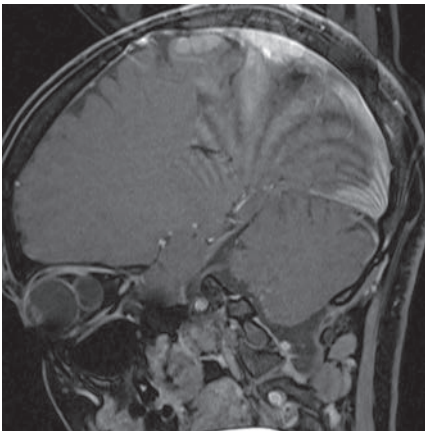


Fig. 2. (A, B) Preoperative sagittal MRI scans of the patient.

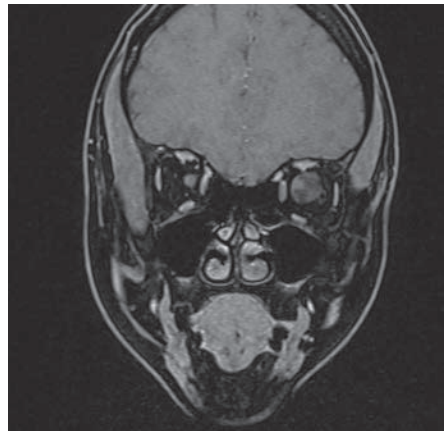


Fig. 3. Preoperative coronal MRI scans of the patient.

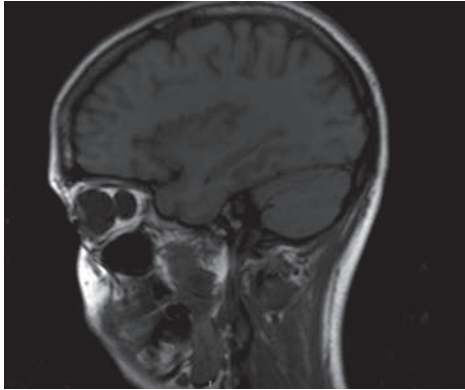


Fig. 4. Postoperative sagittal MRI scan of the patient.

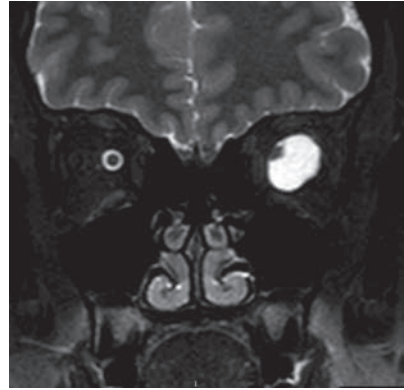


Fig. 5. Postoperative coronal MRI with contrast scan of the patient.

not been observed. Above all, the most important change we have noticed is the improvement in the VA.

## Discussion

The pathogenesis of the arachnoid cyst of optic nerve sheath is still unknown. It is possible that its origin is related to trauma, which leads to cyst formation. Congenital entrapment or sequestration of their secretory neuroepithelial cells secondary to a neoplasm might result in cyst formation, although most of these cysts are idiopathic.<sup>1,3</sup>

The most commonly accepted approach regarding treatment is observation in asymptomatic arachnoid cyst.<sup>4</sup> When they are asymptomatic and don't threaten the vision of the patient, follow-up could be done with visual fields and strict examinations of the optic nerve to be able to detect possible atrophy if this appears. Symptomatic patients are candidates for surgery.<sup>5</sup> These symptoms could be progressive loss vision or proptosis until headache, seizure, and dizziness if they have an intracranial portion.<sup>6</sup> Microsurgical incision or fenestration of the cyst and open excision are the surgical options in the treatment of arachnoid cysts of the optic nerve,<sup>7</sup> and sometimes an additional mini-orbitotomy is needed. Because of the characteristics of our case, we decided for a microsurgical incision with superonasal transconjunctival approach without removing cranial bone.

If an incision is performed instead of excision, there are more possibilities of relapse, but in many cases, this first option cannot be performed because of the location of the mass. In cases of possible optic nerve sheath arachnoid cyst, a biopsy is potentially both diagnostic and therapeutic.<sup>1</sup> Indications for biopsy include evaluation for neoplasm, particularly meningioma and for decompression.

Decompression may result in resolution of disc oedema if it exists and some visual improvement.<sup>1,8</sup> The differential diagnosis has to be established between meningioma, hemangioma, glioma, or another type of tumours.<sup>2</sup>

## Conclusions

Arachnoid cysts of the optic nerve are rare, benign, fibrovascular proliferations that comprise the leptomeninges that surrounds the optic nerve, and normally their progression is slow. They can be asymptomatic lesions, especially smaller ones, or may result in proptosis and loss of vision because of the compression. The best imaging examination for their follow-up is the MRI. They should be differentiated from other conditions, especially the tumours.

## Conflict of interest

No potential conflict of interest relevant to this article has been reported.

## References

1. Akor C, Wojno TH, Newman NJ, Grossniklaus HE. Arachnoid cyst of the optic nerve. Report of two cases and review of the literature. *Ophthalmic Plast Reconstr Surg*. 2013;19(6):466-469.
2. Moschos MM, Lymberopoulos C, Moschos M. Arachnoid cyst of the optic nerve. A case report. *Klin Monbl Augenheilkd*. 2004 May;221(5):408-409.
3. Holt H. Cysts of the intracranial portion of the optic nerve. *Am J Ophthalmol*. 1966;61:1166-1170.
4. Al-Holou WN, Terman S, Kilburg C, et al. Prevalence and natural history of arachnoid cysts in adults. *J Neurosurg*. 2013;118(2):222-231.
5. Kural C, Kullmann M, Weichselbaum A, Schuhmann MU. Congenital left temporal large arachnoid cyst causing intraorbital optic nerve damage in the second decade of life. *Child Nerv Syst*. 2016;32:575-578.
6. Wester K, Moen G. Documented growth of a temporal arachnoid cyst. *J Neurol Neurosurg Psychiatry*. 2000;69:699-700.
7. Pradilla G, Jallo G. Arachnoid cysts: case series and review of the literature. *Neurosurg Focus*. 2007;22(2):E7.
8. Miller NR, Green WR. Arachnoid cysts involving a portion of the intraorbital optic nerve. *Arch Ophthalmol*. 1975 Nov;93(11):1117-1121.

# Secondary glaucoma due to thrombosis of sigmoid and transverse sinus

**Matta Rudhira Reddy, Vijaya Pai H.**

*Department of Ophthalmology, Katsurba Hospital, Manipal Academy of Higher Education, Manipal, India*

## **Abstract**

*An 88-year-old female presented with redness in the left eye of one-month duration. On examination, the left eye showed 3 mm of proptosis with dilated and tortuous episcleral vessels and relative afferent pupillary defect. Intraocular pressure was 60 mmHg and showed open angles on gonioscopy with cup disc ratio of 0.8 in OS. A diagnosis of secondary open-angle glaucoma due to elevated episcleral venous pressure (EVP) was made. Magnetic resonance venogram revealed thrombosis of transverse and sigmoid sinus on the left side. This is the first case report of secondary open-angle glaucoma due to elevated EVP following thrombosis of transverse and sigmoid sinus.*

**Keywords:** *glaucoma, raised episcleral venous pressure, venous thrombosis*

## **Introduction**

Elevated episcleral venous pressure (EVP) is one of the causes of secondary open-angle glaucoma. Any condition that raises EVP also raises intraocular pressure (IOP) by obstructing the post-trabecular flow of aqueous humor.<sup>1</sup> The causes of glaucoma secondary to elevated EVP fall into three categories: (a) arteriovenous anomalies, (b) venous obstruction, and (c) idiopathic variety.<sup>2</sup> Most of the cases are idiopathic, often without angiographic abnormalities.<sup>3</sup> Cases of glaucoma secondary to elevated EVP due to cavernous sinus thrombosis have been reported previously.<sup>4</sup> Here, we are reporting a case of secondary open-angle glaucoma, presenting as the initial manifestation of transverse and sigmoid sinus thrombosis without any neurological manifestations.

## **Case report**

An 88-year-old female presented with chief complaints of redness in the left eye for one month. Redness was not associated with pain, headache, and discharge. There was no history of head injury. She had undergone clear corneal phacoemulsification

**Correspondence:** Vijaya Pai H., Department of Ophthalmology, Katsurba Hospital, Manipal Academy of Higher Education, Tiger Circle Road, Madhav Nagar, Manipal, Karnataka 576104, India.

E-mail: [paivijaya@yahoo.co.in](mailto:paivijaya@yahoo.co.in)

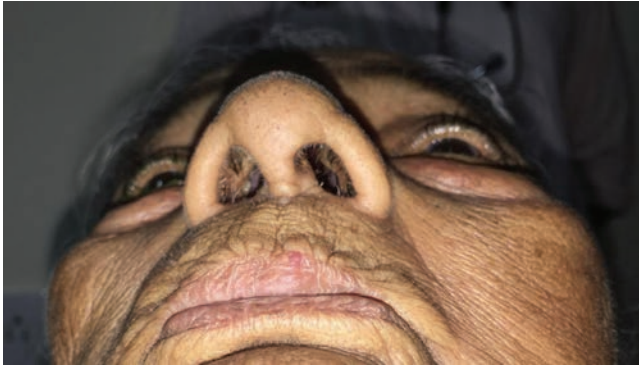

Fig. 1. Proptosis of the left eye.

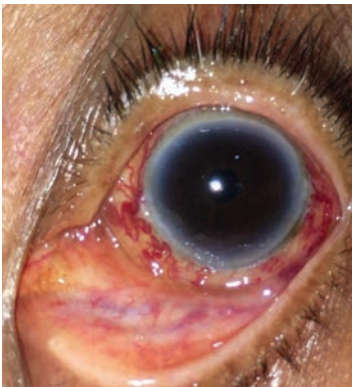

Fig. 2. Dilated and tortuous episcleral vessel OS.

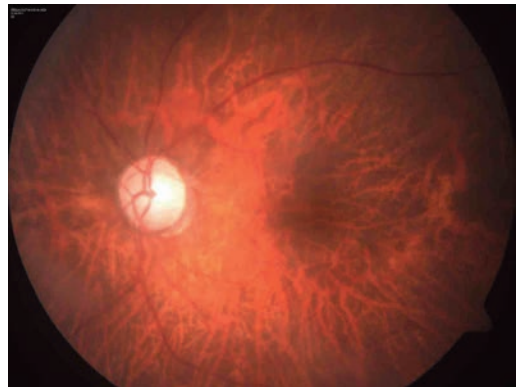


Fig. 3. Optic disc stereo photograph of the left eye showing cup disc ratio of 0.8 OS with disc pallor.

and foldable intraocular lens implantation by the author in the left eye a year ago. Patient was on tablet amlodipine 5 mg for systemic hypertension for the past five years. On examination, her best corrected visual acuity was 6/9 OD and 6/6p OS. The left eye showed proptosis of 3 mm with Hertel's exophthalmometer (Fig. 1). On auscultation, there was no bruit heard. The left eye showed dilated and tortuous episcleral vessels (Fig. 2), relative afferent pupillary defect, and pseudophakia. Anterior chamber was of normal depth and there was no flare or cells. The right eye examination showed nuclear sclerosis. IOP was 16 mmHg OD and 60 mmHg OS with Goldmann applanation tonometer. Gonioscopy revealed open angles in both eyes, with blood in the Schlemm's canal of the left eye.

Dilated fundus examination showed cup disc ratio of 0.3 OD and 0.8 OS with disc pallor (Fig. 3).



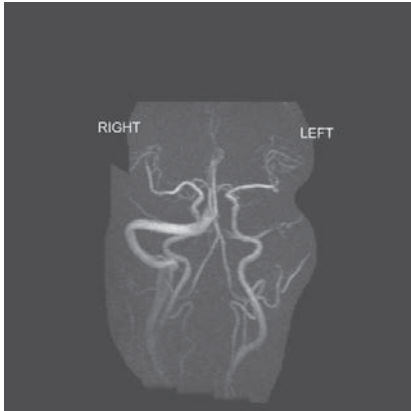


Fig. 4. Magnetic resonance angiogram showing no evidence of AV fistula, nonfilling of transverse sinus on the left side.

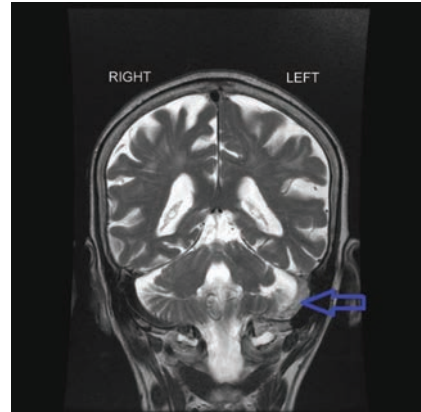


Fig. 5. Magnetic resonance imaging showing thrombus in the left sigmoid and transverse sinus.

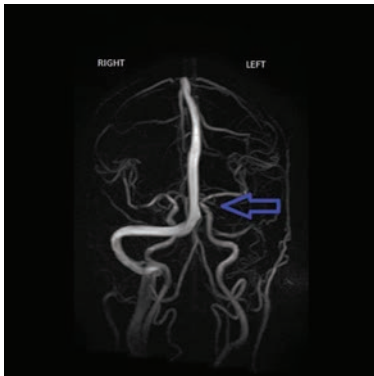


Fig. 6. Magnetic resonance venogram shows no flow in sinuses on left sigmoid and transverse sinus suggestive of thrombosis.

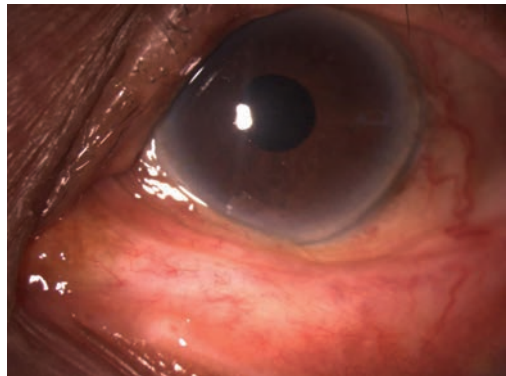


Fig. 7. Posttreatment—decreased congestion of episcleral vessels.

A diagnosis of secondary open-angle glaucoma due to elevated EVP OS was made. We thought it could be due to arteriovenous (AV) fistula of low flow type. Magnetic resonance angiogram did not reveal any evidence of AV fistula (Fig. 4). However, left-side transverse and sigmoid sinuses showed poor filling and thrombus (Fig. 5).

Radiologist suggested magnetic resonance venogram to rule out venous thrombosis. Magnetic resonance venogram revealed thrombosis of transverse sinus and sigmoid sinus on the left side (Fig. 6).

The patient was started on topical on dorzolamide 2% and Timolol 0.5% combination eye drops in the left eye. Patient was referred to the physician for further management of the thrombosis of the sinuses. Patient was investigated for coagulopathies and all were negative. Activated partial thromboplastin time, prothrombin time, was normal and lupus anticoagulant was negative. The physician recommended T. aspirin 150 mg/day.

On follow-up, patient IOP reduced to 26 mmHg. Episcleral venous congestion reduced (Fig. 7). At four weeks posttreatment, IOP was 18 mmHg.

## Discussion

Cerebral sinus venous thrombosis (CSVT) is a rare type of venous thromboembolism. CSVT represents almost 0.5 to 3% of all the types of stroke,<sup>5</sup> affecting predominantly younger people. Clinical manifestations of CSVT are variable and not specific, thus making the definite diagnosis difficult. Common manifestations include headache, altered consciousness, focal neurologic deficits, and seizure. The ocular manifestations include obscuration of vision, papilledema.<sup>6</sup> Our patient presented with dilation of episcleral vessels with raised IOP with no other neurological symptoms, which is unusual. EVP is a component of the normal IOP, and any rise in EVP is associated with the same amount of increase in IOP and typically has a wide open anterior chamber angle, with blood in the Schlemm's canal. The normal EVP is 8 to 10 mm Hg. When the EVP rises, a similar rise occurs in the IOP.<sup>7</sup> AV fistula is the most common cause of secondary open-angle glaucoma due to elevated EVP.<sup>8</sup> The episcleral venous system mainly drains into the anterior ciliary and superior ophthalmic veins, finally draining into the cavernous sinus. Thus, any disease process that affects this drainage pathway because of structural, occlusive, compressive, or destructive physiopathology may alter the IOP.<sup>9</sup> Transverse and sigmoid sinus thrombosis causing increase in EVP is not yet reported. Magnetic resonance imaging and computed tomography are useful to diagnose these conditions. MRV features include nonvisualization of the vessel indicating no flow, flow defect, and presence of collaterals at the site of occlusion.<sup>10</sup> We believe thrombosis of transverse sinus and sigmoid sinus must have caused back pressure on the cavernous sinus, which in turn caused the increase in EVP and secondary glaucoma. Glaucoma associated with raised EVP is difficult to diagnosis and treat. Our patient responded well to topical dorzolamide Timolol combination. IOP decreased from 60 to 26 mmHg in the left eye. Such a remarkable response to topical antiglaucoma medication, possibility of spontaneous resolution of the cerebral venous thrombosis, should be considered. Our patient presented with glaucoma as the initial presentation of cerebral venous thrombosis. We conclude that thrombosis of sigmoid and transverse sinuses is a rare cause of secondary glaucoma.

### References

1. Stamper RL, Lieberman MF, Drake MV (Eds). *Becker-Shaffer's Diagnosis and Therapy of the Glaucomas*. 8th ed. St. Louis: Mosby; 2009:284.
2. Weinberg RN, Jeng S, Goldstick BJ. Glaucoma secondary to elevated episcleral venous pressure. In: Ritch R, Shields MB, Krupin T, eds. *The Glaucomas*. St. Louis: Mosby; 1989:1130.
3. Cioffi GA. *Glaucoma: Basic and Clinical Science Course*. San Francisco, CA: American Academy of Ophthalmology; 2014-2015:95.
4. De Keizer R. Carotid-cavernous and orbital arteriovenous fistulas: ocular features, diagnostic and hemodynamic considerations in relation to visual impairment and morbidity. *Orbit*. 2003 Jun;22(2):121-142.
5. Bousser MG, Ferro JM. Cerebral venous thrombosis: an update. *Lancet Neurol*. 2007;6:162-170.
6. Alvis-Miranda HR, Castellar-Leones SM, Alcalá-Cerra G, Moscote-Salazar LR. Cerebral sinus venous thrombosis. *J Neurosci Rural Pract*. 2013 Oct-Dec;4(4):427-438.
7. Moses RA, Grodzki WJ. Mechanism of glaucoma secondary to increased venous pressure. *Arch Ophthalmol*. 1985;103:1653-1658.
8. Carvalho RA, Delloiagono HS, Jammal AA, Resende GM, Angotti HS. Secondary glaucoma following carotid cavernous fistula. *Rev. Bras. Oftalmol*. 2016;75(2):156-159.
9. Nassr MA, Morris CL, Netland PA, Karcioğlu ZA. Intraocular pressure change in orbital disease. *Sur Ophthalmol*. 2009;54(5):519-544.
10. El Damarawy EA, El-Nekiedy AE, Fathi AM, Eissa ED. Role of magnetic resonance venography in evaluation of cerebral veins and sinuses occlusion. *Alex J Med*. 2012;48:29-34.

# In vitro study on the effect of antibiotic combinations on *Staphylococcus epidermidis* biofilms

Bhupinder Pal Kaur, Shamim Ahmad, Humayoun Ashraf,  
Giby Thachil

Faculty of Medicine, Jawaharlal Nehru Medical College, Institute of  
Ophthalmology, Aligarh Muslim University, Aligarh, India

## Abstract

**Purpose:** Effect of combination of various antibiotics on *Staphylococcus epidermidis* biofilm.

**Study design:** Experimental study.

**Methods:** The biofilm-producing strains of *S. epidermidis* were isolated from 100 patients undergoing cataract surgery before instillation of any antibiotic. The strains were subjected to sensitivity test to various antibiotic combinations. The most effective agent was selected and its minimum inhibitory concentration was determined by broth dilution method. The statistics were performed using SPSS Version 23 (IBM Corp.) and Chi square test.

**Results:** A total of 22 biofilm-positive samples were obtained. The combinations of vancomycin with ceftazidime ( $p < 0.05$ ) followed by moxifloxacin with cefuroxime ( $p < 0.05$ ) were found to be the most effective. Antibiofilm activity was also shown by other antibiotic combination. The minimum inhibitory concentration of vancomycin and ceftazidime in 11 samples was 2.5 and 2.8 mg/ml, while in the rest of the samples, it was 2.5 and 5.6 mg/ml, respectively. The minimum inhibitory concentration of moxifloxacin and cefuroxime was 0.125 and 2.81 mg/ml, respectively.

**Conclusion:** In our study, we conclude that antibiotics are effective in eradicating biofilms.

**Keywords:** biofilms, ceftazidime, cefuroxime, endophthalmitis, moxifloxacin, *Staphylococcus epidermidis*, vancomycin

## Introduction

The postoperative endophthalmitis is the most devastating complication after cataract surgery. The reported incidence varies from 0.01 to 0.367%, and it differs among various surgeries, across studies and countries. It is reported

**Correspondence:** Bhupinder Pal Kaur, Faculty of Medicine, Jawaharlal Nehru Medical College, Institute of Ophthalmology, Aligarh Muslim University, Aligarh, 202002 Uttar Pradesh, India.

E-mail: [bhupinderpalk@gmail.com](mailto:bhupinderpalk@gmail.com)

that 70% of postoperative endophthalmitis occur following cataract surgery. Coagulase-negative *Staphylococcus epidermidis* bacteria has been recognized as the most common organism isolated from the cases of postoperative endophthalmitis.<sup>1</sup> *S. epidermidis* is the main commensal bacterium found on human skin, conjunctiva, and eyelids. It is nowadays seen as an important opportunistic pathogen and causative agent for nosocomial infections, similar to *Staphylococcus aureus* (Centers for Disease Control and Prevention, National Nosocomial Infection Surveillance, 2004). *S. epidermidis* possesses high affinity for indwelling medical devices. The pathogenicity of *S. epidermidis* is contributed by formation of biofilm.<sup>2</sup> Bacteria use biofilm as a way to survive in the nature and hence are difficult to treat because of resistance to host defence and antibiotics.<sup>3,4</sup> The resistance can be contributed to complex biofilm structure and its role in adherence to inert surface.<sup>5</sup> In our study, we tried to select best antibiofilm agent to prevent the postoperative endophthalmitis in patients undergoing cataract surgery. We compare the effect of combination of vancomycin and ceftazidime, vancomycin and amikacin, vancomycin and tobramycin, and moxifloxacin and cefuroxime. Vancomycin is a glycopeptide and covers gram-positive bacteria, whereas ceftazidime and aminoglycosides like tobramycin and amikacin cover gram-negative bacteria. It has been shown in various studies that bacterial contamination occurs during implantation of intraocular lenses (IOLs) and it can be prevented by antibiotic prophylaxis. The aim of our study was to see various antibiotics in combination on the inhibition of biofilm by *S. epidermidis* in patients undergoing cataract surgery and hence prevention of occurrence of postoperative endophthalmitis.

### Materials and methods

This study was an experimental study done in 24 months in Institute of Ophthalmology, Jawaharlal Nehru Medical College Hospital (JNMCH), AMU, Aligarh, from October 2015 to September 2017.

### Bacterial strains

The bacterial strains of *S. epidermidis* were isolated from conjunctival sac and lids of the 100 patients undergoing cataract surgery in JNMCH, AMU, Aligarh. The biofilm producer *S. epidermidis*—MTCC 435 (Microbial Type Culture Collection) and non-biofilm producer *S. epidermidis*—ATCC 12228 (American Type Culture Collection) were used as controls.

## Media used in the study

Nutrient agar for the initial isolation of *S. epidermidis* strains and to determine morphological characteristics of the bacteria.

Modified Congo red agar (CRA) to differentiate the strains of biofilm producers from non-biofilm producers.

## Agents used

1. Inj. vancomycin = 1 mg in 0.1 ml
2. Inj. ceftazidime = 2.25 mg in 0.1 ml
3. Inj. tobramycin = 0.2 mg in 0.1 ml
4. e/d or single moxifloxacin = 0.5% in 0.4 ml. Take 0.05 ml directly (0.0025 mg in 0.05 ml)
5. Inj. cefuroxime = 1 mg in 0.1 ml

## IOL used

The polymethylmethacrylate (PMMA) IOLs were used in the study. The IOLs were used because their surface acts as a platform for the formation of biofilm.

## Technique

The conjunctival and lid swabs obtained during the study were seeded on nutrient agar and stained by Gram staining for determination of purity and morphology and specific staining for isolation of *S. epidermidis* strains. After confirmation of these cultural and morphological characteristics, the strains were subjected to catalase and coagulase tests and other relevant biochemical tests for further identification. The positive growth was transferred to nutrient broth.

## Study of biofilm production

The phenotypic characterization of biofilm production was performed by modified CRA plates as proposed by Kaiser *et al.*<sup>6</sup> The biofilm producers formed black colonies and the non-biofilm producers formed red colonies.

## Antibacterial susceptibility examination of agents under study

The biofilm-producing strains of *S. epidermidis* were subjected to inhibition studies using different antibiotics in combination. For susceptibility, disc diffusion method was used and zone of inhibition was interpreted by NCCLSM100-S12. The media used was nutrient agar. The bacterial suspension of the titrated strain that gives 100 CFU was selected for inoculation on culture plate for antibiotics. After overnight incubation, the zone of inhibition was observed and measured by calipers or ruler. The results are recorded in millimetres, and accordingly, the most effective drug will be selected on the basis of inhibition zone.



## Agents used for antibiotic inhibition

Vancomycin and ceftazidime, vancomycin and amikacin, vancomycin and tobramycin, moxifloxacin and cefuroxime.

The most effective agent was selected and its minimum inhibitory concentration was determined by broth dilution method. About 1 ml of bacterial inoculum and 1 ml of antimicrobial agent were taken in the test tubes along with IOLs and were incubated at 37°C for 24 hours. The antibiotic concentration in least turbid inoculum was taken as minimum inhibitory concentration. The positive control was kept for comparison and it showed growth button. After 24 hours, lenses were taken out and each IOL was gently washed with phosphate-buffered saline and stained with 1% crystal violet to stain and detect biofilm.

## Statistical tests

Analysis was done by using IBM SPSS version 23 and Chi square test.

## Results

A total number of 100 patients undergoing cataract surgery, 52 males and 48 females, were included in this study. The male-to-female ratio was found to be 1:1 (male = 52, female = 48). The mean age of male and female was  $58.53 \pm 11.74$  and  $60.31 \pm 11.56$  years, respectively. All patients were admitted for cataract surgery with IOL implantation. The eye specimens were obtained with the help of moistened sterile cotton swabs in order to isolate *S. epidermidis* strains among

Table 1. Screening of *S. epidermidis* isolates for biofilm production on modified CRA medium

S. no.		Biofilm-positive isolates	Biofilm-negative isolates	Total isolates
1.	Number of isolates	22	12	34
2.	Percentage of isolates	64.71	35.29	

Table 2. Incidence of sensitivity and resistance of biofilm-positive strains to various antibiotic combinations

Drug	Susceptible no (%)	Resistant no (%)	p value
Vancomycin and ceftazidime	18 (81.8)	4 (18.2)	<0.05
Vancomycin and amikacin	12 (54.5)	10 (45.5)	>0.05
Vancomycin and tobramycin	13 (59.09)	9 (40.9)	>0.05
Moxifloxacin and cefuroxime	16 (72.7)	6 (27.3)	<0.05

the normal conjunctival and periocular flora.

Among the confirmed *S. epidermidis* isolates, the percentage of biofilm-positive isolates was found to be 64.71 and the percentage of biofilm-negative isolates was 35.29, as determined by the modified CRA method (Table 1).

As shown in Table 2, the 18 of 22 strains were sensitive to vancomycin and ceftazidime and it was significant ( $p < 0.05$ ). The sensitivity to combination of vancomycin and amikacin was shown by 12 strains whereas about 13 strains were sensitive to vancomycin and tobramycin and it was not significant ( $p > 0.05$ ). The 16 strains showed sensitivity to moxifloxacin and cefuroxime and was significant ( $p < 0.05$ ). Out of 22 isolates of *S. epidermidis*, combination of vancomycin and ceftazidime was the most effective followed by combination of moxifloxacin and cefuroxime. The minimum inhibitory concentration was determined by standard broth dilution method as advised by Clinical and Laboratory Standards Institute (CLSI). The minimum inhibitory concentration of vancomycin and ceftazidime in 11 samples was 2.5 and 2.8 mg/ml, respectively, and in rest of the samples, it came out to be 2.5 and 5.6 mg/ml, respectively. The minimum inhibitory concentration of moxifloxacin and cefuroxime was 0.125 and 2.81 mg/ml, respectively.

## Discussion and conclusion

This study was undertaken to find the role of various antibiotics in prevention of *S. epidermidis*-producing biofilms on IOLs and is first of its kind, thereby highlighting the importance of prophylaxis against endophthalmitis in patients undergoing cataract surgery. We had already conducted study on the adhesion of biofilm-forming *S. epidermidis* strains on IOLs.<sup>7</sup> They compare biofilm formation and adhesion on different IOL materials by *S. epidermidis* isolates obtained from cataract surgery patients.<sup>8</sup> Bacterial adherence to the implant surfaces and biofilm formation seem to depend on the hydrophobicity or hydrophilicity of the biomaterial. The results of this *in vitro* study suggest that *S. epidermidis* biofilms form more readily on hydrophobic acrylic IOLs and least on silicone IOL material. The best possible IOL material, therefore, in terms of suitability for implantation in cataract surgery seems to be silicone compared with PMMA or hydrophobic acrylic (silicone > PMMA > hydrophobic acrylic) in order to minimize biofilm formation and adhesion by *S. epidermidis* strains. The PMMAs were used as these are the most widely used in our institute. So this study is a step forward from the previous study. This study was an attempt to find the best possible agent effective against the biofilm formation on IOLs.

The strains of *S. epidermidis* are supposed to constitute the normal flora of eye but it may be pathogenic and can lead to devastating infections, as mentioned in Medical Microbiology, 4th ed., by Davis (1996). A number of researchers have carried out various studies to determine the incidence of *S. epidermidis* strains, including

methicillin-resistant *S. epidermidis* (MRSE) among preoperative cataract surgery patients. Olson *et al.* performed a study on preoperative cataract patients to find characteristics of bacterial flora on ocular and periocular surfaces. The incidence of *S. epidermidis* was 62.9%, followed by *S. aureus* (14.0%). MRSE accounted for 47.1% of *S. epidermidis* isolates, and methicillin-resistant *S. aureus* accounted for 29.5% of *S. aureus* isolates.<sup>9</sup> In another study in Taiwan, the researchers collected the conjunctival and nasal culture from patients undergoing cataract surgery before instillation of any antibiotic solution. The most common organism found was coagulase-negative *Staphylococcus*.<sup>10</sup> The incidence of *S. epidermidis* was 34% in the patients undergoing cataract surgery in this study.

The most common organism found in the patients of endophthalmitis after cataract surgery, according to the European Society of Cataract and Refractive Surgeons (ESCRS), was *S. epidermidis* (33-77%), followed by *S. aureus* (10-21%). The study of normal conjunctival flora by Keshav and Basu<sup>11</sup> found the same results. Similarly, Trinavarat and Atchaneeyasakul<sup>12</sup> investigated the eyes of postoperative endophthalmitis. The most common bacteria found were coagulase-negative *Staphylococci* and the other were *Streptococcus* spp. and *Corynebacterium* spp. In light of our research, we found that incidence of coagulase-negative *Staphylococci* was 34%, which is a high incidence and this may lead to serious IOL-related infections like endophthalmitis. These results are similar to the Endophthalmitis Vitrectomy Study (EVS) done by ESCRS and the study done by Trinavarat and Atchaneeyasakul in 2005.

The screening of confirmed *S. epidermidis* isolates for the production of biofilm was done by modified CRA method, as described by Kaiser *et al.*<sup>6</sup> with minor modifications. The method is easy to carry out and the results are usually based on the colony colour produced, which ranges from red for non-biofilm-producing strains to black for biofilm-producing strains. This method gave better visualization and easier interpretations, due to the colour homogeneity of the spots, especially for the biofilm-producing strains. Biofilm-forming bacteria develops different mechanism to resist the immune system and antimicrobial drugs.<sup>13</sup> These bacteria alter gene expression, decrease penetration of drugs, and maintain their high density and slow growth.<sup>14</sup> So these factors lead to antibiotic resistance and hence increased virulence.

Vancomycin is a glycopeptide and covers gram-positive bacteria whereas ceftazidime and aminoglycosides like tobramycin and amikacin cover gram-negative bacteria. It is obvious that bacterial adhesion on IOLs occurs during lens implantation phase in cataract surgery. A study done by Özkan *et al.*<sup>15</sup> showed that cefuroxime (0.2 mg/ml), teicoplanin (0.1 mg/ml), and vancomycin (0.1 mg/ml) significantly inhibit bacterial adherence to IOLs. The effect of cefuroxime on adherence inhibition was significantly higher than that of teicoplanin and vancomycin. Bacterial adherence is an important factor in bacterial virulence.

Antibiotics, especially cefuroxime, can successfully inhibit bacterial adherence.

In an *in vitro* study in 2003, Drago *et al.*<sup>16</sup> proved the role of tobramycin and chloramphenicol against the *Pseudomonas aeruginosa* and *S. aureus* biofilm on IOLs. We also use combination of vancomycin and tobramycin for inhibition of biofilm strains of *S. epidermidis*: In this study, this combination was able to inhibit 13 biofilm-positive strains. Vancomycin is active against gram-positive bacteria and used as first line of drug in endophthalmitis. As per EVS, vancomycin is safe to use at 1 mg/0.1 ml concentration. In another study, decrease in *S. epidermidis* biofilm formation on IOLs was noted after treating with vancomycin.<sup>17</sup> Vancomycin was used in concentration of 1 mg/0.1 ml in this study for sensitivity, which is an intravitreal dose vancomycin as suggested by EVS group in 1995. According to Koul *et al.*<sup>18</sup> reduction of endophthalmitis by cefuroxime can be contributed to its anti-adhesion effect. In ESCRS, five- to six-times decrease in endophthalmitis was observed after using the intracameral injection of cefuroxime (1 mg in 0.1 ml in normal saline) at the end of cataract surgery.<sup>19</sup>

Subconjunctival injection of cefuroxime could be beneficial as it shows sustained increase in anterior chamber concentration even after two hours of injection.<sup>20</sup> Moxifloxacin and gatifloxacin combination shows good ocular permeability and has less side effect.<sup>21</sup> Barreau *et al.*<sup>22</sup> showed decrease in the occurrence of endophthalmitis with intracameral cefuroxime from 2,289 patients compared without intracameral cefuroxime (35 from 2,826 patients) with statistically significant ( $p < 0.0001$ ) difference.

The synergistic effect was observed by addition of amikacin and rifampin with vancomycin and teicoplanin on *S. epidermidis* biofilm eradication on polyvinyl catheters.<sup>23</sup> In our study, vancomycin (1 mg/0.1 ml) with amikacin (0.4 mg/0.1 ml) was able to show inhibitory effect on 12 biofilm-positive strains and remaining 10 strains showed resistance, and results were statistically insignificant ( $p > 0.05$ ). The resistance can be contributed to selected subpopulations of *S. epidermidis* that may be methicillin resistant, reducing the effect of antibiotics on biofilm.<sup>24</sup>

Singh *et al.* in 2009 found that *S. aureus* and *S. epidermidis* biofilms reduce the penetration of oxacillin, cefotaxime, and vancomycin whereas no effect was noted that of amikacin and ciprofloxacin. Thus, combination of vancomycin with aminoglycosides (amikacin and tobramycin) may give additive effect on the inhibition of biofilm production and leads to decreased incidence of postoperative endophthalmitis.<sup>25</sup>

Karadag *et al.*<sup>26</sup> reported that moxifloxacin and cefuroxime effectively decrease the adhesion of bacteria to IOL surface. In 2016, Benbouzid *et al.*<sup>27</sup> compared the anti-adherence effect of cefuroxime (1 mg/0.1 ml) and moxifloxacin (0.5 mg/0.1 ml) on the primary attachment phase of *S. epidermidis* on hydrophobic acrylic IOLs.<sup>27</sup> Both moxifloxacin and cefuroxime were able to reduce *S. epidermidis* adhesion on

*hydrophobic acrylic IOLs significantly. Moxifloxacin was more effective in preventing adherence.* Haripriya et al.<sup>28</sup> concluded that routine moxifloxacin (0.5 mg/0.1 ml) prophylaxis leads to reduction of endophthalmitis by 3.5-fold (threefold for small-incision cataract surgery and nearly sixfold for phacoemulsification).

Bacterial virulence is the result of bacterial adhesion. Many researches have been done in the past years to know exact mechanism behind *S. epidermidis* biofilm. Antibiotics are found to be effective in biofilm prevention. So, prior use of antibiotics can halt endophthalmitis caused by biofilm. More studies should be conducted to inhibit the formation and prevention of biofilm.

## References

1. Endophthalmitis Vitrectomy Study Group. Results of the Endophthalmitis Vitrectomy Study; a randomized trial of immediate vitrectomy and of intravenous antibiotics for the treatment of postoperative bacterial endophthalmitis. Arch Ophthalmol. 1995;113:1479-1496.
2. Rupp ME, Ulphani JS, Fey PD, Bartscht K, Mack D. Characterization of the importance of polysaccharide intercellular adhesin/hemagglutinin of *Staphylococcus epidermidis* in the pathogenesis of biomaterial-based infection in a mouse foreign body infection model. Infect Immun. 1999;67(5):2627-2632.
3. Prosser BL, Taylor D, Dix BA, Cleeland R. Method of evaluating effects of antibiotics on bacterial biofilm. Antimicrob Agents Chemother. 1987;31(10):1502-1506.
4. Nichols WW, Evans MJ, Slack MP, Walmsley HL. The penetration of antibiotics into aggregates of mucoid and non-mucoid *Pseudomonas aeruginosa*. J Gen Microbiol. 1989;135(5):1291-1303.
5. Dreeszen PH. Biofilm Key to Understanding and Controlling Bacterial Growth in Automated Drinking Water Systems. Edstrom Industries, Inc. 1997; 2008.
6. Kaiser TD, Pereira EM, Dos Santos KR, Maciel EL, Schuenck RP, Nunes AP. Modification of the Congo red agar method to detect biofilm production by *Staphylococcus epidermidis*. Diagn Microbiol Infect Dis. 2013;75:235-239.
7. Ahmad S, Ashraf H, Akram SM. Adhesion of biofilm forming *Staphylococcus epidermidis* strains on intraocular lenses – an update. In: The Battles Against Microbial Pathogens: Basic Science, Technological Advances and Educational Programs. ISBN-13 Vol 1:978-84942134-6-5, ISBN-13 Collection: 978-84942134-5-8; 2015:357-363.
8. Akram SM. An in vitro study to compare biofilm formation and adhesion on different intraocular lens materials by *Staphylococcus epidermidis* isolates obtained from cataract surgery patients (Thesis submitted in JNMCH, AMU, Aligarh); 2013.
9. Olson R, Donnenfeld E, Bucci FA, et al. Methicillin resistance of *Staphylococcus* species among health care and nonhealth care workers undergoing cataract surgery. Clin Ophthalmol. 2010;4:1505-1514.
10. Lin Y-H, Kang Y-C, Hou C-H, et al. Antibiotic susceptibility profiles of ocular and nasal flora in patients undergoing cataract surgery in Taiwan: an observational and cross-sectional study. BMJ Open. 2017;7(8):e017352.
11. Keshav BR, Basu S. Normal conjunctival flora and their antibiotic sensitivity in Omanis undergoing cataract surgery. Oman J Ophthalmol. 2012;5:16-18.
12. Trinavarat A, Atchaneeyasakul LO. Surgical techniques of cataract surgery and subsequent postoperative endophthalmitis. J Med Assoc Thai. 2005;88:1-5.
13. Donlan RM, Costerton JW. Biofilms: survival mechanisms of clinically relevant microorganisms. Clin Microbiol Rev. 2002;15:167-193.
14. Stewart PS, Costerton JW. Antibiotic resistance of bacteria in biofilms. Lancet. 2001;358:135-138.

15. Özkan B, Karabas VL, Gundes S, Altintaş O, Etiler N, Çağlar Y. Effect of vancomycin, teicoplanin and cefuroxime on *Staphylococcus epidermidis* adherence to intraocular lenses. *J Cataract Refract Surg.* 2005;31:1814-1820.
16. Drago L, DeVecchi E, Nicola L, Gismondo MR. Antimicrobial activity and interference of tobramycin and chloramphenicol on bacterial adhesion to intraocular lenses. *Drugs Exp Clin Res.* 2003;29:25-35.
17. Das T, Sharma S, Muralidhar AV. Effect of vancomycin on adherence to polymethyl methacrylate intraocular lenses; Endophthalmitis Research Group. *J Cataract Refract Surg.* 2002;28:703-708.
18. Koul S, Philipson A, Philipson BT, Kock E, Nylén P. Intraocular levels of cefuroxime in uninfamed rabbit eyes. *Acta Ophthalmol.* 1990;68:455-465.
19. Endophthalmitis Study Group, European Society of Cataract & Refractive Surgeons. Prophylaxis of postoperative endophthalmitis following cataract surgery: results of the ESCRS multicenter study and identification of risk factors. *J Cataract Refract Surg.* 2007;33:978-988.
20. Kamalarajah S, Ling R, Silvestri G, et al. Presumed infectious endophthalmitis following cataract surgery in the UK: a case-control study of risk factors. *Eye.* 2007;21:580-586.
21. Ong-Tone L. Aqueous humor penetration of gatifloxacin and moxifloxacin eyedrops given by different methods before cataract surgery. *Cataract Refract Surg.* 2007;33:59-62.
22. Barreau G, Mounier M, Marin B, et al. Intracameral cefuroxime injection at the end of cataract surgery to reduce the incidence of endophthalmitis. *J Cataract Refract Surg.* 2012;38:1370-1375.
23. Pascual A, Ramirez de Arenello E, Perea EJ. Activity of glycopeptides in combination with amikacin or rifampicin against *Staphylococcus epidermidis* biofilms on plastic catheters. *Eur J Clin Microbiol Infect Dis.* 1994;13:515-517.
24. Palazzo ICV, Araujo MLC, Darini ALC. First report of vancomycin-resistant staphylococci isolated from healthy carriers in Brazil. *J Clin Microbiol.* 2005;43:179-185.
25. Singh R, Ray P, Das A, Sharma M. Role of persisters and small-colony variants in antibiotic resistance of planktonic and biofilm-associated *Staphylococcus aureus*: an in vitro study. *J Med Microbiol.* 2009;58:1067-1073.
26. Karadag S, Ozkan B, Karabas L, Alintaş O, Yumuk Z, Çağlar Y. Effect of cefuroxime and moxifloxacin on *Staphylococcus epidermidis* adherence to intraocular lenses. *Can J Ophthal.* 2009;44:663-667.
27. Benbouzid F, Kodjikian L, Hartmann D, Renaud F, Baillif S. Moxifloxacin superior to cefuroxime in reducing bacterial adhesion of *Staphylococcus epidermidis* on hydrophobic intraocular lenses. *Acta Ophthalmol.* 2016;94:11-15.
28. HariPriya A, Chang F, Ravindran RD. Endophthalmitis reduction with intracameral moxifloxacin prophylaxis. *Am Acad Ophthalmol.* 2017;124:768-775.



# Retinal thickness among normal myopic Filipinos using spectral domain optical coherence tomography

Camille Elaine Zabala, Jubaida Mangondato-Aquino,  
Jose Ma. Martinez, John Mark de Leon

Department of Health Eye Center, East Avenue Medical Center, Quezon City,  
Philippines

## Abstract

**Purpose:** To determine mean macular and retinal nerve fiber layer (RNFL) thickness of myopic Filipinos using spectral domain optical coherence tomography (SD-OCT) and to evaluate influence of age, gender, and degree of myopia.

**Design:** Observational clinic-based cohort

**Methods:** Participants were divided into two groups: low-moderate myopia [spherical equivalent (SE) -0.50 D to -6.00 D] and high-pathologic myopia (SE < -6.00 D and AL > 26.5 mm). Subgroup analyses between low myopia (refraction < -3.00 D or less) and moderate myopia (> -3.00 D to -6.00 D), and high myopia (> -6.00 D to -8.00 D) and pathologic myopia (more than -8.00 D) were done. Macular and RNFL thickness were measured by a SD-OCT and axial length (AL) with non-contact biometry.

**Results:** Of 156 eyes, 88/156 (56%) had low-moderate myopia, 68/156 (44%) had high-pathologic myopia. There were 67/156 (43%) male and 89/156 (57%) female subjects. Mean central foveal subfield thickness measurements were  $264 \pm 24 \mu\text{m}$  for low myopia,  $258 \pm 17 \mu\text{m}$  for moderate myopia,  $253 \pm 25 \mu\text{m}$  for high myopia, and  $218 \pm 48 \mu\text{m}$  for pathologic myopia. Mean RNFL thickness measurements were  $105.62 \pm 3.89 \mu\text{m}$  for low myopia,  $97.6 \pm 2.45 \mu\text{m}$  for moderate myopia,  $85.9 \pm 3.87 \mu\text{m}$  for high myopia, and  $75.14 \pm 3.89 \mu\text{m}$  for pathologic myopia. Average SE ( $p < 0.0001$ ) decreased while AL ( $p < 0.0001$ ) increased with more myopia. Myopia and age significantly affected macular and RNFL thickness parameters except for the following where only the degree of myopia was a significant factor: central foveal, temporal parafoveal, nasal perifoveal, inferior and nasal RNFL thicknesses.

**Conclusion:** Retinal SD-OCT thickness measurements decreased with increasing level of myopia and age. Central foveal, temporal parafoveal, nasal perifoveal, inferior and nasal RNFL thicknesses may be more appropriate SD-OCT parameters among myopic Filipino patients to monitor for glaucoma since they may be less influenced by age.

**Correspondence:** John Mark de Leon, Department of Health Eye Center, East Avenue Medical Center, East Avenue, Diliman, Quezon City, Philippines.

E-mail: [jmarkmd1@yahoo.com](mailto:jmarkmd1@yahoo.com)

**Keywords:** Filipino, macular thickness, myopia, retinal nerve fiber layer thickness, spectral-domain OCT

Myopia is identified by the World Health Organization as one of the leading causes of visual disability and the most common ocular disorder among children and adults worldwide. In the Beaver Dam and Baltimore Eye Studies, the prevalence rates of myopia among adults were 22.7% and 26.2%, respectively.<sup>1</sup> These prevalence rates were seen to be higher for Southeast Asian countries at 31% to 40%, with an exponential growth observed during recent years.<sup>2-4</sup> A clinic-based study in the Philippines revealed a myopia prevalence rate of 59%; however, this was derived from a patient population at a refractive/cataract screening centre.<sup>5</sup> With the current statistics and the projected increase in prevalence rates, myopia poses a large public health impact due to the visual difficulties and other potentially blinding ocular conditions associated with it. By 2030, the projected rate is estimated to be more than 50%. This translates to a significant number of people with potential visual impairment inherent with the condition.<sup>6-8</sup>

Myopic individuals may have structural changes in the eye brought about by the increased axial elongation inherent in the disease process. Moreover, myopia has been established to have associations with other ocular diseases such as glaucoma, optic nerve abnormalities and a myriad of chorioretinal abnormalities.<sup>9</sup> Diagnosis of these conditions becomes a challenge to the examiner because of structural factors. For glaucoma, the tilting of the optic nerve, large ovalness index, deformation of the disc, shallow and large cup, large peripapillary crescent and occasional optic disc hypoplasia of highly myopic subjects impede accurate diagnosis.<sup>10</sup> The recent use of retinal nerve fibre layer (RNFL) thickness analysis using spectral-domain optical coherence tomography (SD-OCT) had aided clinicians in distinguishing glaucomatous damage. However, SD-OCT's may falsely diagnose normal myopic patients with glaucoma since their normative data were collected from normal eyes with low to no myopia.<sup>11</sup> Similarly, the use of SD-OCT macular examination for the diagnosis and monitoring of diseases of the macula may give erroneous results for myopic individuals when compared with age-matched individuals with normal axial length (AL).

The establishment of mean local data for macula and RNFL thickness parameters among myopic patients can be used for comparison in the clinical setting in order to diagnose glaucoma and other macular diseases more accurately and to monitor its progression.

In a meta-analysis done, myopia was defined in most studies as having a spherical equivalent (SE) of  $-0.50$  D or less (58.7% of all included studies).

Classification of myopia was varied among studies. The American Academy of Ophthalmology has defined high myopia as having a SE of less than  $-6.00$  D or an

AL > 26.5 mm. Pathologic myopia was defined as an SE of less than  $-8.00$  D or an AL  $\geq 32.5$  mm.<sup>8,12,13</sup> Due to the increased AL in myopia, there are several ocular structures that may be altered. Studies have demonstrated the direct relationship between retinal thickness and increased AL due to thinning of the choroid and sclera and elongation of photoreceptor outer segments.<sup>14</sup> Previous investigations have also revealed that the optic disc and the peripapillary atrophy start to enlarge at about an AL of  $\sim 26.5$  mm and that the prevalence of myopic retinopathy and glaucomatous optic neuropathy steeply increased beyond this value.<sup>13</sup> There are several ocular diseases associated with myopia. These diseases may develop in part due to the increased AL and the concurrent structural changes induced within the eye. Previous population-based and hospital-based studies have revealed that axial myopia, in particular high axial myopia, is a risk factor for the development of several vitreoretinal pathologies. Myopic patients are also at risk to develop rhegmatogenous retinal detachment and subretinal neovascularization. In addition, they were also seen to have optic nerve changes such as the presence of optic nerve crescents and peripapillary atrophy.<sup>7,13</sup> Because of the structural changes in the eye that occur concomitantly with myopia, it is a challenge for clinicians to diagnose some clinical entities such as glaucoma or macular thinning. For instance, the advent of SD-OCT has been useful in identifying damage. However, a significant number of normal myopic eyes might have been flagged as abnormal primarily because the normative data were derived from eyes with normal to no myopia. Furthermore, the normative data of the OCT machines derive their values mostly from other races, and interracial differences in measurements are not taken into consideration. As a result, it is sometimes difficult for Filipino ophthalmologists to decide whether abnormal values on macular and RNFL thickness are reliable.

The main objective of our study is to determine the mean values for macular and RNFL thickness measures among adult myopic Filipinos. Specific objectives are as follows: (1) to describe the demographic characteristics of patients with myopia, (2) to compare average RNFL and macular thickness measurements across the different degrees of myopia, (3) to evaluate the effects of age and gender on RNFL and macular thickness and (4) to provide mean values for macular and RNFL thickness measurements among the different degrees of myopia.

## Materials and methods

### Study population

This cross-sectional, observational study was conducted at an eye centre of a tertiary government hospital in Quezon City, Metro Manila, Philippines. All the patients seen consecutively at the outpatient department from August 22 to

September 2, 2016, were screened. Patients were included in the study if they satisfy the following inclusion criteria: age >18 years, best-corrected visual acuity (BCVA) better than or equal to 20/40, no history of previous intraocular and refractive surgery and a refraction of  $-0.50$  D or less by automated kerato-refractometer (GRK1 Auto Ref/Keratometer, Ryusyo Industrial Co., Ltd, Osaka, Japan). Patients with other ocular diseases such as glaucoma, chorioretinitis, retinopathies and other neurologic diseases that may alter the optic nerve head, RNFL and the macula were also excluded from this study.

All participants had provided full and informed consent prior to participation in this study. This study was approved by the Institutional Ethics Review Board of the East Avenue Medical Center. All aspects of this study adhered to the tenets of the Declaration of Helsinki.

### **Clinical examination and myopia classification**

All patients underwent complete history-taking, visual acuity testing, colour testing using Ishihara plates, slit-lamp biomicroscopy (Haag–Streit®, Koenz, Switzerland), intraocular pressure measurement using Goldmann applanation tonometry (Haag–Streit®, Koenz, Switzerland), indirect ophthalmoscopy (Keeler® Ophthalmic Instruments, Windsor, United Kingdom) using 20 D and 90 D lenses (Volk® Optical, Inc., Mentor, OH, USA) and objective refraction. All examinations were performed by an ophthalmology resident who was not part of this study.

All recruited patients underwent macular and RNFL thickness measurement using an SD-OCT (Spectralis®, Heidelberg Engineering, Heidelberg, Germany) on the same day. Only those patients whose scans had good centration and quality scores  $\geq 20$  were used for analysis. The thickness of the RNFL, defined as the area between the inner margins of the internal limiting membrane and the outer segment of the RNFL was measured around the optic nerve. The measurement was derived from averaging 16 consecutive circular B-scans, each with a diameter of 3.5 mm. The built-in tracking system (TruTrack® image alignment software) was used to maintain fixation on target areas despite eye movement. The Spectralis® software, version 5.3.3.0, was used. Following this, the OCT volume scan was done on a  $20 \times 20$  degree cube with 49 raster lines, each containing 1,064 pixels, separated by 120 microns. All scans were performed by one technician who is not aware of the patient's screening results, who reviewed each of the scans. Macular thickness measurements were reported using a modified Early Treatment of Diabetic Retinopathy Study (ETDRS) macular map. The ETDRS map has central 1-mm foveal field, surrounded an inner (parafoveal) and outer (perifoveal) subfields having diameters of 3 mm and 6 mm, respectively. AL measurements were done using an optical biometry (IOL Master® 500, Carl Zeiss Meditec, Oberkochen, Germany) by a single technician who was not aware of the screening results.

Table 1. Patient demographics

	Myopia degree				p
	Low (n = 55)	Moderate (n = 33)	High (n = 27)	Pathologic (n = 41)	
<b>Age (years)</b>					
Mean ± SD	36 ± 13	31 ± 10	41 ± 13	43 ± 14	0.001 <sup>a</sup>
Median (IQR)	31 (14)	30 (8)	37 (23)	42 (28)	
<b>Age (years), n (%)</b>					
19-40	40 (73%)	31 (29%)	17 (63%)	18 (44%)	0.001 <sup>a</sup>
41-60	10 (18%)	1 (3%)	8 (30%)	19 (46%)	
>60	5 (42%)	1 (8%)	2 (17%)	4 (33%)	
<b>Gender, n (%)</b>					
Male	30 (54%)	10 (30%)	11 (41%)	16 (39%)	0.140
Female	25 (46%)	23 (70%)	16 (59%)	25 (61%)	
<b>Spherical equivalent (D)</b>					
Mean ± SD	-1.7 ± 0.8	-4.1 ± 0.5	-6.8 ± 0.6	-13.7 ± 4.2	0.000 <sup>a</sup>
Median (IQR)	-2.0 (1.0)	-4.0 (0.75)	-6.8 (0.8)	-12.8 (5.9)	
<b>Axial length (mm)</b>					
Mean ± SD	24.3 ± 0.7	25.7 ± 0.6	26.9 ± 0.9	29.4 ± 2.3	0.000 <sup>a</sup>
Median (IQR)	24.4 (0.9)	25.8 (0.9)	26.7 (0.4)	28.4 (3.0)	

<sup>a</sup>Significant at 5% level

IQR: interquartile range; SD: standard deviation

Participants were divided into two groups for analysis: low-to-moderate myopia (SE -0.50 D to -6.00 D) and high-pathologic myopia (SE less than -6.00 D and AL > 26.5 mm). Furthermore, subgroup analyses between low myopia (refraction less than -3.00 D) and moderate myopia (more than -3.00 D to -6.00 D) and high myopia (more than -6.00 D to -8.00 D) and pathologic myopia (more than -8.00 D) were done.

**Statistical analysis**

Data of evaluable patients were encoded in MS Excel spreadsheets. Data processing and statistical analyses were done using IBM SPSS v. 20.0 statistical software (IBM Corporation, New York, USA). Descriptive statistics were presented

Table 2. Visual acuity

	Myopia degree				p
	Low	Moderate	High	Pathologic	
	(n = 55)	(n = 33)	(n = 27)	(n = 41)	
<b>Visual acuity(LogMar) Mean ± SD</b>	0.04 ± 0.01	0.07 ± 0.13	0.11 ± 0.13	0.45 ± 0.22	0.000 <sup>a</sup>
<b>Median (IQR)</b>	0.00 (0.00)	0.00 (0.10)	0.10 (0.20)	0.40 (0.40)	

<sup>a</sup>Significant at 5% level

IQR: interquartile range; SD: standard deviation

as mean ± SD and median (IQR) and as n (%) for categorical data. Checks for homogeneity of sample population and normality assumption were performed. Kruskal–Wallis test was performed to determine whether the thickness measurements differed across levels of myopia. Stepwise multiple regression analysis was used to provide prediction equations of each macular and RNFL thickness measures considering effects of levels of myopia, age and gender. Regression models based on four levels of myopia (low, moderate, high, and pathologic) and two levels (low-to-moderate and high-to-pathologic) were generated and compared. Diagnostic checks were performed in selecting the best-fit regression models. Normative values of macular and RNFL thickness measures by level of myopia were generated based on the final regression equations generated using four levels of myopia. Statistical significance was based on  $p$ -value  $\leq 0.05$ .

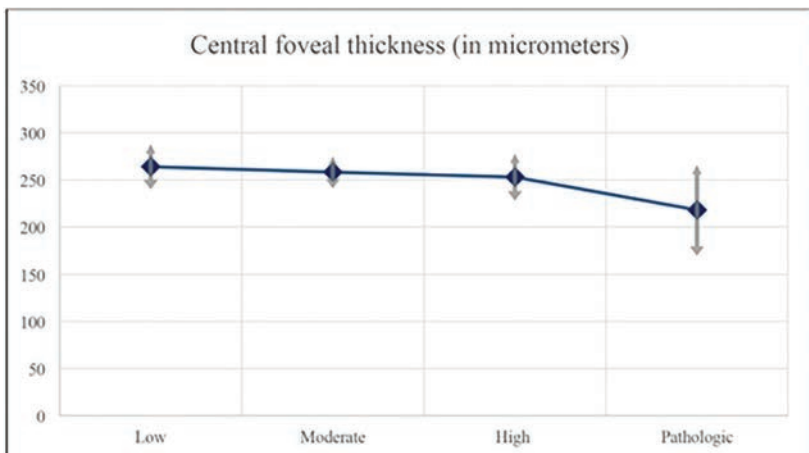


Fig. 1. Mean central foveal thickness across different degrees of myopia

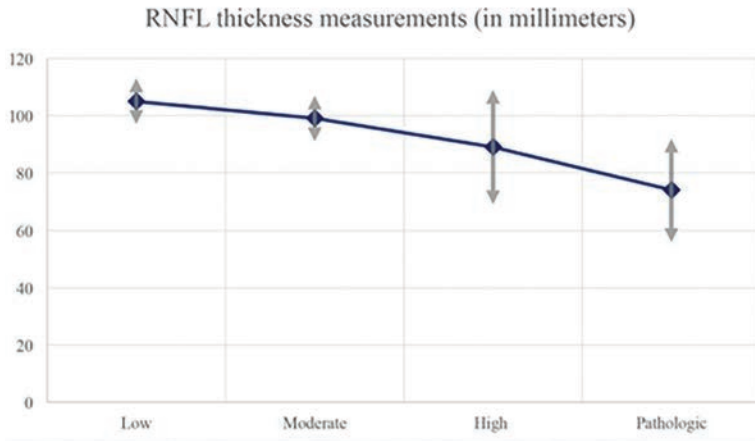


Fig. 2. Mean RNFL thickness across different degrees of myopia

## Results

A total of 175 eyes were included in our study. However, some participants were excluded in the analysis due to the presence of concurrent ocular conditions such as glaucoma (four eyes), previous history of intraocular surgery (eight eyes) and refractive surgery (two eyes). Five scans were also excluded due to poor signal strength.

Table 1 shows the number and percentage of eyes for each of the degrees of myopia. The average age of patients was 32 years (IQR = 23; range from 19 to 67 years old). There were 67/156 (43%) male and 89/156 (57%) female subjects. Majority were unilateral cases (52%;  $p = 0.497$ ). Patients with pathologic myopia were oldest (42 years;  $p = 0.001$ ). Majority of patients with low (73%), moderate (29%) or high myopia (63%) belonged to the 19 to 40 years age group ( $p = 0.001$ ). Most patients with low (54%) myopia were male, while those with moderate, high or pathologic myopia were female ( $p = 0.140$ ). Average SE ( $p = 0.000$ ) and AL ( $p = 0.000$ ) decreased with level of myopia.

It was observed that average BCVA decreased with the level of myopia ( $p = 0.000$ ; Table 2). All patients had normal colour vision by Ishihara testing. For the macula, the mean central foveal subfield thickness was the thinnest among all the parameters at  $249 \pm 33 \mu\text{m}$ . Figure 1 summarizes the mean central foveal thickness measurements and reflects the decrease in the means as the degree of myopia progresses ( $p < 0.0001$ ; Table 3). There were generally thicker measurements for the parafoveal and perifoveal regions. The mean circumpapillary RNFL thickness global average was  $92.51 \pm 18.60 \mu\text{m}$ . Figure 2 summarizes the circumpapillary RNFL thickness and shows that RNFL measurements decreases with level of myopia ( $p < 0.0001$ ; Table 3). Regression equations were generated



Table 3. Comparison between different OCT parameters

Thickness ( $\mu\text{m}$ )	Myopia degree				p
	Low	Moderate	High	Pathologic	
	(n = 55)	(n = 33)	(n = 27)	(n = 41)	
<b>Central foveal</b>					0.000 <sup>a</sup>
Mean $\pm$ SD	264 $\pm$ 24	258 $\pm$ 17	253 $\pm$ 25	218 $\pm$ 48	
Median (IQR)	263 (33)	261 (19)	261 (42)	232 (88)	
<b>Parafoveal superior</b>					0.000 <sup>a</sup>
Mean $\pm$ SD	343 $\pm$ 14	337 $\pm$ 15	320 $\pm$ 19	281 $\pm$ 40	
Median (IQR)	343 (23)	336 (17)	318 (35)	288 (80)	
<b>Parafoveal inferior</b>					0.000 <sup>a</sup>
Mean $\pm$ SD	337 $\pm$ 12	335 $\pm$ 13	316 $\pm$ 21	277 $\pm$ 38	
Median (IQR)	336 (18)	333 (17)	316 (43)	274 (70)	
<b>Parafoveal nasal</b>					0.000 <sup>a</sup>
Mean $\pm$ SD	344 $\pm$ 15	339 $\pm$ 16	322 $\pm$ 20	282 $\pm$ 43	
Median (IQR)	341 (21)	338 (18)	322 (37)	300 (88)	
<b>Parafoveal temporal</b>					0.000 <sup>a</sup>
Mean $\pm$ SD	328 $\pm$ 13	322 $\pm$ 16	311 $\pm$ 18	279 $\pm$ 32	
Median (IQR)	326 (18)	321 (21)	313 (37)	280 (54)	
<b>Perifoveal superior</b>					0.000 <sup>a</sup>
Mean $\pm$ SD	304 $\pm$ 15	303 $\pm$ 10	290 $\pm$ 15	273 $\pm$ 24	
Median (IQR)	304 (19)	304 (15)	287 (15)	277 (29)	
<b>Perifoveal inferior</b>					0.000 <sup>a</sup>
Mean $\pm$ SD	291 $\pm$ 14	288 $\pm$ 9	274 $\pm$ 17	260 $\pm$ 25	
Median (IQR)	292 (20)	289 (9)	277 (30)	263 (31)	
<b>Perifoveal nasal</b>					0.000 <sup>a</sup>
Mean $\pm$ SD	320 $\pm$ 15	316 $\pm$ 13	303 (16)	272 $\pm$ 48	
Median (IQR)	319 (25)	315 (20)	301 (29)	273 (44)	
<b>Perifoveal temporal</b>					0.000 <sup>a</sup>
Mean $\pm$ SD	289 $\pm$ 18	290 $\pm$ 16	275 $\pm$ 18	264 $\pm$ 26	
Median (IQR)	288 (16)	287 (17)	275 (15)	269 (34)	
<b>RNFL global average</b>					0.000 <sup>a</sup>
Mean $\pm$ SD	105 $\pm$ 8	99 $\pm$ 8	89 $\pm$ 20	74 $\pm$ 18	
Median (IQR)	103 (11)	99 (12)	92 (17)	72 (25)	
<b>RNFL superior</b>					0.000 <sup>a</sup>
Mean $\pm$ SD	131 $\pm$ 16	128 $\pm$ 14	111 $\pm$ 17	78 $\pm$ 28	
Median (IQR)	130 (22)	129 (14)	111 (21)	79 (47)	

Thickness (µm)	Myopia degree				p
	Low (n = 55)	Moderate (n = 33)	High (n = 27)	Pathologic (n = 41)	
<b>RNFL inferior</b>					0.000 <sup>a</sup>
Mean ± SD	140 ± 24	125 ± 18	121 ± 16	82 ± 31	
Median (IQR)	138 (23)	128 (19)	121 (16)	85 (44)	
<b>RNFL nasal</b>					0.000 <sup>a</sup>
Mean ± SD	78 ± 15	71 ± 19	67 ± 17	51 ± 20	
Median (IQR)	76 (12)	71 (24)	70 (21)	45 (29)	
<b>RNFL temporal</b>					0.137
Mean ± SD	75 ± 8	75 ± 11	77 ± 16	68 ± 27	
Median (IQR)	75 (10)	77 (13)	76 (21)	69 (37)	

<sup>a</sup>Significant at 5% level

IQR: interquartile range; SD: standard deviation

and compared based on four levels of myopia (low, moderate, high and pathologic and two levels); however, based on the results of diagnostic checks, the final regression models were those generated using four levels of myopia. Multiple regression analysis showed that level of myopia and age influence macular and RNFL thickness parameters except for central foveal subfield thickness, temporal parafoveal thickness, nasal perifoveal thickness, inferior RNFL thickness and nasal RNFL thickness where only the level of myopia was a significant factor (Fig. 3). No regression model could be generated for temporal RNFL thickness since the level of myopia, age and gender were not significant factors. Table 4 shows the reference range of macular and RNFL thickness measurements per level of myopia with correction for age.

## Discussion

In our study among normal myopic Filipinos, the mean central foveal subfield thickness measurement was 249 ± 33 µm. This was lower than the mean of 270 ± 22.5 µm derived using the Spectralis®SD-OCT from a previous study, whose subjects comprised mostly of a Caucasian population with no-to-low myopia.<sup>15</sup> It was closely comparable to the mean value of 250.83 ± 17.04 µm obtained also using the Spectralis®SD-OCT in a previous study from the same institution; however, the subjects were normal Filipinos with no-to-low myopia (unpublished, Dans *et al.*, oral presentation, Philippine Academy of Ophthalmology 2015). These findings may suggest differences between the retinal thickness measurements across different races.

We observed that macular thickness parameters were thinnest at the central foveal subfield, with increasing measurements for the parafoveal and perifoveal

Table 4. Macular and RNFL thickness parameters by degrees of myopia

Thickness parameter	Degree of myopia	Range ( $\mu\text{m}$ )
Central foveal	Low	267.91-268.61
	Moderate	253.84-254.08
	High	239.45-239.87
	Pathologic	224.79-226.61
Parafoveal superior	Low	341.85-352.75
	Moderate	327.14-333.74
	High	302.87-313.81
	Pathologic	281.87-293.63
Parafoveal inferior	Low	336.89-348.21
	Moderate	322.72-329.58
	High	298.83-310.05
	Pathologic	278.43-290.17
Parafoveal nasal	Low	342.65-354.09
	Moderate	328.24-335.12
	High	304-315.22
	Pathologic	283.05-295.03
Parafoveal temporal	Low	331.74-332.14
	Moderate	316.18-317.40
	High	300.55-300.85
	Pathologic	284.75-285.95
Perifoveal superior	Low	299.85-312.61
	Moderate	295.74-303.48
	High	280.25-293.33
	Pathologic	268.96-282.14
Perifoveal inferior	Low	288.57-296.49
	Moderate	282.07-286.87
	High	268.46-276.58
	Pathologic	257.22-265.90

## Retinal thickness among normal myopic Filipinos

Thickness parameter	Degree of myopia	Range (µm)
Perifoveal nasal	Low	324.04-324.46
	Moderate	308.64-308.82
	High	293.15-293.45
	Pathologic	277.29-278.99
Perifoveal temporal	Low	290.62-291.74
	Moderate	282.45-287.55
	High	270.69-279.01
	Pathologic	261.05-270.15
RNFL global average	Low	101.73-109.51
	Moderate	95.15-100.05
	High	82.03-89.77
	Pathologic	71.25-79.03
RNFL superior	Low	127.65-142.03
	Moderate	117.21-126.13
	High	94.46-108.98
	Pathologic	76.8-90.7
RNFL inferior	Low	142.54-143.24
	Moderate	124.64-124.90
	High	106.42-106.72
	Pathologic	88.15-89.31
RNFL nasal	Low	78.62-79.06
	Moderate	70.34-70.60
	High	61.94-62.22
	Pathologic	53.43-54.19

areas. This is consistent with the normal anatomic contour as previously reported in OCT studies of the normal macula among Caucasians.<sup>16,17</sup>

In terms of the circumpapillary RNFL thickness measurements, the mean global average derived in our study was  $92.51 \pm 18.60$  µm. This was lower than the mean measurement of  $100.05 \pm 6.84$  µm using the same OCT device from a previous study done among normal healthy Koreans and comparable to the mean of  $92.7 \pm 7.20$  µm observed among normal healthy Caucasians. Alasil *et al.* observed that Asians had thicker RNFL measurements than their Caucasian and

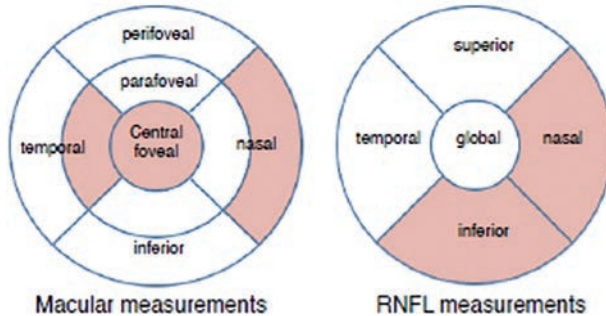


Fig. 3. Degree of myopia and age significantly affected thickness parameters, except for those areas highlighted in red (areas only affected by the degree of myopia).

Hispanic counterparts.<sup>21</sup> The individual RNFL quadrant measurements, however, were all thinner than normal Koreans and Caucasians.<sup>18-21</sup> The inferior circumpapillary RNFL quadrants had the thickest measurements, followed by the superior, temporal and then nasal quadrants. This slightly deviates from the established ISNT rule, where the inferior was thickest, followed by the superior, nasal and then temporal quadrants. An explanation might be the presence of technical difficulties in measuring the peripapillary area due to structural changes brought about by axial myopia. These may include the tilting of the optic nerve, the presence of peripapillary atrophy and a marked elongation and corresponding thinning of the peripapillary scleral flange.<sup>13,18,19</sup>

In general, there was a negative correlation between all macular and RNFL thickness measurements and degree of myopia based on AL. This could be explained by the mechanical stretching of the eyeball that occurs with myopia, which consequently leads to thinning of ocular structures including the retina. Histologically, thinning of the macula in axial myopia is believed to be caused by the secondary defects in the Bruch's membrane that occur with the condition. This was also supported by histologic evidence of the attenuation or lack of the retinal pigment epithelium cells, choriocapillaries, the large choroidal vessel layer and photoreceptors among pathologic axial myopic patients.<sup>13</sup>

Gender was not a contributing factor in terms of macular and RNFL thickness. This was also demonstrated by previous studies done by Tewari *et al.* and Grover *et al.*<sup>15</sup> In contradistinction, some studies done by Song *et al.*, Wong *et al.* and Appatukkan *et al.* revealed that men had thicker macular measurements.<sup>20</sup> They even attributed the higher incidence of macular holes among women to this particular finding, but this was not evident in this study. This was also evident in a previous study among Filipinos, where male subjects had thicker central macular thickness compared with females (unpublished, Dans *et al.*, oral presentation, Philippine Academy of Ophthalmology 2015).

There was also a negative correlation between retinal thickness measurements and age, except for central foveal subfield thickness, temporal parafoveal thickness, nasal perifoveal thickness and inferior and nasal RNFL measurements. This was consistent with a similar study done in India where they also found a negative correlation between age and macular thickness measurements, except for the central foveal thickness. In contrast, in the study done by Grover *et al.*, age had no effect on macular thickness measurements; however, this study was limited by a relatively smaller sample size.<sup>15</sup> There is conflicting evidence in literature as to whether age can affect RNFL thickness.<sup>10</sup> Akashi *et al.* observed that RNFL thickness decreased with age.<sup>11</sup> This thinning may be explained by the histologic evidence of a decrease in the number of ganglion cells, photoreceptors and retinal pigment epithelial cells that come with age.<sup>20</sup> Since the abovementioned retinal thickness measurements in our study were less affected by age, they might be better SD-OCT measurement parameters among myopic Filipino patients to monitor for disease progression.

The linear regression models were used to provide reference values for each of the retinal thickness parameters. However, this may be limited by the sample size and a larger population is needed in order to provide a more accurate normative data for Filipino myopic individuals. Future studies with a larger sample size may be done in order to establish an accepted normative range for myopic individuals. Be that as it may, the derived mean values may be a more accurate reference point in the clinical setting rather than the built-in normative values with the OCT machines. This study also reveals the importance of structural peculiarities of the myopic eye and that clinicians should not readily interpret abnormal OCT findings indicated by the machine as outside of the normal limits.

## Conclusion

The central foveal subfield thickness reference values derived from the mean of a normal cohort for each degree of myopia were as follows: low,  $264 \pm 24 \mu\text{m}$ ; moderate,  $258 \pm 17 \mu\text{m}$ ; high,  $253 \pm 25 \mu\text{m}$  and pathologic,  $218 \pm 48 \mu\text{m}$ . For global average RNFL thickness, the following reference values were derived: low,  $105.62 \pm 3.89 \mu\text{m}$ ; moderate,  $97.60 \pm 2.45 \mu\text{m}$ ; high,  $85.90 \pm 3.87 \mu\text{m}$  and pathologic,  $75.14 \pm 3.89 \mu\text{m}$ . Most of the macular thickness and RNFL measurement parameters were affected by the degree of myopia and age, while gender was not a factor. Generally, thickness measurements decreased with increasing level of myopia as well as age. Therefore, it is important to take into account these factors when analyzing retinal thickness measurements among myopic patients. Since the central foveal, temporal parafoveal, nasal perifoveal, inferior RNFL and nasal RNFL thicknesses were less influenced by age, they may be better SD-OCT measurement parameters to monitor for disease among myopic Filipino patients.

Lastly, using derived mean measurements for each level of myopia and age from a population of the same ethnicity may be a more accurate reference value in the clinical setting than the built-in normative values in OCT machines.

## References

1. Wang Q, Klein BE, Klein R, Moss SE. Refractive status in the Beaver Dam Eye Study. *Invest Ophthalmol Vis Sci.* 1994;35:4344-4347. <https://www.ncbi.nlm.nih.gov/pubmed/8002254>.
2. Zhao J, Pan X, Sui R, Munoz SR, Sperduto RD, Ellwein LB. Refractive error study in children: results from Shunyi District, China. *Am J Ophthalmol.* 2000;129:427-435. <https://www.ncbi.nlm.nih.gov/pubmed/10764849>
3. Lin LL, Shih YF, Hsiao CK, Chen CJ, Lee LA, Hung PT. Epidemiologic study of the prevalence and severity of myopia among schoolchildren in Taiwan in 2000. *J Formos Med Assoc.* 2001;100:684-691. <https://www.ncbi.nlm.nih.gov/pubmed/11760374>.
4. Ling SL, Chen AJ, Rajan U, Cheah WM. Myopia in ten year old children—a case control study. *Singapore Med J.* 1987;28:288-292. <https://www.ncbi.nlm.nih.gov/pubmed/3423791>.
5. Reyes KB, Uy HS. Refractive errors in Filipino eyes in a single-center study population. *Philipp J Ophthalmol.* 2010;35:50-55. [paojournal.com/vol35no2/toc.php](http://paojournal.com/vol35no2/toc.php).
6. Kang SH, Hong, SW, Im SK, Lee SH, Ahn MD. Effect of myopia on the thickness of the retinal nerve fiber layer measured by Cirrus HD optical coherence tomography. *Invest Ophthalmol Vis Sci.* 2010;51:4075-4083. <https://www.ncbi.nlm.nih.gov/pubmed/20237247>.
7. Foster PJ, Jiang Y. Epidemiology of myopia. *Eye (Lond).* 2014;28:202-208. <https://www.ncbi.nlm.nih.gov/pubmed/24406412>.
8. Emerole CG, Nneli RO, Osim EE. Prevalence, distribution and determinants of myopia in Owerri, Nigeria. *J Exp Clin Anat.* 2013;12: 57-61. <http://www.jecajournal.org/article.asp?issn=1596-2393;year=2013;volume=12;issue=2;spage=57;epage=61;aulast=Emerole>.
9. Saw SM, Gazzard G, Shi-Yen E, Chua WH. Myopia and associated pathological complications. *Ophthal Physio Opt.* 2005;25:381-391. <https://www.ncbi.nlm.nih.gov/pubmed/16101943>.
10. Shoji T, Sato H, Ishida M, Takeuchi M, Chihara E. Assessment of glaucomatous changes in subjects with high myopia using spectral domain optical coherence tomography. *Invest Ophthalmol Vis Sci.* 2011;52:1098-1102. <https://www.ncbi.nlm.nih.gov/pubmed/21051712>.
11. Akashi A, Kanamori A, Ueda K, Inoue Y, Yamada Y, Nakamura M. The ability of SD-OCT to differentiate early glaucoma with high myopia from highly myopic controls and non-highly myopic control. *Invest Ophthalmol Vis Sci.* 2015;56:6573-6580. <https://iovs.arvojournals.org/article.aspx?articleid=2464683>.
12. Holden B, Fricke T, Wilson D, et al. Global prevalence of myopia and high myopia and temporal trends from 2000 through 2050. *Am J Ophthalmol.* 2016;123:1036-1042. <https://www.ncbi.nlm.nih.gov/pubmed/26875007>.
13. Jonas JB, Xu L. Histological changes of high axial myopia. *Eye.* 2014;28:113-117. <https://www.ncbi.nlm.nih.gov/pmc/articles/PMC3930258>.
14. Beresford J, Crewther S, Kiely P, Crewther DP. Comparison of refractive state and circumferential morphology of retina, choroid and sclera in chick models of experimentally induced ametropia. *Optom Vis Sci.* 2002;78:40-49. <https://www.ncbi.nlm.nih.gov/pubmed/11233334>.
15. Grover S, Murthy R, Brar V, Chalam KV. Normative data for macular thickness by high-definition spectral-domain optical coherence tomography (Spectralis®). *Am J Ophthalmol.* 2009;148:266-271. <https://www.ncbi.nlm.nih.gov/pubmed/19427616>.
16. Kanai K, Abe T, Murayama K, Yoneya S. Retinal thickness and changes with age. *Nippon Ganka Gakkai Zasshi.* 2002;106:162-165. <https://www.ncbi.nlm.nih.gov/pubmed/11925953>.
17. Chan A, Duker JS, Ko TH, Fujimoto JG, Schuman JS. Normal macular thickness measurements in healthy eyes using Stratus optical coherence tomography. *Arch Ophthalmol.* 2006;124:193-198. <https://www.ncbi.nlm.nih.gov/pmc/articles/PMC1941772/>.



# Amiodarone-induced vortex keratopathy at a low maintenance dose

Deepti Mahajan, Anil Verma, Rajesh Sharma

Department of Ophthalmology, Rajendra Prasad Medical College, Tanda, India

## Abstract

Vortex keratopathy is a common side effect of amiodarone, which is a class III antiarrhythmic agent. We describe a 50-year-old man who developed vortex keratopathy with amiodarone 200 mg BD for atrial fibrillation since two years. The daily (400 mg/day) and cumulative dose (100 g) combined with the length of therapy is associated with the toxicity. Toxic effects may also be observed at lower maintenance doses, as observed in this patient. This case indicates that multi-organ toxicity due to amiodarone may develop even with short-term use and a low maintenance dose. Having been off the medication for two months, it is expected that the deposition pattern will diminish, as is the case for the vast majority of patients.

**Keywords:** amiodarone, keratopathy, vortex

Vortex keratopathy is a common side effect of amiodarone, which is a class III antiarrhythmic agent effective against all types of tachyarrhythmias. It is well known to cause toxicity affecting the lungs, thyroid gland, liver, eyes, skin and nerves. The most common ocular findings that have been reported due to amiodarone are corneal, lens opacities and optic neuropathy.<sup>1</sup>

We describe a 50-year-old man who was referred by the medicine department after he reported glare in his eyes for a few weeks. He was taking amiodarone 200 mg BD for atrial fibrillation since 2 years. His best-corrected visual acuity was 6/6 bilaterally. Slit-lamp examination of the anterior segment showed a whorl-like pattern of corneal epithelial deposits bilaterally, characterizing amiodarone-induced vortex keratopathy (also called cornea verticillata). Other ocular structures were normal (Fig. 1). Fundus examination revealed a normal fundus in the right eye and temporal pallor in the left eye (Fig. 2).

The ocular effect of amiodarone is vortex keratopathy creating a whorl-like pattern by producing lysosomal deposits in the basal epithelial layer.<sup>2,3</sup> The whorl-like pattern which was firstly described by Fleischer in 1910 is characterized as powdery, white, yellow or brown corneal opacities beneath the cornea apex. Two mechanisms describe the production of the pattern. The first is that

**Correspondence:** Dr. Deepti Mahajan, Arunodya, Cemetery Road, Sanjauli, Shimla, Himachal Pradesh, India 171006.

E-mail: [mahajandeepi22@gmail.com](mailto:mahajandeepi22@gmail.com)

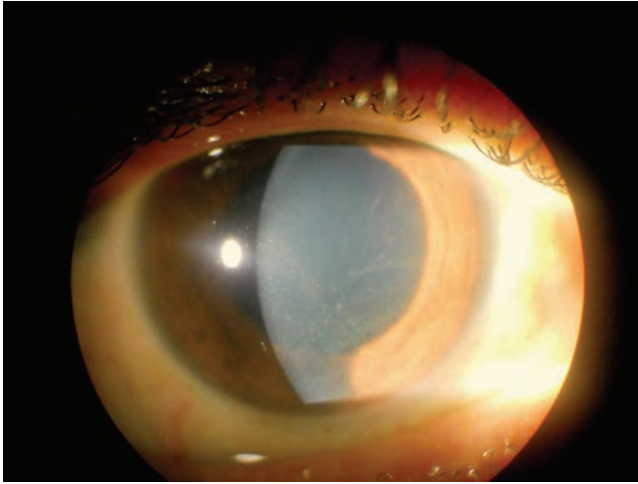


Fig. 1. Amiodarone deposits in the corneal epithelium.

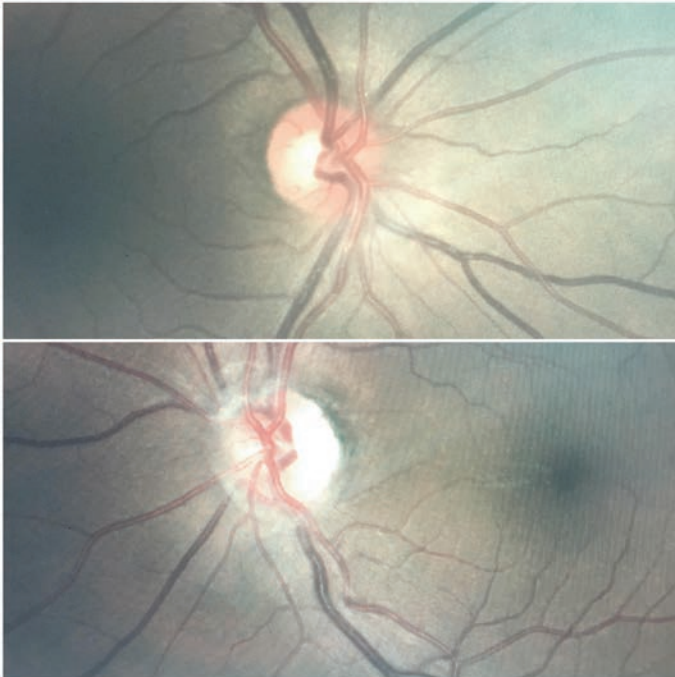


Fig. 2. Fundus photograph of the patient.

the predominant horizontal line across the lower two-thirds of the cornea corresponds to the line of lid closure and that the deposits result directly from the concentration of the drug in the tears.<sup>4</sup> Another theory is that the lines are a manifestation of the centripetal trajectory of migrating epithelial cells from a non-uniform distribution of stem cells at the limbus. The direction of movement is thought to follow a pattern similar to that of water flowing down a plug hole, with the point of the vortex in the midline at the junction of the lower and middle third of the cornea.<sup>5</sup>

The daily (400 mg/day) and cumulative dose (100 g) combined with the length of therapy is associated with the toxicity. Toxic effects may also be observed at lower maintenance doses, as observed in this patient.<sup>2</sup> This case indicates that multi-organ toxicity due to amiodarone may develop even with short-term use and a low maintenance dose. Laboratory studies including liver and thyroid functions should be checked every 6 months and ocular examination should be done regularly to detect ocular side effects to prevent irreversible ocular damages in patients taking amiodarone. Hence amiodarone should be used at lowest possible doses. Having been off the medication for two months, it is expected that the deposition pattern will diminish, as is the case for the vast majority of patients.

### Acknowledgement

I would like to thank the entire Ophthalmology Department which worked as a team for doing various procedures for the patients.

### References

1. Gittinger JW, Jr, Asdourian GK. Papillopathy caused by amiodarone. *Arch Ophthalmol.* 1987;105:349-351.
2. Hollander DA, Aldave AJ. Drug-induced corneal complications. *Curr Opin Ophthalmol.* 2004;15:541-548.
3. D'Amico DJ, Kenyon KR, Ruskin JN. Amiodarone keratopathy: drug-induced lipid storage disease. *Arch Ophthalmol.* 1981;99:257-261.
4. Flach AJ, Dolan BJ, Sudduth B, Weddell J. Amiodarone-induced lens opacities. *Arch Ophthalmol.* 1983;101:1554-1556.
5. Uçakhan OO, Kanpolat A, Yılmaz N, Ozkan M. Amiodarone keratopathy: an *in vivo* confocal microscopy study. *Eye Contact Lens.* 2005;31:148-157.

# Differences of tear film osmolarity between two time-points of the day in healthy subjects

Hugo Pena-Verdeal, Covadonga Vazquez-Sanchez, Jacobo Garcia-Queiruga, Carlos Garcia-Resua

Department of Applied Physics (Area of Optometry), Universidade de Santiago de Compostela, Santiago de Compostela, Spain

## Abstract

**Purpose:** Tear film hyperosmolarity is considered one of the core mechanisms of the dry eye along with the tear film stability. Many tear physiological variables oscillate during the day. This study was designed to assess the differences in tear film osmolarity between morning and afternoon in a group of healthy subjects.

**Material and methods:** A total of 25 healthy subjects who fulfilled the study's inclusion criteria were enrolled for the study. Tear osmolarity was measured using the TearLab™ system in two separated sessions, at 9.30 am and 6.30 pm. A paired t-test and a Bland–Altman test were used to assess the differences between sessions.

**Results:** Tear osmolarity (mean  $\pm$  SD) was  $309.96 \pm 9.00$  and  $296.48 \pm 12.98$  mOsm/l at 9.30 am and 6.30 pm, respectively, being significantly lower at 6.30 pm than at 9.30 am (mean difference  $\pm$  SD =  $13.48 \pm 8.69$  mOsm/l; paired t-test;  $p < 0.001$ ).

**Conclusions:** Tear film osmolarity does appear to have some influence by the time of day in healthy patients.

**Keywords:** dry eye disease, osmolarity diurnal variations, tear film osmolarity, TearLab

## Introduction

Dry eye disease (DED) has recently been redefined by the Dry Eye Workshop II (DEWS II) as a multifactorial disease of the ocular surface characterized by a loss of homeostasis of the tear film, and accompanied by ocular symptoms, in which tear film instability and hyperosmolarity, ocular surface inflammation and damage and neurosensory abnormalities play aetiological roles.<sup>1-4</sup> Similar to the original DEWS report in 2007,<sup>5-7</sup> the DEWS II report reaffirmed that tear film instability and increased tear osmolarity are key mechanisms in DED, regardless of the underlying aetiology.<sup>4,8</sup> The inclusion of “homeostasis” in the new definition emphasizes that DED is not caused by any single factor but rather a fine balance of many different systems working in concert. It has been proposed that on normal or healthy subjects the tear film osmolarity value is near to 300 mOsm/l, while reaches to values up to 325 to 340 mOsm/l or

**Correspondence:** Hugo Pena-Verdeal,  
E-mail: [hugo.pena.verdeal@usc.es](mailto:hugo.pena.verdeal@usc.es)

higher on abnormal or dry eye subjects.<sup>9-11</sup> Thus, osmolarity measurement has been proposed as the gold standard in the dry eye diagnosis, being an easy and useful way to capture in a single parameter the status of the tear film status.<sup>12</sup>

Many physiological tear film and ocular surface variables change along the day, such as the corneal sensitivity, the tear pH or the tear film volume in the meniscus.<sup>13-15</sup> The possibility of diurnal variations in tear film parameter should be considered by the clinician, since the time of day tear film measurements are made can influence or be critical for a right diagnosis. A hallmark of DED is an unstable tear film, which is associated with variability in objective measures of sign and symptoms on this disease.<sup>4,16,17</sup> While repeated measurements over a period of time have been shown to be low and stable in normal subjects, DED subjects showed relatively elevated and unstable readings.<sup>18-20</sup> Indeed, the variability of osmolarity should be considered as an indication of the loss of tear film homeostasis that occurs with DED,<sup>21</sup> being recommended as a feature that clinicians should specifically be looking at diagnosis.<sup>22</sup> The aim of this study was to assess differences of tear film osmolarity between two time-points of the day, morning and afternoon, in a group of young healthy subjects.

## Material and methods

### Sample

A total of 25 participants (10 men, 15 women, mean age  $21.5 \pm 2.72$  years), who fulfilled the study's inclusion established on a previous report,<sup>23</sup> were recruited from students and subjects attending the Optometry Clinic of the Optometry Faculty (USC, Spain). Subjects were excluded if they had a history of the conjunctival, scleral or corneal disease, prior eye surgery, glaucoma, diabetes mellitus, a thyroid disorder or wore contact lenses. Qualifying subjects were also administered a battery of dry eye tests (OSDI and McMonnies questionnaires, Schirmer test, phenol red test, tear meniscus height [TMH] and corneal staining) to rule out DED. Cut-off criteria were set at a score  $<13$  for OSDI,<sup>24</sup> a score  $<10$  for McMonnies,<sup>25</sup>  $>14.5$  mm for both the Schirmer I test without anaesthesia and phenol red test,<sup>26,27</sup> a corneal staining grade  $\leq 1$  on the Oxford Grading Scale<sup>28</sup> and a central TMH without fluorescein  $\geq 0.20$  mm.<sup>29,30</sup> Subjects were excluded if they failed to fulfill more than two of these six inclusion criteria.<sup>23</sup> No participant was under any type of medication or used artificial tears at the time of the study. The study protocol was adhered to the tenets of the Declaration of Helsinki and was approved by the Ethics Committee of the University of Santiago de Compostela.

**Experimental procedure**

Tear film osmolarity was measured using the TearLab™ (TearLab, San Diego, CA, USA).<sup>31-35</sup> During all protocols, the instrument and test cards used for both study parts were kept in the same humidity- and temperature-controlled room.<sup>19</sup> Quality control electronic check cards provided by the manufacturer was performed daily to verify the correct status of the system according to the given specifications (if reading was  $334 \pm 3$ , the pen was working correctly). In all procedures, the same test card lot number was used.

Participants were seated with the chin tilted upward and eyes directed towards the ceiling. The first eye to be measured was randomly selected. The instrument probe (housing the disposable microchip) was then placed on the lower tear meniscus until a beep is emitted indicating the tear sample has been collected. Measurements are directly made on the tear meniscus using the probe, which takes up the sample through capillary action. Only a 0.05- $\mu$ l tear sample is needed. The TearLab converts the electrical impedance of the sample into osmolarity (mOsm/l), which is displayed on the device screen. Device measurement range goes from 275 to 400 mOsm/l. Measurements were performed in two separate sessions, at 9.30 am and 6.30 pm.<sup>23</sup> Only the right eye was examined because of induced excess tearing in the second eye and to avoid overstating the precision of statistical estimates.<sup>36</sup> Throughout the study, laboratory conditions of temperature, light and humidity were kept constant (temperature 20-23°C, humidity 50-60%).

**Statistical analysis**

SPSS statistical software, v. 19.0 for Windows (SPSS Inc., Chicago, IL), was used for data analysis. Significance was set at a  $p \leq 0.05$  for all the analyses. Previous to analysis, the normal distribution of the data was checked using the Kolmogorov–Smirnov test; osmolarity data for both sessions data showed a normal distribution (both  $p \geq 0.153$ );<sup>37</sup> hence, parametric tests were used.

Bland–Altman procedures were used<sup>38</sup> to compare intra-day differences in osmolarity obtained in each patient’s eye on both sessions. Those differences

**Table 1. Descriptive statistics, differences (paired t-test) and 95% CI between measurements recorded in the two sessions**

Session	Mean $\pm$ SD	Mean difference $\pm$ SD	p	95% LoA	
				Minimum	Maximum
9.30 am	309.96 $\pm$ 9.00	13.48 $\pm$ 8.69	0.001	–3.55	+30.51
6.30 pm	296.48 $\pm$ 12.98				

All data expressed on mOsm/l.  $n = 25$

95% CI: 95% confidence interval; 95% LoA: 95% limits of agreement; SD: standard deviation

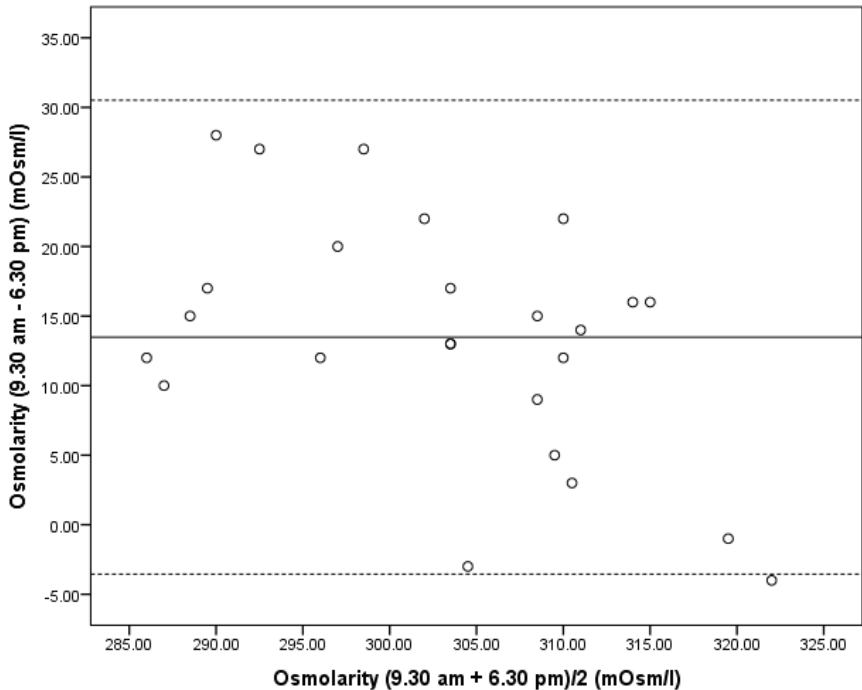


Fig. 1. Mean versus differences between the values obtained in the two sessions (9.30 am vs. 6.30 pm). The solid line indicates mean difference and dashed lines indicate the 95% LoA (Mean difference  $\pm$  1.96  $\times$  SD differences). SD = standard deviation. n = 25.

between both osmolarity measurement sessions were assessed using a paired *t*-test for related samples. Also, 95% limits of agreements (LoA) were calculated (mean difference  $\pm$  1.96  $\times$  SD differences). In addition, a Bland–Altman plot representing averages versus differences was generated.

## Results

Tear osmolarity (mean  $\pm$  SD) was 309.96  $\pm$  9.00 mOsm/l (values from 292 to 323) and 296.48  $\pm$  12.98 mOsm/l (values from 276 to 324) at 9.30 am and 6.30 pm, respectively (Table 1). Results were significantly lower at 6.30 pm than at 9.30 am (paired *t*-test; *p* < 0.001), indicating better tear film quality in the afternoon than in the morning on healthy subjects (Table 1).

Figure 1 provides a Bland–Altman plot of means against the differences between the osmolarity values obtained in each time-point. As could be seen, dots were spread and there was a wide bias according to the 95% confidence



interval, showing high differences between the osmolarity values obtained in both morning and afternoon sessions.

## Discussion

Diurnal variations in tear film variables have not been clearly established yet. The present findings indicate that tear film osmolarity does appear to be influenced by the time of day in healthy subjects: osmolarity readings indicated an improvement (lower osmolarity) in the afternoon (Fig. 1). As in previous reports,<sup>39,40</sup> two time-points were used (9.30 am-6.30 pm), which represent the start and the end of a normal work timetable in Spain.<sup>40</sup> In addition, it is important to note that the inclusion criterion for the present study was strict in order to use only really healthy patients.

Tear osmolarity is considered a global indicator of the DED.<sup>9-11,41,42</sup> Elevated tear osmolarity induces apoptosis, serve as a pro-inflammatory stress and reduce the ability of mucin-like molecules to lubricate the ocular surface, which can permanently damage the ocular surface.<sup>41,43,44</sup> It was reported that osmolarity is the single best marker of disease severity as an objective numerical measure for diagnosing, grading severity and managing treatment of DED.<sup>12,45</sup> However, to date, there is still controversy over the best cut-off for osmolarity between normal and DED subjects. Most studies have examined the threshold for DED diagnosis, and were recommended values that vary from 308 to 320 mOsm/l.<sup>9-11,45</sup> Using a cut-off of 312 mOsm/l, tear osmolarity have a 72.8% sensitivity and 92.0% specificity in separating DED from normal eyes.<sup>9,45,46</sup> While in the present study, a battery of specific dry eye diagnostic test was made as an inclusion criteria (OSDI, McMonnies, Schirmer, phenol red test, TMH and corneal staining).<sup>24-30</sup> It is important to note that the mean osmolarity in the first session was near to this cut-off criteria value (mean  $\pm$  SD = 309.96  $\pm$  9.00 mOsm/l). On the other hand, normal eyes tend to vary by  $\pm$ 7 mOsm/l, whereas DED can vary  $\geq$ 11 mOsm/l between eyes or and tests but generally a difference of  $\geq$ 8 mOsm/l between eyes indicates tear film instability.<sup>4,9,16</sup> In the present study, a mean difference  $\pm$  SD between morning and afternoon of 13.48  $\pm$  8.69 was found, higher than those diagnostic values. One reported reason for variability in tear osmolarity threshold values is tear film instability, a hallmark characteristic of the disease.<sup>19,16</sup> Indeed, the variability of osmolarity or increasing variation with increasing value is a statistical characteristic called heteroscedasticity and might be considered as a clinical indication of the loss of tear film homeostasis that occurs with dry eye.<sup>4,16,19,21,45</sup> It has been reported that consecutive measurements of the tear film osmolarity in short periods of time showed a lower variability, contrary to dry eye patients.<sup>18,20</sup> Tears of individuals with DED demonstrated increasing variation due to a combination of chaotic or incomplete mixing between blinks and spatially variable tear

film break-up, leading to a stochastically increased evaporation rate.<sup>4,19</sup>

In addition to the cut-off limitation or differences between measurements, diurnal variations of that parameter should be assessed and established in order to minimize possible diagnosis misleading. Previous studies have also used the TearLab osmometer to assess the osmolarity diurnal variation in healthy patients.<sup>31-35</sup> Some of those studies also reported no variations on tear film osmolarity along the day,<sup>31,34,35</sup> while other shows variations in some points of the day.<sup>33</sup> The same results were found in studies where osmometers based on freezing point depression were used, where variation<sup>47,48</sup> and no variation<sup>40,49</sup> was found between osmolarity measured at some different points of the day in healthy patients. Despite the little variations found in some measurement points on these studies, all of them concluded that osmolarity has a near to stable profile along the day in healthy subjects. In addition, although there is some controversy over diurnal tear film osmolarity, this variable has been observed to differ between healthy individuals and those pathological.<sup>33,35</sup> Also, as eye closure during sleep generates a hypoosmotic environment due to the reduction in tear film evaporation, production, and drainage, it has been hypothesized by previous authors that osmolarity is in its lower values upon eyelid opening.<sup>37</sup> Then, in the afternoon as the eye responds to the relative variations in the surrounding conditions that could enhance the evaporation process,<sup>51</sup> osmolarity rises to normal values.<sup>31-35</sup> Patients have reported that symptoms worsened over the day within 2 hours of getting up in the morning and at the end of the day, suggesting an environment- or task-related aetiology for dry eye symptoms.<sup>52</sup>

These differences between studies, both the daily variation and the relationship between healthy and pathological subjects, may reach from different error sources. The first one is the different criteria to choose the session day-time, with a wide range of day points from 6.00 am<sup>49</sup> to 7.00 pm.<sup>40</sup> The second could be the different devices or principles used in the different studies, while some studies have been reported a poor correlation between different principle osmometers.<sup>53,54</sup> Finally, the last source of error may be the different number of subjects in the studied groups (very small in some cases),<sup>55</sup> or the variations between age, sex or symptomatology. A larger study population, both healthy and pathological, may be required to detect a true daily osmolarity pattern and the differences between the tear osmolarity of dry eye subjects and that of healthy individuals.

In summary, while the osmolarity general profile follows a near to stable pattern along the day, tear film osmolarity does appear to be influenced by the time of day in healthy patients.

## Acknowledgements

This study was funded by the Spanish Ministry of Science and Education and the Institute of Health Carlos III (ISCIII) through research project PI10/01098.

## References

1. Bron AJ, de Paiva CS, Chauhan SK, et al. TFOS DEWS II pathophysiology report. *Ocul Surf.* 2017;15:438-510.
2. Craig JP, Nichols KK, Akpek EK, et al. TFOS DEWS II definition and classification report. *Ocul Surf.* 2017;15:276-283.
3. Stapleton F, Alves M, Bunya VY, et al. TFOS DEWS II epidemiology report. *Ocul Surf.* 2017;15:334-365.
4. Wolffsohn JS, Arita R, Chalmers R, et al. TFOS DEWS II diagnostic methodology report. *Ocul Surf.* 2017;15:539-574.
5. The definition and classification of dry eye disease: report of the Definition and Classification Subcommittee of the International Dry Eye WorkShop. *Ocul Surf.* 2007;5:75-92.
6. Methodologies to diagnose and monitor dry eye disease: report of the Diagnostic Methodology Subcommittee of the International Dry Eye WorkShop. *Ocul Surf.* 2007;5:108-152.
7. Research in dry eye: report of the Research Subcommittee of the International Dry Eye WorkShop. *Ocul Surf.* 2007;5:179-193.
8. Nelson JD, Craig JP, Akpek EK, et al. TFOS DEWS II introduction. *Ocul Surf.* 2017;15:269-275.
9. Jacobi C, Jacobi A, Kruse FE, Cursiefen C. Tear film osmolarity measurements in dry eye disease using electrical impedance technology. *Cornea.* 2011;30:1289-1292.
10. Messmer EM, Bulgen M, Kampik A. Hyperosmolarity of the tear film in dry eye syndrome. *Dev Ophthalmol.* 2010;45:129-138.
11. Tomlinson A, Khanal S, Ramaesh K, Diaper C, McFadyen A. Tear film osmolarity: determination of a referent for dry eye diagnosis. *Invest Ophthalmol Vis Sci.* 2006;47:4309-4315.
12. Muselier-Mathieu A, Bron AM, Mathieu B, et al. Ocular surface assessment in soft contact lens wearers; the contribution of tear osmolarity among other tests. *Acta Ophthalmol.* 2014;92:364-369.
13. Carney LG, Hill RM. Human tear pH. Diurnal variations. *Arch Ophthalmol.* 1976;94:821-824.
14. du Toit R, Vega JA, Fonn D, Simpson T. Diurnal variation of corneal sensitivity and thickness. *Cornea.* 2003;22:205-209.
15. Shen M, Wang J, Tao A, et al. Diurnal variation of upper and lower tear menisci. *Am J Ophthalmol.* 2008;145:801-806.
16. Lemp MA, Bron AJ, Baudouin C, et al. Tear osmolarity in the diagnosis and management of dry eye disease. *Am J Ophthalmol.* 2011;151:792-798 e791.
17. Urzua CA, Vasquez DH, Huidobro A, Hernandez H, Alfaro J. Randomized double-blind clinical trial of autologous serum versus artificial tears in dry eye syndrome. *Curr Eye Res.* 2012;37:684-688.
18. Gokhale M, Stahl U, Jalbert I. In situ osmometry: validation and effect of sample collection technique. *Optom Vis Sci.* 2013;90:359-365.
19. Keech A, Senchyna M, Jones L. Impact of time between collection and collection method on human tear fluid osmolarity. *Curr Eye Res.* 2013;38:428-436.
20. Nolfi J, Caffery B. Randomized comparison of in vivo performance of two point-of-care tear film osmometers. *Clin Ophthalmol.* 2017;11:945-950.
21. Sullivan B. Challenges in using signs and symptoms to evaluate new biomarkers of dry eye disease. *Ocul Surf.* 2014;12:2-9.
22. Sullivan BD, Whitmer D, Nichols KK, et al. An objective approach to dry eye disease severity. *Invest Ophthalmol Vis Sci.* 2010;51:6125-6130.

23. Pena-Verdeal H, Garcia-Resua C, Ramos L, Yebra-Pimentel E, Giraldez MJ. Diurnal variations in tear film break-up time determined in healthy subjects by software-assisted interpretation of tear film video recordings. *Clin Exp Optom*. 2016;99:142-148.
24. Miller KL, Walt JG, Mink DR, et al. Minimal clinically important difference for the ocular surface disease index. *Arch Ophthalmol*. 2010;128:94-101.
25. Glasson MJ, Stapleton F, Keay L, Sweeney D, Willcox MD. Differences in clinical parameters and tear film of tolerant and intolerant contact lens wearers. *Invest Ophthalmol Vis Sci*. 2003;44:5116-5124.
26. Nichols KK, Mitchell GL, Zadnik K. The repeatability of clinical measurements of dry eye. *Cornea*. 2004;23:272-285.
27. Nichols KK, Nichols JJ, Mitchell GL. The lack of association between signs and symptoms in patients with dry eye disease. *Cornea*. 2004;23:762-770.
28. Bron AJ, Evans VE, Smith JA. Grading of corneal and conjunctival staining in the context of other dry eye tests. *Cornea*. 2003;22:640-650.
29. Garcia-Resua C, Santodomingo-Rubido J, Lira M, Giraldez MJ, Vilar EY. Clinical assessment of the lower tear meniscus height. *Ophthalmic Physiol Opt*. 2009;29:487-496.
30. Johnson ME, Murphy PJ. The agreement and repeatability of tear meniscus height measurement methods. *Optom Vis Sci*. 2005;82:1030-1037.
31. Aslan Bayhan S, Bayhan HA, Muhafiz E, Bekdemir S, Gurdal C. Effects of osmoprotective eye drops on tear osmolarity in contact lens wearers. *Can J Ophthalmol*. 2015;50:283-289.
32. Dimit R, Miller W, Leach N, Bergmanson J. Comparison of morning and afternoon osmolarity in silicone hydrogel wearers and non-contact lens wearers. *Invest Ophthalmol Vis Sci*. 2011;52:6538.
33. Li M, Du C, Zhu D, Shen M, Cui L, Wang J. Daytime variations of tear osmolarity and tear meniscus volume. *Eye Contact Lens*. 2012;38:282-287.
34. Oncel BA, Pinarci E, Akova YA. Diurnal variation of the tear osmolarity in normal subjects measured by a new microchip system. *Eur J Ophthalmol*. 2012;22 Suppl 7:S1-S4.
35. Yiğit U, Evcimen Y, Kırık F, Ağaçhan A. Daytime variations of tear osmolarity measurement in dry eyes patients (article in turkish). *Turk J Ophthalmol* 2013;43:437-441.
36. Armstrong RA, Davies LN, Dunne MC, Gilmartin B. Statistical guidelines for clinical studies of human vision. *Ophthalmic Physiol Opt*. 2011;31:123-136.
37. Bland JM, Altman DG. Statistical methods for assessing agreement between two methods of clinical measurement. *Lancet*. 1986;1:307-310.
38. Farris RL, Stuchell RN, Mandel ID. Tear osmolarity variation in the dry eye. *Trans Am Ophthalmol Soc*. 1986;84:250-268.
39. Garcia N, Teson M, Enriquez-de-Salamanca A, et al. Basal values, intra-day and inter-day variations in tear film osmolarity and tear fluorescein clearance. *Curr Eye Res*. 2014;39:673-679.
40. Liu H, Begley C, Chen M, et al. A link between tear instability and hyperosmolarity in dry eye. *Invest Ophthalmol Vis Sci*. 2009;50:3671-3679.
41. Stahl U, Willcox M, Stapleton F. Osmolality and tear film dynamics. *Clin Exp Optom*. 2012;95:3-11.
42. Luo L, Li DQ, Pflugfelder SC. Hyperosmolarity-induced apoptosis in human corneal epithelial cells is mediated by cytochrome c and MAPK pathways. *Cornea*. 2007;26:452-460.
43. Sullivan BD, Crews LA, Messmer EM, et al. Correlations between commonly used objective signs and symptoms for the diagnosis of dry eye disease: clinical implications. *Acta Ophthalmol*. 2014;92:161-166.
44. Potvin R, Makari S, Rapuano CJ. Tear film osmolarity and dry eye disease: a review of the literature. *Clin Ophthalmol*. 2015;9:2039-2047.
45. Ray WA, O'Day DM. Statistical analysis of multi-eye data in ophthalmic research. *Invest Ophthalmol Vis Sci*. 1985;26:1186-1188.

46. Versura P, Profazio V, Campos EC. Performance of tear osmolality compared to previous diagnostic tests for dry eye diseases. *Curr Eye Res.* 2010;35:553-564.
47. Benjamin WJ, Hill RM. Human tears: osmotic characteristics. *Invest Ophthalmol Vis Sci.* 1983;24:1624-1626.
48. Dalton K, Jones L. The performance of a novel nanolitre osmometer to investigate diurnal tear film osmolality. *Optom Vis Sci* 2005; 82. E-abstract 0557070.
49. Lee YB, Koh JW, Hyon JY, Wee WR, Kim JJ, Shin YJ. Sleep deprivation reduces tear secretion and impairs the tear film. *Invest Ophthalmol Vis Sci.* 2014;55:3525-3531.
50. Niimi J, Tan B, Chang J, et al. Diurnal pattern of tear osmolality and its relationship to corneal thickness and deswelling. *Cornea.* 2013;32:1305-1310.
51. Himebaugh NL, Begley CG, Bradley A, Wilkinson JA. Blinking and tear break-up during four visual tasks. *Optom Vis Sci.* 2009;86: E106-E114.
52. Torricelli AA, Novaes P, Matsuda M, et al. Correlation between signs and symptoms of ocular surface dysfunction and tear osmolality with ambient levels of air pollution in a large metropolitan area. *Cornea.* 2013;32:e11-e15.
53. Garcia N, Melvi G, Pinto-Fraga J, Calonge M, Maldonado MJ, Gonzalez-Garcia MJ. Lack of agreement among electrical impedance and freezing-point osmometers. *Optom Vis Sci.* 2016;93:482-487.
54. Pena-Verdeal H, Garcia-Resua C, Minones M, Giraldez MJ, Yebra-Pimentel E. Accuracy of a freezing point depression technique osmometer. *Optom Vis Sci.* 2015;92:e273-e283.
55. Benjamin WJ, Hill RM. Tear osmotic differences across the ocular surface. *Graefes Arch Clin Exp Ophthalmol.* 1986;224:583-586.

# Ocular surface squamous neoplasia: a case series

Gholamhossein Yaghoobi<sup>1</sup>, Abbas Hosseini Rad<sup>1</sup>,  
Saeed Reza Heydari<sup>2</sup>, Malihe Nikandish<sup>1</sup>

<sup>1</sup>Ophthalmology Department, Valiasr Hospital, Birjand University of Medical Sciences, Birjand, Iran; <sup>2</sup>Mashhad University of Medical Science, Mashhad, Iran

## Abstract

**Purpose:** This study was conducted to show diverse clinical presentation of ocular surface squamous neoplasia with a rare presentation of caruncle squamous cell carcinoma (SCC).

**Methods:** All cases that had suspicious ocular lesion were included in the treatment study. A detailed history including demographic data was obtained. Clinical features regarding the type of lesion, location, and the involvement of cornea were evaluated. For all patients, excisional biopsy following "Shield's no-touch technique" with 3 to 4 mm margins of uninvolved tissue and cryotherapy at excisional margins was done. All specimens were sent for a histopathological evaluation. Topical chemotherapy (mitomycin C, 0.02%) was used as an adjunctive therapy following surgical excision for large and diffuse ocular surface tumors. All patients were subjected to long-term regular follow-ups.

**Results:** Twenty-six patients (18 men and 8 women) with a mean age of 54.2 years were enrolled in this study. The results showed that the most common localization was bulbar conjunctiva (92%). Nodular lesions (46.5%) and SCC (57.5%) were the most common clinical and histopathological features, respectively. We observed one rare case of primary SCC of the left caruncle in a 68-year-old man who had an asymptomatic medial canthal mass. Recurrence was found in two patients with SCC, one of them having an orbital extension.

**Conclusion:** The early suspicion of ocular surface neoplasia will be accomplished with a simple excision in most cases, leading to a favorable outcome except in severe progressive cases.

**Keywords:** caruncle, ocular surface squamous neoplasia, squamous cell carcinoma

## Introduction

Ocular surface squamous neoplasia (OSSN) is a spectrum of pathology ranging from noninvasive intraepithelial dysplasia of the conjunctiva and cornea to invasive squamous cell carcinoma (SCC).<sup>1</sup> The limbal stem cells are the origin of OSSN, which normally arise in the interpalpebral region and involved the bulbar conjunctiva, the cornea, or both structures.<sup>2</sup>

**Correspondence:** Malihe Nikandish, Valiasr Hospital, Ayatollah Ghaffari Ave., Birjand, Southern Khorasan Province, Iran.

E-mail: [nikandishm@bums.ac.ir](mailto:nikandishm@bums.ac.ir); [malihenikandish@yahoo.com](mailto:malihenikandish@yahoo.com)

There are no consistent clinical criteria for distinguishing intraepithelial dysplasia from invasive SCC. The presence of feeder vessels, intrinsic vascularity, and a nodular lesion raise suspicion of invasive SCC.<sup>3</sup>

Male gender, temporal and superior locations, lack of corneal involvement, and papillomatous and nodular appearance were associated with higher-grade OSSN lesions in a study in the United States.<sup>4</sup>

While histopathology is the gold standard in the diagnosis of OSSN, high-resolution optical coherence tomography can be used to noninvasively detect the presence of OSSN in patients with coexisting ocular conditions.<sup>5</sup>

The standard modality for treatment of OSSN ranges from wide surgical excisions to “no-touch” technique and adjunctive cryotherapy.<sup>6</sup>

OSSN has a good prognosis; with the modern techniques, the recurrence rate is about 5% and regional metastasis is of 2%.<sup>6</sup>

This study describes diverse clinical presentation and treatment response in a series of patients attended our eye clinic.

## Methods

All cases that had suspicious ocular surface lesions participated in the treatment study after submitting their informed consent. A detailed history including demographic data of age, sex, occupation, and HIV status of all the patients was obtained. Clinical features including the type of lesion, location, and the involvement of cornea were evaluated. For all patients, excisional biopsy following “Shield’s no-touch technique” with 3 to 4 mm margins of uninvolved tissue and cryotherapy at excisional margins was done. Affected corneal epithelium was completely removed using absolute alcohol, with care taken to avoid the Bowman’s layer. All specimens were sent for histopathological evaluation. Topical chemotherapy was used as an adjunctive therapy following surgical excision for large and diffuse ocular surface tumors. Topical chemotherapy regimen included mitomycin C (0.02%) four times daily with cycles of two weeks on, two weeks off, and maximum two cycles until clinical resolution occurred. We prevented punctal stenosis and reduced systemic absorption by punctal plug placement. All patients had long-term regular follow-ups, and complete ocular surface examination and palpation of the regional lymph node were done at each visit.

## Results

Twenty-six patients (18 men and 8 women) with a mean age of 54.2 years (range: 31-74 years) participated in this study. Table 1 shows the distribution of the lesions according to sex and age. The mean follow-up period was 20 months. All patients were negative for HIV. At presentation, the tumor involved the limbus and cornea in 15 eyes, forniceal conjunctiva in one eye, and no tarsal conjunctiva



Table 1. Distribution of OSSN regarding the patients' age and sex.

Age (years)	Men	Women	Recurrence
<30	0	0	0
31-40	1	0	0
41-50	4	1	0
51-60	5	4	0
>60	8	3	2
<b>Total</b>	<b>18 (69%)</b>	<b>8 (31%)</b>	<b>2</b>

involvement. One patient had both temporal and nasal involvement in the right eye. Seven patients (27%) presented with pterygium-like lesions, 12 (46.5%) with nodular lesions (Fig. 1), and six (23.5%) with gelatinous pattern. The pattern of distribution of OSSN lesions within the interpalpebral fissure of the ocular surface in this study was most commonly on the nasal side (57.5%), followed in the order by temporal (27%), superior (7.5%), inferior (4%), and caruncle (4%), respectively. A total of 83.7% of subjects had both corneal and conjunctival involvement, while 16.3% had conjunctival involvement only. A total of 38.4% of subjects had dysplasia and 57.6% had SCC (Fig. 2). Localization and distribution pattern of the lesions, as well as clinical and histopathological features, are shown in Table 2.

Five patients received adjuvant topical chemotherapy following surgical excision because of the large size of lesions (Fig. 3). Recurrence was found in two patients with SCC, one of them having an orbital extension. This patient refused further intervention and died several months later due to this malignant disease.

We had one rare case of ocular surface neoplasia, a primary SCC of the left caruncle in a 68-year-old man (Fig. 4) who presented with asymptomatic medial canthal mass and underwent wide-margin surgical excision and adjuvant topical chemotherapy.

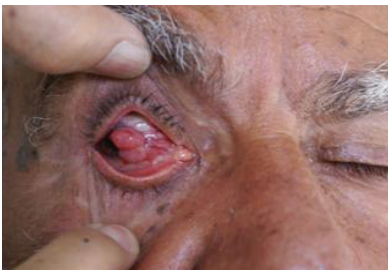

Fig. 1. Nodular OSSN.

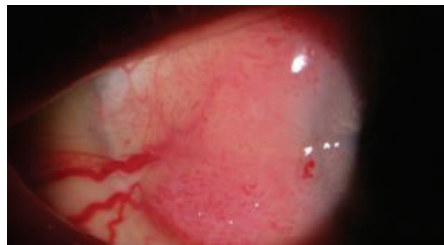

Fig. 2. Limbal SCC with prominent intrinsic vascularity and feeding vessel.

Table 2. Distribution of OSSN regarding the localization, pattern of distribution, and clinical and histopathological features of the lesions

	Number (total = 26)
<b>Localization</b>	
OD/OS	11/15
Bulbar	24
Fornix	1
Caruncle	1
Limbal involvement	15
<b>Clinical features</b>	
Nodular	12
Pterygium like	7
Gelatinous	6
Caruncle mass	1
<b>Pattern of distribution</b>	
Nasal	15
Temporal	7
Superior	2
Inferior	1
<b>Histopathological features</b>	
Cornea/conjunctival intraepithelial neoplasia	10
SCC	15
Caruncle carcinoma	1

## Discussion

OSSN typically arises adjacent to the limbus, over a preexisting pinguecula; that is, over an area of solar elastosis.

The purpose of the present retrospective case series is to show diverse clinical presentation of OSSN with a rare presentation of caruncle SCC.

The age and sex distributions of OSSN patients in this study were consistent with those of prior studies;<sup>6</sup> a majority of cases were presented during the fifth to seventh decades with a mean age of 54.2 years and with marked male predominance (69%). Male predominance is justified by the climatic and occupational issues of patients involving outdoor work and more ultraviolet light exposure.

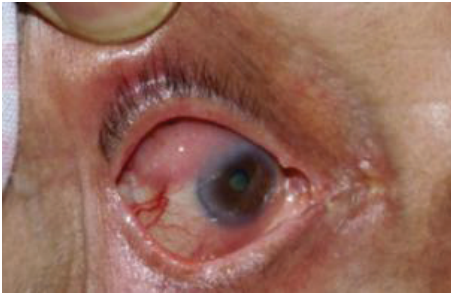


Fig. 3. Diffuse and large OSSN.

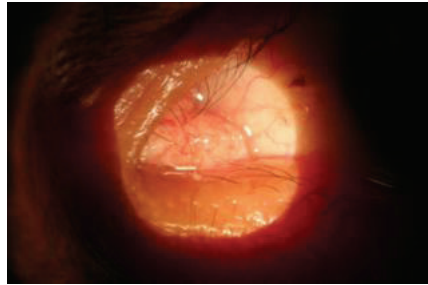


Fig. 4. Caruncle carcinoma presented with asymptomatic medial canthal mass.

Clinically, OSSN has a high presentation rate with different growth patterns. In this regard, our results are consistent with other studies,<sup>3</sup> which reported the most common morphological growth pattern to be nodular (Fig. 1).

A significantly higher number of SCC in bulbar conjunctiva has been reported in the nasal part compared with the temporal part, which is in line with the results of a previous study.<sup>7</sup>

We reported a rare case of primary squamous carcinoma of caruncle (Fig. 4), which was resected completely followed by the topical chemotherapy and showed total cure with no recurrence during a 20-month follow-up.

Because of the inherent difficulty in clearly differentiating dysplasia, carcinoma in situ, and SCC based solely on clinical features, clinicians often tend to use the generic diagnosis of OSSN.<sup>8</sup>

Shields *et al.* identified that the greatest relative risk for SCC versus cervical intraepithelial neoplasia included a diffuse configuration, brown pigmentation, >10 mm median basal diameter, and >1 mm thickness.<sup>8,9</sup>

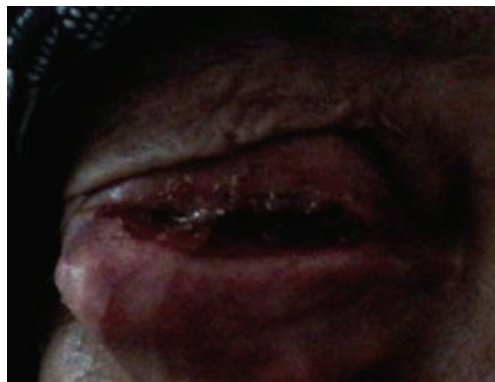

Fig. 5. Recurrent OSSN with orbital extension.

In a study conducted to evaluate the recurrence rate of OSSN after excision and cryotherapy, Li *et al.* showed a recurrence rate of 7.1%.<sup>10</sup>

In our study, 24 patients were disease free at a mean follow-up of 20 months and the recurrence rate was 7.5%.

We had an orbital extension in a patient who refused further intervention after recurrence (Fig. 5). In a study by Ali *et al.*, the most common malignancy leading to an orbital extension was an extensive OSSN.<sup>11</sup>

This study had a number of limitations including a short-term follow-up and a limited number of patients.

## Conclusion

In conclusion, although OSSN has numerous clinical features, its most common presentation is a nodular type of lesion. OSSN also can be presented as a pterygium. The early suspicion of ocular surface neoplasia will be accomplished with simple excision in the most cases even in caruncle and favorable outcome except in advance case with conflict consequence.

## References

1. Lee GA, Hirst LW. Ocular surface squamous neoplasia. *Surv Ophthalmol.* 1995;39(6):429-450.
2. Mitchell T, Carol LK. Modern management of ocular surface squamous neoplasia. *Expert Rev Ophthalmol.* 2013;8(3):287-295.
3. Dandala PP, Malladi P, Kavitha. Ocular Surface Squamous Neoplasia (OSSN): a retrospective study. *J Clin Diagn Res.* 2015;9:NC10-NC13.
4. Kao AA, Galor A, Karp CL, Abdelaziz A, Feuer WJ, Dubovy SR. Clinicopathologic correlation of ocular surface squamous neoplasms at Bascom Palmer Eye Institute: 2001 to 2010. *Ophthalmology.* 2012;119(9):1773-1776.
5. Atallah M, Joag M, Galor A, et al. Role of high-resolution optical coherence tomography in diagnosing ocular surface squamous neoplasia with coexisting ocular surface diseases. *Ocul Surf.* 2017 Oct;15(4):688-695.
6. Meel R, Dhiman R, Vanathi M, Pushker N, Tandon R, Devi S. Clinicodemographic profile and treatment outcome in patients of ocular surface squamous neoplasia. *Indian J Ophthalmol.* 2017;65:936-941.
7. Tanabe M, Yoshikawa H, Onishi Y, Kohno R, Ishibashi T. Ocular surface squamous neoplasia: analysis of 34 cases. *Nippon Ganka Gakkai Zasshi.* 2014 May;118(5):425-432.
8. Honavar SG. Ocular surface squamous neoplasia: are we calling a spade a spade? *Indian J Ophthalmol.* 2017;65:907-909
9. Shields CL, Alset AE, Boal NS, et al. Conjunctival tumors in 5002 cases. Comparative analysis of benign versus malignant counterparts. The 2016 James D. Allen Lecture. *Am J Ophthalmol.* 2017;173:106-133.
10. Li AS, Shih CY, Rosen L, Steiner A, Milman T, Udell IJ. Recurrence of Ocular Surface Squamous Neoplasia treated with excisional biopsy and cryotherapy. *Am J Ophthalmol.* 2015 Aug;160(2):213-219.
11. Ali MJ, Pujari A, Dave TV, Kaliki S, Naik MN. Clinicopathological profile of orbital exenteration: 14 years of experience from a tertiary eye care center in South India. *Int Ophthalmol.* 2016 Apr;36(2):253-258.

# The repair of canalicular lacerations with an annular silicone tube and round-tipped pigtail probe

Fatih Mehmet Adibelli<sup>1</sup>, Sevim Söker Çakmak<sup>1,2</sup>

<sup>1</sup>Department of Ophthalmology, School of Medicine, Harran University, Sanliurfa, Turkey; <sup>2</sup>Department of Ophthalmology, Medical Park Hospital, Bahçelievler, Istanbul, Turkey

## Abstract

**Purpose:** To analyze the outcomes of surgical repair of canalicular lacerations with a round-tipped pigtail probe and silicone tube implantation.

**Methods:** A retrospective review was conducted of the case records of 64 patients who presented to the Ophthalmology Department of Harran University between 2010 and 2015 and underwent surgical repair of canalicular lacerations. Each patient's age, gender, nationality, mechanism of injury, injured canaliculi, and follow-up time were evaluated. In addition to the anatomical and functional results, complications were also analyzed.

**Results:** A total of 64 patients, 51 (79.7%) males and 13 (20.3%) females, with a mean age at presentation of 14.6 years (range: 1-69 years) were enrolled. Forty-six patients were aged <15 years (71.9%). Forty-two patients (65.6%) had lower canalicular lacerations, and 19 patients had isolated upper canalicular lacerations (29.7%). At the final follow-up (mean: 33.7 months), anatomical success was observed in all patients.

**Conclusion:** Silicone tube implantation using a round-tipped pigtail probe is an effective method that facilitates anatomical and functional success in cases of canalicular laceration.

**Keywords:** canalicular laceration, lacrimal canalicular surgery, ocular trauma, round-tipped pigtail probe

## Introduction

Canalicular laceration is the most commonly observed form of injury in the lacrimal system and is seen in 36% of eyelid injuries.<sup>1</sup> Although the eye trauma resulting from not repairing the obstruction and the associated epiphora can be seen at any age, it has been reported more often in the inferior canaliculus among those patients in the pediatric age group.<sup>2,3</sup> The basic surgical principle of canalicular lacerations is based on providing the opportunity for the mucosa to recover by drawing the torn eyelid tissues together.<sup>4</sup> Various methods have been

**Correspondence:** Fatih Mehmet Adibelli, Department of Ophthalmology, Harran University School of Medicine, Osmanbey Yerleskesi 63290, Sanliurfa, Turkey.  
E-mail: [fadibelli@gmail.com](mailto:fadibelli@gmail.com)

described for the repair of canalicular lacerations, which can be implemented with the assistance of the Quickert-Dryden probe, the Crawford stent, the Monoka stent, and a pigtail probe.<sup>5-7</sup> The pigtail probe, which was first introduced by Worst, was later modified.<sup>8</sup> Some authors suggest that the pigtail probe should not be used for repair because of the high risk of damage to the undamaged portion of the canalicular system.<sup>9,10</sup> Complications may be seen in all the techniques used to repair canalicular laceration.<sup>11</sup> Jordan *et al.* reported that to use a round-tipped pigtail probe is safe for canalicular laceration repair.<sup>12</sup> Due to its practical efficiency, it is currently used as a preferred surgical method for repairing canalicular lacerations.<sup>12-14</sup>

The aim of this study was to present the epidemiology of canalicular lacerations and the results of surgical repair with a round-tipped pigtail probe in cases that presented to the Ophthalmology Department of Harran University Hospital in the south eastern region of Turkey.

## Material and methods

A retrospective evaluation was conducted on the records of 64 patients with canalicular lacerations following trauma between 2010 and 2015. Approval for the study was granted by the Clinical Research Ethics Committee of Harran University. The study included 64 eyes of 64 patients, where canalicular repair was done with the assistance of a round-end pigtail probe. A record was made of each patient's age, gender, the agent causing the injury, the affected eye, the affected canaliculus, the time to surgery, and other findings accompanying the canalicular injury. Patients with common canalicular injuries and those needing external dacryocystorhinostomy were excluded from the study.

In all patients, annular intubation was done with a silicone tube (FCI Ophthalmics, Marshfield Hills, MA, USA) using a round-end pigtail probe under general anesthesia (Fig. 1). For 15 days postoperatively, tobramycin 0.3% eye drops were applied four times per day. Postoperative follow-up examinations were performed with fluorescein tests on patients aged <10 years and with lacrimal lavage in those aged >10 years. Follow-up examinations were made at one week and then at one, three, six, and 12 months postoperatively. The silicone tube was left in place for 12 months. Anatomic success was confirmed in cases where the canaliculus was open in tear duct irrigation, and anatomic and functional success consisted of no pooling in the fluorescein disappearing test and no tearing the eye.

## Surgical method

All the cases were carefully examined once again under general anesthesia. All surgeries were performed by the same surgeon (SC). After expansion of the punctum with a dilator, the damaged canaliculus was reached by passing the

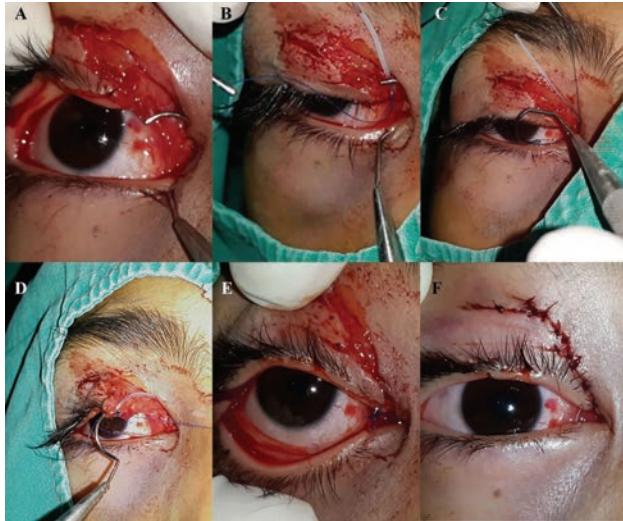

**Fig. 1. A round-tipped pigtail probe.**

round-tipped pigtail probe from the punctum of the healthy canaliculus (Fig. 2A). A 6/0 prolene suture was passed from the hole at the end of the round-tipped pigtail probe into the spot where the silicone tube had been previously placed (Fig. 2B). When the round-tipped pigtail probe was drawn back inside the canaliculus, the silicone tube was also pulled together with the prolene suture (Fig. 2C). Then, the silicone tube was passed to the other end, assisted by the round-tipped pigtail probe from the punctum of the damaged canaliculus (Fig. 2D). Thus, the silicone tube passed both the upper and lower canaliculi. The 6/0 prolene suture passing within the silicone was tightly bound end to end (Fig. 2E). The ends of the silicone remaining exposed were embedded within the canaliculus. The posterior and anterior sections of the lacerated canalicular wall were sutured with 8/0 Vicryl and the skin laceration with 6/0 prolene, and fixation was performed by drawing the wound lips together. The ends of the silicone tube were left at some length to prevent them from reaching the cornea and causing irritation (Fig. 2F). The average length of the tubing used in all patients was approximately 20 mm, which was close to the mean value previously mentioned in the literature.<sup>14</sup> The silicone tube was left in place for at least one year.

## Results

The study included 64 patients, comprised 51 (79.7%) males and 13 (20.3%) females, with a mean age of  $14.66 \pm 16.83$  years (range: 1-69 years). Of the total number of patients, 46 (71.9%) were aged <15 years. The mean follow-up period was  $33.7 \pm 17.41$  months (range: 2-58 months). The cause of the canalicular



**Fig. 2. Right upper lacrimal canalicular injury repairing with annular silicone tube and round-tipped pigtail probe.**

laceration was associated with penetrating trauma in 36 (56.3%) cases and with blunt trauma in 28 (43.8%) cases. The laceration was in the lower canaliculus in 42 (65.6%) cases, in the upper canaliculus in 19 (29.7%) cases, and in both canaliculi in three (4.7%) cases. In addition to canalicular laceration, eyelid laceration was confirmed in 15 (23.4%) cases, conjunctival injury in seven (10.9%), corneal injury in two (3.1%), cornea-scleral laceration in one (1.6%), extraocular muscle laceration in one (1.6%), and frontal sinus fracture in one (1.6%). At the final follow-up examination, traumatic ectropion was observed and associated with epiphora in one patient, and surgery was reperformed. In the follow-up of this patient, the epiphora appeared to be resolved. In one patient where a round-tipped pigtail probe had been applied for canalicular laceration at an external centre, the tube had not passed to the canaliculus; the tube was long, and as the suture had not been folded, it was then in contact with the cornea, thus causing irritation. The tube was reapplied with a round-tipped pigtail probe to pass from the canaliculus, and the length was shortened. In the follow-up period, no epiphora was observed. At the end of the one-year follow-up after removal of the silicone tube, no cases of anatomical or functional failure were observed.

## Discussion

Canalicular injuries have been reported as constituting 15.5% of all eyelid injuries.<sup>15</sup> Lacrimal canalicular laceration is the most frequently seen injury of the lacrimal



system. In a study of 25 cases, Wulc *et al.* reported that as the canalicular region includes less connective tissue compared to the tarsal region, injuries associated with trauma occur more easily, and the most common cause of canalicular laceration, at a rate of 84%, was blunt trauma.<sup>16</sup> In contrast, Jordan *et al.* reported that canalicular tears developed as a result of penetrating trauma in 55.2% of 236 cases.<sup>17</sup> In this study, the injuries were found to be associated with penetrating trauma in 36 (56.3%) cases and with blunt trauma in 28 (43.8%) cases, which are rates closer to those of the second above-mentioned study.

It is possible to prevent epiphora following trauma with correct diagnosis and an appropriate surgical approach. Some authors have stated that the lower canaliculus is important and therefore prefer not to use a probe in the repair of the upper canaliculus. Other authors have reported that tear drainage has a significant role in the function of both canaliculi.<sup>4,18-20</sup> In previous studies, there have been more reports of canalicular lacerations in the lower canaliculus.<sup>3,12</sup> In this study, lacerations of the lower canaliculus were seen twice as much as that of the upper canaliculus. Furthermore, the laceration was in the lower canaliculus in 42 (65.6%) patients and in the upper canaliculus in 19 (29.7%) patients.

In a study of 13 patients, Smit and Mourits repaired mono-canalicular lacerations with cutaneous and subcutaneous sutures only, without the application of silicone tube.<sup>21</sup> This study concluded that despite the observation of epiphora, this method had not caused great discomfort, and it was also stated that some cases were of "familial" causes. In response to criticisms of this application, it was stated that because of the length of ophthalmology operating lists and the risks of treatment, this particular approach could be considered a viable surgical option.<sup>21</sup> In contrast, in a study by Jordan, it was reported that although same-day canalicular repair is not mandatory, better results are obtained in cases treated within seven to 10 days.<sup>22</sup> In one of the cases in this study, canalicular laceration repair had been performed at an external center one week previously, but the patient had complaints of stinging and epiphora. As the knots of the suture joining the silicone tube had not been turned inside the canaliculus, this was causing irritation, and the silicone tube itself was not within the canaliculus. After the intervention in our clinic, anatomic and functional success was observed in the follow-up. This case can be considered as good evidence confirming the claim that rather than doing nothing, and even if there is a delay of a few days, the patient should still be referred to a center where canalicular repair can be effectively performed.

Ultimately, there are three basic principles for successful canalicular repair: (i) end-to-end proximity of the lacerated parts, (ii) endo-canalicular support with the silicone tube, and (iii) an atraumatic approach to the non-injured side of the lacrimal system.<sup>12</sup> With functional and anatomic success obtained for all of the present study's patients, the use of the round-end pigtail probe and silicone tube

can be considered to have met these three principles. Epiphora was only observed in one (1.8%) of the patients. The reason for epiphora in this case was associated not with the canaliculus, but with traumatic ectropion, which was corrected with surgery; at the end of the one-year follow-up, there was no further complaint of epiphora. To corroborate the results presented here, one of the largest case series in the literature using a round-tipped pigtail probe in canalicular laceration repair was by Jordan *et al.*, where the success rate was reported as 97.4% with the application of this method.<sup>14</sup>

The limitation of this method have been reported as involving the risk of damage to the healthy canaliculus or to the common canaliculus, the risk of opening the wrong passage, and that the method cannot be used in individuals with no common canaliculus.<sup>14,20-23</sup> The pigtail probe cannot be used in patients without common canaliculus because there is no anatomic patency to allow the probe to pass. In our practice, we have used a round-end pigtail probe in all cases of isolated canalicular laceration without encountering any of these disadvantages, but we still prefer not to use the method in patients with laceration of the common canaliculus. In a study of 18 cases of canalicular laceration repaired with the assistance of a round-tipped pigtail probe, success was reported for 100% of the patients, and in another study of 22 cases, the success rate was 94%.<sup>12,24</sup> In this study of 64 cases, a success rate of 100% was achieved both anatomically and functionally.

Some authors have claimed that as there is a traumatic effect on the healthy canalicular system, the results of the pigtail probe may not be satisfactory, and the method should be abandoned.<sup>9,20</sup> These comments are most likely formed in reference to the single round-tipped pigtail probe and, more specifically, directed at the "hook-end" pigtail probe introduced by Worst.<sup>8</sup> With the use of a round-tipped pigtail probe, may be, the anatomical and functional success rates are still extremely high.<sup>8,13,22</sup> Reasons for unsuccessful surgeries may include the severity of the trauma and the use of other material in place of the silicone stent. That the silicone stent within the lumen does not create any narrowing of the canalicular wall is extremely important in terms of facilitating the healing process. In an animal experimental study by Snead *et al.*, it was shown that the silicone tube within the canaliculus was maintained in a stable position with the blink reflex without any effect on epithelialization.<sup>25</sup> Therefore, in this study, the silicone tube was left in place within the canaliculus for one year, and this can be considered to have had as much of an effect on the functional success as the surgical approach itself.

Although the duration of the silicone tube is generally recommended as six months, in some series, cases with recurrent tearing after removal of the silicone tube even after 10 months have been mentioned.<sup>14</sup> The reason why we prefer the duration of the silicone tube as 12 months is to avoid recurrent punctal closure,

re-stenosed, canalicular narrowing, and intermittent tearing. We think that the biggest reason for our success in our cases is due to the duration of this silicon tube.

In conclusion, in cases of traumatic canalicular laceration, annular silicone placement with a round-tipped pigtail probe is a surgical method which can be quickly learned and easily applied, with low costs and high success rates. Thus, its current use remains justified. It should be noted that the learning curve is not long since the residents have very short time to learn this surgical method.

## References

1. Naik MN, Kelapure A, Rath S, Honavar SG. Management of canalicular lacerations: epidemiological aspects and experience with Mini-Monoka monocanicular stent. *Am J Ophthalmol.* 2008;145(2):375-380.
2. Reifler DM. Management of canalicular laceration. *Surv Ophthalmol.* 1991;36(2):113-132.
3. Kennedy RH, May J, Dailey J, Flanagan JC. Canalicular laceration. An 11-year epidemiologic and clinical study. *Ophthal Plast Reconstr Surg.* 1990;6(1):46-53.
4. Jones LT, Marquis MM, Vincent NJ. Lacrimal function. *Am J Ophthalmol.* 1972;73(5):658-659.
5. Quickert MH, Dryden RM. Probes for intubation in lacrimal drainage. *Trans Am Acad Ophthalmol Otolaryngol.* 1970;74(2):431-433.
6. Crawford JS. Intubation of obstructions in the lacrimal system. *Can J Ophthalmol.* 1977;12(4):289-292.
7. Fayet B, Bernard JA, Pouliquen Y. Repair of recent canalicular wounds using a monocanicular stent. *Bull Soc Ophthalmol Fr.* 1989;89(6-7):819-825.
8. Worst JG. Method for reconstructing torn lacrimal canaliculus. *Am J Ophthalmol.* 1962;53:520-522.
9. Saunders DH, Shannon GM, Flanagan JC. The effectiveness of the pigtail probe method of repairing canalicular lacerations. *Ophthalmic Surg.* 1978;9(3):33-40.
10. Welham R. The immediate management of injuries to the lacrimal drainage apparatus. *Trans Ophthalmol Soc UK.* 1982;102:216.
11. Anderson RL, Edwards JJ. Indications, complications and results with silicone stents. *Ophthalmology.* 1979;86(8):1474-1487.
12. Jordan DR, Nerad JA, Tse DT. The pigtail probe, revisited. *Ophthalmology.* 1990;97(4):512-519.
13. Beyer CK. A modified lacrimal probe. *Arch Ophthalmol.* 1974;92(2):157.
14. Jordan DR, Gilberg S, Mawn LA. The round-tipped, eyed pigtail probe for canalicular intubation: a review of 228 patients. *Ophthal Plast Reconstr Surg.* 2008;24(3):176-1780.
15. Herzum H, Holle P, Hintschich C. Eyelid injuries: epidemiological aspects. *Ophthalmologie.* 2001;98(11):1079-1082.
16. Wulc AE, Arterberry JF. The pathogenesis of canalicular laceration. *Ophthalmology.* 1991;98(8):1243-1249.
17. Jordan DR, Ziai S, Gilberg SM, Mawn LA. Pathogenesis of canalicular lacerations. *Ophthal Plast Reconstr Surg.* 2008;24(5):394-398.
18. Ho T, Lee V. National survey on the management of lacrimal canalicular injury in the United Kingdom. *Clin Exp Ophthalmol.* 2006;34(1):39-43.
19. Linberg JV, Moore CA. Symptoms of canalicular obstruction. *Ophthalmology.* 1988;95(8):1077-10789.
20. Canavan YM, Archer DB. Long-term review of injuries to the lacrimal drainage apparatus. *Trans Ophthalmol Soc UK.* 1979;99(1):201-204.

21. Smit TJ, Mourits MP. Monocanalicular lesions: to reconstruct or not. *Ophthalmology*. 1999;106(7):1310-1312.
22. Jordan DR. To reconstruct or not. *Ophthalmology*. 2000;107(6):1022-1023.
23. Hing SJ. A retrospective study of lacrimal canaliculus injuries in Auckland. *Trans Ophthalmol Soc N Z*. 1984;36:72-73.
24. Walter WL. The use of the pigtail probe for silicone intubation of the injured canaliculus. *Ophthalmic Surg*. 1982;13(6):488-492.
25. Snead JW, Rathbun JE, Crawford JB. Effects of the silicone tube on the canaliculus: an animal experiment. *Ophthalmology*. 1980;87(10):1031-1036.

# Deep anterior lamellar keratoplasty with manual small-incision cataract surgery: a modification of the triple procedure

Pawan Prasher

Department of Ophthalmology, Sri Guru Ram Das Institute of Medical Sciences and Research, Vallah, Amritsar, Punjab, India

## Abstract

We describe a modified surgical technique for performing the triple procedure that combines deep anterior lamellar keratoplasty with manual small-incision cataract surgery. This technique offers advantages in terms of undergoing a single surgery as compared to the staged procedure, preservation of the host Descemet's membrane and endothelium, and ability to perform cataract surgery in a closed-chamber setting.

**Keywords:** deep anterior lamellar keratoplasty, manual small-incision cataract surgery, triple procedure

Penetrating keratoplasty (PKP) triple is a well-established surgical procedure used for the management of patients with comorbidities of corneal opacities and cataract.<sup>1</sup> It involves making a full-thickness circular incision incorporating the pathology in the host cornea, performing cataract extraction and intraocular lens (IOL) implantation by open-sky technique, followed by suturing the donor cornea to the host bed. Over the last two decades, there has been a paradigm shift from full-thickness PKP to lamellar keratoplasty, which is aimed at replacing only the diseased layers of the cornea while preserving the normal ones. This has posed new challenges in terms of offering combined procedures to the patients with comorbidities. Although a combination of deep anterior lamellar keratoplasty (DALK) with phacoemulsification has been described by various surgeons,<sup>2-5</sup> phacoemulsification may not always be possible for logistic reasons, or it may be difficult due to patient-related factors such as small pupil, hard cataract, or weak zonules. Manual small-incision cataract surgery (MSICS) technique is a viable alternative to phacoemulsification and is routinely used to perform cataract surgery in developing countries like India. Herein, we describe a modification of the triple procedure that combines DALK with MSICS and offers advantages of both surgeries while obviating the need for multiple surgeries in selected patients with comorbidities.

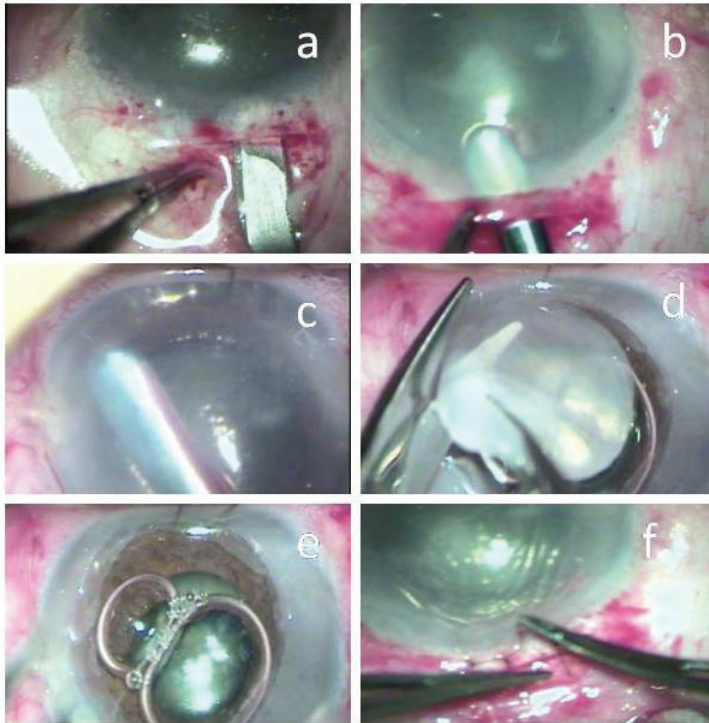
**Correspondence:** Dr. Pawan Prasher, Amritsar Eye Hospital, GNDU Shopping Complex, GT Road, Amritsar, Punjab 143001, India.  
E-mail: [pawanprasher@yahoo.com](mailto:pawanprasher@yahoo.com)

## Case report

A 65-year-old male, farmer by occupation, presented with bilateral corneal opacities, attributed to corneal scarring and degeneration secondary to old trachomatous infection, and a cataract in the right eye. The opacity appeared to be predominant in the anterior cornea with relative sparing of posterior stroma and Descemet membrane. The left eye had undergone cataract surgery 2 years back; however, the patient was not satisfied with the poor visual outcome which was attributed to visually significant corneal opacity in that eye. Best spectacle-corrected visual acuity (BSCVA) was 6/60 in the right eye and 6/24 in the left eye. The intraocular pressure was 14 and 16 mmHg in the right and left eye. The remaining ocular and systemic examination was unremarkable. As the opacity was denser in the right eye, a combined triple procedure was planned after getting informed consent from the patient. The IOL power was measured using a presumed keratometry reading of 44 D as is routinely done at our institute for the triple procedures.

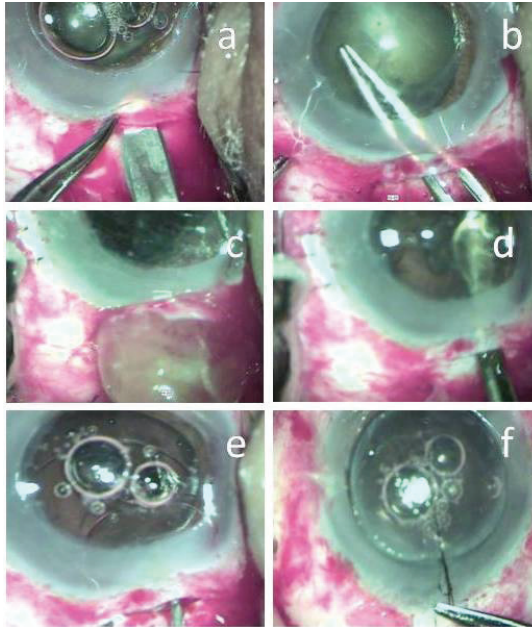
## Surgical technique

The patient was taken up for surgery after a donor corneal button was procured from one of the approved eye banks under Central Distribution System of India. Under peribulbar anesthesia, a superior rectus bridle suture was placed and a fornix-based conjunctival flap was raised along the superior limbus. A 4-mm-long, partial thickness, scleral incision was made 2 mm posterior to the superior limbus. A corneoscleral tunnel was constructed up to the limbus with a crescent blade. An oblique side-port incision was made inferotemporally and a large air bubble was injected into anterior chamber to make eye firm. The stromal dissection was carried out all around the cornea up to 1.5 to 2 mm inside the limbus with a Morlet dissector (Duckworth and Kent, Hertfordshire, England), using a technique described by Melles.<sup>6</sup> This technique makes use of the specular reflection to achieve dissection as close to Descemet membrane as possible (Fig. 1). The scleral incision was subsequently closed with three interrupted 10-0 nylon sutures. Most of the air bubble was subsequently aspirated leaving behind a small bubble in the anterior chamber to aid in the visualization of the integrity of Descemet membrane. A viscoelastic was injected into the scleral tunnel to separate the anterior and posterior corneal lamellae. The movement of air bubble to the periphery of anterior chamber confirmed the separation and posterior distension of the posterior lamella. Anterior corneal button was removed using an 8-0 trephine and corneal scissors, as is routinely done for conventional PKP. The surgeon now moved to the temporal side of the patient and a fornix-based conjunctival flap was fashioned temporally. A temporal sclerocorneal tunnel was constructed as is routinely done in MSICS up to 1 mm inside the temporal limbus



**Fig. 1.** Intraoperative pictures describing various steps of lamellar dissection: (a) sclerocorneal tunnel construction. (b and c) Stromal dissection. (d) Excision of anterior corneal lamella. (e) Air bubble in anterior chamber suggestive of preservation of integrity of Descemet membrane. (f) Suturing of the scleral incision.

taking care not to extend the tunnel to the plane of corneal dissection. Subsequent maneuvers including hydrodissection, nucleus delivery using viscoexpression, cortical aspiration, and implantation of single-piece polymethyl methacrylate IOL were performed gently in an attempt to prevent any abrupt changes in the anterior chamber pressure (Fig. 2). The residual stroma offered excellent view for performing various steps. During the cortical aspiration, a note was made of posterior movement of posterior lamella towards the aspiration tip which was easily prevented by manual reduction of the speed of aspiration. The temporal sclera incision was closed with a 10-0 nylon suture to avoid any potential wound gape by traction from subsequent corneal sutures to be used to secure donor cornea to the host bed. The anterior stromal bed was meticulously washed to remove any viscoelastic material or debris. The donor cornea preparation



**Fig. 2.** Intraoperative pictures describing various steps of cataract surgery and donor placement: (a) temporal sclerocorneal tunnel construction. (b) Capsulorrhexis. (c) Nucleus delivery. (d) Cortex aspiration. (e) IOL implantation. (f) Suturing of donor cornea to the host bed.

included complete stripping of Descemet's membrane and endothelium using dry Weck-Cels. An 8.25-mm trephine was subsequently used to prepare the donor corneal button which was sutured to the host bed using a combination of 12 interrupted and a 12-bite single running suture. The conjunctival flaps were closed and subconjunctival gentamicin and dexamethasone combination was injected before closing the eye.

### Postoperative course

The early postoperative treatment included topical moxifloxacin four times daily, topical prednisolone eye drops six times daily and topical lubricants six times daily for 3 weeks. Moxifloxacin was subsequently discontinued and prednisolone drops were gradually tapered to twice daily over a period of 6 weeks. The early postoperative period was significant for a persistent epithelial defect which was treated with a bandage contact lens application. He had a stromal rejection episode at 10 months which was attributed to a loose suture and was controlled



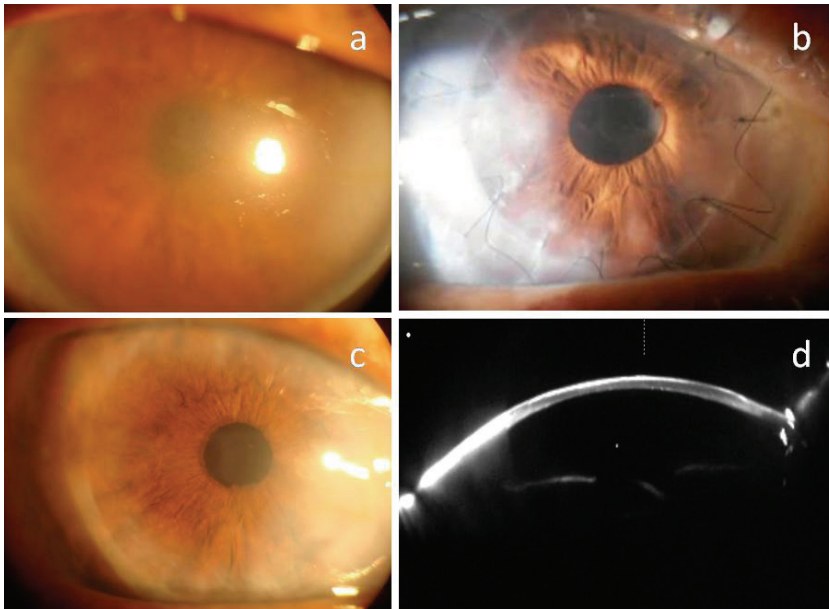


Fig. 3. (a) Slit-lamp pictures of the cornea show dense corneal opacity preoperatively. (b) At 3 months, graft is clear with mild interface haze. (c) At last follow-up more than 3 years after surgery, graft has remained clear with mild persistent interface haze. (d) Scheimpflug imaging shows minimal reflectivity at the interface.

by intensive topical and oral steroids along with suture removal. At his last visit 3.5 years post-operatively BSCVA was 6/12 with a manifest refraction of  $-0.75$  D  $-2$  D  $\times$  170. The graft looked healthy apart from mild interface haze, which was confirmed on Scheimpflug imaging, and the IOL was well-centered (Fig. 3). The specular microscopy was not available in the current case.

## Discussion

We describe a modification of the triple procedure that combines DALK with MSICS. It offers advantages in terms of early visual rehabilitation by treating corneal disease and cataract in the same sitting as compared to the staged procedure. The advantages of DALK over PKP include preservation of host endothelium, which carries lower risk of endothelial rejection and hence lesser need for long-term steroids, leading to lower incidence of postoperative glaucoma, cataract and secondary infection, and better wound integrity in situations of inadvertent trauma.<sup>1-10</sup> The drawbacks of the current technique include interface haze as a result of scarring due to residual stroma as Descemet's membrane is not bared, unlike the more preferred Anwar's big-bubble technique in which

Descemet membrane is bared.<sup>7</sup> Although previous authors have successfully performed phacoemulsification with DALK using big-bubble technique, there has been a concern regarding the unpredictability of the type of bubble formation. While it was possible to perform phacoemulsification when big-bubble formation occurred at the pre-Descemet level; the residual tissue in a big-bubble formed at the level of Descemet membrane could not withstand the raised intraocular pressure during cataract surgery, leading to its rupture.<sup>4</sup> In such a situation, having some residual stromal tissues may offer advantage in providing sufficient strength to the posterior corneal lamella for performing combined cataract surgery in a closed chamber. Although interface haze has been a concern with manual dissection, a randomized controlled trial between Melles' versus Anwar technique did not show any significant difference in terms of visual acuity and refractive outcomes between the two techniques, although contrast sensitivity was better with Anwar technique.<sup>8</sup> Another study, however, found a correlation between reduced visual acuity and residual stromal thickness, wherein they reported that more than 80  $\mu\text{m}$  of residual stroma is associated with significantly reduced visual acuity.<sup>9</sup>

The current technique makes use of a sclerocorneal tunnel to perform the cataract surgery in a closed chamber as compared to open-sky method in routine triple procedure. In a closed-chamber setting, the surgeon has a greater control in performing various steps like capsulorrhexis, nucleus delivery, cortex aspiration, and IOL placement in the capsular bag, and there is a less risk of potentially devastating complications associated with open-sky method like expulsive hemorrhage and choroidal effusion.<sup>11</sup> Although phacoemulsification is considered a gold standard for cataract surgery, efficacy and safety of MSICS has been well established, especially in developing countries.<sup>12-14</sup> Although phacoemulsification can also be done with DALK, we believe MSICS is a viable alternative in situations where phacoemulsification may be difficult or risky like in eyes with hard cataracts, small pupils, and weak zonules, or where phacoemulsification may not be possible or available for logistic reasons. MSICS has the advantage of being a manual procedure devoid of complications related to ultrasound energy and is relatively inexpensive. In the current technique, cataract surgery component can be added to DALK with minimal cost in terms of additional equipments or instruments. Although phacoemulsification offers advantage of inducing less astigmatism, it may not always transform into functional improvement for the patients.<sup>14</sup> Also, in a combined triple procedure, the final astigmatism is more likely to be determined by donor graft–host interaction rather than by the cataract surgery incision alone. The current technique would be suitable for a subset of patients with coexisting anterior corneal pathologies not involving the Descemet's membrane and visually significant cataracts in situations where

phacoemulsification machine and foldable IOLs may not be available due to logistics or cost factors.

In conclusion, despite some of its inherent drawbacks, combined DALK with MSICS technique may be useful in select patients with comorbidities and provides a viable alternative to the corneal surgeons planning to perform triple procedure in such patients.

## References

1. Oie Y, Nishida K. Triple procedure: cataract extraction, intraocular lens implantation, and corneal graft. *Curr Opin Ophthalmol.* 2017;28:63-66.
2. Muraine MC, Collet A, Brasseur G. Deep lamellar keratoplasty combined with cataract surgery. *Arch Ophthalmol.* 2002;120:812-815.
3. Senoo T. Combined surgery with deep lamellar keratoplasty. *Semin Ophthalmol.* 2001;16:126-136.
4. Zaki AA, Elalfy MS, Said DG, Dua HS. Deep anterior lamellar keratoplasty—triple procedure: a useful clinical application of the pre-Descemet's layer (Dua's layer). *Eye (Lond).* 2015;29:323-326.
5. Panda A, Sethi HS, Jain M, Nindra Krishna S, Gupta AK. Deep anterior lamellar keratoplasty with phacoemulsification. *J Cataract Refract Surg.* 2011;37:122-126.
6. Melles GR, Lander F, Rietveld FJ, Remeijer L, Beekhuis WH, Binder PS. A new surgical technique for deep stromal, anterior lamellar keratoplasty. *Br J Ophthalmol.* 1999;83:327-333.
7. Anwar M, Teichmann KD. Big-bubble technique to bare Descemet's membrane in anterior lamellar keratoplasty. *J Cataract Refract Surg.* 2002;28:398-403.
8. Baradaran-Rafii A, Eslani M, Sadoughi MM, Esfandiari H, Karimian F. Anwar versus Melles deep anterior lamellar keratoplasty for keratoconus: a prospective randomized clinical trial. *Ophthalmology.* 2013;120:252-259.
9. Ardjomand N, Hau S, McAlister JC, et al. Quality of vision and graft thickness in deep anterior lamellar and penetrating corneal allografts. *Am J Ophthalmol.* 2007;143:228-235.
10. Prasher P, Muftuoglu O, Mootha VV. Traumatic graft dehiscence after anterior lamellar keratoplasty. *Cornea.* 2009;28:240-242.
11. Chen W, Ren Y, Zheng Q, Jhanji V. Stabilized triple procedure for management of coexisting corneal opacity and cataract. *J Cataract Refract Surg.* 2014;40:1966-1970.
12. Gogate PM, Kulkarni SR, Krishnaiah S, et al. Safety and efficacy of phacoemulsification compared with manual small-incision cataract surgery by a randomized controlled clinical trial: six-week results. *Ophthalmology.* 2005;112:869-874.
13. Ruit S, Tabin G, Chang D, et al. A prospective randomized clinical trial of phacoemulsification vs manual sutureless small-incision extracapsular cataract surgery in Nepal. *Am J Ophthalmol.* 2007;143:32-38.
14. Gogate P, Optom JB, Deshpande S, Naidoo K. Meta-analysis to compare the safety and efficacy of manual small incision cataract surgery and phacoemulsification. *Middle East Afr J Ophthalmol.* 2015;22:362-369.

# Asymptomatic chronic hypotony due to subclinical choroidal effusion after blunt trauma

John Mark S. de Leon, Ronald Steven Medalle II

Department of Health Eye Center, East Avenue Medical Center, East Avenue, Diliman, Quezon City, Philippines

## Abstract

**Objective:** To present a case report of asymptomatic post-traumatic chronic hypotony in which the cause was undetected until phacoemulsification.

**Methodology:** Case report.

**Results:** A 55-year-old female's left eye suffered blunt trauma causing hyphema and iritis, which were successfully managed; however, up to a year after, the intraocular pressure (IOP) ranged from 3 to 5 mmHg and the anterior chamber remained very shallow (Van Herick grade 4) with the lens-iris diaphragm pushed anteriorly with difficulty assessing the angles for recession or clefts. Visual acuity was initially 20/20 upon resolution of the hyphema but worsened to 20/40 a year after, presumably due to a developing cataract. Periodic dilated fundus examinations revealed no hypotony maculopathy or choroidal effusions. Prior to phacoemulsification, ultrasound biomicroscopy (UBM) revealed 360 degrees of mild peripheral choroidal effusions. During phacoemulsification, after intraocular lens insertion, direct gonioscopy revealed a supero-nasal cyclodialysis cleft (2 clock hours) and this was repaired intraoperatively with direct cyclopexy through a partial thickness scleral flap. Post-operatively, the vision improved to 20/20 without correction and the IOP normalized to 16 to 18 mmHg.

**Conclusion:** Chronic hypotony post-trauma may be asymptomatic and the cause may not be clinically evident and may be detected by UBM (choroidal effusion). In our case, the proximate aetiology (cyclodialysis cleft) of the effusion was only observed intraoperatively after phacoemulsification for which cyclopexy was performed which increased the IOP to physiologic levels.

**Keywords:** blunt trauma, choroidal effusion, cyclopexy, hypotony, intraocular pressure, ultrasound biomicroscopy

## Background

Chronic hypotony may be due to surgery, trauma, inflammation or systemic diseases. Patient with chronic hypotony may be asymptomatic or can have blurred vision with complications.<sup>1</sup> Since management can be either be conservative or

**Correspondence:** John Mark S. de Leon, Torres Bugallon Street, Tierra Pura Subd., Quezon City 1107, Philippines.  
E-mail: [jmarkmd1@yahoo.com](mailto:jmarkmd1@yahoo.com)

aggressive, a thorough investigation of hypotony through clinical and auxiliary means is invaluable.

### Case presentation

A 55-year-old female presented with blurring of vision and redness on her left eye (OS) from blunt trauma from a tossed cup. At the emergency room her visual acuity (VA) was 20/20 for both eyes; slit-lamp examination revealed traumatic hyphema, grade I, OS. Intraocular pressures (IOPs) were 10 mmHg in both eyes (OU). Antibiotic-steroid eye drops, OS and oral tranexamic acid were prescribed. Day 3 post-trauma, the hyphema progressed to grade III with VA dropping to good light projection, necessitating admission for observation. IOP, OS ranged from 5 to 6 mmHg. The hyphema resolved on day 4 and the patient was discharged. The central anterior chamber depth, OS was shallow (Fig. 1a), in contrast to OD (Fig. 1b).

Four-mirror gonioscopy, OS showed closed angles nasally and temporally and it was difficult to appreciate any angle recession or cyclodialysis clefts even on indentation because of the lens-iris diaphragm pushed forward. IOPs, OS still ranged from 4 to 5 mmHg. A dilated retinal examination, OS revealed an unremarkable posterior pole. Upon discharge, the best-corrected VA (BCVA) was as follows:

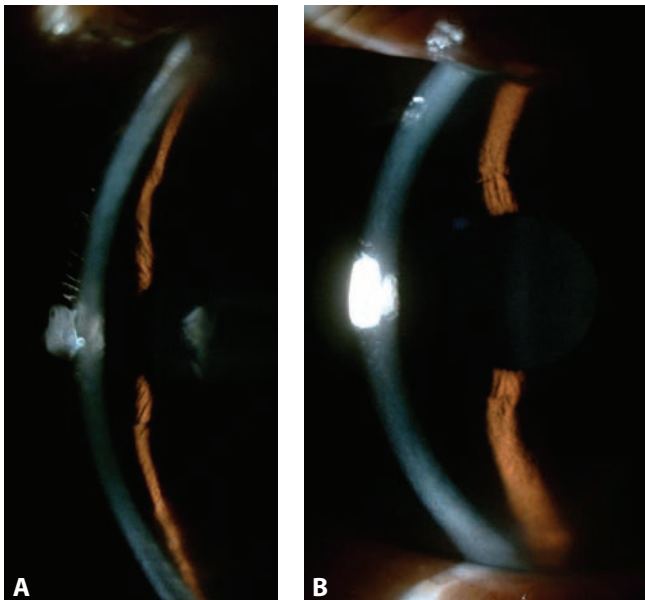


Fig. 1. (a) Central anterior chamber depth, OS. (b) Central anterior chamber depth, OD.

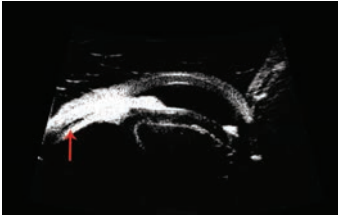


Fig. 2. UBM showing choroidal effusion, OS.



Fig. 3. Cyclodialysis cleft, OS.

OD: +1.25 -0.25 × 90 (20/20) and OS: +1.50 (20/32). On monthly follow-ups, BCVA, OS was stable at 20/32, though with progressive blurring of vision.

A year after the trauma because of the persistence of asymptomatic hypotony, an ultrasound biomicroscopy (UBM) was done, OS showing closed angles as well as 360 degrees of choroidal effusion (red arrow; Fig. 2); however, no cyclodialysis cleft was observed in any of the cross-sectional UBM cuts.

Since the cataract progressed and BCVA dropped to 20/40, phacoemulsification with intraocular lens insertion was performed. Immediately after lens insertion, the anterior chamber was filled with viscoelastic and an intraoperative gonioscopy with a direct gonioscope revealed a 2-clock hour supero-nasal cyclodialysis cleft (red arrow; Fig. 3).

The conjunctival area overlying the cleft was marked, a conjunctival peritomy and a partial thickness scleral flap was dissected anteriorly to the ciliary body. Direct cyclohexy was then completed at the site with nylon 10-0 sutures (Fig. 4).

One-week after cataract surgery and cyclohexy, OS, VA improved to 20/20, the anterior chamber was formed with open angles and the IOP was 18 mmHg.

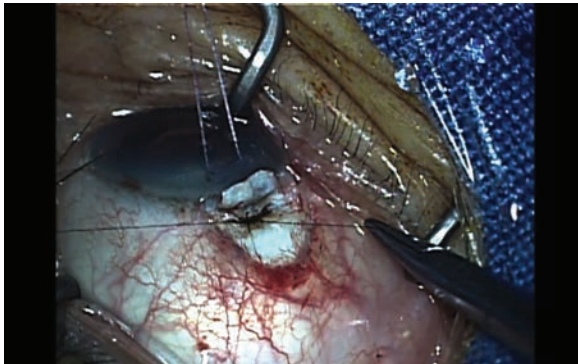


Fig. 4. Direct cyclohexy, OS.

## Discussion and conclusion

There are several aetiologies of chronic hypotony due to trauma depending on the mechanisms involved. In one study, only 6.9% of blunt trauma cases led to hypotony.<sup>2</sup> Chronic hypotony is relatively uncommon and can be asymptomatic, and symptoms are usually due to damage to the cornea, lens, choroid, retina or optic nerve. A hyperopic shift, which was not observed in our patient, may also occur with hypotony. Choroidal effusions usually occur in hypotony due to accumulation of serous fluid in the suprachoroidal space due to the pressure gradient between the IOP and hydrostatic pressure in the choroidal blood vessels.<sup>3</sup> Not only do choroidal effusions result from hypotony but may also lower IOP further by reducing aqueous humor production and probably through increased uveoscleral outflow as well, thus presenting a vicious cycle of hypotony.<sup>4</sup> Hypotony post-trauma can be due to ciliary shutdown, but this usually is transient; however, hypotony in our patient lasted for more than a year. When choroidal effusion is subclinical, the VA may be good and occult effusions may be diagnosed only by UBM, as seen with our patient. Hypotony maculopathy was ruled out since the macular examination was normal. Choroidal effusions eventually resolve when hypotony improves, considering that the inciting factor is managed.

Pre-operatively in our case, clinical examination and diagnostics had only revealed a shallow anterior chamber with narrow angles, with no angle recession and 360 choroidal effusions on UBM. Phacoemulsification in our case was only able to reveal the cyclodialysis cleft. The cleft or a recessed angle was probably not seen pre-operatively because of the difficulty indenting the four-mirror gonioscopy due to the swollen lens and the lens-iris diaphragm pushed forward. The supine patient with the cataract already removed made it more possible to see the cleft better with the direct gonioscopy.

Cyclodialysis clefts appear as a recess between the scleral spur and ciliary body. From the disrupted anatomy, aqueous may now enter the posterior chamber through the suprachoroidal space, leading to increased outflow and consequently lower IOP as well as a flat anterior chamber, resulting in the choroidal effusions. These are rare even in the setting of eye trauma; in one study, only 2% of 145 eyes studied were hypotonic and found to have an associated cyclodialysis cleft.<sup>2</sup> It was also found that most IOPs associated with clefts are around <7 mmHg on diagnosis, with a wide range of VA among patients, whereas those with < 4 mmHg having worse VA due to the complications from hypotony.<sup>5</sup>

There should be a high index of suspicion in cases of IOP <5 mmHg in cases of blunt trauma associated with hyphema, similar to our patient, or when associated with iris sphincter tears.<sup>6</sup> Similar to choroidal effusion, these may spontaneously resolve, otherwise, may cause the complications mentioned for hypotony. Diagnostics would include gonioscopy, anterior segment OCT and UBM, although



the latter is found to be the most sensitive to detect these clefts, especially when they are small.<sup>7</sup> A study showed that UBM detected clefts in 100% of patients compared to only 16.7% detected by gonioscopy.<sup>6</sup>

Management of cyclodialysis clefts and subsequently chronic hypotony can range from medical to surgical, especially when the former fails. They also depend on the size of the cleft.

- Medical treatment is usually for clefts 4 clock hours or less and limited to 6 to 8 weeks with topical cycloplegics. This theoretically would allow time for fusion of the ciliary muscles to the sclera.<sup>8</sup> There is no consensus with the use of topical steroids to aid in the healing.
- Laser photocoagulation, diathermy or cryotherapy is the next step with unresponsive clefts and treatment modalities include argon laser photocoagulation, trans-scleral diathermy and trans-conjunctival cryotherapy or diode laser cyclophotocoagulation.<sup>6</sup> We did not opt to do these procedures because we were contemplating to do phacoemulsification.
- Surgery is the next option if still unresponsive or with large clefts > 4 clock hours in size.<sup>8</sup> The various techniques are beyond the scope of this case report, but it is of note to mention that surgery was the immediate action done due to the fact that medical management had already failed and that there already was an opportunity during the cataract surgery. Despite the small size of the cleft, it had become chronic and unresponsive to the medications. Direct cyclopexy was the procedure of choice, where the ciliary body was sutured directly to the sclera through the flap created. This technique had already been established in these cases with high success rates.<sup>9</sup>

This case presented as an asymptomatic post-traumatic chronic hypotony due to subclinical choroidal effusion observed only by UBM. The aetiology was a small 2-clock-hour cyclodialysis cleft only detected by direct gonioscopy during phacoemulsification after a traumatic cataract developed. Our case also highlighted the fact that choroidal effusion could also mask a small cyclodialysis cleft. Intraoperative direct cyclopexy resulted in normalization of the IOP post-operatively.

## Acknowledgements

### Ethics approval and consent to participate

This observational study was approved under an expedited review by the ethics review board of the East Avenue Medical Center.



### Consent for publication

Our patient had given written consent to show photographs of his eye and print-outs of his tests in this manuscript.

### Availability of data and materials

The patient data used during this study are available from the corresponding author on reasonable request

### Competing interests

The authors declare that they have no competing interests.

### Funding

There was no source of any funding for this study.

### Authors' contributions

JMSL and RSSM contributed both to the manuscript preparation. RSSM contributed to data gathering and JMSL contributed to the finalization of the article prior to submission.

### References

1. Thomas M, Vajaranant TS, Aref AA. Hypotony maculopathy: clinical presentation and therapeutic methods. *Ophthalmol Ther.* 2015;4(2):79-88. doi:10.1007/s40123-015-0037-z.
2. Ding C, Zeng J. Clinical study on hypotony following blunt ocular trauma. *Int J Ophthalmol.* 2012;5(6):771. doi:10.3980/j.issn.2222-3959.2012.06.21.
3. Kahook MY, Noecker RJ. Why do choroidals form, and how do you treat them. *Glaucoma Today.* 2007;36-38. [http://glaucomatoday.com/2007/10/GT0907\\_07.php/](http://glaucomatoday.com/2007/10/GT0907_07.php/).
4. Reddy AC, Salim S. Diagnosis and management of choroidal effusions. *Eyenet.* 2012. <https://www.aao.org/eyenet/article/choroidal-effusions>.
5. Ormerod LD, Baerveldt G, Sunalp MA, Riekhof FT. Management of the hypotonous cyclodialysis cleft. *Ophthalmology.* 1991;98(9):1384-1393. <https://www.ncbi.nlm.nih.gov/pubmed/1945314>.
6. Kiely AE, Salim S. All contributors. [http://eyewiki.aao.org/Cyclodialysis\\_Clefts](http://eyewiki.aao.org/Cyclodialysis_Clefts).
7. American Academy of Ophthalmology. *Glaucoma 10.* San Francisco, CA: American Academy of Ophthalmology; 2014.
8. Ramulu PM. Cyclodialysis cleft after trauma. *Eyenet.* 2004. <https://www.aao.org/eyenet/article/cyclodialysis-cleft-after-trauma>.
9. Rodrigues IA, Shah B, Goyal S, Lim KS. Gonioscopically guided nonpenetrating cyclodialysis cleft repair: a novel surgical technique. *J Curr Glaucoma Prac.* 2017;11(1):31. <https://www.ncbi.nlm.nih.gov/pmc/articles/PMC5263884/>.

# Safety and efficacy of reconstituted atropine 0.01% eye drops for Indian children with myopic progression

Vidhya C., Kaushik Murali, Sowmya R.

*Pediatric Ophthalmology and Strabismus Department, Sankara Eye Hospitals, Bangalore, India*

## Abstract

**Aim:** To evaluate safety and efficacy of reconstituted atropine 0.01% eye drops for Indian children with myopic progression.

**Methods:** Fifty children with progressive myopia with their spherical equivalent increasing at least 0.75 D in 6 months (0.75 to 1.50 D) were put on reconstituted atropine 0.01%. Ocular examination, including near vision, near point of accommodation (NPA), pupil size and axial length, was done. Subjective symptoms of glare and photophobia were noted. Systemic side effects were documented. Analysis was done using Microsoft Excel 2010.

**Results:** The average age of patients was 9.5 years (range 5 to 14 years) and they were followed up for 1 year. Average mesopic and photopic pupil size was 5 and 4 mm, respectively. Average NPA was 9 cm. Mean increase in spherical equivalence was 0.18 D over 6 months. Average increase in axial length was  $0.12 \pm 0.11$  mm over 6 months and  $0.2 \pm 0.29$  mm over 1 year. Average increase in spherical equivalent over 6 months was  $0.07 \pm 0.19$  D and over 1 year was  $0.32 \pm 0.29$  D. No systemic side effects were recorded.

**Conclusion:** Reconstituted atropine 0.01% eye drops is safe and efficacious in slowing the progression of myopia in Indian children.

## Introduction

Myopia is one of the most common ocular disorders in the world and considered to be the leading cause of visual impairment.<sup>1</sup> Various prevalence studies have shown a substantial increase in myopia among adolescents and it is now thought to be approaching 10% to 25% in the West and 60% to 80% in the East.<sup>2</sup> Various surveys in India have found myopia prevalence ranging from 6.9% to 19.7%.<sup>3,4</sup>

At present, the mechanisms involved in the aetiology of myopia are unclear and both environmental and genetic factors have been associated with the onset and progression of myopia.<sup>1,5,6</sup>

**Correspondence:** Dr. Vidhya C., MS, FPOS, FAICO, Pediatric Ophthalmology and Strabismus Department, Sankara Eye Hospitals, Varthur Main Road, Kundalahalli Gate, 560037 Bangalore, India.

E-mail: dr.optho.vidhya@gmail.com

Atropine eye drops were first proposed as a treatment of myopia in the 1920s. Since then, there have been numerous studies on this subject. However, evidence from randomized controlled trials has become available only over the last two decades. These trials confirm that atropine eye drops are effective in the control of myopia in a dose-dependent manner.<sup>7-10</sup>

The broad-band muscarinic antagonist, atropine, is believed to have a therapeutic effect in reducing the progression of axial myopia in humans via a non-accommodative mechanism. It is still unclear, however, whether long-term atropine usage would alter the retinal function via two possible mechanisms, namely retinal toxicity and photic retinopathy.<sup>11</sup>

While ATOM2 study showed the efficacy of low-dose atropine of 0.01%, there is little evidence of low-dose atropine in preventing myopic progression in Indian children. Also, with not many commercial preparations, reconstituted atropine 0.01% as an alternative need to be studied. A study was undertaken to evaluate the safety and efficacy of reconstituted atropine 0.01% used daily in children with progressive myopia.

## **Materials and methods**

The study was approved by our hospital's ethics committee and informed consent was obtained from the parents regarding the off-label use of the drug and that a reconstituted preparation was being used.

Reconstitution was done under aseptic precautions and laminar flow by mixing 0.1 ml of atropine 1% (Atrosulph Eye Drops, Entod Pharmaceuticals Ltd., Mumbai, India) into 10 ml of carboxymethylcellulose eye drops 5 mg/ml (Extralube Eye Drops, Microlabs Limited, Mumbai, India) and the drops were to be used within 1 month of reconstitution.

A prospective study was conducted enrolling 50 children presenting to the paediatric ophthalmology outpatient department, between 5 and 15 years with a minimum base line refractive error  $-2$  D (spherical power) with progressive myopia where progression was defined as documented increase of myopia by 0.75 D or more within a period of 6 months.

Children with severe congenital or developmental delay or systemic diseases, inability to communicate or undertake a complete ophthalmic examination or with conditions in the eye affecting visual acuity (apart from the refractive error) were excluded.

Enrolled patients underwent a comprehensive eye examination and the following tests:

- visual acuity with logMAR chart
- photopic pupil size using Optikon scout

- near point of accommodation (NPA) using RAF (Royal Air Force) ruler
- axial length recorded using Lenstar Biometry
- macular thickness measured by spectral domain optical coherence tomography

All these values were taken as baseline values. Refractive error was documented as spherical equivalent.

All the selected children were given reconstituted atropine 0.01% eye drops to be applied one drop to each eye at night.

The above tests were repeated during each review visits every 3 months and subjective symptoms of glare to light and photophobia were elicited from the children. Findings at 6 months and at final follow-up (9 to 16 months) was taken for analysis.

Children and parents were also asked if the atropine eye drops were acceptable to the child as a long-term medication and if it interfered with their daily tasks resulting in discontinuation.

Any systemic side effects were elicited and documented. Possibility of contamination was ruled out by sending 10 eye drop samples for culture on blood agar when the eye drop bottle was returned after use for 1 month.

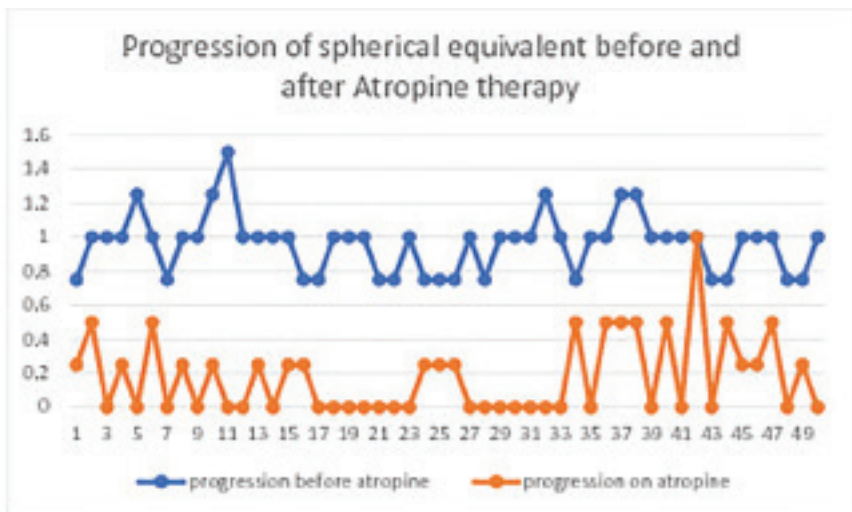


Fig. 1. Progression of spherical equivalent before and after starting atropine therapy over 6 months.

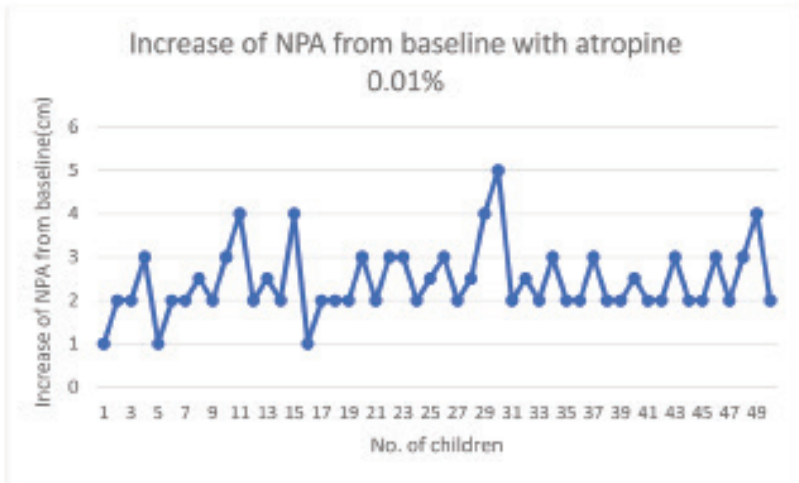


Fig. 2. Average increase of NPA (cm) with atropine 0.01% at the end of 6 months.

## Results

The average age of the patients was 9.5 years (range 5 to 14 years). The average follow-up was 1 year (range 10 to 16 months). Thirty-five children completed the 1-year follow-up.

Average spherical power was 5.5 D (range 3 to -9.5 D) with a mean progression of 1.0 D per 6 months (range 0.75 to 1.50 D) before starting atropine eye drops (Fig. 1). Mean best-corrected visual acuity on presentation and at every follow-up was 0.1 logMAR and near vision in all patients was N6 equivalent. Slit-lamp examination showed no evidence of any conjunctival congestion or corneal affliction at any visits. No systemic side effects were recorded.

Average photopic pupil size recorded on atropine therapy was 3.5 mm and a difference of 0.5 mm noted from baseline value.

Average NPA was 9 cm while on atropine 0.01%. Average increase of NPA from baseline was  $2.44 \pm 0.79$  cm (Fig. 2).

Average increase in axial length was  $0.12 \pm 0.11$  D over 6 months and  $0.2 \pm 0.29$  D over 1 year (p value = 0.36). Average increase in spherical equivalent over 6 months was  $0.07 \pm 0.19$  D and over 1 year was  $0.32 \pm 0.29$  D (p value = 0.32).

There was no significant difference noted in the macular thickness after 1 year of atropine 0.01% usage (p value = 0.3).

Five children had occasional glare to light and four children had occasional photophobia, not requiring any treatment for the same. One child had progression of 1.0 D over 6 months period while on atropine 0.01% eye drops.

All cultures were negative.

Table 1. Comparison of our study results with ATOM2 study using various concentrations of atropine

Parameters	Our study (Atropine 0.01%)	ATOM2 (Atropine 0.01%)	Atropine 0.1%	Atropine 0.5%
Allergic conjunctivitis	Nil	Nil	Present in 4.1%	Present in 4.1%
Children using progressive photochromatic glasses	Nil	6%	All	All
Spherical equivalent increase over 1 year (D)	0.32 ± 0.29	0.43 ± 0.52	0.31 ± 0.50	0.17 ± 0.47
Axial length increase over 1 year (mm)	0.2 ± 0.29	0.24 ± 0.19	0.13 ± 0.18	0.11 ± 0.17

## Discussion

Atropine at 1.0%, 0.5%, and 0.01% has been demonstrated through randomized trials to be effective in slowing myopia progression.<sup>12</sup> Apart from effectiveness of medication, the long-term use of any medication calls for attention with regards to tolerability and compliance. However, the safety profile of atropine (systemic side effects and visual disturbances) often has been a source of concern and deterred many from using this medication.

Every unit increase in pupil size results in an exponential increase in the amount of light entering the eye, and this can cause glare and potential phototoxicity. Atropine, by its dilating and cycloplegic effect, might cause retinal phototoxicity and near vision problems necessitating the need for bifocal or progressive glasses for reading.

Atropine 0.01% has been proven to be effective in controlling progression of myopia. But atropine 0.01% was not commercially available when we started the study. If atropine needs to be used as a part of our clinical practice, it would need to be reconstituted. Contamination of the eye drops on storage becomes an additional concern apart from those listed above.

Our study collaborated findings of others<sup>13-15</sup> in the absence of any systemic side effects with daily use over a period of 16 months. Atropine 0.01% was effective in reducing the progression of myopia by 91%. There were no gross vision disturbances affecting their day-to-day life. All the children had near vision of N6

equivalent. The retinal thickness remains unaffected by 1-year usage of the drug. There was no contamination of the eye drop at the end of 1 month.

The differences of our result from ATOM2 study may be due to the small sample size (Table 1).

There are some limitations in our study. First, this study is not a double-blind randomized design. Second, the small sample size and relatively short follow-up time are noted in our study. Long-term side effects may be apparent in a long period of follow up.

The lowest concentration of 0.01% atropine thus seems to retain efficacy in Indian children with darker iris and is a viable concentration for reducing myopia progression in children while being well-tolerated and safe from adverse effects. Even if this concentration is not commercially available in a locality, it can be safely reconstituted under laminar flow and used for controlling myopia progression in children.

## **Conclusion**

Atropine 0.01% eye drops is safe and efficacious in controlling myopia progression in Indian children. Even if the commercially available preparation is not available, reconstituted atropine eye drops can be safely used.

## **References**

1. World Health Organization. Elimination of Avoidable Visual Disability due to Refractive Errors (WHO/PBL/0079). Geneva, Switzerland: World Health Organization; 2000:Vision 2020.
2. Saw S-M. A synopsis of the prevalence rates and environmental risk factors for myopia. *Clin Exp Optom*. 2003;86:289-294.
3. Jain IS, Jain S, Mohan K. The epidemiology of high myopia—changing trends. *Indian J Ophthalmol*. 1983;31:723-728.
4. Mohan M, Pakrasi S, Zutshi R. Myopia in India. *Acta Ophthalmol Suppl*. 1988;185:19-23.
5. Goss DA, Hampton MJ, Wickham MG. Selected review on genetic factors in myopia. *J Am Optom Assoc*. 1988;59:875-884.
6. Mutti DO. Myopia—the nature versus nurture debate goes on. *Invest Ophthalmol Vis Sci*. 1996;37(6):952-957.
7. Yen MY, Liu JH, Kao SC, Shiao CH. Comparison of the effect of atropine and cyclopentolate on myopia. *Ann Ophthalmol* 1989;21:180-182, 187.
8. Shih YF, Chen CH, Chou AC, et al. Effects of different concentrations of atropine on controlling myopia in myopic children. *J Ocul Pharmacol Ther*. 1999;15:85-90.
9. Shih YF, Hsiao CK, Chen CJ, et al. An intervention trial on efficacy of atropine and multi-focal glasses in controlling myopic progression. *Acta Ophthalmol Scand*. 2001;79:233-236.
10. Chua WH, Balakrishnan V, Chan YH, et al. Atropine for the treatment of childhood myopia. *Ophthalmology*. 2006;113:2285-2291.
11. Luu CD, Lau AM, Koh AH, Chua WH, Balakrishnan V, Tan D. Effects of long term atropine usage on retinal function. *Invest Ophthalmol Vis Sci*. 2003;44:4790.
12. Chia A, Chua W-H, Cheung Y-B, et al. Atropine for the treatment of childhood myopia: safety and efficacy of 0.5%, 0.1%, and 0.01% doses (atropine for the treatment of myopia 2). *Ophthalmology*. 2012;119(2):347-354.

13. Wu PC, Yang YH, Fang PC. The long-term results of using low concentration atropine eye drops for controlling myopia progression in schoolchildren. *J Ocul Pharmacol Ther.* 2011;27(5):461-466.
14. Loughman J, Flitcroft DI. The acceptability and visual impact of 0.01% atropine in a Caucasian population. *Br J Ophthalmol.* 2016;100(11):1525-1529.
15. Nishiyama Y, Moriyama M, Fukamachi M, et al. Side effects of low dose atropine. *Nippon Ganka Gakkai Zasshi.* 2015;119(11):812-816.



# Successful management of intralenticular Ozurdex injection causing cataract and intractable glaucoma

Kalpa Negiloni, Ronnie Jacob George, Sridharan Sudharshan, Shweta Tripathi

Medical Research Foundation, Sankara Nethralaya, Chennai, Tamil Nadu, India

## Abstract

A 50-year-old female presented with profound vision loss and was previously advised injection Ozurdex in the left eye. In the left eye, the anterior chamber was quiet, intraocular pressure (IOP) was 58 mmHg and cataractous changes were noted with Ozurdex implant inside the lens substance. The left eye had glaucomatous cupping (0.9:1 CDR), bipolar rim thinning, inferior notch and healed choroiditis. The patient underwent phacoemulsification, trabeculectomy and mitomycin-C in the left eye. Visual acuity improved and IOP was under control. Although Ozurdex is effective, there are reports of complications related to the drug and implantation procedure. This case highlights an uncommon complication of an uncontrolled, persistent steroid response leading to glaucomatous optic atrophy and profound vision loss due to an accidental intralenticular implantation of Ozurdex. Our case reinforces the need for caution about the decision regarding the judicious use of intravitreal steroids and employment of appropriate technique.

**Keywords:** glaucoma, intravitreal corticosteroid implant, intralenticular Ozurdex, Ozurdex, posterior uveitis

## Introduction

Intravitreal corticosteroid implants are widely available options for the treatment of macular oedema, non-infectious posterior uveitis, diabetic retinopathy, retinal venous occlusions and others. Ozurdex® (Allergan, Inc., Irvine, CA, USA), the dexamethasone (DEX) drug delivery system, is a biodegradable intravitreal implant that delivers a sustained release of 700 µg preservative-free DEX to the retina and vitreous.<sup>1,2</sup> Although Ozurdex has been effective, there are reports of several complications related to the drug and the implantation procedure itself, such as its dislocation into the anterior chamber, accidental entry into the crystalline lens, increased intraocular pressure (IOP) and retinal detachment. We describe the successful management of a patient with increased IOP, advanced

**Correspondence:** Sridharan Sudharshan, 18, College Road, Nungambakkam, Chennai 600006, Tamil Nadu, India.

Phone: +91 44 2727 1616

E-mail: [drdharshan@gmail.com](mailto:drdharshan@gmail.com)

glaucomatous cupping and cataract due to accidental intralenticular injection of Ozurdex treated for geographic helicoid peripapillary choroiditis (GHPC). Our case highlights and reinforces the need for caution about the decision regarding the judicious use of intravitreal steroids and employment of appropriate technique.

### Case details

A 50-year-old female presented to us with diminished vision in the right eye since 10 years and left eye in the last 2 months. She had been diagnosed with GHPC in both the eyes and had been administered injection Ozurdex in the left eye, 9 months ago. Her visual acuity recorded 2 months ago was 20/200 in the right eye and perception of light with inaccurate projection of rays in the left eye. The IOP was recorded as 11 and 38 mmHg in the right and left eye, respectively. At presentation to us, her best-corrected visual acuity was 20/60; N10 at 30 cm in the right eye and hand movements close to face with relative afferent pupillary defect in the left eye. The slit-lamp examination of the right eye was unremarkable. The left-eye anterior chamber was quiet, with cataractous changes and Ozurdex implant inside the lens substance with a visible posterior capsule entry site (Fig. 1). Posterior capsule break was noted from 4 to 7 o'clock position at the area of entry of Ozurdex in the left eye. The anterior capsule was not breached. Lens opacification was noted along the injection track. Clinically, no definite leakage of lens material into vitreous cavity was noted. The IOP was 12 and 58 mmHg in the right and left eye, respectively. The patient was on a combination of brimonidine and timolol twice daily and travoprost eye drops once daily in the left eye. She was on tablet acetazolamide thrice daily since a month. The gonioscopy revealed open angles in the right eye and closed angles in all quadrants which opened easily on compression with no Peripheral anterior synechiae in left eye. The retinal evaluation showed a healthy disc and healed choroiditis in the right eye. The left eye showed glaucomatous cupping with a 0.9:1 CDR, bipolar rim thinning, inferior notch and healed choroiditis. Investigations revealed raised ESR (32 mm), normal chest X-ray and negative rapid plasma reagin, Mantoux and Treponema pallidum haemagglutination tests. The patient underwent a combined procedure of phacoemulsification with foldable intraocular lens implantation and trabeculectomy with mitomycin C application under local anaesthesia. There were no intraoperative or post-operative complications. Post-operatively, the IOP was 6 mmHg on first day and was maintained at 18 mmHg at 1 week and thereafter. Her visual acuity improved to counting fingers at 3 m. The post-operative period was uneventful. Topical steroids were tapered and stopped.

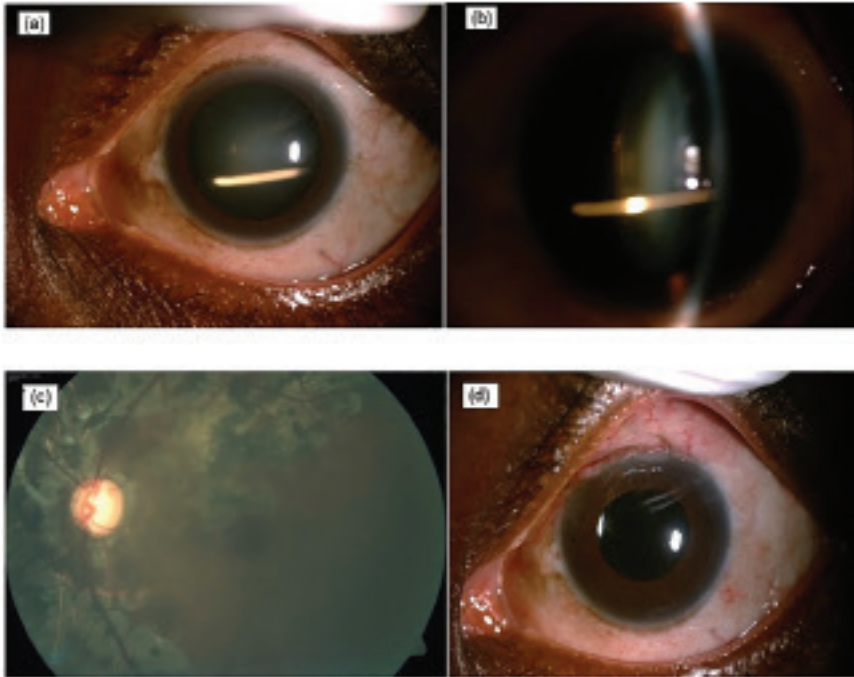


Fig. 1. Intralenticular Ozurdex implant in the left eye. (a and b) Intralenticular Ozurdex implant in the left eye. (c) Left eye fundus showed glaucomatous cupping, cup–disc ratio of 0.9 with bipolar rim thinning and patches of healed choroiditis. (d) Post-phacoemulsification with posterior chamber intraocular lens.

## Discussion

Intravitreal corticosteroid implants have been used in the treatment of non-infectious intermediate, posterior and panuveitis with better safety profile. Commonly available intravitreal implants are biodegradable or non-biodegradable drug delivery systems such as Retisert, Iluvien and Ozurdex. These provide a sustained release of the drug to the posterior and intermediate segments of the eye.<sup>3,4</sup>

Ozurdex® (Allergan, Inc, Irvine, CA, USA) DEX drug delivery system is a biodegradable intravitreal implant that delivers sustained release of 700 µg preservative-free DEX to the retina and vitreous.<sup>1</sup> The procedure is performed under controlled aseptic conditions and adequate anaesthesia to the periorcular skin, eyelid and ocular surface. The tip of the needle of the Ozurdex injection is advanced within sclera for about 1 mm and redirected towards the centre of the eye until the vitreous cavity is entered.<sup>1</sup>

DEX implants have potential advantages of easy implantation, less frequent dosing, minimal side effects and biodegradability. There are anecdotal case reports of accidental entry of intravitreal implants to crystalline lens causing lens damage. The surgical intervention of cataract following intralenticular implantation has been managed variously by different authors. The decision of cataract surgery has depended on various factors such as the presence or absence of macular oedema and associated IOP (IOP). Surgery has been planned after resolution of macular oedema and till medical control of IOP<sup>5,6</sup> or when vision drop was significant due to cataract.<sup>7</sup>

It is not always only the cataract that is the cause for vision loss but associated glaucoma too as was seen in our patient. In our case, Ozurdex was accidentally injected into the visual axis of the lens causing significant vision obstruction. Our patient also had a high IOP and was being managed medically elsewhere. The cause for profound vision loss in our patient was not only due to cataract but also due to glaucomatous changes of the disc secondary to raised persistent IOP.

In our patient, Ozurdex implant was injected accidentally into the visual axis of the lens causing profound vision loss due to cataract and intractable glaucoma. Our patient underwent phaco-trab as a treatment for both cataract and uncontrolled IOP. Our decision to plan the combined surgery was to prevent further irreversible loss due to glaucomatous optic nerve head damage.

In addition to cataractous change, our patient had severe intractable glaucoma when compared to other reported cases.<sup>8,9</sup> This could possibly be due to the anterior location of the implant closer to the trabecular meshwork which is sensitive to the steroid. An exaggerated response in our case could also be partly related to extensive synechial angle closure. This significant high rise in IOP combined with delayed surgical treatment could have led to glaucomatous optic atrophy and severe vision loss.

In patients without other major complications such as cataract or glaucoma, options of repositioning or removal of implant alone have also been considered by some authors, but this can add to the further stress to PC causing a risk of external tear, anterior vitrectomy may be required, or implant can split or migrate to the anterior chamber.<sup>5</sup> Intralenticular implantation could also be caused due to the use of larger diameter injectors that can cause considerable pressure on the globe and the pain experienced by the patient can provoke inadvertent eye or head movements.<sup>7,8,10,11</sup>

In our case, profound vision loss could be due to the presence of the implant in the visual axis, cataract or glaucomatous optic nerve head damage which needs early surgical intervention. In such cases, implant removal alone may not be sufficient. The interesting feature in our patient was that although Ozurdex was injected in our patient 9 months ago, the implant remained inside the lens without much

decay. The pharmacokinetics and pharmacodynamics of a sustained-release DEX implant have been studied in monkeys, and the authors have concluded that the implant resulted in sustained levels of DEX and biological activity for 6 months, with the peak concentration of drug during the first 2 months.<sup>12</sup> Although there is no definitive explanation for the long non-decay, in rare instances such as our cases the implant can remain like this inside the capsular bag for much longer time.

### Conclusion

It is important to advise Ozurdex in select cases of non-infectious type of intermediate or posterior uveitis as adjuvant therapy. It is helpful in the treatment of macular oedema, especially in patients not tolerating systemic medications. Appropriate technique needs to be employed, and if there is an accidental injection into the, then our case indicates that it needs to be managed immediately, both for the complicated cataract and the associated high IOP, thus preventing irreversible vision loss due to glaucoma. Our case highlights an uncommon complication of an uncontrolled, persistent steroid response leading to glaucomatous optic atrophy and profound vision loss due to an accidental intralenticular implantation of Ozurdex. An exaggerated IOP response may be seen following intralenticular injection, and in such an event, early cataract surgery with or without additional filtration procedure and removal of the implant could prevent irreversible vision loss. Although GHPC resolved with treatment, there was aggravated IOP and cataract which was managed successfully surgically. Uveitis patients may already be at risk for secondary glaucoma aggravated by the use of steroids, and intravitreal steroids need to be used with caution. It is also important that the appropriate technique of implantation be followed to avoid such accidental injections which can result in irreversible visual complications.

### References

1. Ozurdex® (Allergan, Inc, Irvine, CA, USA). <http://www.ozurdex.com/>. Last accessed 15 January 2018.
2. Haller JA, Kuppermann BD, Blumenkranz MS, et al. Dexamethasone DDS phase II study group. Randomized controlled trial of an intravitreal dexamethasone drug delivery system in patients with diabetic macular edema. *Arch Ophthalmol*. 2010;128(3):289-296.
3. Myung JS, Aaker GD, Kiss S. Treatment of noninfectious posterior uveitis with dexamethasone intravitreal implant. *Clin Ophthalmol*. 2010;4:1423-1426.
4. Ghosn CR, Li Y, Orilla WC, et al. Treatment of experimental anterior and intermediate uveitis by a dexamethasone intravitreal implant. *Invest Ophthalmol Vis Sci*. 2011;52(6):2917-2923.
5. Sekeroglu MA, Anayol MA, Koc F, Tirhis H, Ozkan SS, Yilmazbas P. Intralenticular sustained-release dexamethasone implant: is it still effective on macular edema. *Case Rep Ophthalmol*. 2016;7(1):85-89.
6. Coca-Robinot J, Casco-Silva B, Armadβ-Maresca F, García-Martínez J. Accidental injections of dexamethasone intravitreal implant (Ozurdex) into the crystalline lens. *Eur J Ophthalmol*. 2014;24:633-636.

7. Fasce F, Battaglia Parodi M, Knutsson KA, et al. Accidental injection of dexamethasone intravitreal implant in the crystalline lens. *Acta Ophthalmol.* 2014;92:e330, e331.
8. Ram J, Agarwal AK, Gupta A, Gupta A. Phacoemulsification and intraocular lens implantation after inadvertent intracapsular injection of intravitreal dexamethasone implant. *BMJ Case Rep.* 2012;12:2012.
9. Sheen OS, Gepstein R, Assia El. Intralenticular Ozurdex implant: a case report. *Clin Surg.* 2017;2:1556.
10. Munteanu M, Rosca C. Repositioning and follow-up of intralenticular dexamethasone implant. *J Cataract Refract Surg.* 2013;39:1271-1274.
11. Roy R, Hegde S. Split Ozurdex implant: a caution. *Can J Ophthalmol.* 2013;48(1):e15, e16.
12. Chang-Lin JE, Attar M, Acheampong AA, et al. Pharmacokinetics and pharmacodynamics of a sustained-release dexamethasone intravitreal implant. *Invest Ophthalmol Vis Sci.* 2011;52(1):80-86.

# Fish hook injury to the eye and its management

Sangeetha Jeganathan, Suneetha Nithyanandam, Reji K. Thomas,  
Shubashree Karat

*Department of Ophthalmology, St Johns Medical College and Hospital,  
Bangalore, India*

## Abstract

*The most common cause of unilateral blindness in paediatric age groups, especially in developing countries, is ocular trauma. Trauma to the eye is very debilitating to the patient; hence, managing various types of penetrating and blunt injury to the eye provide a challenge to the ophthalmologist. It is simply preventable by the supervision of the parents and caregivers. We will be discussing one such case and our experience in dealing with a fish hook injury to the eye in a 12-year-old boy—the challenges we faced and the precautions we took to give a good visual outcome.*

**Keywords:** *advance-and-cut technique, fish hook, open globe injury, visual outcome*

## Introduction

Ocular trauma, although not an everyday encounter for many ophthalmologists, is a serious problem for our health system and economy.<sup>1,2</sup> Ocular injuries can occur in any setting, including recreational and sports-related activities, the workplace, the home, rural agricultural settings, motor vehicle accidents and intentional altercations. The personal impact of ocular injury is difficult to define, although the lifestyle of the affected individual may be permanently altered. In addition to the visual concerns, ocular trauma levies a tremendous financial penalty in terms of both direct and indirect costs. During the last several decades, the prognosis for patients with ocular injuries, especially those with open globe injuries, has significantly improved. This has been attributed to the advent of enhanced microsurgical techniques and instrumentation, along with an improved understanding of the pathophysiological mechanisms of ocular trauma, as well as the availability of new antibiotics which can achieve good intraocular concentrations. Eye injuries can be greatly reduced by promoting the concept of prevention by the ophthalmologist. To do an effective job of prevention, the ophthalmologist must have knowledge of the eye injury potential, a particular patient may experience and the proper protective devices that are available to prevent the same.

**Correspondence:** Dr. Sangeetha Jeganathan,  
Department of Ophthalmology, St Johns Medical College and Hospital, Sarjapur Main  
Rd, John Nagar, Koramangala, Bengaluru, Karnataka 560034, Bangalore, India.  
E-mail: [drjsangs81@gmail.com](mailto:drjsangs81@gmail.com)

## Case report

A 12-year-old boy presented to us at the emergency with history of foreign body in the left eye while fishing. He complained of minimal discomfort and diminution of vision.

On examination, his visual acuity was 20/20 in right eye and finger counting close to face in left eye with accurate projection of rays. Anterior segment of the left eye showed a fish hook passing through the limbus with the entry point at 9 o'clock and exit point at 6 o'clock position as shown in Figure 1. There was associated subconjunctival haemorrhage in the area. Siedel's test was negative. Cornea was clear without any tear and anterior chamber was well formed with no signs of inflammation or hyphaema. Pupil was brisk reacting briskly to direct and consensual light reflex. Lens was clear and fundus was normal. The intraocular pressure (IOP) at presentation was 16 mmHg. Computed tomography (CT) orbit showed a fish hook passing at the limbus through the uveal tissue and with the barbed end at the exit as shown in Figure 2.

We got a clearance from the anaesthetist and took up the child for removal of the fish hook and primary repair under general anaesthesia. A peritomy was done and wound explored, and in view of the arrowhead-shaped hook, it was decided to pull the hook out through the exit wound to prevent ripping up of the tissues by the arrow head. As the hook was lodged in the ciliary body zone,

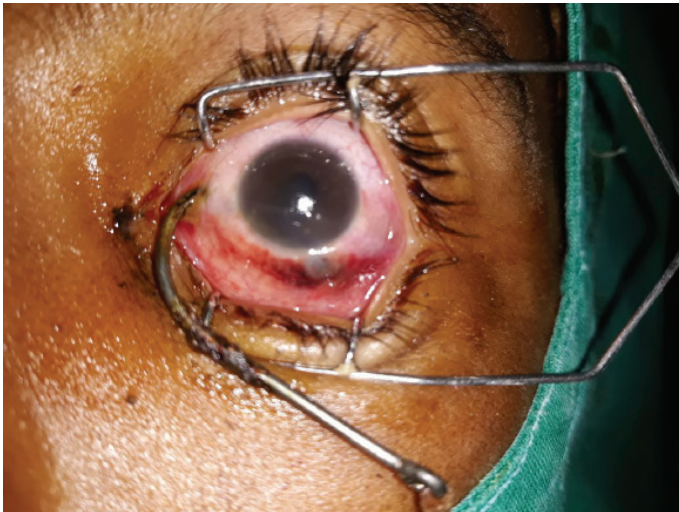

Fig. 1. Photograph showing the barbed fish hook penetrating the limbus at 9 o'clock position and exit point seen at 6 o'clock position.



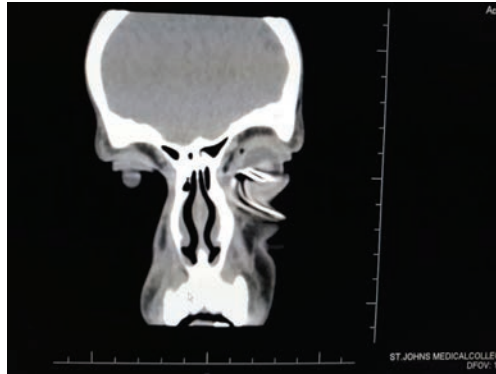


Fig. 2. CT orbit showing the end on view of the fish hook embedded in the eye.

cryotherapy was done around the hook to prevent and minimize the bleeding during the removal of the hook. Following cryotherapy, the metallic knob at the entry site was cut using bone cutter (Fig. 3), then the hook was slowly pushed out of the exit site; however, this was not fruitful as the hook was deeply imbedded and there was bleeding during the manoeuvre. Hence, using a 15-number BP blade, we made an incision along the shank of the hook at the inferior limbus and extracted the hook. The wound was sutured with 10-0 Ethilon. Hyphaema was noted at the end of the surgery. Intravitreal injection of vancomycin and amphotericin was given to prevent infection. Post-operative day 1 showed corneal haze inferiorly with hyphaema—as shown in Figure 3.

Post-operatively he developed cataract which self-absorbed over a period of 2 months. His vision with +10 was 6/12 with normal fundus. The parents were counselled regarding the need for a secondary intraocular lens later, once the bag underwent fibrosis as the zonules were damaged inferiorly along the entire tract of the hook. No IOP or retina abnormalities were observed during the follow up.

## Discussion

A barbed fish hook embedded in the eye is daunting to both patient and the ophthalmic surgeon.<sup>3</sup> Large intraocular foreign bodies are associated with poor visual prognosis.<sup>4</sup> Fish hook injuries to the eye can involve the eyelids and the anterior or posterior segments. Aiello et al. described four main techniques to remove the fish hook.<sup>5</sup> (a) The back-out or retrograde method—this usually causes excessive damage during the extraction of the hook; (b) snatch or string-yank technique, (c) advance-and-cut technique which is what we used in

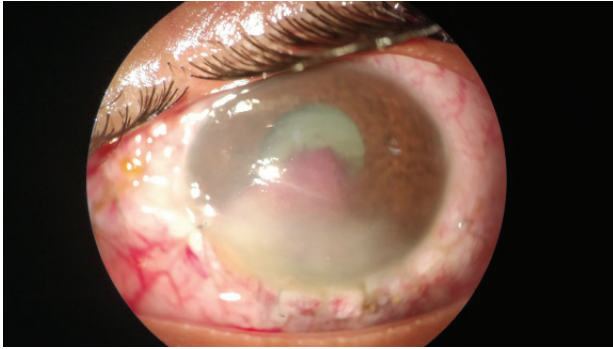


Fig. 3. Eye on post-operative day 1 showing hyphaema, traumatic cataract and inferior corneal haze.

our patient and (d) the needle-cover technique which is preferred for hooks that have penetrated the retina.

The manoeuvre of pushing the hook out through the eye is the same movement used in manipulating a curved suture needle. The shaft of the hook should be left long to facilitate manipulation. The extraocular barbs should be removed and this will require powerful steel cutters. This is called the advance-and-cut technique described by Ahmad et al.<sup>6</sup> The use of cryotherapy in our patient helped minimize the bleed that would have occurred as the hook was imbedded at the limbus along the ciliary zone. The challenge in this case was the technique of removing the foreign body, and assistance from orthopaedic department for cutting the dense metallic knob at the entry site and also to minimize the bleeding as the hook was situated at the most vascular part of the eye. If the manoeuvring was not delicate, there was a chance that the choroid and retinal tissue would be damaged which would have given a poor visual outcome. The cryotherapy on table also reduced the risk of dense haemorrhage.

## Conclusion

Management of ocular fish hook injuries can be daunting and very difficult for the ocular surgeon. These injuries often lead to poor visual prognosis; however, in some cases they may have a good long-term prognosis if prompt and appropriate surgical intervention is advocated. The advance-and-cut technique is a safe method to prevent damage to ocular tissues during removal of the hook. Cryotherapy adjacent to the shank of the hook in the scleral side prevented torrential bleed in this patient. The hook should be removed under careful examination using the correct technique. Also the shaft of the hook should be left long and no attempt should be made by non-trained personnel to remove it as doing so can

result in further damage. Although many forms of ocular trauma are preventable, ocular trauma will continue to represent a significant problem in the foreseeable future. Education and common sense can effectively reduce the number of ocular injuries and ophthalmologists can and should play a key role in the education of patients. It is not enough to merely tell a patient to use some eye protection, but rather prescribe a specific appropriate protective eyewear

### References

1. Cao H, Li L, Zhang M, Li H. Epidemiology of pediatric ocular trauma in the Chaoshan Region, China, 2001–2010. *PLoS One*. 2013;8:e60844.
2. Agrawal R, Laude A, Taneja M. Fish hook injury of the eye. *Int Ophthalmol*. 2012;32(3):269-271.
3. Bartholomew RS, MacDonald M. Fish hook injuries of the eye. *Br J Ophthalmol*. 1980;64:531-533.
4. Jonas JB, Knorr HL, Budde WM. Prognostic factors in ocular injuries caused by intraocular or retrobulbar foreign bodies. *Ophthalmology*. 2000;107(5):823-828.
5. Aiello LP, Iwamoto M, Guyer DR. Penetrating and ocular fish hook injuries: surgical management and long-term visual outcome. *Ophthalmology*. 1992;99(6):862-866.
6. Ahmad SS, Seng CW, Ghani SA, Lee JF. Cut it out technique for ocular fish-hook injury. *J Emerg Trauma Shock*. 2013;6(4):293-295.

# Pterygium excision with suture-less and glue-free conjunctival autograft

Fariha S. Wali, Muhammad Jawed, Rafeen Talpur,  
Naeemullah Shaikh, Shehnilla Shujaat, Khalid I. Talpur  
*Department of Ophthalmology, Sindh Institute of Ophthalmology and  
Visual Sciences, Hyderabad, Pakistan*

## Abstract

*Pterygium excision is a commonly encountered surgery with different methods being used. These procedures range from simple excision to use of grafts. Limbal conjunctival autograft is currently the most popular surgical procedure.*

*The most common method of autograft fixation is suturing. But it has its own drawbacks like increased operating time, post-operative discomfort, inflammation, buttonholes, necrosis, giant papillary conjunctivitis, scarring, and granuloma formation.*

*Glue is widely used due to many advantages like easy fixation of the graft, shorter operation time, and reduction in complications and post-operative discomfort but at the same time has some disadvantages also like high cost, the risk of transmission of infections and inactivation by iodine preparations.*

**Purpose:** *In the following study, we describe a simple method of accomplishing conjunctival autograft adherence during pterygium surgery avoiding possible complications associated with the use of fibrin glue or sutures.*

**Design:** *Prospective study.*

**Method:** *We used conjunctival autograft, which was not sutured or glued to the scleral bed. The fibrin formed from the oozing blood was used to get the graft adhesion to the scleral bed. This study was approved by institutional review board, and written consent form was taken from each participant.*

**Results:** *The suture-less and glue-free conjunctival autograft was found to have excellent results in terms of surgical outcome as well as post-operative recovery. In addition, risk of side effects related to sutures and glue was eliminated.*

**Conclusion:** *Suture-less and glue-free conjunctival autograft is a new, easy, and cheaper technique for the management of pterygium.*

**Keywords:** *conjunctival autograft, pterygium excision, suture-less, glue-free*

## Introduction

Pterygium is a triangular, vascular, fleshy growth that grows from conjunctiva to the corneal limbus and to the corneal surface.<sup>1</sup> Pterygium occurs more

**Correspondence:** Muhammad Jawed, Department of Ophthalmology, Sindh Institute of Ophthalmology and Visual Sciences, Hyderabad, Pakistan.  
E-mail: [jawedbiotech@yahoo.com](mailto:jawedbiotech@yahoo.com)

frequently in people who live in areas with high ultraviolet radiation, specifically UV\_B radiation.<sup>2</sup> Dusty, hot, dry, windy, and smoky environments also play a part. A hypothesis is that ultraviolet radiation causes mutations in the p53 tumour suppressor gene, thus facilitating the abnormal proliferation of limbal epithelium.<sup>3</sup> Most pterygia occur on the nasal side.<sup>4</sup>

In the disease process, pterygia are usually asymptomatic but there can be signs of dry eye such as burning, itching, or tearing as the lesion causes irregular wetting of the ocular surface.<sup>5</sup> The lesion can increase in size and become more apparent to the naked eye causing a cosmetic blemish. Further growth may cause visual symptoms due to induced astigmatism or direct encroachment onto the visual axis.<sup>6</sup> Pterygia less than 3 mm may induce some astigmatism. Lesions larger than 3 mm are likely to be associated with more than 1 D of astigmatism and often cause blurring of uncorrected vision.<sup>7</sup> All these indications make pterygium excision a frequently encountered surgery to ophthalmologists.

The objective of surgical excision is to completely remove the head, neck, and body of the pterygium. The most common technique was to leave to the sclera bare after pterygium excision. High post-operative recurrence led to adoption of adjuvant methods. Use of mitomycin C, beta irradiation, and anti-vascular endothelial growth factor has been employed to decrease the recurrence.<sup>8</sup>

Pterygium excision with ocular surface reconstruction is the current procedure of choice in view of its comparatively higher efficacy in preventing recurrence.<sup>9</sup> This included amniotic membrane grafting or use of conjunctival autograft.<sup>10</sup>

Free conjunctival autograft is now the most preferred method to prevent recurrence, being anatomically and physiologically similar to the tissue required.<sup>11</sup> The free graft including limbal stem cells act as a barrier to prevent the growth of fibrovascular tissue onto the cornea. To adhere the graft to the scleral bed, either sutures or fibrin glue is used.<sup>12,13</sup> The most common method of autograft fixation is suturing, but it increases operating time, post-operative discomfort, inflammation, buttonholes, necrosis, giant papillary conjunctivitis, scarring, and granuloma formation.<sup>14</sup> Glue enables easy fixation of the graft, shorter operation time, reduction in post-operative discomfort, but have some limitations such as high cost, risk of transmission of infections, and inactivation by iodine preparations.<sup>15</sup>

Suture-less and glue-free conjunctival autograft is a new, easy, and cheaper technique for the management of pterygium where the fibrin formed as a normal clotting process acts as a glue to hold the graft to the scleral bed.<sup>16,17</sup>

## Materials and methods

In the following prospective study, autologous limbal conjunctival grafting was done without sutures and glue. Our objective was to reduce patient discomfort by using suture-less and glue-free technique.

The study design was approved by the Institutional Review Board of Sindh Institute of Ophthalmology and Visual Science, Pakistan. Before recruitment, the objectives of the study were clarified to each individual, and written consent form was obtained. Principles of the Declaration of Helsinki were considered during the whole study.

**Inclusion criteria:** Patients of all ages and of either sex presenting with primary nasal pterygium.

**Exclusion criteria:** Recurrent pterygium, glaucoma, retinal pathology requiring surgical intervention, history of previous ocular surgery or trauma.

**Surgical technique:** Peribulbar anaesthesia with 2% lignocaine and 0.5% bupivacaine in 1:1 ratio was given pre-operatively. The body of the pterygium was dissected 4 mm from the limbus to achieve bare sclera. Pterygium was removed from the cornea by avulsion method.<sup>18</sup> Large haemorrhages were tamponade with direct compression. No cautery was done. Graft slightly larger than the scleral bed was marked from superotemporal limbus. The graft was resected with the help of conjunctival scissors. Care was taken to include as minimal of tenon capsule as possible. The graft was placed on bare sclera with limbus–limbus orientation. The graft was kept opposed to the scleral bed for 10 minutes by applying gentle pressure with fine non-toothed forceps. Small bleed in the scleral bed and small ooze of serum act as adhesive. Large bleeds can lift the graft from scleral bed and were tamponaded before placing the graft. Conjunctival fornix was painted with moxifloxacin eye drops and padded. Pad was removed after 48 hours.

## Results

Patients were followed post-operatively on the second post-operative day when the eye pad was removed, then after two weeks, and then at one month (Fig. 1A, 1B and 1C).

Out of 112 patients, two patients had slightly displaced grafts and two lost their graft. All the remaining patients with stable graft were kept on topical combination of tobramycin and dexamethasone eye drops. Patients with lost grafts were managed with bare sclera technique. To them, topical cyclosporine was added in addition to topical tobramycin and dexamethasone combination.

On second follow-up after two weeks, graft was found stable with decreased oedema and surrounding congestion. Patients with inferiorly displaced grafts had good enough adherence, and so did not require any further treatment.

At one-month follow-up, all patients had smooth conjunctival surface except two who had displaced grafts. In those two patients, conjunctiva was slightly folded inferiorly but the patients were symptom free. In a few patients, conjunctival wound gape was noted (Fig. 2A and 2B).

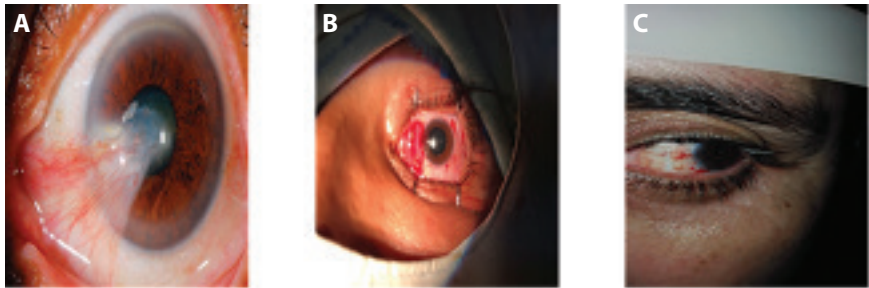


Fig. 1. A. Pre-operative picture of pterygium involving visual axis. B. Pre-operative picture of suture-less and glue-free conjunctival autograft. C. Two-days post-operative picture of suture-less and glue-free conjunctival autograft.

## Discussion

Pterygium is a commonly encountered problem in tropical regions and often needs to be surgically treated. Many different techniques and methods have been used to optimise pterygium excision. Post-excision inflammatory process leads to accumulation of fibroblasts, proliferation of vascular channels, and extracellular matrix deposition. This process leads to recurrence of pterygium.<sup>19</sup>

Out of the multiple surgical options and adjunctive medications, pterygium excision with autograft is associated with a lesser rate of recurrence.<sup>20</sup> This technique was first described by Kenyon *et al.*<sup>21</sup> This technique is much more demanding in terms of surgical expertise and proper graft orientation. The conjunctival autograft maintains the ocular surface smooth and also restores the normal anatomy and physiology of ocular surface. Conjunctival autograft comprises the limbal stem cells, which act as a barrier to conjunctival overgrowth.<sup>22</sup>

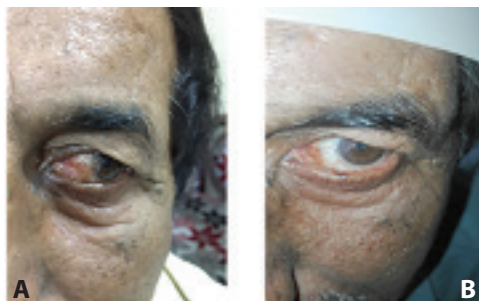


Fig. 2. A. Pre-operative and B. One-month post-operative picture after suture-less and glue-free conjunctival autograft.

Conjunctival autograft can be secured to the scleral bed with the help of sutures. Use of sutures demands increased operating time and is also associated with suture-related irritation, photophobia, and even granuloma formation. Use of fibrin glue is associated with ease, reduced surgical time, and early post-operative recovery. High cost, availability, and risk of transmission of infections and chronic inflammation are a few disadvantages associated with the use of fibrin glue.<sup>23</sup> Both techniques though gave excellent results with minimal recurrence, the challenges of having sutures or glue-related side effects led to the thought of using autologous fibrin.

Fibrin is formed in the blood when protease thrombin acts on fibrinogen. Fibrin forms long tough strands of insoluble protein that are bound to the platelets. The blood oozed in the scleral bed contains fibrin that helps adhere the graft to the bed.<sup>24</sup> Stark and co-workers stressed on having minimal tenon attached to conjunctival graft, which needs good dissection of conjunctiva from tenon. The graft is kept with limbus to limbus orientation and is left to adhere for 10 minutes. Suture-less and glue-free surgery takes lesser time and gives early post-operative recovery, associated with minimal side effects and negligible recurrence rates.

## Conclusion

Pterygium excision with conjunctival autograft is the most successful method in terms of reducing recurrence rate. Instead of using sutures or commercially available fibrin glue, fibrin formed on the scleral bed as a result of normal clotting cascade can be used for graft adherence. This suture-less and glue-free conjunctival autograft is cost effective, easy, and without risk of side effects due to foreign materials.

## References

1. Zloto O, Rosen N, Leshno A, Rosner M. Very long term success of pterygium surgery with conjunctival graft. *Cont Lens Anterior Eye*. 2017;40(4):267-269.
2. Gross J, Wegener AR, Kronschläger M, Holz FG, Schönfeld C-L, Meyer LM. Ultraviolet radiation exposure triggers neurokinin-1 receptor upregulation in ocular tissues in vivo. *Exp Eye Res*. 2018;174:70-79.
3. Mao L, Huang W, Zou P, Dang X, Zeng X. The unrecognized role of tumor suppressor genes in atrial fibrillation. *Gene*. 2018;642:26-31.
4. Arriola-Villalobos P, Cifuentes-Canorea P, Peraza-Nieves JE, et al. Fibrin glue conjunctival autograft for primary pterygium: Overall outcomes and outcomes in expert versus trainee ophthalmologists. *J Fr Ophthalmol*. 2018;41(4):326-332.
5. Messmer EM, von Lindenfels V, Garbe A, Kampik A. Matrix metalloproteinase 9 testing in dry eye disease using a commercially available point-of-care immunoassay. *Ophthalmology*. 2016;123(11):2300-2308.
6. Kheirkhah A, Safi H, Molaei S, Nazari R, Behrouz MJ, Raju VK. Effects of pterygium surgery on front and back corneal astigmatism. *Can J Ophthalmol*. 2012;47(5):423-428.
7. Spaide RF, Fujimoto JG, Waheed NK, Sadda SR, Staurengi G. Optical coherence tomography angiography. *Prog Retin Eye Res*. 2018;64:1-55.



8. Zarei R, Masoumpour M, Moghimi S, Fakhraei G, Eslami Y, Mohammadi M. Evaluation of topical bevacizumab as an adjunct to mitomycin C augmented trabeculectomy. *J Curr Ophthalmol.* 2017;29(2):85-91.
9. Mednick Z, Boutin T, Einan A, Sorkin N, Slomovic A. Simple limbal epithelial transplantation for recurrent pterygium: a case series. *Am J Ophthalmol Case Rep.* 2018.
10. Vlasov A, Sia RK, Ryan DS, et al. Sutureless cryopreserved amniotic membrane graft and wound healing after photorefractive keratectomy. *J Cataract Refract Surg.* 2016;42(3):435-443.
11. Akbari M, Soltani-Moghadam R, Elmi R, Kazemnejad E. Comparison of free conjunctival autograft versus amniotic membrane transplantation for pterygium surgery. *J Curr Ophthalmol.* 2017;29(4):282-286.
12. Brejchova K, Trosan P, Studeny P, et al. Characterization and comparison of human limbal explant cultures grown under defined and xeno-free conditions. *Exp Eye Res.* 2018;176:20-28.
13. Vazirani J, Mariappan I, Ramamurthy S, Fatima S, Basu S, Sangwan VS. Surgical management of bilateral limbal stem cell deficiency. *Ocul Surf.* 2016;14(3):350-364.
14. Messmer EM, May CA, Stefani FH, Welge-Luessen U, Kampik A. Toxic eosinophil granule protein deposition in corneal ulcerations and scars associated with atopic keratoconjunctivitis. *Am J Ophthalmol.* 2002;134(6):816-821.
15. Shwin KW, Lee C-CR, Goldbach-Mansky R. Dermatologic manifestations of monogenic autoinflammatory diseases. *Dermatol Clin.* 2017;35(1):21-38.
16. Elwan SAM. Comparison between sutureless and glue free versus sutured limbal conjunctival autograft in primary pterygium surgery. *Saudi J Ophthalmol.* 2014;28(4):292-298.
17. Kheirkhah A, Nazari R, Nikdel M, Ghassemi H, Hashemi H, Behrouz MJ. Postoperative conjunctival inflammation after pterygium surgery with amniotic membrane transplantation versus conjunctival autograft. *Am J Ophthalmol.* 2011;152(5):733-738.
18. Pérez-Silguero D, Díaz-Ginory A, Santana-Rodríguez C, Pérez-Silguero MA. Pterygium surgery and fibrin glue: avoiding dehiscence. *Arch Soc Esp Oftalmol (English Edition).* 2014;89(1):35-37.
19. Kim KW, Lee SJ, Kim JC. TNF- $\alpha$  upregulates HIF-1 $\alpha$  expression in pterygium fibroblasts and enhances their susceptibility to VEGF independent of hypoxia. *Exp Eye Res.* 2017;164:74-81.
20. Dhany R. Primary nasal pterygium excision with sutureless and glue-free technique of conjunctival autograft. *Asian J Ophthalmol.* 2019;16(3).
21. Kenyon KR, Wagoner MD, Hettinger ME. Conjunctival autograft transplantation for advanced and recurrent pterygium. *Ophthalmology.* 1985;92(11):1461-1470.
22. Soliman Mahdy MA, Bhatia J. Treatment of primary pterygium: role of limbal stem cells and conjunctival autograft transplantation. *Eur J Ophthalmol.* 2009;19(5):729-732.
23. Uy HS, Reyes JMG, Flores JDG, Lim-Bon-Siong R. Comparison of fibrin glue and sutures for attaching conjunctival autografts after pterygium excision. *Ophthalmology.* 2005;112(4):667-671.
24. Alston SM, Solen KA, Broderick AH, Sukavaneshvar S, Mohammad SF. New method to prepare autologous fibrin glue on demand. *Transl Res.* 2007;149(4):187-195.

# Improving the prediction of effective lens position for intraocular lens power calculations

Juanita N. Chui<sup>1,2</sup>, Keith Ong<sup>2,3</sup>

<sup>1</sup>Sydney Medical School, The University of Sydney, New South Wales, Australia;

<sup>2</sup>Royal North Shore Hospital, Kolling Institute, St Leonards, New South Wales,

Australia; <sup>3</sup>Department of Ophthalmology, Northern Clinical School, Faculty of Medicine, University of Sydney, New South Wales, Australia

## Abstract

**Purpose:** Achieving the desired post-operative refraction in cataract surgery requires accurate calculations for intraocular lens (IOL) power. Latest-generation formulae use anterior-chamber depth (ACD)—the distance from the corneal apex to the anterior surface of the lens—as one of the parameters to predict the post-operative IOL position within the eye, termed the effective lens position (ELP). Significant discrepancies between predicted and actual ELP result in refractive surprise. This study aims to improve the predictability of ELP. We hypothesise that predictions based on the distance from the corneal apex to the mid-sagittal plane of the cataractous lens would more accurately reflect the position of the principal plane of the non-angulated IOL within the capsular bag. Accordingly, we propose that predictions derived from ACD +  $\frac{1}{2}$ LT (length thickness) would be superior to those from ACD alone.

**Design:** Retrospective cohort study, comparing ELP predictions derived from ACD to a proposed prediction parameter.

**Method:** This retrospective study includes data from 162 consecutive cataract surgery cases, with posterior-chamber IOL (AlconSN60WF) implantation. Pre- and post-operative biometric measurements were made using the IOLMaster700 (ZEISS, Jena, Germany). The accuracy and reliability of ELP predictions derived from ACD and ACD +  $\frac{1}{2}$ LT were compared using software-aided analyses.

**Results:** An overall reduction in average ELP prediction error ( $PE_{ELP}$ ) was achieved using the proposed parameter (root-mean-square-error [RMSE] = 0.50 mm), compared to ACD (RMSE = 1.57 mm). The mean percentage  $PE_{ELP}$ , comparing between eyes of different axial lengths, was  $9.88\% \pm 3.48\%$  and  $-34.9\% \pm 4.79\%$  for predictions derived from ACD +  $\frac{1}{2}$ LT and ACD, respectively. A  $44.10\% \pm 5.22\%$  mean of differences was observed ( $p < 0.001$ ).

**Conclusion:** ACD +  $\frac{1}{2}$ LT predicts ELP with greater accuracy and reliability than ACD alone; its use in IOL power calculation formulae may improve refractive outcomes.

**Keywords:** anterior-chamber depth, cataract, cataract surgery, ELP, effective lens position, intraocular lens, IOL power, IOL power calculation formulae

**Correspondence:** Dr. Keith Ong, 2 Railway Avenue, Eastwood, New South Wales 2122, Australia.

E-mail: [keithong@optusnet.com.au](mailto:keithong@optusnet.com.au)

## Introduction

In cataract surgery, achieving the desired post-operative refraction depends on selecting the appropriate intraocular lens (IOL) power. In IOL power calculation formulae, corneal curvature, axial length (AL) and the post-operative position of the IOL implant within the eye, referred to as the effective lens position (ELP), play an important part in the prediction of the refractive outcome. While ocular biometrics can be measured pre-operatively, the post-operative ELP is predicted. Many formulae have been developed to predict the optical properties of the pseudophakic eye, yet accurately and reliably predicting ELP remains a challenge in modern IOL power calculations.<sup>1</sup> As such, improving the predictability of ELP should minimise refractive surprise and thereby improve refractive outcomes.

In IOL power calculations, it has been shown that inaccuracy in predictions of post-operative ELP represent one of the greatest sources of total refractive prediction error.<sup>1</sup> Many modern IOL power calculation formulae, including *Holladay II*, *Olsen*, *Barrett Universal II* and *Haigis*, use anterior-chamber depth (ACD) as one of the parameters to predict post-operative ELP.

The ACD measurement in optical biometry is defined by the distance from the apex of the cornea to that of the lens.<sup>2</sup> However, the principal plane of the non-angular biconvex IOL, in its intended position, should lie in the mid-sagittal plane of the capsular bag. In the phakic eye, this position approximates the mid-sagittal plane of the cataractous lens. This deviation from the theoretical post-operative position of the IOL may contribute to discrepancy between the predicted ELP based on ACD alone and the post-operative outcome, particularly when the IOL tends to be markedly thinner than the cataractous lens. Furthermore, the distance of the anterior surface of the lens from the corneal apex is subject to variations in lens thickness (LT) due to aging and pathology,<sup>3-5</sup> which may compromise ELP predictions.

In current methods, a range of assumptions, correction factors and optimisation processes are used to account for prediction error due to ocular biometric measurements and limitations of IOL power calculation formulae.<sup>6</sup> However, such assumptions bear an inherent degree of inaccuracy and optimisation of constants for regression minimises average error at best. Furthermore, predictions for post-operative refraction are known to vary between different IOL formulae. Not only does this contribute to the challenge in selecting the appropriate IOL power for cataract surgery, but to refractive surprise as well.<sup>7</sup> Such variation in predictions have been reported to be most prevalent in non-average eyes, such that those with extreme myopia and extreme hypermetropia are particularly prone to refractive surprise.<sup>8,9</sup>

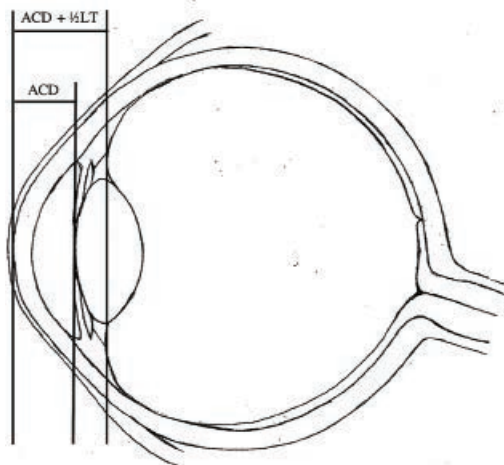
The present study aims to develop an algorithm to predict ELP with improved accuracy and precision for use in IOL power calculations. We propose an

approach based on structural geometry and anatomy of the anterior chamber of the eye rather than statistical associations between pre- and post-operative ocular biometric factors, as seen in many preceding IOL power calculation formulae.

### Hypothesis and proposed ELP prediction parameter

ELP defined as the distance from the anterior apex of the cornea to the mid-sagittal plane of the IOL optic may provide a more accurate model for prediction (Fig. 1). The position of the mid-sagittal plane of the phakic lens should closely approximate the principal plane of the non-angulated biconvex IOL within the capsular bag. Accordingly, we hypothesise that accounting for half the thickness of the cataractous lens in addition to ACD, according to the following algorithm, will help improve predictions for ELP:  $ACD + \frac{1}{2}LT$ .

Lens growth continues throughout life, such that ACD decreases as LT increases with age.<sup>5</sup> However, the distance from the corneal apex to the mid-sagittal plane of the cataractous lens should be relatively unchanged. This model should remove variation due to LT and more closely reflects the position of the IOL, in comparison to ACD, the predominant parameter for ELP prediction in current methods.



**Fig. 1.** Proposed ELP prediction model. The mid-sagittal plane of the natural lens is estimated to be positioned at half the value of its thickness from its anterior surface. This is hypothesised to align with the principal plane of the non-angulated biconvex IOL within the capsular bag.

Table 1. Post-operative IOL ELP prediction parameters

Current	ACD	The distance from the anterior surface of the cornea to the anterior surface of the IOL
Proposed	ACD + ½LT	The distance from the anterior surface of the cornea to the mid-sagittal plane positioned at half the thickness of the IOL

### Materials and methods

This study has received approval from the Northern Sydney Local Health District Human Research Ethics Committee and is in accordance with the National Health and Medical Research Council's National Statement on Ethical Conduct in Human Research 2007 and the CPMP/ICH Note for Guidance on Good Clinical Practice. This is a single-centre project, which has been assessed as low/negligible risk.

### Sample and data collection

This retrospective cohort study utilised pre- and post-operative data obtained from 162 consecutive cases of phacoemulsification and implantation of posterior-chamber IOL (Alcon SN60WF). Ocular biometric measurements for each case were obtained pre-operatively (1 week before surgery) and post-operatively (2 months after surgery) using the IOLMaster 700 with SWEPT source biometry (Carl Zeiss Meditec, Jena, Germany).

### Inclusion and exclusion criteria

Cases of phacoemulsification with posterior-chamber IOL implantation performed by Dr. Keith Ong, from the period of 1 August 2017 until 28 February 2018, were included. Patients who had undergone previous eye surgery, previous trauma to the eye or incomplete pre- and post-operative data were excluded from this study. The Alcon SN60WF implant, a biconvex IOL with planar (non-angulated) haptics, was used for all cases.

### Statistical methods

Predictions made using ACD were compared to those made using the proposed parameter, ACD + ½LT, for each case (Table 1). Residual analyses were performed for both prediction parameters. Average model ELP prediction error was compared through root-mean-square-error (RMSE) and coefficient of determination ( $R^2$ ) statistics.

The ELP prediction error ( $PE_{ELP}$ ) was determined by calculating the difference between the predicted ELP and the measured ELP post-operation for the two parameters:

$$PE_{ELP} = ACD_{pre-op} - ACD_{post-op}$$

$$PE_{ELP} = ACD + \frac{1}{2}LT_{pre-op} - ACD + \frac{1}{2}LT_{post-op}$$

To permit comparison of data obtained from eyes of different ALs,  $PE_{ELP}$  was compared as a percentage of the measured ELP to account for proportional bias:

$$\text{Percentage } PE_{ELP} = \frac{PE_{ACD}}{ACD_{post-op}}$$

$$\text{Percentage } PE_{ELP} = \frac{PE_{ACD + \frac{1}{2}LT}}{ACD + \frac{1}{2}LT_{post-op}}$$

Paired two-tailed *t*-tests were performed ( $\alpha = 0.05$ ) for mean  $PE_{ELP}$  and mean percentage  $PE_{ELP}$ . One-tailed one-sample *t*-tests were performed ( $\alpha = 0.05$ ) to determine directionality of  $PE_{ELP}$  for predictions derived from each parameter.

Data collected were entered into Microsoft Excel 2010 (Microsoft Corporation, Redmond, WA, USA). All analyses were performed with aid of software, GraphPad Prism 7 for Windows (GraphPad Software, La Jolla, CA, USA, [www.graphpad.com](http://www.graphpad.com)). Prior to applying parametric tests, D'Agostino-Pearson normality tests<sup>10</sup> were applied to all data sets.

## Results

### Study sample

A total of 162 consecutive cases (from 100 patients), undergoing phacoemulsification and implantation of posterior-chamber IOL (AlconSN60WF) during the 6-month study period, were analysed. Of these, 38 cases belonged to patients who undertook surgery on one eye and 124 cases to patients on both. There were 73 eyes of male patients (45%). Mean patient age was  $67.8 \pm 5.28$  years (range, 46 to 83 years) (Table 2). The mean AL was  $24.68 \pm 1.89$  mm (range, 21.72 to 32.99 mm).

Table 2. Patient characteristics

Variable	
No. of cases (patients)	162 (100)
One eye	38 (38)
Both eyes	124 (62)
Male	73 (45)
Female	89 (55)
Age (years)	
Mean $\pm$ SD	$67.8 \pm 5.28$
Range	46–83

Table 3. Characteristics of study sample

Variable	Pre-operation (1 week)		Post-operation (2 months)	
	Mean ± SD (mm)	SEM	Mean ± SD (mm)	SEM
ACD	3.02 ± 0.33	0.02	4.59 ± 0.29	0.02
LT	4.69 ± 0.36	0.03	0.61 ± 0.10	0.01
AL	24.68 ± 1.89	0.15		

Ocular biometric measurements were made using IOLMaster 700 (Zeiss, Australia), pre-operatively (1 week) and post-operatively (2 months) for all eyes analysed ( $n = 162$ ). SEM, standard error of mean.

A summary of the characteristics for eyes analysed are included in Table 3. Normality tests supported that sampled data, ELP prediction errors and pairs were sampled from a population where differences are consistent with a normal distribution ( $p < 0.05$ ).

### Residual error analysis

The RMSE performance and  $R^2$  statistic for ACD and ACD + ½LT predictions are presented in Figure 2. Performance metrics indicate that the proposed prediction parameter achieves a reduced average model prediction error (RMSE = 0.50,  $R^2 = 0.70$ ), as compared to ACD (RMSE = 1.57 mm,  $R^2 = 0.67$ ) (Fig. 2).

### Analysis of variance and hypothesis testing

The mean  $PE_{ELP}$  for predictions were  $-1.57 \pm 0.20$  mm for those derived from ACD + ½LT and  $0.48 \pm 0.16$  mm for those derived from ACD (Fig. 3a and Table 4). The difference between means of  $2.04 \pm 0.18$  mm between two prediction groups was statistically significant (95% CI = 2.02 - 2.07 mm;  $t = 142.3$ ,  $df = 161$ ;  $p < 0.0001$ ; Table 5).

Comparing  $PE_{ELP}$  as a percentage of the measured ELP to account proportional bias due to different AL of eyes, predictions made based on ACD alone demonstrated a mean  $PE_{ELP}$  of  $-34.22\% \pm 4.78\%$ , while predictions made using the proposed algorithm yielded a  $PE_{ELP}$  of  $9.88\% \pm 3.50\%$  (Fig. 3b and Table 4). Applying paired two-tailed  $t$ -test analysis, a mean of differences of  $44.10\% \pm 5.22\%$  was found to be statistically significant (95% CI = 43.30% - 44.91%;  $t = 107.6$ ,  $df = 161$ ;  $p < 0.0001$ ) (Table 5).

### Direction of error

One-tailed one-sample  $t$ -test analyses showed that predictions made using ACD uniformly underestimated outcomes (95% CI =  $-1.60$  to  $-1.53$  mm;  $t = -99.27$ ,  $df = 161$ ;  $p < 0.0001$ ), whereas predictions made using ACD + ½LT uniformly overestimated ELP (95% CI =  $0.45$  -  $0.50$  mm;  $t = 39.04$ ,  $df = 161$ ;  $p < 0.0001$ ) (Fig. 3). Both ELP prediction parameters demonstrated directionality in respective degrees of  $PE_{ELP}$ .

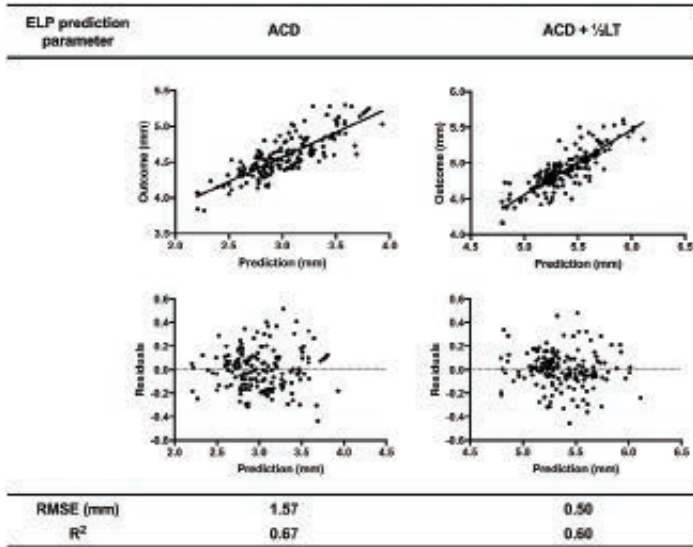


Fig. 2. Predicted vs. observed ELP (mm) (top) and graphs of residuals (bottom). RMSE and R<sup>2</sup> were used to evaluate average ELP prediction error.

### Discussion

The results of the present study demonstrate that improved accuracy for ELP predictions may be achieved using proposed parameter, ACD + 1/2LT, as compared to use of the ACD measurement alone. This thereby supports the hypothesis that accounting for half the value of LT improves estimations of the post-operative position of the IOL principal plane. Overall, a significant improvement in average error was achieved with the proposed prediction parameter (RMSE = 0.5 mm),

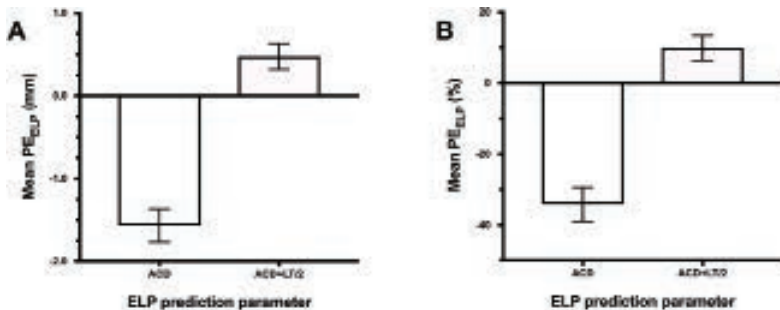


Fig. 3. Mean error of ELP predictions (n = 162). (a) The mean difference between the predicted ELP and the measured outcome. (b) The mean prediction error is shown as a percentage of the measured ELP post-operation to permit comparison between eyes of different ALs. Error bars represent standard deviation.



**Table 4. Comparison of post-operative ELP predictability for ACD alone and proposed parameter (n = 162)**

ELP prediction parameter	ACD	ACD + ½LT
Mean PE <sub>ELP</sub> ± SD (mm)	-1.56 ± 0.20	0.48 ± 0.16
SEM	0.02	0.01
Mean PE <sub>ELP</sub> ± SD (%)	-34.22 ± 4.78	9.88 ± 3.50
SEM	0.38	0.27

p-Value <0.05 was statistically significant.

compared to ACD (RMSE = 1.57 mm). Accounting for half the value of LT in addition to ACD resulted in a significant reduction in mean PE<sub>ELP</sub> compared to using ACD alone, from -1.57 ± 0.20 mm to 0.48 ± 0.16 mm (Fig. 2 and Table 5).

Currently, IOL power calculations are adjusted to minimise systematic error by the use of fudge factors and IOL constant optimisation processes<sup>11</sup>; however, these measures only improve prediction accuracy on average, by minimising error for eyes within a target range, but does not cater for the non-average eye. For this reason, IOL constants are known to vary with AL, and there is at present no single formula that can optimally predict IOL power for all eyes.<sup>12,13</sup> The success in reducing error by such means also depend in practice, on the baseline used for optimisation that varies with the patient cohort and approach; *Haigis*, for example, recommends the use of data from at least 50 eyes for optimisation.<sup>14</sup> In contrast, the proposed parameter should facilitate individualisation of ELP predictions by accounting for variations in LT. Measurements of ACD to the anterior surface of the lens are affected by LT, which the proposed parameter aims to overcome. By determining the position of the mid-sagittal plane of a biconvex lens, the effect of variations in thickness of phakic lenses on ELP predictions, are minimised.

While our results demonstrate a significant reduction in error for the proposed

**Table 5. Paired two-tailed t-test showing significance of differences between the means of PE resulting from the current and proposed ELP prediction parameters (n = 162)**

	Mean of differences (mm)	SEM of differences	p-Value	95% Confidence interval	
				Lower limit	Upper limit
Mean PE <sub>ELP</sub> ± SD (mm)	2.04 ± 0.18	0.01	<0.0001	2.02	2.07
Mean PE <sub>ELP</sub> ± SD (%)	44.10 ± 5.22	0.41	<0.0001	43.30	44.91

p-Value <0.05 was considered statistically significant.

parameter, they have not been eliminated. We acknowledge that while our model assumes that the IOL is perfectly biconvex, the human lens is not; the anterior surface tends to be more planar than the posterior.<sup>15</sup> With further analysis, however, our results demonstrate that  $PE_{ELP}$  observed with the use of  $ACD + \frac{1}{2}LT$  occurs in a single direction, as do predictions made using ACD. This residual error can therefore be systematically accounted for using current approaches; correction factors and optimisation of IOL constants used in current IOL power calculation formulae may still be applied.

Above all, our results also show a reduction in the spread of  $PE_{ELP}$ , indicating that ELP predictions were made with greater precision using the proposed parameter (3.50% SD), compared to using the ACD measurement alone (4.78% SD). This finding may hold greater implications than the reduction of error previously discussed, as while constant optimisation processes and fudge factors may correct for average error, the reliability of predictions (the dispersion of error around the mean) are unchanged by such measures.<sup>16</sup>

Overall, this preliminary study has demonstrated the potential for prediction of ELP based on the position of the mid-sagittal plane of the natural lens in the phakic eye to reduce inaccuracy and imprecision, compared to ACD alone. Despite statistically promising results, the potential and scope for clinical application of the proposed ELP prediction parameter will require further study. In this regard, the addition of half the value of LT represents a simple modification to current ELP predictions based on the ACD measurement, which may easily be applied to existing IOL power calculation formulae and constant optimisation processes. Additionally, IOL formulae using ACD, such as the *Haigis* formula, cannot be used in the pseudophakic eye when IOL exchange is required, while our proposed parameter would allow usage of such formulae. Finally, while the scope of the present study extends only to predicting the ELP of planar haptic IOL, applying the proposed model to angled haptic IOLs may be possible with a correction factor. It may thus be of interest for future studies to evaluate refractive outcomes when applying the proposed parameter, as well as its performance when applied to pseudophakic eyes and angulated haptics.

## Conclusion

Our small study demonstrated that the IOL ELP can more accurately and reliably be determined using  $ACD + \frac{1}{2}LT$ , as compared to ACD alone. The incorporation of the proposed parameter into current IOL power calculation formulae may therefore improve the predictability of post-operative refraction and thereby minimise refractive surprise in cataract surgery. In light of our present findings, we hope to explore the clinical applications of the proposed ELP prediction parameter in future studies.

## References

1. Norrby SJ. Sources of error in intraocular lens power calculation. *Cataract Refract Surg.* 2008;34(3):368-376.
2. Muthappan V, Paskowitz D, Kazimierczak A, Jun AS, Ladas J, Kuo IC. Measurement and use of postoperative anterior chamber depth of fellow eye in refractive outcomes. *J Cataract Refract Surg.* 2015;41(4):778-784. doi:10.1016/j.jcrs.2014.08.034.
3. Rosen AM, Denham DB, Fernandez V, et al. In vitro dimensions and curvatures of human lenses. *Vision Research.* 2006;46(6-7):1002-1009.
4. Jones CE, Atchison DA, Pope JM. Changes in lens dimensions and refractive index with age and accommodation. *Optom Vis Sci.* 2007;84(10):990-995.
5. Richdale K, Bullimore MA, Zadnik K. Lens thickness with age and accommodation by optical coherence tomography. *Ophthalmic Physiol Opt.* 2008;28(5):441-447.
6. Sheard R. Optimising biometry for best outcomes in cataract surgery. *Eye.* 2014;28(2):118-125.
7. Ong K, Feng L. Prevalence of variation in predicted refraction between different intraocular lens formulae. *Asian J Ophthalmol.* 2018;16:60-61.
8. Abulafia A, Barrett GD, Rotenberg M, et al. Intraocular lens power calculation for eyes with an axial length greater than 26.0 mm: comparison of formulas and methods. *J Cataract Refract Surg.* 2015;41(3):548-556. doi:10.1016/j.jcrs.2014.06.033.
9. Wong RS, Ong K. Influence of anterior chamber depth on postoperative refractive outcome in Chinese eyes. *Asian J Ophthalmol.* 2018;16:79-85.
10. D'Agostino RB. Tests for normal distribution. In: D'Agostino RB, Stepenes MA, eds. *Goodness-Of-Fit Techniques.* Boca Raton, FL: CRC Press.
11. Aristodemou P, Knox Cartwright NE, Sparrow JM, Johnston RL. Intraocular lens formula constant optimization and partial coherence interferometry biometry: refractive outcomes in 8108 eyes after cataract surgery. *J Cataract Refract Surg.* 2011;37(1):50-62.
12. Sanders DR, Retzlaff J, Kraff MC. Comparison of the SRK II formula and other second generation formulas. *J Cataract Refract Surg.* 1988;14(2):136-141.
13. Sahin A, Hamrah P. Clinically relevant biometry. *Curr Opin Ophthalmol.* 2012;23(1):47-53.
14. Haigis W. User group for laser interference biometry. <http://www.augenklinik.uni-wuerzburg.de/ulib/czm/dload.htm>. Accessed 9 September 2013.
15. Dubbelman M, Van der Heijde GL. The shape of the ageing human lens: curvature, equivalent refractive index and the lens paradox. *Vision Research.* 2001;41(14):1867-1877.
16. Olsen T. Improved accuracy of intraocular lens power calculation with the Zeiss IOLMaster. *Acta Ophthalmologica Scandinavica.* 2007;85(1):84-87.

# Asian Journal of OPHTHALMOLOGY

[www.asianjo.com](http://www.asianjo.com)  
[www.kuglerpublications.com](http://www.kuglerpublications.com)