

Using tropicamide and phenylephrine without cyclopentolate for pupil dilation in cataract surgery reduces postoperative intraocular pressure rise

Rachel Xuan¹, Keith Ong^{1,2,3,4,5}

¹Department of Ophthalmology, Royal North Shore Hospital, Sydney, Australia

²Northern Clinical School, University of Sydney, Sydney, Australia ³Chatswood Private Hospital, Sydney, Australia ⁴Sydney Adventist Hospital, Sydney, Australia

⁵Save Sight Institute, University of Sydney, Sydney, Australia

Abstract

The aim of this retrospective study was to evaluate whether intraocular (IOP) elevation post-cataract surgery can be reduced by using tropicamide and phenylephrine only, without cyclopentolate. Medical records across two surgical facilities were analyzed. One surgical facility (Cohort A) used a combination of tropicamide, cyclopentolate, and phenylephrine preoperatively, while the other (Cohort B) used tropicamide and phenylephrine only. Of patients in Cohort A, 63.6% ($n = 7$) had a higher IOP in the operated eye, while it was only 27.3% ($n = 3$) in Cohort B. Therefore, it is preferable to exclude the use of cyclopentolate in the preoperative dilation regimen of patients undergoing cataract surgery. However, a study with a larger sample population is required to further evaluate the significance of these results.

Keywords: cataract, cyclopentolate, intraocular pressure, pupil dilatation

Introduction

A combination of tropicamide, cyclopentolate and phenylephrine is commonly used for preoperative pupil dilation in cataract surgery. In addition, ketorolac can be included in the preoperative eye drop regimen or be given 24 hours prior to surgery to help maintain pupil dilation by blocking prostaglandin-induced pupil constriction.¹

In a day surgery operating facility, it is unlikely to experience delays in planned operating schedules. Hence, it may be appropriate to omit the longer acting cyclopentolate, using only tropicamide and phenylephrine preoperatively. The author (KO) has been using tropicamide, phenylephrine, and Acular (Allergan,

Correspondence: Dr. Keith Ong, MBBS, FRACO, FRACS, MMed, PGCert HE,
2 Railway Avenue, Eastwood, NSW 2122, Australia.
E-mail: keithong@hotmail.com.au

Australia) as part of the preoperative regimen in a private day surgery facility. However, in a general public hospital, cyclopentolate is included in the preoperative eye drop regimen as eye surgery can occasionally be delayed due to priority being given to more urgent, life-threatening surgery.

It has been noted that at Day 1 postoperative, the pupils were functioning normally and there was less intraocular pressure (IOP) elevation when cyclopentolate was excluded in the preoperative eye drop regimen. Hence, a retrospective audit of cases was conducted with and without the use of cyclopentolate in preoperative pupil dilation for cataract surgery.

Materials and methods

This study was a consecutive, retrospective audit of preoperative and postoperative IOP of patients in two surgical facilities. Cohort A consisted of 11 cataract surgery cases performed at Royal North Shore Hospital (RNSH), Sydney, Australia from March to September 2020. Cohort B consisted of 11 cataract surgery cases done at Chatswood Private Hospital (CPH), Sydney, Australia in August 2020. Patients with glaucoma were excluded in this study.

Centurion[®] Vision System (Alcon, Fort Worth, Texas, USA) was used at RNSH and Constellation[®] Vision System (Alcon, Fort Worth, Texas, USA) was used at CPH. All cases were routine cataract phacoemulsification with insertion of SN60WF (Alcon, Fort Worth, Texas, USA) posterior chamber intraocular lens (PCIOL). DuoVisc (Viscoat and ProVisc, Alcon, Fort Worth, Texas, USA) was used in all cases; Viscoat being employed during nucleus phacoemulsification and ProVisc employed for PCIOL insertion. All patients had removal of viscoelastic after PCIOL insertion with Simcoe Irrigation-Aspiration. Two drops of pilocarpine 2% were instilled after subconjunctival injection of cephazolin and dexamethasone. The principal operating surgeon was the same for all cases.

The preoperative and Day 1 postoperative IOP of the operated and non-operated eyes were obtained retrospectively. Patients had their operation between 8 am and 5 pm and were examined between 8 am and 10 am the days after. IOP was measured with Goldmann applanation tonometry (Haag-Streit, Bern, Switzerland).

Results

Patients routinely have the IOP of both eyes recorded preoperatively and postoperatively on Day 1; this information was obtained from the medical records. Postoperative IOP rise was defined as higher IOP in the operated eye compared to the non-operated eye, which served as a control.

Cohort A consisted of seven males and four females, while Cohort B consisted of three males and eight females. The range in age of patients in Cohort A was

62–88 years (average 67.9 years), while in Cohort B it was 58–85 years (average 68.8 years).

In Cohort A, the percentage of patients with a higher IOP in the operated eye on Day 1 postoperative was 63.6% ($n = 7$). In Cohort B, the percentage of patients with higher IOP in the operated eye was 37.3% ($n = 3$) (Fig. 1). There were three patients in Cohort A and two patients in Cohort B who had a higher IOP in the operated eye of 20 mmHg or higher, which is an IOP elevation that is clinically significant.

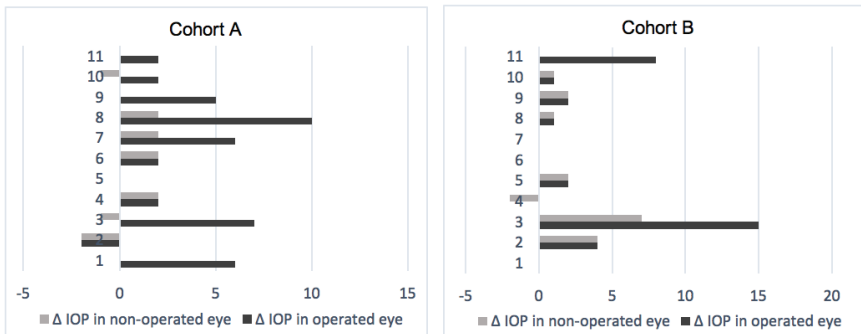


Fig. 1. IOP difference between operated and control eye in Cohorts A and B.

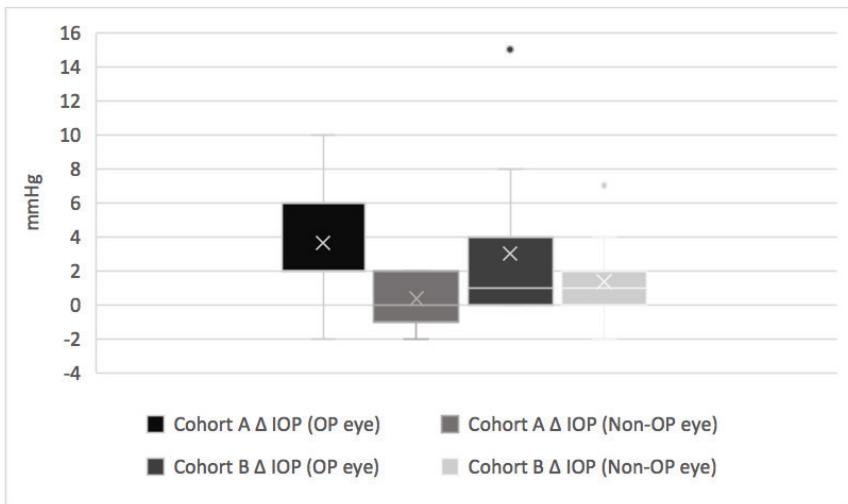


Fig. 2. Mean and range in IOP difference between operated vs control eye in Cohorts A and B, including outliers.

Table 1. Comparison of clinical characteristics and mean IOP rise in Cohorts A and B

	Cohort A		Cohort B	
Population	11		11	
Mean age (years)	67.9		68.8	
	Operated eye	Non-operated eye	Operated eye	Non operated eye
Mean IOP rise (95% CI) mmHg	3.64 ± 1.18	0.36 ± 0.37	3.00 ± 1.07	1.36 ± 0.72
p-value	0.003		0.06	

IOP: intraocular pressure

A higher rise was detected in the operated eye of patients who received cyclopentolate in their preoperative pupil dilation regimen: we found an average IOP rise of 3.64 ± 1.18 (95% CI; *p*-value = 0.003) in Group A compared to 3.0 ± 1.07 (95% CI; *p*-value = 0.06) in Group B (Table 1). The difference in mean IOP rise was not statistically significant. We observed a significantly higher mean IOP rise in Cohort A (3.27 ± 0.81) compared to Cohort B (1.64 ± 0.35) (Fig. 2).

Discussion

This study showed that the incidence of postoperative IOP rise following cataract surgery was reduced when cyclopentolate was excluded in the preoperative eye drop regimen to dilate the pupil. In patients with increased IOP, there was no correlation identified for age or gender.

Anticholinergics such as tropicamide and cyclopentolate block the function of the sphincter pupillae and ciliary muscle. When the ciliary muscle contracts, it pulls on the trabecular meshwork and opens its filtration channels, which can help drain aqueous and any viscoelastic that remains in the anterior chamber after cataract surgery.¹ This helps explain the findings of our study, in which normal ciliary muscle function helps prevent IOP rise. The instillation of pilocarpine postoperatively further helps increase outflow through the trabecular meshwork, as pilocarpine stimulates contraction of the ciliary muscle, which then opens up the spaces in the trabecular meshwork.²

Tropicamide has a half-life of 30 minutes and its effect on the pupil and ciliary muscle wears off after 4 hours, while cyclopentolate has a half-life of 111 minutes and usually lasts for up to 24 hours.¹⁻⁴ This explains the mid-dilated

pupil in patients who had cyclopentolate on Day 1 postoperative, and the normal functioning pupil in patients who were not given cyclopentolate.

Conclusion

This small retrospective audit study demonstrates that using tropicamide and phenylephrine only, without cyclopentolate, reduces the incidence of postoperative IOP rise following cataract surgery. However, a larger study would be useful to ascertain the significance of these results.

It would be preferable to avoid or minimize the use of cyclopentolate for preoperative pupil dilation in cataract surgery, especially in patients with glaucoma. If there is a delay in surgery schedule and the pupil becomes less dilated, extra drops of tropicamide can be used to re-dilate the pupil without compromising surgical safety.

References

1. Zanetti F, Fulco EA, Chaves FR, da Costa Pinto A, Arieta CE, Lira RP. Effect of preoperative use of topical prednisolone acetate, ketorolac tromethamine, nepafenac and placebo, on the maintenance of intraoperative mydriasis during cataract surgery: A randomized trial. *Indian J Ophthalmol*. 2012;60(4):277-281.
2. Hancox J, Murdoch I, Parmar D. Changes in intraocular pressure following diagnostic mydriasis with cyclopentolate 1%. *Eye (London, England)*. 2002;16(5):562-566.
3. Li G, Farsiu S, Chiu SJ, et al. Pilocarpine-induced dilation of Schlemm's canal and prevention of lumen collapse at elevated intraocular pressures in living mice visualized by OCT. *Invest Ophthalmol Vis Sci*. 2014;55(6):3737-3746.
4. Lahdes K, Huupponen R, Kaila T, Monti D, Saettone MF, Salminen L. Plasma concentrations and ocular effects of cyclopentolate after ocular application of three formulations. *Br J Clin Pharmacol*. 1993;35(5):479-483.
5. Sani RY, Hassan S, Habib SG, Ifeanyiichukwu EP. Cycloplegic effect of atropine compared with cyclopentolate-tropicamide combination in children with hypermetropia. *Niger Med J*. 2016;57(3):173-177.
6. Stanley RG. Ocular clinical pharmacology. In: Maddison JE, Page SW, Church DB, editors. *Small Animal Clinical Pharmacology* (2nd Edition). Edinburgh: WB Saunders; 2008. p. 557-573.
7. Kilic O, Ozturk M, Ata Gozcelioglu E. Tropicamide ophthalmic solution reduces clozapine-induced sialorrhea: a case report. *Psychiat Clin Psych*. 2017;27(4):431-434.