

# Pythium keratitis: clinical course of an emerging scourge

Radhika Natarajan<sup>1</sup>, Ankit Anil Harwani<sup>1</sup>, Ramya Ravindran<sup>2</sup>

<sup>1</sup>Department of Cornea and Refractive Surgery, Medical Research Foundation, Chennai, India; <sup>2</sup>Department of Ophthalmology, Sri Muthukumaran Medical College Hospital and Research Institute, Chennai, India

## Abstract

We hereby report two cases of the emerging and devastating *Pythium* keratitis for their different presentations, prolonged clinical course, and suspicion of recurrence after therapeutic penetrating keratoplasty (TPK). The history, clinical presentation, investigations including smears, cultures, polymerase chain reaction (PCR) and confocal microscopy, the tumultuous course of the infection, and outcome of TPK have been discussed for two cases having this unusual and severe emerging infection. These two cases demonstrate that *Pythium* keratitis can present as a central reticular or peripheral guttering corneal ulcer with dense infiltration. PCR is a valuable tool for diagnosis. *Pythium* keratitis has a severe and prolonged clinical course. Response to antibiotics is modest and needs to be closely monitored. It can present with inflammation after TPK that mimics the dreaded recurrence of the infection. *Pythium* keratitis presents variably and can be suspected from typical clinical and microbiological findings. It needs protracted treatment with close follow-up. Although the infection is known to recur in the therapeutic graft, not all recurrences are what they seem.

**Keywords:** *pythium keratitis, recurrent infection, therapeutic keratoplasty*

## Introduction

*Pythium* keratitis is an emerging dreaded infection of the cornea due to its poor response to traditional antifungal medication, protracted course, and ocular morbidity.<sup>1</sup> Originally mistaken for a fungus, *Pythium insidiosum* is an oomycete of the Pythiaceae family.<sup>2</sup> Because its cell wall is composed of cellulose, it remains unharmed by antifungals, which target the ergosterol in the fungal cell walls.<sup>3</sup> Therapeutic keratoplasty (TPK) may be the only recourse in recalcitrant infections and, even then, recurrence is quite common.<sup>4</sup> However, it is important to distinguish recurrent infection from other causes of postoperative inflammation, as the treatments are different. We hereby report two cases of *Pythium*

**Correspondence:** Dr. Radhika Natarajan, FRCS, Department of Cornea and Refractive Surgery, Medical Research Foundation, Chennai, Tamil Nadu 600006, India.  
E-mail: 100radsam@gmail.com

keratitis for their different presentations, prolonged clinical course, and suspicion of recurrence after TPK.

## Case reports

### Case 1

A 45-year-old male patient presented with redness, pain, and photophobia of the left eye for 2 weeks. There was an 8 mm corneal stromal infiltrate with reticular edges, reaching the temporal limbus (Fig. 1A). The rest of the ocular examination was normal. Corneal scraping revealed sparsely septate fungus-like filaments with ribbon-like folding. The culture grew *Pythium insidiosum*, which was confirmed by a polymerase chain reaction (PCR) test.

The patient was started on 0.2% fortified linezolid and 1% azithromycin eye drops hourly. The size of the infiltrate increased, and he developed a hypopyon in the second week of medical treatment. The patient then underwent an 11 mm TPK, during which cryotherapy of the host margins and absolute alcohol swabbing of the edges were done to reduce the chances of recurrence. The patient was then continued on topical azithromycin and linezolid hourly reduced

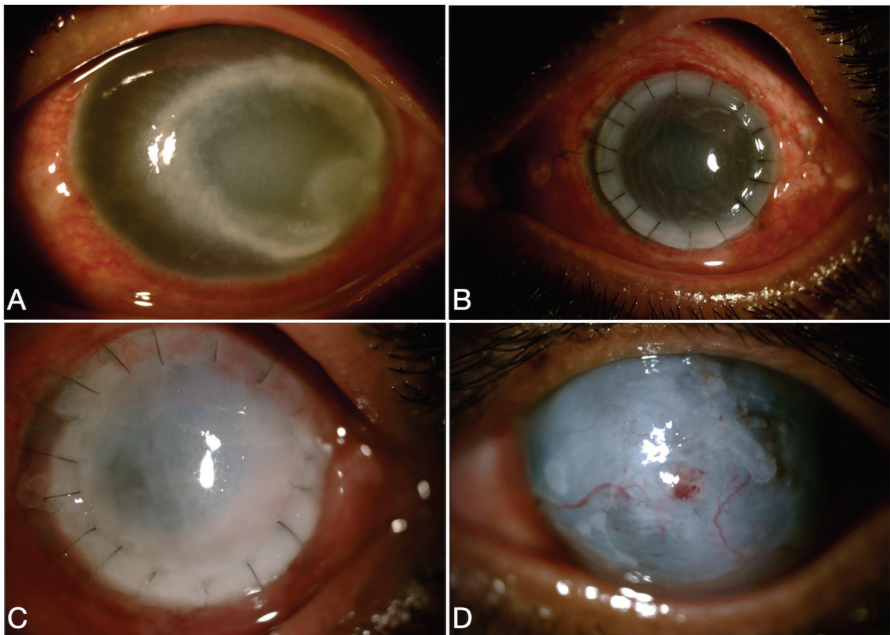


Fig. 1. (A) *Pythium* keratitis presenting as central corneal infiltrate in the first case. (B) Large therapeutic graft. (C) Steamy graft with cellularity at 3 weeks. (D) Resolved graft inflammation.

to eight times a day after 2 weeks along with azithromycin 500 mg once daily for 10 days. The graft remained clear with epithelial healing in the immediate postoperative period (Fig. 1B).

Three weeks later, he presented with a large epithelial defect, 20% stromal thinning, cloudy cornea, and an exudate behind the graft (Fig. 1C). Suspecting a recurrence, the corneal graft was again scraped for smears, cultures, and PCR, all of which proved negative. In vivo confocal microscopy was performed, which showed only inflammatory cells but no fungus-like filaments, indicating it was not a recurrence. An anterior chamber tap from the exudate was kept as a standby investigation should the condition worsen.

There were no keratic precipitates or other features of graft rejection. With confocal images and PCR proving negative, this was treated as an inflammatory episode with close observation. The antibiotics were reduced and copious lubricants started. After conservative treatment, tissue adhesive and bandage lens were used to heal the epithelial defect with thinning and a small temporary lateral tarsorrhaphy was also done. Topical steroids were given in a tapering dose after epithelial healing. The eye quietened down (Fig. 1D) and the patient subsequently underwent a successful optical keratoplasty 10 months later.

## **Case 2**

A 62-year-old man presented with diminished vision of the right eye for 10 days. He was suspected to have *Pythium* keratitis and was already using 0.2% linezolid and 1% azithromycin eye drops hourly and oral azithromycin 500 mg once a day. The patient owned an aquarium business and dealt with Thai fish.<sup>5</sup> Vision in the right eye was counting fingers close to face. The cornea had a peripheral guttering ulcer 2–3mm wide with concentric spread (5 to 11 o'clock hours). The central edge was sloping and the peripheral edges were steep. There was a dense infiltrate at the base with 60–70% stromal thinning and the central cornea was steamy (Fig. 2A). There was no scleral involvement and no sparing of corneal tissue between the ulcer and the limbus, unlike immune disease. Ocular examination was otherwise normal. Corneal scraping was performed and the smear showed sparsely septate filaments suspicious of *Pythium*. This was confirmed on culture and by a PCR test.

Cyanoacrylate glue was applied over the thinned-out area with a bandage contact lens. The medications were continued. Confocal microscopy showed multiple, linear, hyper-reflective, lattice-like structures in the area of infiltrate, extending up to the posterior stroma suggestive of *Pythium*, which reduced with ongoing treatment. The disease followed a prolonged waxing and waning course. Later, as the symptoms and signs showed healing, topical therapy was reduced to eight times a day and stopped after 2 months.

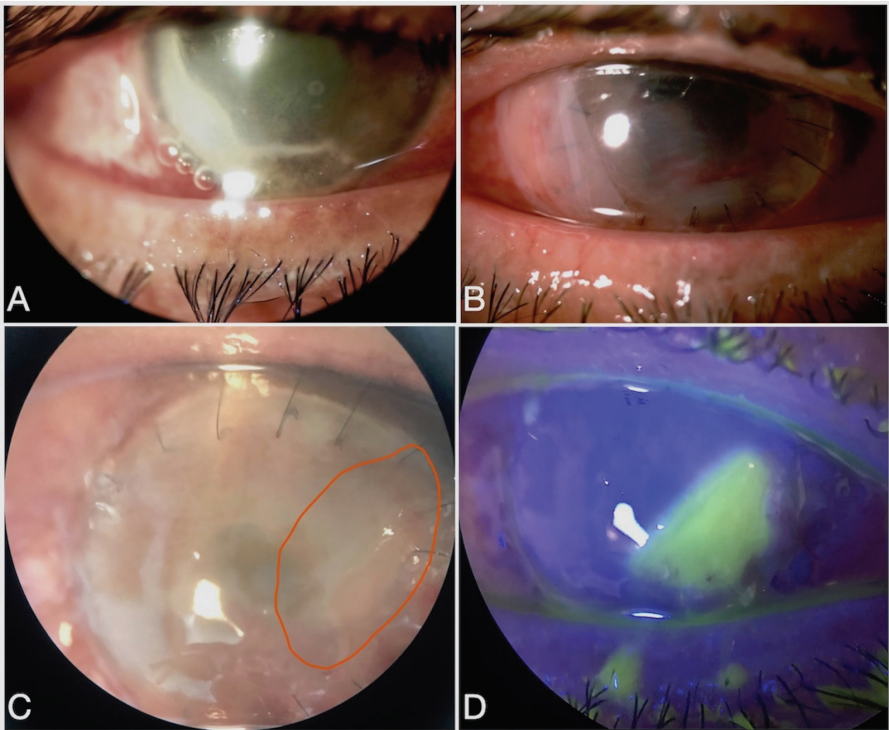


Fig. 2. (A) *Pythium* keratitis presenting as a peripheral gutter with infiltrate in the second case. (B) Slightly eccentric therapeutic graft. (C) Granular inflammation in the outlined area with early suture loosening. (D) Associated epithelial defect.

The patient presented after 2 weeks of stopping the topical eye drops with increased pain and discomfort. There was a corneal perforation under the glue with mild fibrinous exudate. TPK was performed along with absolute alcohol application and cryotherapy to the host edges to reduce the chance of recurrence (Fig. 2B). The corneal button showed and grew *Pythium insidiosum*. Postoperatively, the medications were continued.

This patient also presented with a 4 mm epithelial defect and aggressive granular inflammation of the graft in the third postoperative week (Fig. 2C and 2D) which, upon investigation, was neither rejection nor recurrence of infection. Topical antibiotics were reduced and loose sutures removed. After epithelial healing, loteprednol 0.5% eye drops and carboxymethylcellulose eye drops helped quieten the eye over the three subsequent months, like the previous case.

## Discussion

*Pythium* keratitis, caused by the oomycete *Pythium insidiosum*, is an aggressive infection, non-responsive to conventional antifungal medication due to the lack of ergosterol in its cell wall.<sup>3</sup> It is diagnosed by its clinical features and laboratory confirmation. The clinical manifestations include reticulated edges of the infiltrate with linear tentacle-like extensions, dot infiltrates, peripheral guttering, and sometimes presence of a hypopyon.<sup>4</sup>

On smear in wet-field microscopy, the organism appears as a T-shaped filament with typical 90° angle, thick cell wall, sparsely septate, and a mass of vehicles inside, showing ribbon-like folding.<sup>1</sup> *Pythium* grows readily on potato dextrose agar and blood agar as flat, feathery-edged, partially submerged, pale colonies with filiform margins.<sup>4</sup> However, it has been suggested that initial scraping samples might not show the organism on smear or culture.<sup>4</sup> Formation of zoospores in aquatic medium is indicative but not pathognomonic of the organism.<sup>3,6</sup> Polymerase chain reaction-based DNA sequencing targeting the internal transcribed spacer region is used to confirm the diagnosis of *Pythium insidiosum*.<sup>1,4</sup> On confocal microscopy, *Pythium* filaments appear as multiple linear, hyper-reflective, well-delineated structures with a width of approximately 4 µm and length of approximately 350 µm. The filaments are X- and Y-shaped, with branching at right angles.<sup>1,2</sup>

Topical linezolid and oral and topical azithromycin have shown modest efficacy in the treatment of *Pythium* keratitis.<sup>7</sup> If the condition worsens on medical management, TPK should be performed. Adjunctive absolute alcohol and cryotherapy to the host margin may help reduce chances of infection recurrence.<sup>3</sup> Although recurrence after TPK is quite common,<sup>3</sup> this should be confirmed with laboratory investigations and the clinical course monitored closely. A sample from the anterior chamber can also be collected for microbiological confirmation when there are postoperative exudates.<sup>1</sup> In our case, which had a small exudate, considering the negative results on scraping and confocal microscopy, TPK was considered should the clinical condition worsen. If the condition worsens after maximum medical management, a repeat TPK should be considered.

The common site for recurrence of *Pythium* keratitis after TPK is in the graft or in the anterior chamber.<sup>3</sup> Since confocal microscopy and microbiology proved there was no re-infection, our patients were treated for the aggressive inflammation of the grafts with epithelial breakdown, mimicking re-infection. These could be attributed to the severe infection, toxic topical medication, and large therapeutic graft surgery with adjuvant treatments.

## Conclusion

These two cases demonstrate that *Pythium* keratitis can present as a central reticular or peripheral guttering corneal ulcer with dense infiltration. It has a severe and prolonged clinical course. Response to antibiotics requires close monitoring. Although the infection is known to recur in the therapeutic graft, not all recurrences are what they seem.

## Acknowledgements

The authors wish to disclose they have no conflicts of interest, financial interests, or financial support in regard to this article.

## References

1. He H, Liu H, Chen X, Wu J, He M, Zhong X. Diagnosis and Treatment of *Pythium* Insidiosum Corneal Ulcer in a Chinese Child: A Case Report and Literature Review. *Am J Case Rep.* 2016;17:982–988.
2. Agarwal S, Iyer G, Srinivasan B, et al. Clinical profile of *pythium* keratitis: perioperative measures to reduce risk of recurrence. *Br J Ophthalmol.* 2018;102(2):153–157.
3. Agarwal S, Iyer G, Srinivasan B, et al. Clinical profile, risk factors and outcome of medical, surgical and adjunct interventions in patients with *Pythium* insidiosum keratitis. *Br J Ophthalmol.* 2019;103(3):296–300.
4. Hasika R, Lalitha P, Radhakrishnan N, et al. *Pythium* keratitis in South India: Incidence, clinical profile, management, and treatment recommendation. *Indian J Ophthalmol* 2019;67(1):42-47.
5. Krajaejun T, Sathapatayavongs B, Prachartam R, et al. Clinical and epidemiological analyses of human *pythiosis* in Thailand. *Clin Infect Dis.* 2006;43(5):569–576.
6. Sharma S, Balne PK, Motukupally SR, et al. *Pythium* insidiosum keratitis: clinical profile and role of DNA sequencing and zoospore formation in diagnosis. *Cornea.* 2015;34(4):438–442.
7. Bagga B, Sharma S, Madhuri Guda SJ, et al. Leap forward in the treatment of *Pythium* insidiosum keratitis. *Br J Ophthalmol.* 2018;102(12):1629–1633.