

# Pterygium excision with suture-less and glue-free conjunctival autograft

Fariha S. Wali, Muhammad Jawed, Rafeen Talpur,  
Naeemullah Shaikh, Shehnilla Shujaat, Khalid I. Talpur  
Department of Ophthalmology, Sindh Institute of Ophthalmology and  
Visual Sciences, Hyderabad, Pakistan

## Abstract

Pterygium excision is a commonly encountered surgery with different methods being used. These procedures range from simple excision to use of grafts. Limbal conjunctival autograft is currently the most popular surgical procedure.

The most common method of autograft fixation is suturing. But it has its own drawbacks like increased operating time, post-operative discomfort, inflammation, buttonholes, necrosis, giant papillary conjunctivitis, scarring, and granuloma formation.

Glue is widely used due to many advantages like easy fixation of the graft, shorter operation time, and reduction in complications and post-operative discomfort but at the same time has some disadvantages also like high cost, the risk of transmission of infections and inactivation by iodine preparations.

**Purpose:** In the following study, we describe a simple method of accomplishing conjunctival autograft adherence during pterygium surgery avoiding possible complications associated with the use of fibrin glue or sutures.

**Design:** Prospective study.

**Method:** We used conjunctival autograft, which was not sutured or glued to the scleral bed. The fibrin formed from the oozing blood was used to get the graft adhesion to the scleral bed. This study was approved by institutional review board, and written consent form was taken from each participant.

**Results:** The suture-less and glue-free conjunctival autograft was found to have excellent results in terms of surgical outcome as well as post-operative recovery. In addition, risk of side effects related to sutures and glue was eliminated.

**Conclusion:** Suture-less and glue-free conjunctival autograft is a new, easy, and cheaper technique for the management of pterygium.

**Keywords:** conjunctival autograft, pterygium excision, suture-less, glue-free

## Introduction

Pterygium is a triangular, vascular, fleshy growth that grows from conjunctiva to the corneal limbus and to the corneal surface.<sup>1</sup> Pterygium occurs more

**Correspondence:** Muhammad Jawed, Department of Ophthalmology, Sindh Institute of Ophthalmology and Visual Sciences, Hyderabad, Pakistan.  
E-mail: [jawedbiotech@yahoo.com](mailto:jawedbiotech@yahoo.com)

frequently in people who live in areas with high ultraviolet radiation, specifically UV\_B radiation.<sup>2</sup> Dusty, hot, dry, windy, and smoky environments also play a part. A hypothesis is that ultraviolet radiation causes mutations in the p53 tumour suppressor gene, thus facilitating the abnormal proliferation of limbal epithelium.<sup>3</sup> Most pterygia occur on the nasal side.<sup>4</sup>

In the disease process, pterygia are usually asymptomatic but there can be signs of dry eye such as burning, itching, or tearing as the lesion causes irregular wetting of the ocular surface.<sup>5</sup> The lesion can increase in size and become more apparent to the naked eye causing a cosmetic blemish. Further growth may cause visual symptoms due to induced astigmatism or direct encroachment onto the visual axis.<sup>6</sup> Pterygia less than 3 mm may induce some astigmatism. Lesions larger than 3 mm are likely to be associated with more than 1 D of astigmatism and often cause blurring of uncorrected vision.<sup>7</sup> All these indications make pterygium excision a frequently encountered surgery to ophthalmologists.

The objective of surgical excision is to completely remove the head, neck, and body of the pterygium. The most common technique was to leave to the sclera bare after pterygium excision. High post-operative recurrence led to adoption of adjuvant methods. Use of mitomycin C, beta irradiation, and anti-vascular endothelial growth factor has been employed to decrease the recurrence.<sup>8</sup>

Pterygium excision with ocular surface reconstruction is the current procedure of choice in view of its comparatively higher efficacy in preventing recurrence.<sup>9</sup> This included amniotic membrane grafting or use of conjunctival autograft.<sup>10</sup>

Free conjunctival autograft is now the most preferred method to prevent recurrence, being anatomically and physiologically similar to the tissue required.<sup>11</sup> The free graft including limbal stem cells act as a barrier to prevent the growth of fibrovascular tissue onto the cornea. To adhere the graft to the scleral bed, either sutures or fibrin glue is used.<sup>12,13</sup> The most common method of autograft fixation is suturing, but it increases operating time, post-operative discomfort, inflammation, buttonholes, necrosis, giant papillary conjunctivitis, scarring, and granuloma formation.<sup>14</sup> Glue enables easy fixation of the graft, shorter operation time, reduction in post-operative discomfort, but have some limitations such as high cost, risk of transmission of infections, and inactivation by iodine preparations.<sup>15</sup>

Suture-less and glue-free conjunctival autograft is a new, easy, and cheaper technique for the management of pterygium where the fibrin formed as a normal clotting process acts as a glue to hold the graft to the scleral bed.<sup>16,17</sup>

## Materials and methods

In the following prospective study, autologous limbal conjunctival grafting was done without sutures and glue. Our objective was to reduce patient discomfort by using suture-less and glue-free technique.

The study design was approved by the Institutional Review Board of Sindh Institute of Ophthalmology and Visual Science, Pakistan. Before recruitment, the objectives of the study were clarified to each individual, and written consent form was obtained. Principles of the Declaration of Helsinki were considered during the whole study.

**Inclusion criteria:** Patients of all ages and of either sex presenting with primary nasal pterygium.

**Exclusion criteria:** Recurrent pterygium, glaucoma, retinal pathology requiring surgical intervention, history of previous ocular surgery or trauma.

**Surgical technique:** Peribulbar anaesthesia with 2% lignocaine and 0.5% bupivacaine in 1:1 ratio was given pre-operatively. The body of the pterygium was dissected 4 mm from the limbus to achieve bare sclera. Pterygium was removed from the cornea by avulsion method.<sup>18</sup> Large haemorrhages were tamponade with direct compression. No cautery was done. Graft slightly larger than the scleral bed was marked from superotemporal limbus. The graft was resected with the help of conjunctival scissors. Care was taken to include as minimal of tenon capsule as possible. The graft was placed on bare sclera with limbus–limbus orientation. The graft was kept opposed to the scleral bed for 10 minutes by applying gentle pressure with fine non-toothed forceps. Small bleed in the scleral bed and small ooze of serum act as adhesive. Large bleeds can lift the graft from scleral bed and were tamponaded before placing the graft. Conjunctival fornix was painted with moxifloxacin eye drops and padded. Pad was removed after 48 hours.

## Results

Patients were followed post-operatively on the second post-operative day when the eye pad was removed, then after two weeks, and then at one month (Fig. 1A, 1B and 1C).

Out of 112 patients, two patients had slightly displaced grafts and two lost their graft. All the remaining patients with stable graft were kept on topical combination of tobramycin and dexamethasone eye drops. Patients with lost grafts were managed with bare sclera technique. To them, topical cyclosporine was added in addition to topical tobramycin and dexamethasone combination.

On second follow-up after two weeks, graft was found stable with decreased oedema and surrounding congestion. Patients with inferiorly displaced grafts had good enough adherence, and so did not require any further treatment.

At one-month follow-up, all patients had smooth conjunctival surface except two who had displaced grafts. In those two patients, conjunctiva was slightly folded inferiorly but the patients were symptom free. In a few patients, conjunctival wound gape was noted (Fig. 2A and 2B).

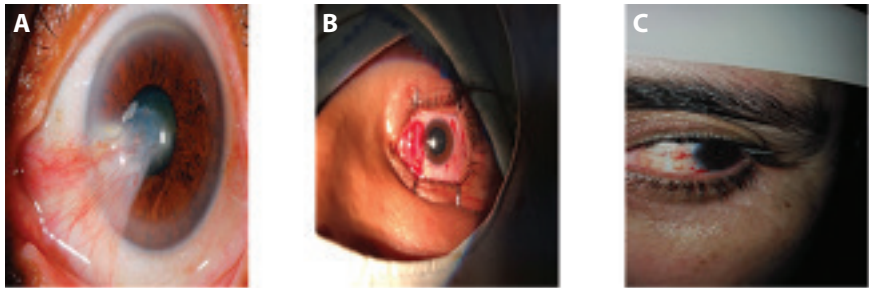


Fig. 1. A. Pre-operative picture of pterygium involving visual axis. B. Pre-operative picture of suture-less and glue-free conjunctival autograft. C. Two-days post-operative picture of suture-less and glue-free conjunctival autograft.

## Discussion

Pterygium is a commonly encountered problem in tropical regions and often needs to be surgically treated. Many different techniques and methods have been used to optimise pterygium excision. Post-excision inflammatory process leads to accumulation of fibroblasts, proliferation of vascular channels, and extracellular matrix deposition. This process leads to recurrence of pterygium.<sup>19</sup>

Out of the multiple surgical options and adjunctive medications, pterygium excision with autograft is associated with a lesser rate of recurrence.<sup>20</sup> This technique was first described by Kenyon *et al.*<sup>21</sup> This technique is much more demanding in terms of surgical expertise and proper graft orientation. The conjunctival autograft maintains the ocular surface smooth and also restores the normal anatomy and physiology of ocular surface. Conjunctival autograft comprises the limbal stem cells, which act as a barrier to conjunctival overgrowth.<sup>22</sup>

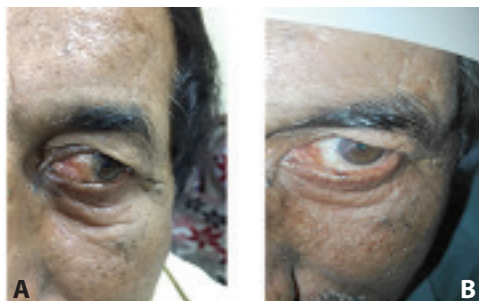

Fig. 2. A. Pre-operative and B. One-month post-operative picture after suture-less and glue-free conjunctival autograft.

Conjunctival autograft can be secured to the scleral bed with the help of sutures. Use of sutures demands increased operating time and is also associated with suture-related irritation, photophobia, and even granuloma formation. Use of fibrin glue is associated with ease, reduced surgical time, and early post-operative recovery. High cost, availability, and risk of transmission of infections and chronic inflammation are a few disadvantages associated with the use of fibrin glue.<sup>23</sup> Both techniques though gave excellent results with minimal recurrence, the challenges of having sutures or glue-related side effects led to the thought of using autologous fibrin.

Fibrin is formed in the blood when protease thrombin acts on fibrinogen. Fibrin forms long tough strands of insoluble protein that are bound to the platelets. The blood oozed in the scleral bed contains fibrin that helps adhere the graft to the bed.<sup>24</sup> Stark and co-workers stressed on having minimal tenon attached to conjunctival graft, which needs good dissection of conjunctiva from tenon. The graft is kept with limbus to limbus orientation and is left to adhere for 10 minutes. Suture-less and glue-free surgery takes lesser time and gives early post-operative recovery, associated with minimal side effects and negligible recurrence rates.

## Conclusion

Pterygium excision with conjunctival autograft is the most successful method in terms of reducing recurrence rate. Instead of using sutures or commercially available fibrin glue, fibrin formed on the scleral bed as a result of normal clotting cascade can be used for graft adherence. This suture-less and glue-free conjunctival autograft is cost effective, easy, and without risk of side effects due to foreign materials.

## References

1. Zloto O, Rosen N, Leshno A, Rosner M. Very long term success of pterygium surgery with conjunctival graft. *Cont Lens Anterior Eye*. 2017;40(4):267-269.
2. Gross J, Wegener AR, Kronschläger M, Holz FG, Schönfeld C-L, Meyer LM. Ultraviolet radiation exposure triggers neurokinin-1 receptor upregulation in ocular tissues in vivo. *Exp Eye Res*. 2018;174:70-79.
3. Mao L, Huang W, Zou P, Dang X, Zeng X. The unrecognized role of tumor suppressor genes in atrial fibrillation. *Gene*. 2018;642:26-31.
4. Arriola-Villalobos P, Cifuentes-Canorea P, Peraza-Nieves JE, et al. Fibrin glue conjunctival autograft for primary pterygium: Overall outcomes and outcomes in expert versus trainee ophthalmologists. *J Fr Ophthalmol*. 2018;41(4):326-332.
5. Messmer EM, von Lindenfels V, Garbe A, Kampik A. Matrix metalloproteinase 9 testing in dry eye disease using a commercially available point-of-care immunoassay. *Ophthalmology*. 2016;123(11):2300-2308.
6. Kheirkhah A, Safi H, Molaei S, Nazari R, Behrouz MJ, Raju VK. Effects of pterygium surgery on front and back corneal astigmatism. *Can J Ophthalmol*. 2012;47(5):423-428.
7. Spaide RF, Fujimoto JG, Waheed NK, Sadda SR, Staurengi G. Optical coherence tomography angiography. *Prog Retin Eye Res*. 2018;64:1-55.

8. Zarei R, Masoumpour M, Moghimi S, Fakhraei G, Eslami Y, Mohammadi M. Evaluation of topical bevacizumab as an adjunct to mitomycin C augmented trabeculectomy. *J Curr Ophthalmol.* 2017;29(2):85-91.
9. Mednick Z, Boutin T, Einan A, Sorkin N, Slomovic A. Simple limbal epithelial transplantation for recurrent pterygium: a case series. *Am J Ophthalmol Case Rep.* 2018.
10. Vlasov A, Sia RK, Ryan DS, et al. Sutureless cryopreserved amniotic membrane graft and wound healing after photorefractive keratectomy. *J Cataract Refract Surg.* 2016;42(3):435-443.
11. Akbari M, Soltani-Moghadam R, Elmi R, Kazemnejad E. Comparison of free conjunctival autograft versus amniotic membrane transplantation for pterygium surgery. *J Curr Ophthalmol.* 2017;29(4):282-286.
12. Brejchova K, Trosan P, Studeny P, et al. Characterization and comparison of human limbal explant cultures grown under defined and xeno-free conditions. *Exp Eye Res.* 2018;176:20-28.
13. Vazirani J, Mariappan I, Ramamurthy S, Fatima S, Basu S, Sangwan VS. Surgical management of bilateral limbal stem cell deficiency. *Ocul Surf.* 2016;14(3):350-364.
14. Messmer EM, May CA, Stefani FH, Welge-Luessen U, Kampik A. Toxic eosinophil granule protein deposition in corneal ulcerations and scars associated with atopic keratoconjunctivitis. *Am J Ophthalmol.* 2002;134(6):816-821.
15. Shwin KW, Lee C-CR, Goldbach-Mansky R. Dermatologic manifestations of monogenic autoinflammatory diseases. *Dermatol Clin.* 2017;35(1):21-38.
16. Elwan SAM. Comparison between sutureless and glue free versus sutured limbal conjunctival autograft in primary pterygium surgery. *Saudi J Ophthalmol.* 2014;28(4):292-298.
17. Kheirkhah A, Nazari R, Nikdel M, Ghassemi H, Hashemi H, Behrouz MJ. Postoperative conjunctival inflammation after pterygium surgery with amniotic membrane transplantation versus conjunctival autograft. *Am J Ophthalmol.* 2011;152(5):733-738.
18. Pérez-Silguero D, Díaz-Ginory A, Santana-Rodríguez C, Pérez-Silguero MA. Pterygium surgery and fibrin glue: avoiding dehiscence. *Arch Soc Esp Oftalmol (English Edition).* 2014;89(1):35-37.
19. Kim KW, Lee SJ, Kim JC. TNF- $\alpha$  upregulates HIF-1 $\alpha$  expression in pterygium fibroblasts and enhances their susceptibility to VEGF independent of hypoxia. *Exp Eye Res.* 2017;164:74-81.
20. Dhany R. Primary nasal pterygium excision with sutureless and glue-free technique of conjunctival autograft. *Asian J Ophthalmol.* 2019;16(3).
21. Kenyon KR, Wagoner MD, Hettinger ME. Conjunctival autograft transplantation for advanced and recurrent pterygium. *Ophthalmology.* 1985;92(11):1461-1470.
22. Soliman Mahdy MA, Bhatia J. Treatment of primary pterygium: role of limbal stem cells and conjunctival autograft transplantation. *Eur J Ophthalmol.* 2009;19(5):729-732.
23. Uy HS, Reyes JMG, Flores JDG, Lim-Bon-Siong R. Comparison of fibrin glue and sutures for attaching conjunctival autografts after pterygium excision. *Ophthalmology.* 2005;112(4):667-671.
24. Alston SM, Solen KA, Broderick AH, Sukavaneshvar S, Mohammad SF. New method to prepare autologous fibrin glue on demand. *Transl Res.* 2007;149(4):187-195.