

Arachnoid cyst of the optic nerve: therapeutic management and progress

Irene Temblador-Barba, Carlos Gálvez-Prieto-Moreno,
María Martínez-Jiménez

Department of Ophthalmology, Hospital Universitario Virgen de las Nieves
(Complejo Hospitalario), Granada, Spain

Abstract

Purpose: To describe the management of a case of an arachnoid cyst of the optic nerve.

Methods: Here, we report a 27-year-old female patient who was diagnosed with arachnoid cyst of the left sheath optic nerve, drained in several occasions, and came to our service because of progressive blurring in the left eye.

Outcomes: Due to the location of the lesion, excision could not be performed; so we performed a microsurgical incision with drain by nasal superior transconjunctival approach. After that, the visual acuity (VA) was 0.7, and we could observe that the size of the cyst was smaller than previous examinations with magnetic resonance imaging (MRI). Nowadays, the patient keeps the same asymptomatic VA. So medical appointments are planned to closely follow-up, and periodically, we perform new scan images and visual fields.

Conclusions: Arachnoid cysts of the optic nerve are rare, benign, slowly progressive conditions. They can be asymptomatic lesions, especially smaller ones, or may result in proptosis and loss of vision because of the compression. The best imaging examination for their follow-up is MRI. They should be differentiated from optic nerve sheath meningioma and other conditions.

Keywords: arachnoid cyst, drain, incision, magnetic resonance imaging, transconjunctival approach

Introduction

Arachnoid cyst of the optic nerve is a rare benign entity, which is a proliferation of normal fibrovascular tissue that comprises the leptomeninges in the location they are found. These cysts may reveal an appearance similar to optic nerve neoplasm, principally meningiomas,¹ although they also resemble gliomas.²

Case report

Here, we report a 27-year-old female patient who was diagnosed with arachnoid cyst of the left optic nerve, drained in several occasions, and came to our service

Correspondence: Irene Temblador-Barba, Department of Ophthalmology, Hospital Universitario Virgen de las Nieves (Complejo Hospitalario), Granada, Spain.
E-mail: irenetemblador@gmail.com

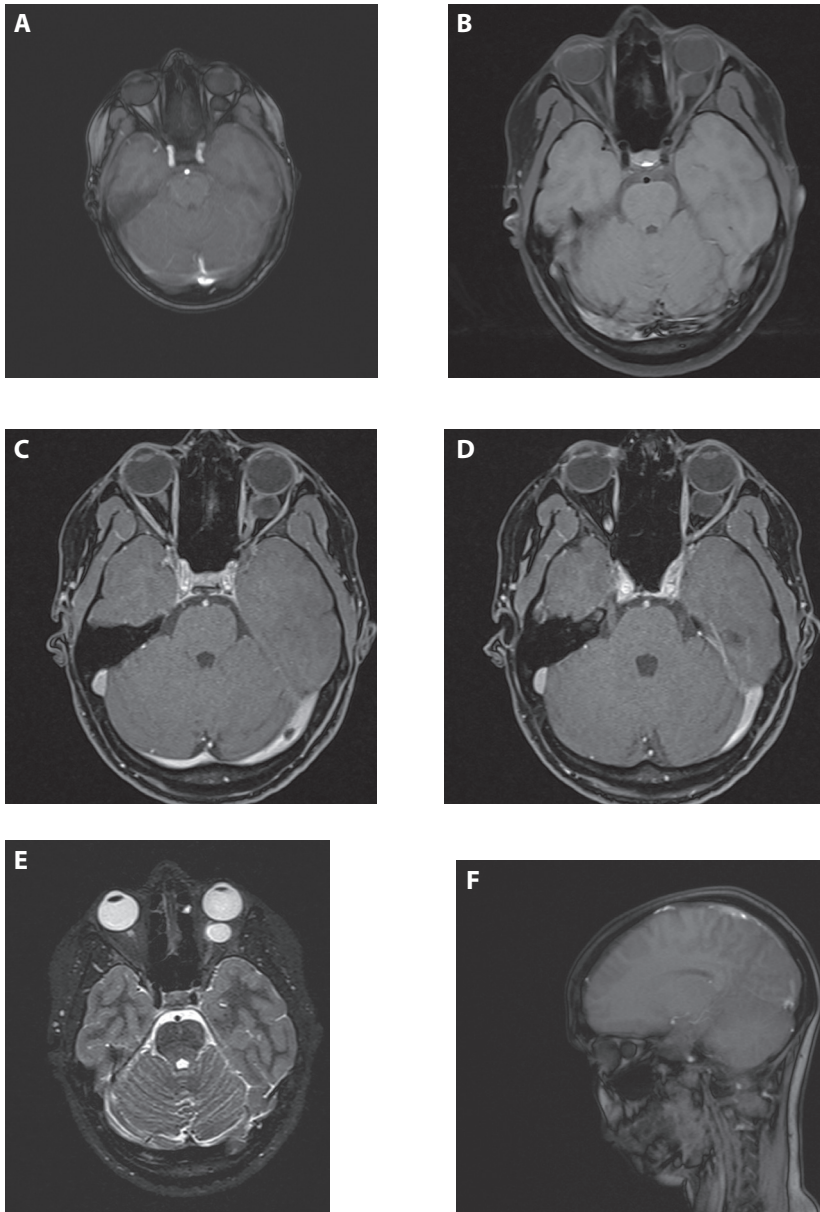


Fig. 1. Preoperative axial MRI scans of the patient. (A) Arachnoid cyst of the left optic nerve. (B) MRI shows enlargement of the left optic nerve. (C) More details about the enlargement of the optic nerve because of the cyst. (D) The whole extension of the cyst. (E) MRI with contrast.

because of progressive blurring in this eye. The visual acuity (VA) was one with the right eye and counting fingers with the left eye. Intraocular tensions were 14 mmHg in both eyes. The pupils and slit-lamp examination were normal. She did not present with exophthalmos. Her ocular fundus showed normality in the right eye, and in the left eye, we could observe transparent papilla at the level of the excavation, where there was liquid behind a hyperpigmented zone. Magnetic resonance imaging (MRI) with and without contrast was performed, and both demonstrated that this cyst was bigger in size than a previous examination done two years earlier in another medical centre (Figs. 1 to 3). Computed tomography showed no calcifications in the orbital/optic nerve mass.

Due to the location of the lesion, excision could not be performed; so we performed a microsurgical incision with drain by nasal superior transconjunctival approach. The incision was perpendicular to the nerve, and its size was about 5 to 6 mm. After that, the VA was 0.7 and the rest of the examination was normal. We could observe that the size of the cyst was smaller than previous examinations with MRI. The fundus examination revealed lower level of liquid, although it was really a very subtle change. The cyst had smaller size than in previous examinations, with diameters of 13×18 mm and 1.7 cm^3 currently compared with previous ones of 14×19 mm and 2.0 cm^3 (both measurements taken in the same plane and sequence for better correlation). It kept the same aspect by image, without pathological enhancement (Figs. 4 and 5). Despite the slight decrease in the size, nowadays, the patient keeps the same asymptomatic VA. So medical appointments are planned to closely follow-up, and periodically, we perform new scan images and visual fields. The visual fields remain stable and a specific pattern has

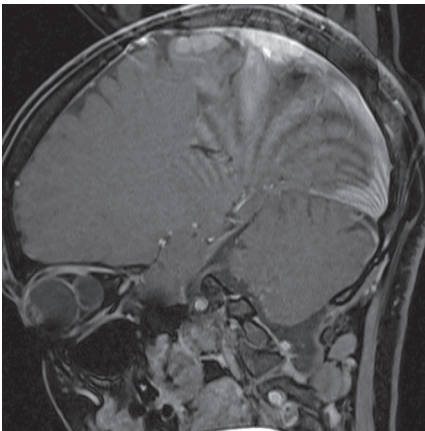


Fig. 2. (A, B) Preoperative sagittal MRI scans of the patient.

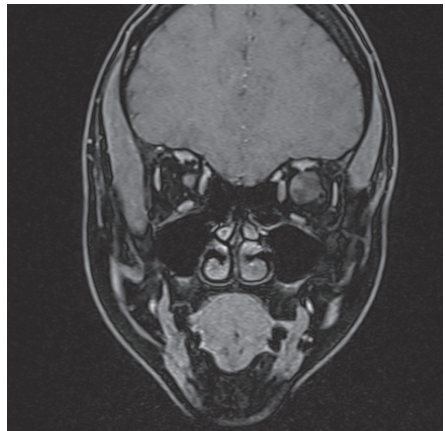


Fig. 3. Preoperative coronal MRI scans of the patient.

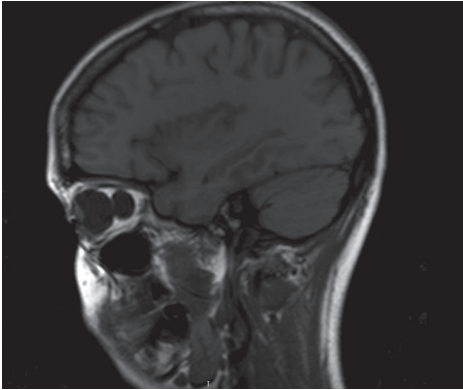


Fig. 4. Postoperative sagittal MRI scan of the patient.

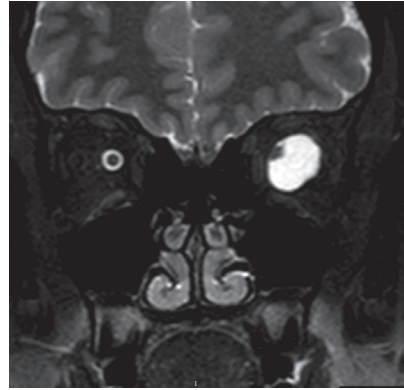


Fig. 5. Postoperative coronal MRI with contrast scan of the patient.

not been observed. Above all, the most important change we have noticed is the improvement in the VA.

Discussion

The pathogenesis of the arachnoid cyst of optic nerve sheath is still unknown. It is possible that its origin is related to trauma, which leads to cyst formation. Congenital entrapment or sequestration of their secretory neuroepithelial cells secondary to a neoplasm might result in cyst formation, although most of these cysts are idiopathic.^{1,3}

The most commonly accepted approach regarding treatment is observation in asymptomatic arachnoid cyst.⁴ When they are asymptomatic and don't threaten the vision of the patient, follow-up could be done with visual fields and strict examinations of the optic nerve to be able to detect possible atrophy if this appears. Symptomatic patients are candidates for surgery.⁵ These symptoms could be progressive loss vision or proptosis until headache, seizure, and dizziness if they have an intracranial portion.⁶ Microsurgical incision or fenestration of the cyst and open excision are the surgical options in the treatment of arachnoid cysts of the optic nerve,⁷ and sometimes an additional mini-orbitotomy is needed. Because of the characteristics of our case, we decided for a microsurgical incision with superonasal transconjunctival approach without removing cranial bone.

If an incision is performed instead of excision, there are more possibilities of relapse, but in many cases, this first option cannot be performed because of the location of the mass. In cases of possible optic nerve sheath arachnoid cyst, a biopsy is potentially both diagnostic and therapeutic.¹ Indications for biopsy include evaluation for neoplasm, particularly meningioma and for decompression.

Decompression may result in resolution of disc oedema if it exists and some visual improvement.^{1,8} The differential diagnosis has to be established between meningioma, hemangioma, glioma, or another type of tumours.²

Conclusions

Arachnoid cysts of the optic nerve are rare, benign, fibrovascular proliferations that comprise the leptomeninges that surrounds the optic nerve, and normally their progression is slow. They can be asymptomatic lesions, especially smaller ones, or may result in proptosis and loss of vision because of the compression. The best imaging examination for their follow-up is the MRI. They should be differentiated from other conditions, especially the tumours.

Conflict of interest

No potential conflict of interest relevant to this article has been reported.

References

1. Akor C, Wojno TH, Newman NJ, Grossniklaus HE. Arachnoid cyst of the optic nerve. Report of two cases and review of the literature. *Ophthalmic Plast Reconstr Surg*. 2013;19(6):466-469.
2. Moschos MM, Lymberopoulos C, Moschos M. Arachnoid cyst of the optic nerve. A case report. *Klin Monbl Augenheilkd*. 2004 May;221(5):408-409.
3. Holt H. Cysts of the intracranial portion of the optic nerve. *Am J Ophthalmol*. 1966;61:1166-1170.
4. Al-Holou WN, Terman S, Kilburg C, et al. Prevalence and natural history of arachnoid cysts in adults. *J Neurosurg*. 2013;118(2):222-231.
5. Kural C, Kullmann M, Weichselbaum A, Schuhmann MU. Congenital left temporal large arachnoid cist causing intraorbital optic nerve damage in the second decade of life. *Child Nerv Syst*. 2016;32:575-578.
6. Wester K, Moen G. Documented growth of a temporal arachnoid cyst. *J Neurol Neurosurg Psychiatry*. 2000;69:699-700.
7. Pradilla G, Jallo G. Arachnoid cysts: case series and review of the literature. *Neurosurg Focus*. 2007;22(2):E7.
8. Miller NR, Green WR. Arachnoid cysts involving a portion of the intraorbital optic nerve. *Arch Ophthalmol*. 1975 Nov;93(11):1117-1121.