

Subretinal crystalline lens – an unusual complication of blunt trauma

Kalpana Badami Nagaraj, Srilatha Tirumale, K.S. Sriprakash, C.S. Savitha, Chaitra Jayadev

Minto Regional Institute of Ophthalmology, Chamrajpet, Bangalore, Karnataka, India

Abstract: We describe the case of a 65-year-old Indian male with a subretinal crystalline lens; an unusual complication of blunt trauma. The patient underwent a three port pars plana vitrectomy during which the subretinal location of the crystalline lens under the inferior giant retinal tear was confirmed. The lens was maneuvered into the vitreous cavity and appropriately managed.

Key words: Blunt trauma, subretinal crystalline lens

Introduction

Posterior dislocation of the crystalline lens following blunt trauma is a well-known complication.¹ We report a case of subretinal migration of the lens through a giant retinal tear following blunt trauma. The lens was brought into the vitreous cavity and was managed appropriately. This complication has not been reported in literature so far.

Case report

A 65-year-old Indian male came with symptoms of loss of vision, pain, watering and swelling of the lids following blunt trauma to his right eye sustained two weeks before presentation. His best corrected visual acuity was perception of light in the right eye and 20/60 in the left eye. Examination of the right eye revealed lid edema, ecchymosis, subconjunctival hemorrhage, inflammatory reaction and vitreous in the anterior chamber. The crystalline lens was not present in the pupillary plane. Fundus examination of the right eye showed vitreous hemorrhage with inferior bullous retinal detachment and a suspicious giant retinal tear. The lens was not visible in the vitreous cavity. Examination of the left eye did not reveal any abnormalities. B-scan ultrasonography of the right eye confirmed an inferior retinal detachment with underlying echoes suggestive of a crystalline lens (Fig. 1).

A three port pars plana vitrectomy under local anesthesia was performed. A subtotal retinal detachment was noted sparing the macula with a giant retinal tear inferiorly. The subretinal location

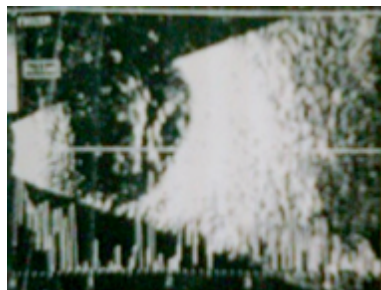

Fig. 1. B-scan ultrasound image showing the subretinal location of the lens

Correspondence: Dr Kalpana Badami Nagaraj, FRCS(Glasg), FMRF, DNB, Minto Regional Institute of Ophthalmology, AV road, Chamrajpet, Bangalore – 560018, Karnataka, India.
E-mail: badamikal@gmail.com

of the crystalline lens was confirmed (Fig. 2). The lens was maneuvered through the giant retinal tear (Fig. 3) using the suction of the vitrector and endoilluminator, into the vitreous cavity (Fig. 4) and appropriately managed. The retina was reattached. At three months follow up, the patient's vision was 20/200 and the retina remained attached.

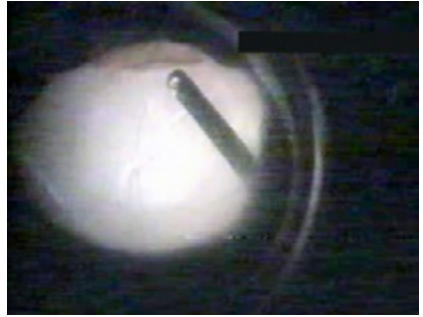

Fig. 2. Subretinal crystalline lens as seen through the inferior retinal detachment with giant retinal tear.

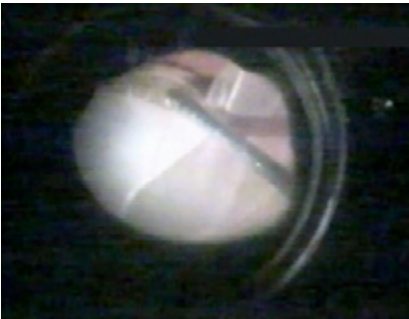

Fig. 3. Crystalline lens being maneuvered through the giant retinal tear.




Fig. 4. Crystalline lens in the vitreous cavity.

Discussion

Blunt trauma is associated with vitreous hemorrhage, dislocation of the lens and retinal detachment.^{1,2} We report subretinal migration of the crystalline lens, an unusual complication of blunt trauma and hitherto unreported.

A lens nucleus dislocated through a retinal dialysis into the subretinal space as a complication of pars plana lensectomy in one report was managed by reattaching the retina over the lens. There was subsequent slow resorption of the lens material with good visual recovery.³ In another report, the lens had migrated subretinally during phacoemulsification and was managed by creating a retinotomy over the nucleus.⁴ The mechanism for the subretinal migration of the crystalline lens in our case could be the impact of the trauma producing dislocation of the lens and the giant retinal tear simultaneously. The lens movement into the subretinal space may have been influenced by the direction of the impact, gravity and/or vitreous adhesions. Following trauma, B-scan ultrasonography aids in diagnosing the nature and extent of the injury.⁵ We managed the subretinal lens by maneuvering it through the tear into the vitreous cavity. Management options might vary depending on the location and status (clear or cataractous

and extent of cataract) of the lens in addition to the associated retinal pathology.⁶⁻⁹ Subretinal migration of crystalline lens is an unusual complication following blunt trauma. However, timely and effective intervention can ensure good visual recovery.

References

1. Williams DF, Mieler WF, Williams GA. Posterior segment manifestations of ocular trauma. *Retina* 1990;10 Suppl 1:S35-44.
2. Steinberg DA, Leslie CL. Traumatic dislocation of the crystalline lens. *J Trauma* 2005;58(1):213-214.
3. Lawrence B. Katzen, MD, Gerald D. Rogell, MD. Subretinal Lens An Unusual Complication of Pars Plana Lensectomy. *Arch Ophthalmol* 1981;99:1396-1397.
4. Rani A, Pal N, Vohra R, Mandal S, Azad R. Subretinal dislocation of the crystalline lens: Unusual complication of phacoemulsification. *J Cataract Refract Surg* 2005;31(9):1843-1844.
5. Aironi VD, Gandage SG. Pictorial essay: B-scan ultrasonography in ocular abnormalities. *Indian J Radiol Imaging* 2009;19(2):109-115.
6. Seo MS, Yoon KC, Lee CH. Phacofragmentation for the treatment of a completely posterior dislocation of total crystalline lens. *Korean J Ophthalmol* 2002;16(1):32-36.
7. Yao K, Shentu X, Jiang J, Du X. Phacofragmentation without perfluorocarbon liquid for dislocated crystalline lenses or lens fragments after phacoemulsification. *Eur J Ophthalmol* 2002;12(3):200-204.
8. Oh J, Smiddy WE. Pars plana lensectomy combined with pars plana vitrectomy for dislocated cataract. *J Cataract Refract Surg* 2010;36(7):1189-1194.
9. Dickinson PJ, Greven CM. Avoiding and managing the dislocated crystalline lens. *Compr Ophthalmol Update* 2006;7(3):113-127.