

External dacryocystorhinostomy: a two-year review

Long Li Ying^{1,2}, Safinaz Mohd Khialdin², Nazila Binti Ahmad Azli¹

¹Department of Ophthalmology, Hospital Selayang, Ministry of Health, Malaysia;

²Department of Ophthalmology, Universiti Kebangsaan Malaysia Medical Centre (UKMMC), Kuala Lumpur, Malaysia

Abstract

Background: Dacryocystorhinostomy (DCR) is the treatment of choice for nasolacrimal duct obstruction. Despite the emergence of new techniques such as endoscopic DCR, external DCR is still the criterion standard in primary cases.

Aim: To analyse the epidemiological data, surgical technique, success rate, and complications of patients who underwent external DCR in Hospital Selayang from January 2015 to December 2016.

Method: Retrospective case series.

Results: A total of 21 eyes of 20 patients who underwent external DCR from January 2015 to December 2016 were identified and reviewed. There were 15 females (75%) and 5 males (25%). Age ranged from 5 to 75 years old, with a median age of 56 years old (IQR 23). Twelve patients presented with epiphora while eight patients presented with symptoms of dacryocystitis. One case was congenital, two were secondary nasolacrimal duct obstruction and the rest were primary nasolacrimal duct obstruction. All patients underwent external DCR under general anaesthesia. Silicone tube were inserted in 21 eyes, of which all were removed 3 months after the surgery except one patient whom had his tube dislodged accidentally. The overall success rate was 90.5% (n = 19), which was defined as no or minimal intermittent epiphora or no reflux on lacrimal irrigation at 12 months postoperative. There was one patient who had a cerebrospinal fluid leak treated successfully with intravenous antibiotics.

Conclusion: The surgical success rate for external dacryocystorhinostomy was comparable to that of the global success rate of external DCR. This is attributed to the application of surgical technique such as anterior suspended flap modification and posterior flap excision.

Keywords: case series, external dacryocystorhinostomy, Malaysia, nasolacrimal duct obstruction

Correspondence: Nazila Binti Ahmad Azli, Department of Ophthalmology, Hospital Selayang, Ministry of Health, Malaysia.

E-mail: drnazy73@yahoo.com

Introduction

Nasolacrimal duct obstruction is a common condition encountered by ophthalmologists and oculoplastic surgeons. It generally affects two age groups: infants and adults older than 40 years old, especially female. It can be classified as primary (idiopathic) or secondary (caused by other local or systemic conditions). The common presentations are watery eye and symptoms associated with dacryocystitis such as mucoid discharge, swelling near the medial angle of the eye, and dacryocystocele.

Dacryocystorhinostomy (DCR) is the treatment of choice for nasolacrimal duct obstruction. It creates anastomosis between the lacrimal sac and nasal cavity through the bony ostium. It can be divided into internal (endoscopic) and external (transcutaneous) approach. Despite the emergence of new techniques such as endoscopic DCR, external DCR is still the criterion standard in primary cases, with a success rate of 80-95%.¹

Materials and methods

A retrospective analysis of patients referred to the Oculoplastic team, Department of Ophthalmology, Hospital Selayang (Kuala Lumpur, Malaysia) that had undergone external DCR from January 2015 to December 2016 were identified. Patients' demographic data, types of nasolacrimal duct obstruction, surgical technique, success rate, outcome, and complications were reviewed.

The diagnosis of nasolacrimal duct obstruction was made by thorough irrigation of the nasolacrimal drainage system. All patients underwent a comprehensive ophthalmic examination and were reviewed by an oculoplastic surgeon prior to surgery.

External DCR was performed under general anaesthesia. The surgeries were all performed by a single surgeon. All patients were prepared with oxymetazoline nasal spray into the affected nostril one day earlier. The nasal cavity was decongested preoperatively with ribbon gauze pre-soaked with cocaine 4%, bupivacaine 0.5%, and adrenaline 1:200,000. A 1 cm vertical skin incision was made 8 mm medial to the inner canthus, followed by blunt dissection of the subcutaneous and orbicularis oculi muscle. The periosteum was incised parallel to the anterior lacrimal crest and reflected away from the bone. Osteotomy of about 10 x 10 mm was performed using a Kerrison punch.

In cases where double-flap was performed, anterior and posterior flaps were created. The posterior flaps were sutured with 6-0 Vicryl (Polyglactin 910) sutures. In no-flap cases, the posterior flaps were excised. This was decided intraoperatively when difficulties such as deep location or friable mucosa were encountered. A silicone tube was inserted into both canaliculi and tied within the nasal cavity.

In all cases, anterior suspended flap modification technique was applied. Anterior flaps of lacrimal sac and nasal mucosa were created. Both flaps were joined with two double-armed 6-0 Vicryl sutures passed through the superior and inferior corners of the flaps. One end of each suture was then passed through the orbicularis muscle at the medial edge of the wound while the other end was passed through orbicularis muscle at the lateral edge of wound and tied together. Through this modification, anterior flaps were suspended like a tent to prevent the possibility of adhesion to deeper tissues. The skin wound was closed with 6-0 Nylon sutures.

Postoperatively, patients were prescribed with dexamethasone 1% neomycin eye drops. The patients were reviewed postoperatively one day and one week later, and subsequently at one, three, and six months as well as yearly thereafter.

Results

A total of 21 eyes of 20 patients undergoing external DCR from January 2015 to December 2016 were identified and analysed. Among the 20 patients, there were 15 females (75%) and 5 males (25%). Age ranged from 5 to 75 years old, with a median age of 56 years old (IQR 23). Twelve patients presented with epiphora and the other eight patients presented with symptoms of dacryocystitis. There were 11 (52.4%) left eyes and 10 (47.6%) right eyes. All patients underwent external DCR under general anaesthesia. Silicone tubes were inserted in 21 eyes with plan for removal 3 months after the surgery, except one patient whom had his tube accidentally dislodged one week postoperatively.

There were 17 new case presentations, whereas 3 were recurrent cases. The recurrent cases had a history of external and/or endoscopic DCR done by different surgeons at least twice. Two cases had secondary causes and one was primary.

In terms of classification (Fig. 1), one case was congenital, two were secondary nasolacrimal duct obstruction, and the rest were primary nasolacrimal duct obstruction. Among the secondary causes, one had a motor vehicle accident with Le Fort type 2 midface fracture involving the zygomatic complex requiring open reduction internal fixation; another had both facial trauma and nasopharyngeal carcinoma with a history of radiotherapy.

Table 1. Sub-group analysis of success rate for PANDO, SANDO, and recurrent cases

Classification	PANDO	SANDO	Recurrent cases
Successful	18	2	3
Failed	1	1	1
Success rate	94.40%	50%	66.70%

PANDO: primary acquired nasolacrimal duct obstruction; SANDO: secondary acquired nasolacrimal duct obstruction.

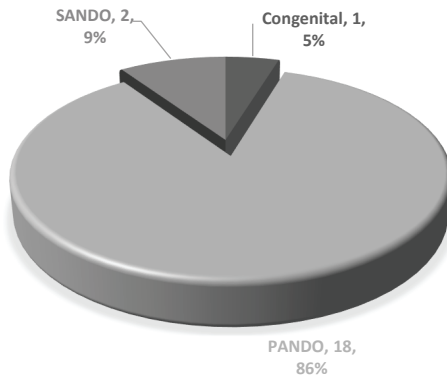


Fig. 1. Classification of nasolacrimal duct obstruction among patients that underwent DCR. PANDO: primary acquired nasolacrimal duct obstruction; SANDO: secondary acquired nasolacrimal duct obstruction.

None of the patients had surgery during active infection. In cases presented with acute dacryocystitis, they were treated with systemic antibiotics and given time for infection to subside prior to external DCR.

The overall success rate was 90.5% (n = 19). Success in our study is defined as no or minimal intermittent epiphora or no reflux on lacrimal irrigation at 12 months postoperative. It is taken as success if patient achieves either anatomical patency (patency on syringing test) or functional patency (no or minimal symptoms). Fourteen (67%) cases had posterior flap excision and six (29%) cases underwent double-flap technique, as shown in Figure 2. Cystectomy was performed in one patient with secondary nasolacrimal duct obstruction due to altered anatomical structure. Anterior flap modification technique was applied in all cases.

In view of altered anatomies in secondary nasolacrimal duct obstruction cases and more scarring for recurrent cases, success rate is also analysed based on classification, shown in Table 1. The success rate was higher among primary nasolacrimal duct obstruction cases (94.4%) and lower in secondary nasolacrimal duct obstruction (50%) and recurrent cases (66.7%). For the recurrent cases, two had posterior flap excision and one had cystectomy performed.

Two patients did not achieve resolution of symptoms after surgery. The first patient was a case of recurrent secondary nasolacrimal duct obstruction who had comorbid nasopharyngeal carcinoma and had undergone radiotherapy. In addition, the silicone tube was accidentally dislodged one week after the operation. The second patient had persistent epiphora and underwent revision surgery.

One patient was complicated with a cerebrospinal fluid leak. The patient was managed with an otolaryngologist and was treated with intravenous antibiotics.

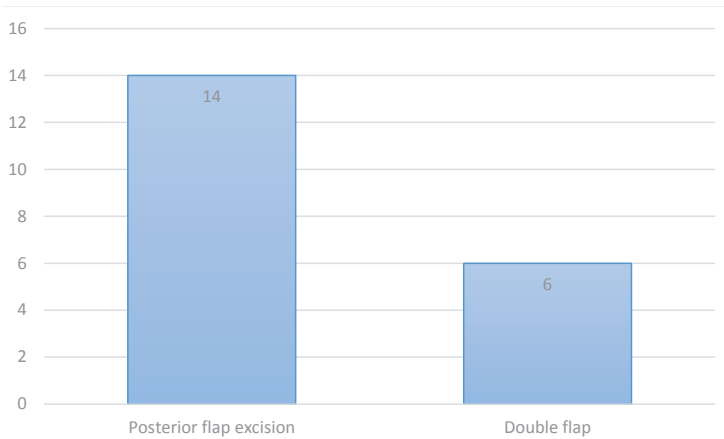


Fig. 2. Surgical techniques applied in 20 eyes. Note: Cystectomy was performed in one patient with secondary nasolacrimal duct obstruction due to altered anatomical structure.

The patient was well without signs and symptoms of meningitis. Otherwise, there were no other intraoperative or postoperative complications reported.

Discussion

External DCR has been the gold standard treatment for nasolacrimal duct obstruction for over 100 years.¹ The advantages of this approach are attributed to its excellent success rate and high patient satisfaction. The patients' main concern will be the cutaneous scarring. Other complications are listed in Table 2.

The success rate of external DCR has been reported to be between 80% to 95% and is usually greater than 90%.¹⁻³ As the standard surgical treatment for nasolacrimal duct obstruction, this technique has its limitations, such as difficult resection and suturing of mucosal flaps, either through formation of granulation tissue at the osteotomy level or through adhesion of the anterior to the posterior flaps, and extended procedural duration. Owing to the deep location of the posterior flaps, suturing these is especially challenging and time-consuming.

The high success rate was attributed to the technique of anterior suspended flap modification. This technique was first described by Baldeschi *et al.*⁴ in 1998, by which the author created anterior flaps of lacrimal sac and nasal mucosa, passing the sutures through the orbicularis oculi to elevate the flaps forward, while not suturing the posterior flaps. This technique resulted in 100% success rate in 45 patients. In a more recent publication, Tetikoglu *et al.* conducted a retrospective study of 50 eyes in 47 patients and found a 100% success rate for patients who underwent modified external DCR with satisfactory surgical time.² The posterior flaps were removed, and the largest possible anterior flaps were

created and suspended to avoid adhesion to the underlying tissue. Modifications of this technique have increased the success rate as well as reduced procedure duration and complications.

In our study, all patients underwent anterior flap suspension with or without posterior flap excision. Posterior flaps of lacrimal sac and nasal mucosa were either sutured together or excised, but none were left unattended. This is an important step to ensure less obstacles to the newly-created ostium. Posterior flap excision of both lacrimal sac and nasal mucosa was performed when there were difficulties encountered intraoperatively, such as deep location or friable mucosa.

External DCR without flap anastomosis has also been applied in a majority of cases in a study done by Takahashi *et al.*⁵ This technique demonstrated a success rate as good as external DCR with double-flap. The author compared the surgical outcomes of 205 external DCR surgeries divided into double-flap group and no-flap group. The results showed that the success rate between these groups was statistically insignificant. Again, this will shorten surgical duration without additional complications.

To avoid an external scar, the endoscopic approach is another excellent option with minimal complications and a success rate of more than 90%.^{6,7} However, this technique is limited by the need for specialized equipment, cost, and a steep learning curve.¹

Possible causes of failure include inadequate size and position of the ostium, unrecognized common canalicular obstruction, scarring, and sump syndrome. Lee *et al.* identified that the site of obstruction was the most significant risk factor for functional failure after external DCR. Common canalicular obstruction or canalicular obstruction were independently associated with higher rates of functional failure.³

There are a few limitations to this study. The number of cases in this study is small and the period of observation is only two years. As this is a descriptive retrospective case series, there are unequal number of cases on each technique for comparison. A prospective randomized control design will be required to further prove the efficacy of each technique. Thus, a longer duration of follow-up is required in order to study the long-term success rate and complications.

Table 2. Summary of complications of external DCR

Complications of external DCR	
Early	Injury to medial canthal structures Haemorrhage/epistaxis Subcutaneous/intraorbital emphysema Wound infection

Complications of external DCR	
	Wound breakdown Medial rectus paresis Orbital fat herniation Cerebrospinal fluid rhinorrhea Meningitis Retrobulbar haemorrhage
Late	Cutaneous scarring (most common) Lid malposition (punctal evertion/ectropion/disruption of MPL) Failed DCR

Conclusion

The surgical success rate for external DCR in our study was 90.5%, which is comparable to the global success rate of external DCR (80-95%).¹ This is attributed to the application of surgical techniques such as anterior suspended flap modification and posterior flap excision.

Acknowledgements

We would like to thank the Director General of Health Malaysia for his permission to publish this article.

References

1. Grob SR, Campbell A, Lefebvre DR, Yoon MK. External versus endoscopic endonasal dacryocystorhinostomy. *Int Ophthalmol Clin*. 2015;55(4):51-62. doi: 10.1097/IIO.000000000000083.
2. Tetikoglu M, Sagdik HM, Ozcura F, Aktas S. Assessment of anterior suspended flaps modification for external dacryocystorhinostomy. *J Craniofac Surg*. 2015;26(3):789-991. doi:10.1097/SCS.0000000000001362.
3. Lee MJ, Khwarg SI, Kim IH, et al. Surgical outcomes of external dacryocystorhinostomy and risk factors for functional failure: a 10-year experience. *Eye*. 2017;31(5):691-669.
4. Baldeschi L, Nardi M, Hintschich CR, et al. Anterior suspended flaps: a modified approach for external dacryocystorhinostomy. *Br J Ophthalmol* 1998;82:790-792.
5. Takahashi Y, Mito H, Kakizaki H. External dacryorhinostomy with or without double mucosal flap anastomosis: comparison of surgical outcomes. *J Craniofac Surg*. 2015;26(4):1290-1293.
6. Rasan MI, Shailendra S, Prepageran N, Gopala K, Sathananthar KS. Endoscopic dacryocystorhinostomy. *Med J Malaysia*. 2008;63(2):143-145.
7. Harvinder S, Rosalind S, Philip R, Mallina S, Gurdeep S. Powered endoscopic dacryocystorhinostomy with mucosal flaps without stenting. *Med J Malaysia*. 2008;63(3):237-238.