

Cavernous haemangioma of the retina

Jed Lusthaus,¹ James Wong,^{1,2} Greg Horowitz¹

¹Sydney Eye Hospital, Sydney, Australia;

²Sydney Retina Clinic and Day Surgery, Sydney, Australia

Abstract: A 29-year-old man was found to have an incidental finding of peripheral cavernous haemangioma of the retina (CHR). Fundus examination revealed peripheral retinopathy with fine haemorrhage. Traditional appearance of CHR was demonstrated by fluorescein angiography. OCT showed the saccular appearance with an overlying epiretinal membrane, consistent with CHR. All other investigations were negative and there was no suggestion of systemic dermatological or neurological involvement.

CHR is a rare and usually incidental finding associated with a small risk of associated systemic vascular and neurological involvement. We have demonstrated the fundal and OCT appearance of peripheral CHR, which is an important clinical and diagnostic finding.

Key words: Cavernous haemangioma of the retina, spectral-domain optical coherence tomography, time-domain optical coherence tomography, fluorescein angiography, phacomatosis

Introduction

Cavernous haemangioma of the retina (CHR) is a congenital, unilateral vascular hamartoma¹ initially described by Niccol and Moore in 1934,² but later expressed as a separate clinical entity by Gass.^{2,3}

Spectral-domain optical coherence tomography (SD-OCT) was compared with time-domain OCT (TD-OCT) to diagnose the following case of CHR, which is a rare condition and can be associated with vascular lesions in the central nervous system (CNS).

Case report

A twenty-nine year old man presented with one year of deteriorating vision in his left eye. Refraction indicated myopia and astigmatism, with left eye vision correcting from 6/36 to 6/6. Slit lamp examination and intraocular pressures were unremarkable.

Dilated fundus examination revealed fine striae at the left posterior pole, consistent with premacular fibrosis. In addition a vascular abnormality was noted in the left retinal periphery, inferior to the optic disc (Fig. 1). Initially it appeared to be a clump of fine haemorrhage with white patches, but on review was appreciated to be a typical cavernous haemangioma:

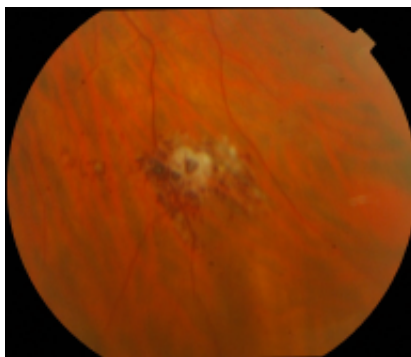


Fig. 1. Peripheral colour fundus photograph of cavernous hemangioma of the retina demonstrating whitish glial tissue overlying 'cluster of grapes' saccular aneurysms.

Correspondence: Dr Greg Horowitz, Maroubra Eye Clinic, 102 Gale Rd, Maroubra, NSW 2035.
E-mail: gghoro@bigpond.net.au

a cluster of saccular aneurysms resembling 'a bunch of grapes'. There was a prominent white fibrous component, but no exudate.

Combined Heidelberg Spectralis HRA with SD-OCT demonstrated the aneurysms with simultaneous fluorescein angiogram and illustrated peripheral saccular retinal lesions with overlying epiretinal membrane (ERM) (Fig. 2a). An image for comparison can also be seen with Zeiss Stratus TD-OCT (Fig. 2b).

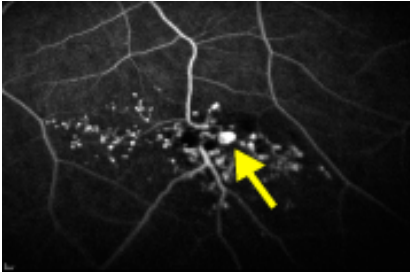
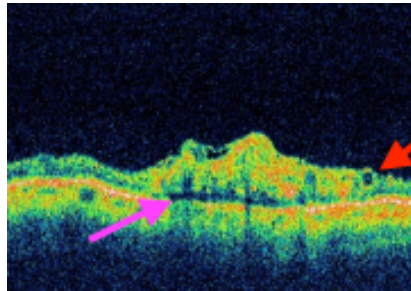
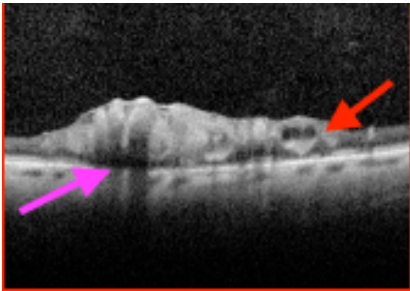


Fig. 2. Comparison of spectral-domain OCT with simultaneous fluorescein angiography demonstrating dilated saccules (a) and time-domain OCT (b) over cavernous hemangioma showing mostly solid lesion with overlying epiretinal membrane, dilated saccule (red arrow) and optically-empty subretinal space (pink arrow)



The patient did not have any subcutaneous vascular lesions or CNS lesions confirmed on MRI. The decreased vision was attributed to his refractive error, so that the left premacular fibrosis and left retinal cavernous haemangioma were essentially incidental findings.

The patient has been followed for twelve months with no change in his vision or appearance of his left macula.

Discussion

Cavernous haemangioma of the retina or optic nerve head is a rare, congenital vascular hamartoma.^{1,2} It is usually unilateral and sporadic, but occasionally can be inherited as autosomal dominant and in this situation it is more likely to be bilateral and have systemic associations.¹⁻⁴ In our patient the vascular lesion was found incidentally, as is often the case. It had a typical appearance, but there was one of the uncommon complications, namely premacular fibrosis (the other, also uncommon complication is vitreous haemorrhage).⁵

Aside from the possibility of developing vitreous haemorrhage there are few clinically important associations with CHR, namely the systemic vascular abnormalities of the brain and skin.^{2,5} The presence of neurological involvement with cutaneous and

retinal haemangiomas constitutes a rare autosomal dominant phacomatosis, known as cavernoma multiplex⁴ or Weskamp-Cotlier syndrome. Although there is no suggestion of familial disease in our case, it is important to be mindful of this connection. Since most eyes with CHR have good visual acuity, treatment is only indicated when vision is impaired by recurrent vitreous haemorrhage, or premacular fibrosis.

OCT is a useful, non-invasive diagnostic tool that allows *in-vivo* optical dissection of retinal and choroidal layers. TD-OCT images have only recently been reported in one case of CHR.⁵ Like this case, we found a mostly solid lesion with overlying epiretinal membrane. The haemangioma was confined to the inner retina as the RPE interface appeared to be intact. It has been suggested that traction of this epiretinal membrane can rarely cause vitreous haemorrhage.⁵ We report additional findings of dilated saccules and an optically-empty subretinal space below the main lesion complex (Fig. 2). Our findings correlate with the reported histopathological appearance of glial tissue and thin-walled, endothelial-lined vascular channels.⁵ SD-OCT has not previously been documented in the literature, but provides a clearer and more detailed evaluation of the retina compared to TD-OCT.

In summary, CHR has a very distinctive ophthalmic appearance. When diagnosed, patients should have neuro-imaging to exclude an associated vascular abnormality of the brain.

References

1. Messmer E, Laqua H, and Wessing A. Nine cases of cavernous hemangioma of the retina. *Am J Ophthalmol* 1983;95:383-390.
2. Hewick S, Lois N, and Olson JA. Circumferential peripheral retinal cavernous hemangioma. *Arch Ophthalmol* 2004;122:1557-1560.
3. Gass JD. Cavernous hemangioma of the retina. A neuro-oculo-cutaneous syndrome. *Am J Ophthalmol* 1971;71(4):799-814.
4. Sarraf D, Payne AM, and Kitchen ND. Familial cavernous hemangioma. *Arch Ophthalmol* 2000;118:969-973.
5. Pringle E, Chen S, Rubenstein A, et al. Optical coherence tomography in retinal cavernous haemangioma may explain the mechanism of vitreous haemorrhage. *Eye* 2009;23:1242-1243.
6. Sayanagi K, Sharma S, Yamamoto T, et al. Comparison of Spectral-Domain versus Time-Domain Optical Coherence Tomography in Management of Age-Related Macular Degeneration with Ranibizumab. *Ophthalmology* 2009;116:947-955.