

Late post-operative endophthalmitis in a non-diabetic patient with urinary tract infection due to *Candida albicans*

M. Jayahar Bharathi, R. Ramakrishnan, C. Shivakumar

Department of Microbiology & Molecular Biology, Aravind Eye Hospital & PG Institute of Ophthalmology, Tirunelveli, Tamil Nadu, India

Abstract: A 56-year-old woman presented with redness, pain and diminution of vision in the right eye for the past month after having undergone cataract surgery six months earlier by phacoemulsification with implantation of a posterior chamber intraocular lens. No history of trauma, systemic or any ocular surface diseases were recorded. She had symptoms of photophobia and floaters. B-scan ultrasonography in the right eye demonstrated membrane echoes that were suggestive of endophthalmitis supported with thickened retinal choroid sclera complex. The intra-vitreous aspirate and urine specimen revealed presence of yeast-like fungus under direct microscopy and culture, while the blood, sputum and vaginal swab samples proved negative. Microbiological evaluation of ocular and other clinical specimens clearly confirmed that the source of infection could be attributed to the urinary tract being infected with *C. albicans* which could have arisen from contamination. This report fortifies the possible risk of urinary tract infection as a causative agent in post-operative endophthalmitis.

Key words: Post-operative endophthalmitis, *Candida albicans*, urinary tract infection, risk of post-cataract endophthalmitis

Introduction

Post-operative infectious endophthalmitis is one of the most devastating complications that can be encountered after any intraocular procedure, especially after a cataract surgery.^{1,2} The incidence, risk factors, prophylaxis, and management of endophthalmitis have been widely reported in ophthalmic literature.¹⁻³ The ocular surface and adnexa acts as primary source for infectious agents in culture-positive cases of post-operative endophthalmitis.⁴ Many studies have demonstrated the predominance of bacteria as a cause of post-cataract surgical endophthalmitis, while fungal pathogens causing post-operative endophthalmitis are rare.¹⁻³ The yeast-like fungus *Candida albicans* has been reported as one of the common causes in endogenous endophthalmitis;³ endophthalmitis due to *C. albicans* of exogenous origin six months after the cataract surgery without any hematogenous dissemination in an immunologically healthy patient is rare. This case is analyzed in this report.

Correspondence: Dr. M. Jayahar Bharathi, Department of Microbiology & Molecular Biology, Aravind Eye Hospital & PG Institute of Ophthalmology, Tirunelveli, Tamil Nadu, India 627 001. E-mail: jayahar@tv.aravind.org

Case report

A 56-year-old woman presented with redness, pain, watering and diminution of vision in her right eye for the past month. Six months earlier, she had undergone an uncomplicated cataract surgery by phacoemulsification with implantation of a posterior chamber intraocular lens. There was no history of trauma, diabetes, hypertension, cardiac diseases or any ocular surface diseases. She had symptoms of photophobia and floaters. On examination, the best corrected visual acuity (VA) was 20/600 in the operated eye (right) and 20/30 in the left eye. She had been using ofloxacin eye drops six times a day at the time of presentation. Slit-lamp biomicroscopic examination revealed grayish white exudates (10 mm x 6 mm) in the inner lip of the corneal section and in the papillary area (4 mm x 3 mm) of the anterior chamber adherent to the corneal endothelium of the right eye. Incidence of associated corneal edema, severe anterior chamber reaction and hypopyon (0.5 mm) were recorded. Aqueous flares and cells were both 3+. Severe circumcorneal congestion was noted. Intraocular pressure was 20 and 18 mmHg in the right and left eye respectively. Fundus details were obscured partially due to corneal edema and anterior chamber reaction, but appeared with the absence of red reflex. The chest X-ray was normal with the blood sugar level touching 75.0 mg/dl during fasting and 98.0 mg/dl postprandially.

B-scan ultra-sonography demonstrated membrane echoes suggestive of endophthalmitis that were supported with thickened retinal choroid sclera complex. A clinical diagnosis of the post-operative endophthalmitis was made and aqueous humor (AH) was aspirated, and intraocular antibiotic injections of vancomycin (1 mg/0.1 ml) and amikacin (400 µgm/0.1 ml) were given. The microbiological analysis of the AH showed negative for presence of any microbes. The patient was treated with 0.3% ciprofloxacin eye drops hourly and 1% cyclopentolate eye drops three times a day. Oral ciprofloxacin 750 mg twice a day, and oral prednisolone 70 mg/day (1 mg/kg) were also administered. The left eye was normal. Based on the typical clinical findings of infectious endophthalmitis, IOL removal (due to the instability of the IOL) and core vitrectomy were performed along with repeated aspiration of the AH. The confirmatory diagnosis of infectious endophthalmitis was established by the microbiological evaluation of AH and vitreous fluid (VF), which were collected by using standard techniques. The part of the collected intraocular aspirates were immediately inoculated into the blood agar, chocolate agar, Sabouraud's dextrose agar and

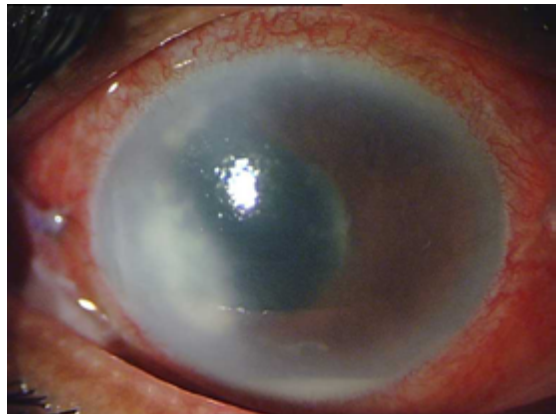


Fig. 1. Slit-lamp biomicroscopic photograph showing an inflamed eye with grayish white exudates (10 mm x 6 mm) extending from the inner lip of the corneal section extending up to the papillary zone (4 mm x 3 mm) associated with hypopyon (0.5 mm) and vitreous exudates.

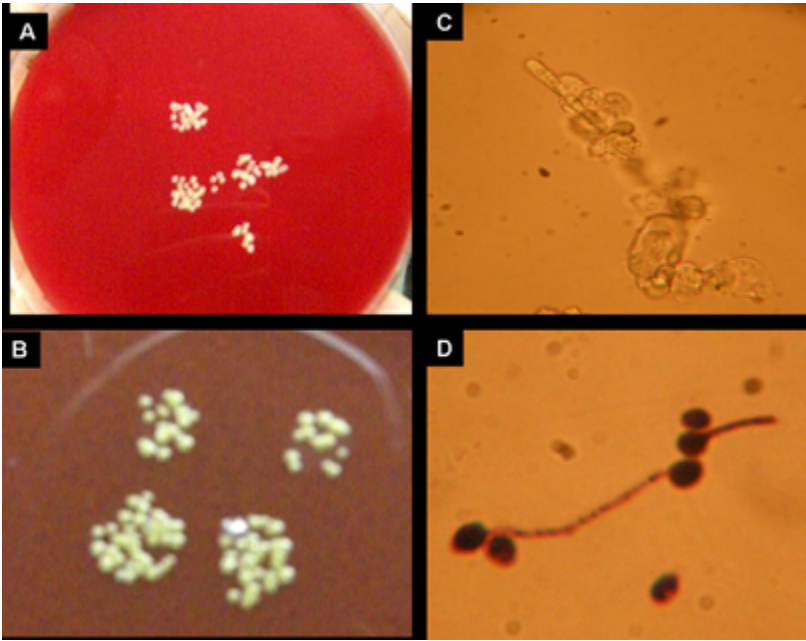


Fig. 2.

A. *Candida albicans* colonies at the inoculated sites on the blood agar plate inoculated with intra-vitreous aspirate.

B. *Candida albicans* colonies at the inoculated sites on the chocolate agar plate inoculated with intra-vitreous aspirate.

C. Vitreous aspirates mounted with 10% potassium hydroxide solution showing long pseudohyphae along with clusters of spherical shaped blastoconidia at the septa of a yeast-like organism.

D. Vitreous aspirate stained with the Gram-staining technique, showing long pseudohyphae along with clusters of spherical shaped blastoconidia at the septa of a yeast-like organism.

also into the liquid media- thioglycolate medium and brain-heart infusion broth in the operating room.⁵ The remaining part of the intraocular aspirates were smeared for 10% KOH wet mounting and Gram-staining procedures.⁵ In the early morning mid-stream urine, vaginal swab, sputum and blood specimens were collected and subjected to microbiological analysis using standard protocols.^{6,7} The inoculated plates for bacterial isolation were incubated both aerobically and anaerobically, while the fungal Sabouraud's dextrose agar plates were incubated under biochemical oxygen demand. The 10% KOH wet mounting and gram-stained smear of AH, VF and urine specimen were found to be positive for a yeast-like fungus. Similarly, the culture of AH, VF and urine specimen were also found to be positive for (significant) *Candida albicans* growth. The blood specimen showed no growth, while the sputum specimen was negative for the growth of *Candida* species even after seven days after the incubation. Standardized microbiological evaluation protocols were followed for ocular and non-ocular clinical specimens.⁵⁻⁷ The pathological analysis of peripheral blood smear showed a normal blood picture and no evidence for immuno-competency disorders or parasitic

infections. After the yeast-like fungus (*Candida* sp.) was seen in smears of AH and VF without the presence of bacteria, the treatment regimen was changed to intra-vitreous voriconazole twice and topical 0.15% amphotericin B and 1% voriconazole topically on an hourly basis. In spite of intensive antifungal therapy, the vision in that eye could not be restored, resulting in phthisis.

Discussion

The microbial etiology of endophthalmitis varies with geographical location and also from person to person depending on the microbial flora at the ocular surface.¹⁻³ The most common infecting organism of the post-operative endophthalmitis following cataract extraction are the coagulase-negative *Staphylococcus* species.^{1,2,3} Gram-negative bacteria and anaerobes are much less frequent causative agents.¹⁻³ A review of the literature showed that fungal endophthalmitis is common among patients with systemic debilitating diseases, malignancy, intravenous drug use, chemotherapy, systemic antibiotics and prolonged corticosteroids therapy, alcoholism and diabetes.⁸ However, filamentous fungi are also frequently encountered among traumatic endophthalmitis and endophthalmitis due to fungal keratitis, while the yeast-like fungi *Candida* species are common among endogenous endophthalmitis in cases with candidemia.⁹ *Candida* endophthalmitis and disseminated candidiasis usually occurs in patients with parental drug abuse and in severely ill patients whose immune mechanisms have got altered.

Candida species are part of the human flora; they exist commensally. When the immune system is compromised, these organisms become potentially pathogenic.⁸⁻¹⁰ In the present case, endophthalmitis occurred six months after the post-operative period due to *C. albicans* which was recovered from two of the four cultured specimens, viz., vitreous aspiration and urine. Blood culture was negative and hence the evidence for candidemia or hematogenous dissemination of *Candida* to the eye was eliminated. Higher rates of positive urine cultures have been reported in candidemia and immunocompromised cases.⁸ It is construed from the study that the risk of developing endophthalmitis could arise from urinary tract infections harboring *C. albicans* which could be ascribed to contamination through improperly cleaned after urination, or unclean hands, that might have acted as potent carriers. The continuous contact of the operated eye and its adnexal structures with the contaminated hands carrying *C. albicans* could be the primary cause of eye infection in our case. This report documents and fortifies the risk of urinary tract infection as a causative agent in post-operative endophthalmitis.

References

1. Lemley CA, Han DP. Endophthalmitis: A review of current evaluation and management. *Retina* 2007;27:662-680.
2. Ramakrishnan R, Bharathi MJ, Shivkumar C, Mittal S, Meenakshi R, Khadeer MA, et al. Microbiological profile of culture-proven cases of exogenous and endogenous endophthalmitis: a 10-year retrospective study. *Eye* 2009;23:943-956.
3. Kresloff MS, Castellarin AA, Zarbin MA. Endophthalmitis. *Surv Ophthalmol* 1998;43:193-224.
4. Speaker MG, Milch FA, Shaf MK, Eisner W, Kreiswirth BN. Role of external bacterial flora in the pathogenesis of acute postoperative endophthalmitis. *Ophthalmology* 1991;98:639-649.

5. Wilhelmus KR, Liesegang TJ, Osato MS, Jones DB. Cumulative Techniques and Procedures in Clinical Microbiology 13A, Laboratory Diagnosis of Ocular Infections. Washington DC: American Society for Microbiology, 1994.
6. Clarridge J, Johnson JR, Pezzlo M. Cumulative Techniques and Procedures in Clinical Microbiology 2B, Laboratory Diagnosis of Urinary Tract Infections. Washington DC: American Society for Microbiology, 1998.
7. Dunne WM, Nolte FS, Wilson M. Cumulative Techniques and Procedures in Clinical Microbiology 1B. Blood Cultures III. Washington DC: American Society for Microbiology, 1997.
8. Chakrabarti A, Shivaprakash MR, Singh R, Tarai B, George VK, Fomda BA, Gupta A. Fungal endophthalmitis: Furteen years' experience from a center in India. *Retina* 2008;28:1400-1407.
9. Donahue SP, Craig MG, Zuravleff JJ, Eller AW, Nguyen MH, Peacock JE Jr, et al. Intraocular candidiasis in patients with candidemia. Clinical implications derived from a prospective multicenter study. *Ophthalmology* 1994;101:1302-1309.
10. Rensch F, Schlichtenbrede FC, Jonas JB. Postoperative mycotic endophthalmitis. *J Cataract Refract Surg* 2010;36:1233-1234.