

# Anterior segment optical coherence tomography of intrastromal corneal cysts

Deepmala Mazumdar, Barsha Lal, Rashima Asokan

Medical and Vision Research Foundation, Sankara Nethralaya, Chennai, India;  
Elite School of Optometry, Chennai, India

## Abstract

We report a case of six-year-old boy who presented with a progressive intracorneal cyst in the left eye. Anterior segment optical coherence tomography (AS-OCT) was performed, and it showed the location of the cyst in the corneal stroma. Its dimension was measured to be 7.09 × 2.12 mm. The cyst aspiration was successfully done. AS-OCT helped in the management and follow-up of the condition.

**Keywords:** anterior segment, AS-OCT, intracorneal cyst

## Introduction

Intracorneal cysts are uncommon, progressive lesions.<sup>1,2</sup> The intracorneal cysts reported so far include epithelial cysts, intrastromal cysts, and pseudocysts.<sup>3,4</sup> In most of the cases, intracorneal cysts were found secondary to trauma or surgery such as cataract extraction, keratoplasty, or any other surgical intervention of cornea.<sup>4,5</sup> In congenital cases, the origin is not known.<sup>5</sup> It would also be misdiagnosed as foreign bodies, herpetic keratitis, and sclerosing keratitis.<sup>3,5,6</sup> These cysts are often found to be progressive in nature, which can cause deterioration of vision by involving the visual axis and can result in cosmetic deformity.<sup>3,6</sup>

Anterior segment optical coherence tomography (AS-OCT, Visante OCT; Carl Zeiss Meditec AG, Jena, Germany) is a noninvasive imaging technology, performed in sitting position, and provides detailed cross-sectional imaging of ocular anterior segment structures. AS-OCT uses infrared light, and imaging is based on the principle of low-coherence interferometry. It measures the delay of infrared light reflected from tissue structures.<sup>7,8</sup> AS-OCT is found as a valuable tool in diagnosing and monitoring the treatment progress in cases like ocular trauma and tumors.<sup>7,8</sup>

Here, we report a case of six-year-old boy with a progressive intrastromal corneal cyst followed up with AS-OCT.

**Correspondence:** Ms. Rashima Asokan, Medical and Vision Research Foundation, Sankara Nethralaya, Chennai, India.

E-mail: [rashi.ashok@gmail.com](mailto:rashi.ashok@gmail.com); [rashima@snmail.org](mailto:rashima@snmail.org)

## Case report

A healthy six-year-old boy presented to the clinic with slowly progressing white opacity on cornea associated with mild pain, photophobia, and watering in the left eye since birth. He was complaining of diminution of vision in the left eye. There was no trauma, surgery, or any other significant medical history. His birth history was found normal. There was no significant family history reported. He reported that he was diagnosed to have the corneal cyst in his left eye elsewhere and underwent drainage with transscleral cryotherapy (TSC) with fibrin glue four years ago. His visual acuity for distance was found to be 6/6 in the right eye and 2/60 in the left eye. Slit lamp examination revealed whitish corneal opacity in the left eye covering the pupillary area sparing 0.5 mm superotemporally; the iris was not adherent (Fig. 1).

AS-OCT was done in four quadrants to locate the cyst exactly and its extension. The cyst was located in corneal stroma extending 360°, and the dimension was measured as 7.09 × 2.12 mm (Fig. 2). Central corneal thickness was found as 2,000 µm.

As the cyst was found sight-threatening, it was aspirated with trichloroacetic acid. The surgery was uneventful. Follow-up on the first day after surgery showed collapsed cyst cavity and mild corneal edema with a small corneal epithelial defect. The patient was comfortable and no specific complaint was reported. The patient returned to the clinic nine months after surgery.

Examination revealed his best corrected visual acuity of 6/6 for the right eye and 6/36 for the left eye. Postoperative slit lamp examination revealed the presence of mild scar in the left eye. AS-OCT was repeated to check if the cyst was

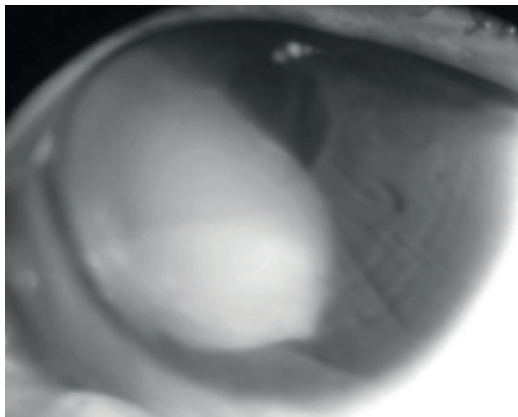


Fig. 1. Preoperative slit lamp image of cyst.

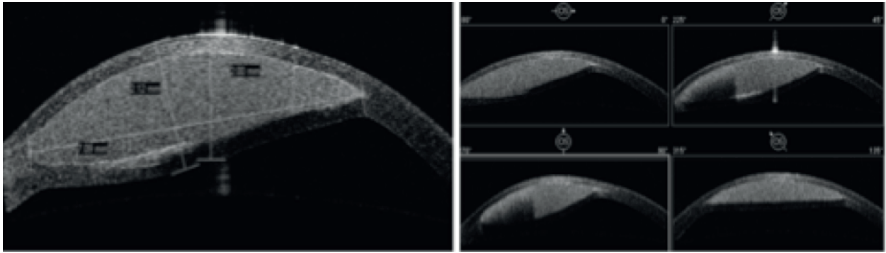


Fig. 2. Preoperative AS-OCT image with dimensions and extension of cyst.

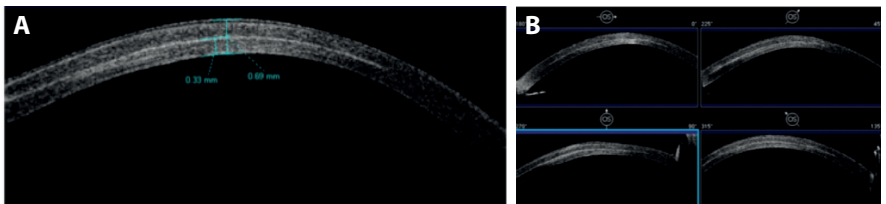


Fig. 3. (A) Postoperative AS-OCT high-resolution corneal image showing central corneal thickness and scar depth. (B) Postoperative AS-OCT corneal quadrant image.

present, and the cyst was found to be completely resolved (Fig. 3A and B). Scar was measured to be 330  $\mu\text{m}$ , and the central corneal thickness was reduced to 690  $\mu\text{m}$  (Fig. 3A).

Patient's left eye vision was not improving even after cyst aspiration, and he was diagnosed as amblyopic in the left eye and was advised for part-time occlusion therapy in the right eye for four hours in a day in order to regain his vision.

## Discussion

Cyst progression is indolent in nature and generally painless.<sup>6,9</sup> Thus, surgical excisions are not advised until there is a threat to vision by the cyst or it is progressive.<sup>9</sup> There are different treatment modalities reported in the literature. It includes cyst aspiration, drainage, cyst wall excision, cryotherapy, and lamellar or penetrating keratoplasty.<sup>6,9</sup>

To date, slit lamp photography has been used to detect progression and follow-up of cases with intracorneal cysts, which does not provide the actual information regarding the extension of the cysts and is not reproducible.

AS-OCT allows precise diagnosis of these cysts by providing exact location and even permits to measure the dimension of the cyst. Preoperative AS-OCT findings enabled the surgical decision by providing dimension quantitatively, and postoperative following up on the case becomes easier. In AS-OCT, cornea can be imaged in four quadrants together and it enables 360° scanning.

Therefore, the extension of the cysts can be imaged. Differential pachymetry map can be generated automatically and is helpful in following up the case. Unlike ultrasound biomicroscopy, AS-OCT does not require direct probe contact to the eye.

### Conclusion

AS-OCT is easy to perform and is not time-consuming. This will help in monitoring the progression of cysts with quantitative measurements. This case report highlights the use of AS-OCT in the management of intrastromal corneal cysts.

### References

1. Bloomfield SE, Jakobiec FA, Iwamoto T. 5. Traumatic intrastromal corneal cyst. *Ophthalmology*. 1980 Sep 1;87(9):951-955.
2. Rao SK, Fogla R, Biswas J, Padmanabhan P. Corneoscleral epithelial cysts: evidence of developmental etiology. *Cornea*. 1998 Jul;17(4):446-450.
3. Mifflin MD, Byers TL, Elliot R, Hoffman R. Surgical treatment of an intrastromal epithelial corneal cyst. *Cornea*. 2001 Mar 1;20(2):222-225.
4. Hosseini Tehrani M, AghaMohammadi R, Mohammadi SF, Rajabi MT, AghaZadeh N. Presumable corneal lymph cyst: a case report. *Iran J Ophthalmol*. 2009 Aug 15;21(3):60-62.
5. Lazzaro DR, Mostafavi D. Massive intracorneal cyst in a patient with no ocular symptoms. *Eye Contact Lens*. 2012 Jan 1;38(1):66-67.
6. Javadi MA, Sharifi A, Hashemian SJ, Yazdani S, Parvizi G, Kanavi MR. Management of intracorneal epithelial cysts with ethanol irrigation and cyst wall excision: a clinicopathologic report. *Cornea*. 2006 May 1;25(4):479-481.
7. Ramos JL, Li Y, Huang D. Clinical and research applications of anterior segment optical coherence tomography—a review. *Clin Exp Ophthalmol*. 2009 Jan 1;37(1):81-89.
8. Wylegala E, Dobrowolski D, Nowińska A, Tarnawska D. Anterior segment optical coherence tomography in eye injuries. *Graefes Arch Clin Exp Ophthalmol*. 2009 Apr 1;247(4):451-455.
9. Bhatt PR, Ramaesh K. Intrastromal corneal limbal epithelial implantation cyst. *Eye*. 2007 Jan 1;21(1):133-135.