

A modified technique for trabeculectomy

Syed Shoeb Ahmad

Department of Ophthalmology, Queen Elizabeth Hospital, Kota kinabalu, Malaysia

Abstract

Aim or purpose: To present a modified technique of trabeculectomy.

Design: Ahmad's modified trabeculectomy technique aims to utilize subtle modifications to the classical trabeculectomy technique in order to achieve a better filtering bleb leading to lesser complications.

Methods: Retrospective interventional case series.

Results: Thirty-four patients underwent this surgery. There was a significant difference in the preoperative and postoperative median intraocular pressure (IOP; $z = 3.928$; $p < 0.001$). The postoperative IOP (median = 12) was significantly lower than the preoperative IOP (median = 28; interquartile range = 9).

Conclusion: This modification can prove to be an effective method to reduce IOP with minimal complications.

Keywords: endophthalmitis, filtering surgery, glaucoma, intraocular pressure, sclerostomy, trabeculectomy

Introduction

Glaucoma is a multifactorial disorder with the common denominator of retinal ganglion cell loss. There are a number of theories, including the mechanical, vascular and biochemical ones, which attempt to explain the causation of this multi-spectrum disorder called glaucoma.¹ The only risk factor that can be modulated currently is intraocular pressure (IOP). Thus, IOP is often used as a surrogate treatment goal to assess the efficacy of any glaucoma management strategy.

Surgical management of glaucoma still lacks a reliable, reproducible, resilient, and robust procedures to maintain a stable IOP throughout the lifetime of the patient without any complications. Since its introduction in the 1960s, trabeculectomy has remained the gold standard of glaucoma filtering surgeries (GFS). Following trabeculectomy, long-term control of IOP has been found to range from 55% to 98%.² However, this procedure remains unpredictable, with results varying from patient to patient and even from case to case performed by the same surgeon.³ It is also known that the more the risk factors for the procedure,

Correspondence: Dr. Syed Shoeb Ahmad, Department of Surgery, Ajmal Khan Tibbiya College, Aligarh, India.

E-mail: syedshoebahmad@yahoo.com

the higher the cumulative effect on the outcome.⁴ Other weaknesses of this procedure include the safety profile, complications such as short- and long-term risks of infection (endophthalmitis, blebitis), ocular hypotony, and others.⁵⁻¹³ As with all operative procedures performed on an open eye, this procedure carries the risk of infection. However, coupled with a thin, vulnerable conjunctival bleb, the situation is made grimmer.¹⁴ Not surprisingly, patients with cystic blebs carry a lifetime risk of bleb-related infections.¹⁵ Looking at the shortcomings of trabeculectomy, the door has opened for novel surgeries to be explored and improved upon.

The key factor that determines the success of trabeculectomy is the characteristic of the filtering bleb. Since bleb-related complications usually influence the outcome of GFS, we have developed some modifications to the classical trabeculectomy procedure. Our method, Ahmad's modified trabeculectomy technique (AMTT), is aimed primarily at overcoming the problems of bleb leakage and poor quality of blebs.

AMTT does not attempt to radically change the classical trabeculectomy procedure. Our modifications can be performed by any surgeon adept in trabeculectomy. AMTT targets to achieve the "much desired diffuse, non-cystic bleb" by promoting posterior flow by making an innovative "spout" configuration in the sclerostomy, tight suturing of the scleral flap anteriorly, and better healing by leaving a cuff of conjunctiva near the limbus.¹⁶

Materials and methods

Inclusion criteria for this prospective study were patients above 14 years of age who were diagnosed to have glaucoma based on their visual field defects, optic disc changes, uncontrolled IOPs despite maximal tolerable medical therapy, retinal nerve fibre thickness changes, central corneal thickness values, and gonioscopic appearance. Patients who did not achieve the target IOP consistently or had progressive visual field changes on at least two consecutive examinations despite maximal medical treatment underwent trabeculectomy using the AMTT procedure.

Surgical technique

Aseptic precautions were taken prior to starting surgery. A corneal traction suture was often used to rotate the eye downwards in order to obtain a good surgical exposure of the field of surgery. Subsequently, a conjunctival flap was fashioned. Unlike the usual fornix-based flaps which are flush to the cornea, we start the peritomy about 0.5 mm posterior to the limbus, leaving a margin of conjunctiva there. Adequate haemostasis is achieved by using a bipolar cautery.

We routinely use mitomycin-C (Kyowa Hakko Kirin Co., Japan). The agent is diluted to a concentration of 0.02% solution. Subsequently, soaked gel sponges are applied to the episcleral tissues. The sponges are kept for 2 to 3 minutes, with the conjunctival flap blanketed over them by holding the edges away from the sponges. After 2 to 3 minutes, the sponges are removed and the area irrigated with nearly 20 ml of balanced salt solution (BSS).

A bevelled limbal stab incision is made in the 9 o'clock region after the mitomycin-C is washed out. Using a 15° knife, a square or trapezoidal scleral flap measuring around 4 × 4 mm is fashioned, hinged at the limbus. The dissection is completed using a crescent knife. Subsequently, a stab incision is made into the anterior chamber just behind the hinge of the scleral flap. Using a 15° blade, the anterior chamber is entered from the centre. A Kelly Descemet punch (1 mm diameter) is then used to cut the deep scleral/trabecular layer in order to perform the sclerostomy. Either two adjacent or overlapping snips are made by the punch. Subsequently, we go back to the centre of the sclerostomy and, tilting the punch downwards, make a half-thickness snip in the posterior lip of the sclerostomy. This produces a spout-like configuration in the centre, allowing aqueous to flow posteriorly rather than towards the sides (Figs. 1 and 2).

A peripheral iridectomy is then made. The scleral flap is sutured with five 10/0 nylon sutures. We keep the anterior two sutures on either side relatively tight while the rest of the three are kept loose. BSS is injected from the limbal stab incision to titrate the flow. The sutures are adjusted to have a smooth flow through the fistula without collapse of the anterior chamber on applying pressure.

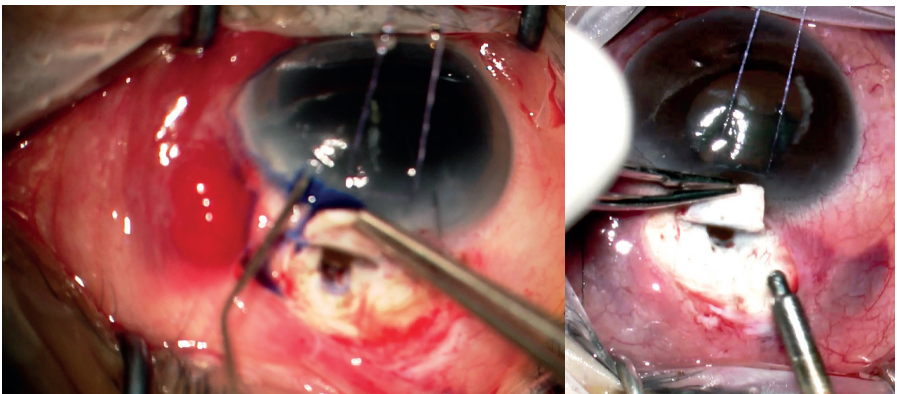


Fig. 1. Left, right: An intraoperative view of the spout configuration.

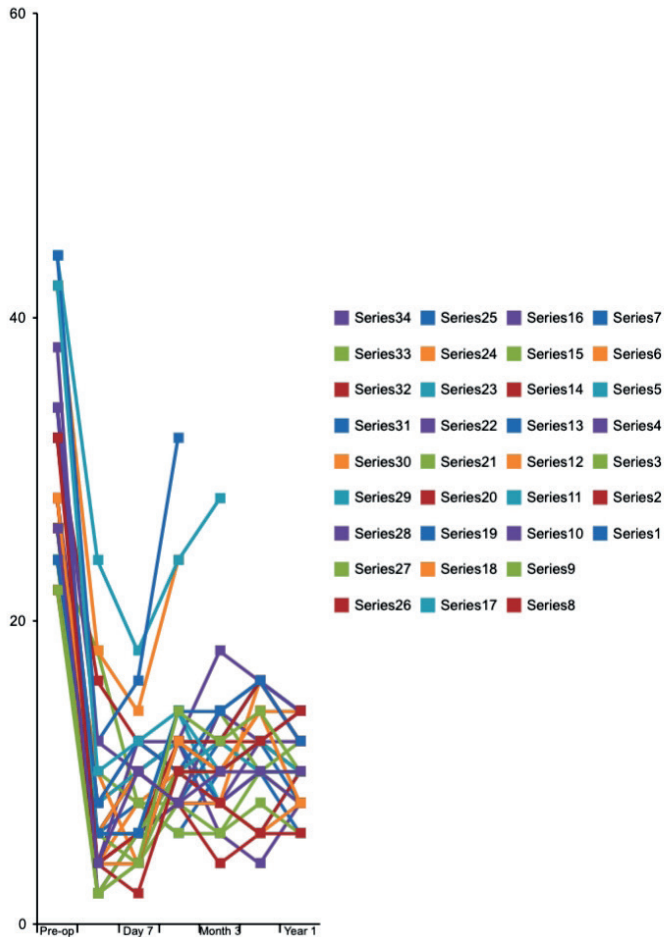


Fig. 2. Graphical representation of changes in IOP during study.

This modification has two advantages: one, it directs flow more posteriorly; and second, in the event the patient requires laser suture lysis subsequently, it is easier to lyse the anterior two tight sutures.

Postoperative review

A total of 34 patients (34 eyes) underwent trabeculectomy using this technique. Visual acuity was determined by the Snellen chart using an auto chart projector (CP-690, Nidek Corp, Japan). IOP was measured by Goldmann applanation tonometer (Carl Zeiss Meditec AG, Jena, Germany).

Patients were followed up for 1, 7, and 30 days postoperatively. Subsequently, they were reviewed according to glaucoma status, ranging from 3- to 6-monthly intervals. The first patient was operated 2 years back using this technique. However, we have included patients who completed 1 year of follow-up. The primary outcome measures analysed in this study were: 1. diffuse bleb with no leak in the immediate postoperative period; and 2. IOP between 6 and 18 mmHg. The secondary outcome measures analysed were: 1. well-functioning bleb without encapsulation/cystic changes; and 2. final IOP between 6 and 18 mmHg without medications.

Results

Descriptive statistics were used to depict baseline data and postoperative complications of the patients. Wilcoxon signed rank test was used to examine the difference between preoperative and postoperative IOP. All analyses were done using Statistical Package for the Social Sciences version 16.

Thirty-four patients were enrolled in this study. One eye of each patient underwent the procedure. We screened all patients for inclusion/exclusion criteria and performed the standard AMTT procedure as described previously. The age of the subjects ranged from 54 to 74 years, with a mean standard deviation of 64 (12). There were 10 males (29.41%) and 24 females (70.58%) in the study. Regarding the type of glaucoma, 22 (64.70%) had angle-closure glaucoma, 10 (29.41%) had open-angle glaucoma, and 2 (5.88%) had neovascular glaucoma. All patients were on four anti-glaucoma medications (a β -blocker, an α -agonist, a prostaglandin analogue, and a topical carbonic anhydrase inhibitor). We put some patients on oral carbonic anhydrase inhibitors for short periods of time while they waited for surgery.

There was a significant difference in the preoperative and postoperative median IOPs ($z = 3.928$; $p < 0.001$). The postoperative IOP (median = 12) was significantly lower than the preoperative IOP (median = 28; interquartile range = 9) (Table 1 and Fig. 3).

All 34 patients underwent AMTT and had follow-ups on day 1, day 7, day 30, 3 months, 6 months, and 3- to 6-monthly intervals thereafter. Early postoperative complications (within the first 3 months) include a flat bleb in three (8.82%) and conjunctival bleb leak in four (11.76%) patients, which occurred in the first week of the postoperative period. The only late complication (around 3 months postoperatively) noted by us was a flat bleb which developed in three (8.82%) patients (Table 1 and Fig. 3).

A modified technique for trabeculectomy

Table 1. Results following AMTT procedure.

Number	Preop	Day 1	Day 7	Month 1	Month 3	Month 6	Year 1
1	26	6	8	6	10	12	8
2	32	8	10	12	10	12	10
3	24	18	8	6	6	10	8
4	28	8	12	12	6	4	8
5	26	6	6	14	8	6	10
6	42	18	14	24			
7	34	6	10	12	8	10	6
8	28	4	6	8	4	6	10
9	26	2	4	8	6	8	6
10	24	4	12	10	8	12	14
11	44	24	18	24	28		
12	28	4	8	10	8	16	12
13	26	6	10	8	12	16	14
14	32	16	12	10	12	12	10
15	26	10	8	8	14	10	12
16	38	2	6	8	8	10	8
17	24	8	10	12	12	16	12
18	22	6	10	8	8	6	8
19	44	12	16	32			
20	28	4	6	10	8	6	6
21	26	6	4	10	12	10	10
22	34	12	10	8	14	12	12
23	24	6	6	10	12	10	10
24	26	10	4	12	10	14	14
25	32	8	12	10	14	16	14
26	22	4	6	12	12	16	12
27	24	2	6	10	10	12	10
28	34	4	4	12	18	16	14
29	42	10	12	14	10	12	10
30	28	4	4	12	10	14	8
31	24	6	6	14	14	16	12
32	32	4	2	10	10	12	14
33	22	2	4	14	12	14	10
34	26	4	10	8	10	10	10

Discussion

Trabeculectomy remains the gold standard to measure the success of innovations in GFS.^{3,17,18} Trabeculectomy itself is being modified to make it more safe, efficient and predictable.¹¹ Despite all these efforts, trabeculectomy is beset with complications and failures at every stage.^{5,6,19-21} In our study, 34 patients with open-angle (10), closed-angle (22), and neovascular glaucoma (2) underwent trabeculectomy due to uncontrolled IOPs with maximal medical treatment (four topical anti-glaucoma medications). Three patients had previously undergone trabeculectomies in the past, but IOP had increased,, requiring a return to four or more anti-glaucoma medications. All surgeries were performed by the author using the modifications described earlier.

We performed all surgeries in this series under sub-Tenon anaesthesia using 2% lidocaine injection. However, trabeculectomies can also be performed using lidocaine hydrochloride gel or jelly and intracameral lidocaine.²²⁻²⁴

We performed a fornix-based conjunctival flap. However, our peritomy did not reach up to the limbus. We left a cuff of conjunctiva about 0.5 mm posterior to the limbus. The two cut edges of the conjunctiva can be easily sutured and the blood vessels at both ends of the flaps promote a more rapid, more natural healing response. Excessive cautery of the episcleral vessels should be avoided to prevent contracture of the scleral flap, which may lead to uncontrolled leakage.

Trabeculectomy can be performed by either a limbus or fornix-based conjunctival flap. Limbus-based procedures are reported to have higher rates of cystic bleb formation, excessive drainage, and, according to Lemon *et al.*, more bleb leaks.²⁵ While limbus-based conjunctival flaps can adhere to the deeper tissues at their periphery, fornix-based flaps have a propensity to fail due to the formation of diffuse conjunctival adhesions and fibrosis spreading along the anterior part of the bleb.²⁶⁻²⁸ We have termed this band of fibrosis as "band of steel", which is more common in darker individuals and spreads around the bleb area, leading to loss of function of the trabeculectomy. A trabeculectomy with a leaking bleb can have an adverse effect on the success rate of GFS.^{7,10,29-31} Bleb leaks occur due to improper closure of the conjunctival flaps or inadvertent conjunctival buttonholes.³²⁻³⁵ Late bleb leaks are usually spontaneous and occur in cystic, thin-walled blebs.³⁶⁻⁴¹ The Ibadan Study found shallow anterior chambers as the most common postoperative complication after trabeculectomy.⁴²

In our study, three patients had a flat bleb and four had a bleb leak in the immediate postoperative period. All patients with the flat bleb underwent initial massage and subsequent laser suture lysis about one week after surgery. None required further surgical modification of the bleb. The patient with the leaking bleb was managed by application of a pressure-patch for two days. One patient with neovascular glaucoma underwent an anterior chamber washout

due to postoperative hyphema. Late bleb failure occurred in the two neovascular glaucoma patients and one very dark-skinned individual. On exploration and revision of the bleb, we found extensive fibrosis in the bleb area. Although revision of the bleb was done in all three cases, the two patients with neovascular glaucoma did not do well postoperatively and had to be restarted on antiglaucoma medications.

The size of the scleral flap in AMTT was kept around 4×4 mm. The shape and size of scleral flaps can vary between rectangular, triangular, and rhomboid. However, a study has shown that increasing the scleral flap size leads to an increase of 48.55% in aqueous egress. Also, a square flap increases aqueous drainage by 36.26% compared with a triangular flap of equivalent area. Thus, a 4×4 mm scleral flap used in our technique appears to be an ideal size to attain maximal aqueous outflow.⁴³

In some surgical techniques, the side incisions of the scleral flap do not reach up to the limbus. This supposedly encourages posterior outflow of aqueous. However, these techniques also recommend sclerostomy incisions to be as anterior and corneal as possible to reduce bleeding and inadvertent injury or exposure of the ciliary body.⁴⁴ A scleral flap hinged posterior to the limbus does not provide adequate visualization of the surgical area anteriorly near the limbus. This increases the risk of scleral flap amputation when manipulations are performed to create a sclerostomy. Therefore, when we fashion the flap, the side incisions reach up to the limbus. This makes it easier to perform anterior sclerostomies. However, when we suture the scleral flap, the anterior two sutures are applied tightly. This encourages aqueous to flow posteriorly and is also convenient for subsequent laser suture lysis. In order to prevent the anterior chamber from collapsing, the scleral flap should be secured first with a posterior suture, after which the two anterior sutures can be applied.

In order to encourage posterior flow of aqueous, we devised another modification to the sclerostomy. After the entire sclerostomy is made as usual, the Kelly Descemet punch is brought back to the centre and tilted down and backwards to make a half-thickness cut in the posterior lip of the sclerostomy. This produces a "spout"-like configuration in the centre. Aqueous is funnelled out of this spout posteriorly, thus encouraging posterior, diffuse blebs. One should be careful while making the spout to have only a half-thickness scleral snip. This avoids any inadvertent injury to the choroid.

A failing bleb in the early postoperative period can be managed by digital massage, scleral flap suture lysis, or the removal of a releasable suture. Argon laser suture lysis can be done two days to two weeks postoperatively. However, this procedure may not be possible at times due to a thick overlying Tenon's capsule, postoperative inflammation, and subconjunctival haemorrhage. However, in our

modification, the tight sutures are applied anteriorly, facilitating lysis of these sutures compared to posterior, deeper sutures.^{45,46}

Some of the popular methods recommend application of mitomycin-C after the scleral flap is made. They claim to have found scar tissue in the subscleral space upon re-exploration.⁴⁴ This is probably the “band of steel” that we have found in patients who require revision of the bleb. However, we avoid using antimetabolites after making the scleral flap. Any iatrogenic holes in the bed of the sclera, especially in cases of advanced glaucoma or myopes, may lead to increased intraocular absorption of the antimetabolite. Also, in case the scleral integrity is compromised, the antimetabolite has to be withheld.

Some techniques for conjunctival closure fashion grooves in the cornea and sutures are placed through them.⁴⁴ Such methods involve manipulating a cornea previously exposed to the antimetabolite. There is also a potential for inducing irregular astigmatism when sutures are applied over the cornea. By leaving a cuff of conjunctiva at the limbus, we are able to suture the two cut ends of the conjunctiva, providing a more secure and comfortable closure.

Some drawbacks of this study include the absence of control eyes and a relatively short follow-up of approximately one year. With this preliminary data at hand, we would like to continue evaluating the long-term results of this process. However, this modification is a simple and effective enhancement of the classic trabeculectomy technique and can be adopted by all surgeons performing GFS.

References

1. Ahmad SS, Ghani SA, Rajagopal TH. Current concepts in the biochemical mechanisms of glaucomatous neurodegeneration. *J Curr Glaucoma Pract.* 2013;7:49-53.
2. Cankaya AB, Elgin U. Comparison of the outcome of repeat trabeculectomy with adjunctive Mitomycin C and initial trabeculectomy. *Korean J Ophthalmol.* 2011;25:401-408.
3. Kahook MY. Glaucoma surgery: how do we get from here to there? *Middle East Afr J Ophthalmol.* 2009;3:105-106.
4. Agarwal HC, Sharma TK, Sihota R, Gulati V. Cumulative effect of risk factors on short-term surgical success of Mitomycin augmented trabeculectomy. *J Postgrad Med.* 2002;48:92-96.
5. Zahid S, Musch DC, Niziol LM, Lichter PR. Collaborative Initial Glaucoma treatment Study Group. Risk of endophthalmitis and other long-term complications of trabeculectomy in the Collaborative Initial Glaucoma treatment Study (CIGTS). *Am J Ophthalmol.* 2013;155:674-680.
6. La Borwit SE, Quigley HA, Jampel HD. Bleb reduction and bleb repair after trabeculectomy. *Ophthalmology.* 2000;107:712-718.
7. Lee GA, Holcombe DJ. Surgical revision of dysfunctional filtration blebs with bleb preservation, sliding conjunctival flap and fibrin glue. *Eye.* 2010;24:947-953.
8. Gedde SJ, Herndon LW, Brandt JD, Budenz DL, Feuer WJ, Schiffman JC. Tube versus Trabeculectomy Study Group. Postoperative complications in the tube versus trabeculectomy (TVT) study during five years of follow-up. *Am J Ophthalmol.* 2012;153:804-814.
9. Edmunds B, Thompson JR, Salmon JF, Wormald RP. The National Survey of Trabeculectomy. III. Early and late complications. *Eye.* 2002;16:297-303.

A modified technique for trabeculectomy

10. Radhakrishnan S, Quigley HA, Jampel HD, et al. Outcomes of surgical bleb revision for complications of trabeculectomy. *Ophthalmology*. 2009;116:1713-1718.
11. Stalmans I, Gillis A, Lafaut A-S, Zeyen T. Safe trabeculectomy technique: long term outcome. *Br J Ophthalmol*. 2006;90:44-47.
12. Coleman AL. Advances in glaucoma treatment and management: surgery. *Invest Ophthalmol Vis Sci*. 2012;53:2491-2494.
13. Vijaya L, Manish P, Ronnie G, Shantha B. Management of complications in glaucoma surgery. *Indian J Ophthalmol*. 2011;59(suppl 1):S131-S140.
14. Watson PG, Jakeman C, Ozturk M, Barnett MF, Barnett F, Khaw KT. The complications of trabeculectomy (a 20-year follow-up). *Eye*. 1990;4:425-438.
15. Casson R, Rahman R, Salmon JF. Long term results and complications of trabeculectomy augmented with low dose Mitomycin C in patients at risk for filtration failure. *Br J Ophthalmol*. 2001;85:686-688.
16. Papadopoulos M, Khaw PT. Improving glaucoma filtering surgery. *Eye (Lond)*. 2001;15:131-132.
17. Gessesse GW, Damji KF. Advanced glaucoma: management pearls. *Middle East Afr J Ophthalmol*. 2013;20:131-141.
18. Furrer S, Menke MN, Funk J, Toteberg-Harms M. Evaluation of filtering blebs using the 'Wuerzburg bleb classification score' compared to clinical findings. *BMC Ophthalmol*. 2012;12:24.
19. Sharaawy T, Bhartiya S. Surgical management of glaucoma: evolving paradigms. *Indian J Ophthalmol*. 2011;59(suppl 1):S123-S130.
20. Ramakrishnan R, Khurana M. Surgical management of glaucoma: an Indian perspective. *Indian J Ophthalmol*. 2011;59(suppl):S118-S122.
21. Yamamoto T, Kuwayama Y. Interim clinical outcomes in the collaborative bleb related infection incidence and treatment study. *Ophthalmology*. 2011;118:453-458.
22. Page MA, Fraunfelder FW. Safety, efficacy, and patient acceptability of lidocaine hydrochloride ophthalmic gel as a topical ocular anesthetic for use in ophthalmic procedures. *Clin Ophthalmol*. 2009;3:601-609.
23. Carrillo MM, Buys YM, Faingold D, Trope GE. Prospective study comparing lidocaine 2% jelly versus sub-Tenon's anaesthesia for trabeculectomy surgery. *Br J Ophthalmol*. 2004;88:1004-1007.
24. Guijjarro-Oria FJ, Gutierrez-Diaz E, Dorado-Lopez-Rosado AM, Montero-Rodriguez M, Lago-Llinas MD, Mencia-Gutierrez E. Prospective study of cooperation and satisfaction in glaucoma surgery under sub-Tenon's anesthesia. *Arch Soc Esp Oftalmol*. 2013;88:102-107.
25. Lemon LC, Shin DH, Kim C, Bendel RE, Hughes BA, Juzych MS. Limbus-based vs fornix-based conjunctival flap in combined glaucoma and cataract surgery with adjunctive mitomycin C. *Am J Ophthalmol*. 1998;125:340-345.
26. Alwitary A, Patel V, King AW. Fornix vs limbus based trabeculectomy with mitomycin C. *Eye (Lond)*. 2005;19:631-636.
27. Wells AP, Cordiero MF, Bunce F, Khaw PT. Cystic bleb formation and related complications in limbus-versus fornix-based conjunctival flaps in pediatric and young adult trabeculectomy with Mitomycin C. *Ophthalmology*. 2003;110:2192-2197.
28. Kuroda U, Inoue T, Awai-Kasaoka N, Shobayashi K, Kojima S, Tanihara H. Fornix-based versus limbal-based conjunctival flaps in trabeculectomy with Mitomycin C in high-risk patients. *Clin Ophthalmol*. 2014;15(8):949-954.
29. Gedde SJ. Results from the tube versus trabeculectomy study. *Middle East Afr J Ophthalmol*. 2009;16:107-111.
30. Filippopoulos T, Hanna E. Correlation of filtration bleb morphology with histology. *Int Ophthalmol Clin*. 2009;49:71-82.
31. Anand N, Arora S, Clowes M. Mitomycin C augmented glaucoma surgery: evolution of filtering bleb avascularity, transconjunctival oozing and leaks. *Br J Ophthalmol*. 2006;92:175-180.

32. Rai P, Kotecha A, Kaltsos K, et al. Changing trends in the incidence of bleb-related infection in trabeculectomy. *Br J Ophthalmol*. 2012;96:971-975.
33. Melo AB, Razeghinejad MR, Palejwala N, et al. Surgical repair of leaking filtering blebs using two different techniques. *J Ophthalmic Vis Res*. 2012;7:281-288.
34. Alwitary A, Rotchford A, Patel V, Abedin A, Moodie J, King AJ. Early bleb leak after trabeculectomy and prognosis for bleb failure. *Eye (Lond)*. 2009;23:858-863.
35. Henderson HW, Ezra E, Murdoch IE. Early postoperative trabeculectomy leakage: incidence, time course, severity, and impact on surgical outcome. *Br J Ophthalmol*. 2004;88:626-629.
36. Azuara-Blanco A, Katz LJ. Dysfunctional filtering blebs. *Surv Ophthalmol*. 1998;43:93-126.
37. Song A, Scott IU, Flynn HW Jr, Budenz DL. Delayed onset bleb-associated endophthalmitis: clinical features and visual acuity outcomes. *Ophthalmology*. 2002;109:985-991.
38. Mandal AK. Management of the late leaking filtration blebs. A report of seven cases and a selective review of the literature. *Indian J Ophthalmol*. 2001;49:247-254.
39. Bochmann F, Azuara-Blanco A. Interventions for late trabeculectomy leak. *Cochrane Database Syst Rev*. 2012;12:9.
40. Feldman RM, Altaher G. Management of late-onset bleb leaks. *Curr Opin Ophthalmol*. 2004;15:151-154.
41. DeBry PW, Perkins TW, Heatley G, Kaufman P, Brumback LC. Incidence of late-onset bleb-related complications following trabeculectomy with mitomycin. *Arch Ophthalmol*. 2002;120:297-300.
42. Ashaye AO, Komolafe OO. Post-operative complication of trabeculectomy in Ibadan, Nigeria: outcome of 1-year follow-up. *Eye*. 2009;23:448-452.
43. Tse KM, Lee HP, Shabana N, Loon SC, Watson PG, Thean SY. Do shapes and dimensions of scleral flap and sclerostomy influence aqueous outflow in trabeculectomy? A finite element simulation approach. *Br J Ophthalmol*. 2012;96:432-437.
44. Dhingra S, Khaw PT. The Moorfields Safer Surgery System. *Middle East Afr J Ophthalmol*. 2009;16:112-115.
45. Thomas R, Jacob P, Braganza A, Mermoud A, Muliylil J. Releasable suture technique for trabeculectomy. *Indian J Ophthalmol*. 1997;45:37-41.
46. Matlach J, Hoffmann N, Freiberg FJ, Grehn F, Klink T. Comparative study of trabeculectomy using single sutures versus releasable sutures. *Clin Ophthalmol*. 2012;6:1019-1027.