

Angle closure glaucoma caused by delayed vitreous prolapse into the posterior chamber after phacoemulsification

Muralidhar Rajamani¹, Chitra Ramamurthy¹

¹Department of Glaucoma, The Eye Foundation, Coimbatore, Tamilnadu, India

Abstract

Vitreous in the anterior chamber is a known cause of raised intraocular pressure following cataract surgery. We present a case of delayed rise in intraocular pressure following cataract surgery in a patient with pseudoexfoliation caused by vitreous prolapse into the posterior chamber. Control of intraocular pressure was achieved by an anterior vitrectomy. Prompt recognition and management of this condition is essential for a good outcome.

Key Messages: It is important to recognize that vitreous can prolapse into the posterior chamber and cause delayed rise in intraocular pressure in patients with a poorly dilating pupil and a posterior capsular rent during cataract surgery

Keywords: Delayed vitreous prolapse, posterior capsular rent, pseudoexfoliation, secondary angle closure with elevated intraocular pressure

Introduction

Causes for raised intraocular pressure after cataract surgery include postoperative inflammation, vitreous in the anterior chamber, retained viscoelastic agent, malignant glaucoma, pigment dispersion, pseudoexfoliation glaucoma, lens particle glaucoma and distortion of the trabecular meshwork.¹ We have also come across a few cases of steroid induced ocular hypertension caused by self-medication of topical steroids in our practice. We present a patient with pseudoexfoliation who presented to us with delayed rise in intraocular pressure after cataract surgery due to vitreous prolapsing into the posterior chamber. We are not aware of any similar reports in literature.

Case history

A 56 year old female presented to us with pain and diminished vision in the left eye for the past 1 week. She denied any history of trauma. She had undergone phacoemulsification with IOL implantation in the left eye a year back. The preoperative records mentioned pseudoexfoliation with poorly dilating pupil in the left eye. Her refractive error recorded prior to surgery was +2.0 D in the right eye and emmetropia in the left eye with a vision of 20/20 OD and 20/40 OS. At the time of surgery, a posterior capsular rent was noted and the intraocular lens (IOL) was placed in the sulcus. No vitreous loss was noted in the surgical records. She had attained a best corrected

Correspondence: Muralidhar Rajamani, Department of Glaucoma, The Eye Foundation, 582A, D.B.Road, R.S.Puram, Coimbatore -641002, Tamilnadu, India
E-mail: rajanimurali@rediffmail.com

visual acuity of 20/20 six weeks after surgery and had not followed up after that. The refractive error recorded then was + 2.0 D in OD and emmetropia in OS.

At presentation she had a vision of 20/20 OD and 20/25 OS. The intraocular pressure was noted to be 22 mmHg OD and 46 mmHg OS on applanation tonometry. The cornea was mildly edematous and the anterior chamber was noted to be slightly shallow with bowing forward of the iris. On gonioscopy, the angles were noted to be closed 360 degrees and did not open on indentation. She was started on topical timolol and brimonidine, oral acetazolamide, and glycerol syrup. She was advised to undergo ultrasound biomicroscopy but was lost to follow up and returned a month later with severe pain in the left eye. On examination she was noted to have a vision of 20/20 OD and **20/120 OS**. The cornea was edematous and the anterior chamber was flat with adhesion of the iris to the cornea. An ultrasound biomicroscopy showed the IOL to be in normal position. There was no anterior rotation of the ciliary processes. The iris was noted to be pushed forward and stuck to the back of the cornea (Fig. 1).

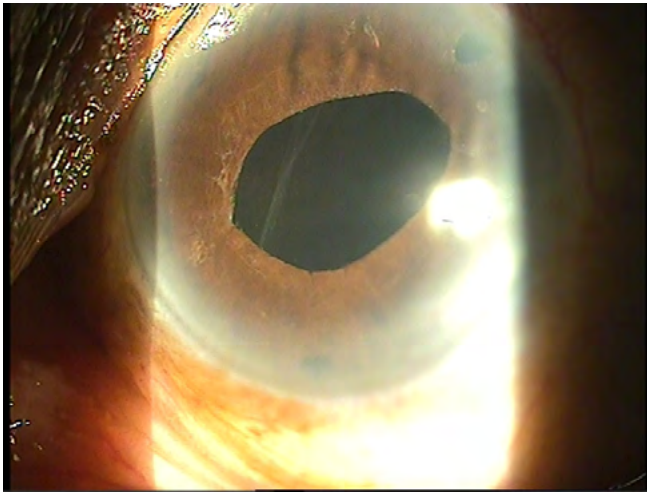


Fig. 1. Ultrabiomicroscopic picture showing the iris stuck to the cornea. The IOL is in normal position. The posterior chamber is inflated.

Vitreous pushing the iris forward was suspected and the patient underwent anterior vitrectomy and peripheral iridectomy under local anaesthesia. A stab incision was made with a 15 degree angled blade and vitreous prolapse was noted. Automated vitrectomy was done in the wound area and the vitrectomy cutter was introduced into the anterior chamber. The vitrectomy cutter was kept in the pupillary area and vitrectomy was also done under the pupillary margin. The iris was noted to fall back with this manoeuvre. A second stab incision was done 4 clock hours apart to introduce the infusion cannula and anterior vitrectomy completed. Corneal clearing was noted on the first postoperative day and 3 weeks later she was noted to have a vision of 20/25 and an intraocular pressure of 15 mmHg OS without any antiglaucoma medication. The anterior chamber was deep and the IOL was well centered. The posterior capsular rent was evident on slit lamp examination (Fig. 2).

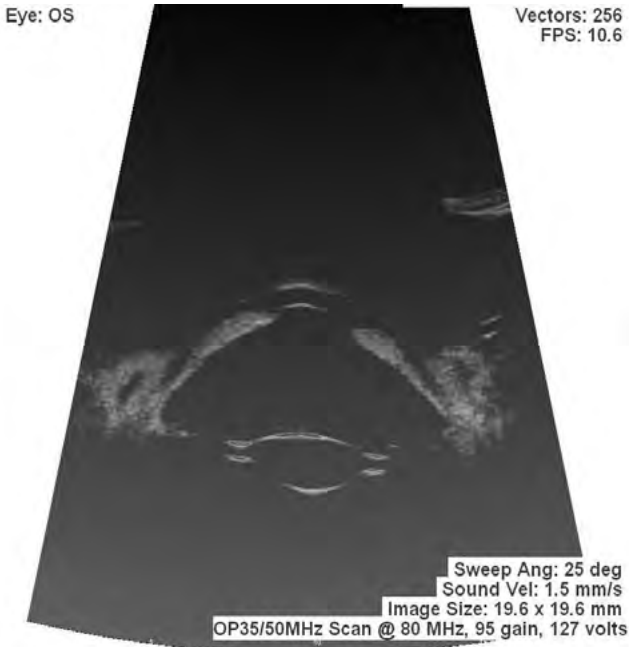


Fig. 2. Postoperative photograph showing posterior capsular rent.

She continues to maintain a stable course until the last follow up of four months. At her last visit, the angles were noted to be open until the scleral spurs in both eyes. A few goniosynechiae were noted in the left eye. The cup-disc ratio was noted to be 0.3:1 in both the eyes. A mild temporal pallor was noted in the left eye, but the visual fields were normal. Her visual acuity was 20/32 OD and 20/20 OS, with a refractive error of + 1.75 D OD and -0.5 x 30 OS.

Discussion

Vitreous filling the anterior chamber is a known etiology for open angle glaucoma in the postoperative period. Similarly, the vitreous also plays a major role in pupillary block glaucoma in aphakia and malignant glaucoma.^{2,3} Vitreous prolapse into the anterior chamber after Nd:YAG capsulotomy has been reported to cause angle closure glaucoma.⁴ Cataract surgery in pseudoexfoliation syndrome may be complicated by an increased incidence of vitreous loss.⁵ But we are not aware of any reports of a delayed migration of vitreous into the posterior chamber pushing the iris forward and leading to a rise in intraocular pressure as in our case.

Possible etiologies for a delayed prolapse of vitreous in the anterior chamber could be liquefaction of vitreous with age, spontaneous rupture of the anterior hyaloid face, or migration through an area of zonular dehiscence, though none was evident on clinical examination. The rigid pupil (as is often seen in patients with pseudoexfoliation) would have prevented the vitreous from migrating into the anterior chamber, causing the iris to bow forward and obstruct the anterior

chamber angle. Diagnosis was based on a high index of clinical suspicion aided by ultrasound biomicroscopy. Ultrasound biomicroscopy findings, such as normal ciliary process position and normal IOL position, were against the possibility of malignant glaucoma. The intraocular pressures were brought under control, though the surgery was delayed by a month. To conclude, it is important to consider delayed migration of the vitreous into the posterior chamber as a cause for delayed rise in intraocular pressure in patients with poorly dilating pupils and posterior capsular rupture/zonular dialysis during cataract surgery. Prompt recognition and treatment of this clinical entity can result in a successful outcome.

References

1. Shields MB. Glaucomas following ocular surgery. In: Shields MB (editor) Textbook of glaucoma. Baltimore: Williams and Wilkins; 1998. p. 345-368.
2. Grant WM. Open-Angle Glaucoma Associated with Vitreous Filling the Anterior Chamber. *Trans Am Ophthalmol Soc.* 1963; 61:196-218.
3. Samples JR, Van Buskirk EM. Open-angle glaucoma associated with vitreous humor filling the anterior chamber. *Am J Ophthalmol.* 1986;102(6):759-761.
4. Li EY1, Wu WK, Jhanji V. Pupillary block glaucoma secondary to vitreous prolapse after Nd:YAG capsulotomy. *Clin Exp Optom.* 2011; 94(4):383-384.
5. Shingleton BJ, Heltzer J, O'Donoghue MW. Outcomes of phacoemulsification in patients with and without pseudoexfoliation syndrome. *J Cataract Refract Surg.* 2003;29(6):1080-1086.