

Ultrasound biomicroscopic comparison of primary open-angle glaucoma and primary angle-closure glaucoma eyes in dark and light conditions

Stephanie M. Young,¹ Maria C.D. Aquino,¹ Noor Shabana,¹ Zheng Ce,¹
Seng Chee Loon,¹ Jovina L.S. See,¹ Yin Teng,¹ Gus Gazzard,²
Paul T.K. Chew¹

¹National University Hospital, Singapore; ²Moorfields Eye Hospital, London, United Kingdom

Abstract

Background: With the use of ultrasound biomicroscopy, we aim to look at differences in anterior segment parameters of eyes with primary open angle glaucoma (POAG) and primary angle closure glaucoma (PACG) in dark and light conditions.

Methods: Ultrasound biomicroscopy was performed for 30 subjects with PACG and 30 subjects with POAG at initial presentation before any treatment. Measurements of angle opening distance (AOD-500 and AOD-750) and trabecular-iris space area (TISA-500 and TISA-750) 500 and 750 μ m from the scleral spur in both dark and light conditions were made. Anterior chamber depth (ACD) and axial length (AL) were also measured.

Results: The mean age of PACG patients was 67.6 ± 9.6 years and POAG patients 62.1 ± 13.9 years. The mean ACD (2.70 ± 0.53 mm) in PACG patients was significantly different from that (3.32 ± 0.52 mm) of POAG patients ($p < 0.0001$). There were also significant differences ($p = 0.0004$) in the mean AL of PACG (22.91 ± 0.86 mm) and POAG (24.47 ± 1.67 mm) patients. Significant differences between POAG and PACG eyes were found for TISA-500, TISA-750, AOD-500 and AOD-750 in both light and dark conditions ($p < 0.001$ for all). The light-dark differences in PACG eyes were smaller than that of POAG eyes for all AOD and TISA values in the inferior, superior, nasal and temporal quadrants. However, with the exception of AOD-750 in the inferior quadrant ($p = 0.0524$), there were no significant differences in light-dark changes between POAG and PACG eyes for all parameters in the 4 quadrants.

Conclusions: Ultrasound biomicroscopy is a useful tool in the diagnosis and management of glaucoma. We found significant differences in mean AL, ACD, TISA-500, TISA-750, AOD-500 and AOD-750 between PACG and POAG eyes. However, there were no significant differences between PACG and POAG eyes in terms of light-dark difference in anterior segment parameters, except for AOD-750 in the inferior quadrant. Further evaluation of the above findings could be done in future with a larger population

Key words: Imaging, Ultrasound biomicroscopy, PACG, POAG

Introduction

Ultrasound biomicroscopy (UBM) is a useful tool in the diagnosis and management of glaucoma, and has revolutionized the evaluation of the anterior segment of the

Correspondence: Dr. Stephanie Ming, National University Hospital, Singapore.
E-mail: stephanieyoung83@gmail.com

eye.¹ It has the capacity to produce high-quality images of anterior segment parameters, and readily images the ciliary body and other structures behind the iris, thus contributing greatly to our understanding of glaucoma and other anterior segment disorders.

The reproducibility of anterior chamber angle measurements of UBM has been shown to be comparable with anterior segment optical coherence tomography (ASOCT).² There have been numerous articles describing and comparing these anterior segment imaging tools.³⁻⁵ The analysis of angle closure eyes with ASOCT and UBM has also been described, showing them to be highly sensitive in detecting angle closure when compared with gonioscopy.⁶⁻⁹ However, there have not been any studies comparing anterior segment parameters of primary open-angle glaucoma (POAG) and primary angle-closure glaucoma (PACG) patients at initial presentation with UBM.

Our study aims to look at differences in anterior segment parameters of eyes with POAG and PACG in both dark and light conditions.

Methods

This was a prospective comparative study of new patients with POAG or PACG, who presented to the National University Health System, a tertiary eye care center in Singapore, from January 2002 to June 2009. These were newly-diagnosed patients, with no previous treatment or laser therapy done. The patients, who presented with unrelated eye conditions, were found to have clinical signs suggestive of glaucoma. They were referred from general ophthalmology clinics and community screening programs for diabetes mellitus and glaucoma, as they were found to have suspicious discs or raised intraocular pressure (IOP).

Ethics approval was obtained from the ethical review board of the National University Hospital Singapore, and written informed consent was obtained from all subjects. The work was carried out in accordance with the World Medical Association's Declaration of Helsinki.

Thirty consecutive patients with PACG, and 30 consecutive subjects with POAG were recruited. PACG was defined as visual field defect, glaucomatous optic neuropathy and at least one recorded IOP > 21 mmHg (among three readings taken) in the presence of an occludable angle and peripheral anterior synechiae (PAS). An occludable angle was defined as one in which the posterior, usually

pigmented, trabecular meshwork was not seen over 270 degrees or more of the angle without indentation.^{10,11} Patients were asymptomatic at the time of presentation with no symptoms of acute attacks such as headache, nausea, vomiting and eye pain. Visual field defect consisted of either two points reduced by > 5 dB or one point reduced by > 10 dB below the age-specific threshold.¹⁰⁻¹² Secondary causes for angle closure, including iris neovascularization, lens intumescence, posterior segment mass, prior penetrating trauma and previous cataract or other ocular surgery, were excluded. Patients with serious medical conditions were also excluded from the study. POAG was defined as visual field defect, glaucomatous optic neuropathy and at least one recorded IOP > 21 mmHg (among the three

readings taken) in the presence of an open angle.

All subjects recruited underwent UBM imaging of the eye(s) with either the Humphrey P40 or the Sonomed UBM. After instilling 2% tetracaine drops in the eye, a plastic eyecup was placed on the sclera and sterile normal saline placed in the eye cup to form a water bath, taking care not to exert pressure on the globe. The UBM probe was placed in the saline reservoir perpendicular to the ocular surface and scanning was performed in the supine position. The contralateral eye was fixated on a distant target on the ceiling to maintain accommodation. The gain was set between 60 and 80 dB to maximize the view of the imaged structures and minimize noise. Images of the central anterior chamber, as well as the superior, inferior, nasal and temporal angle quadrants were captured. Imaging of all quadrants was performed in both light and dark conditions (Figs. 1 and 2).

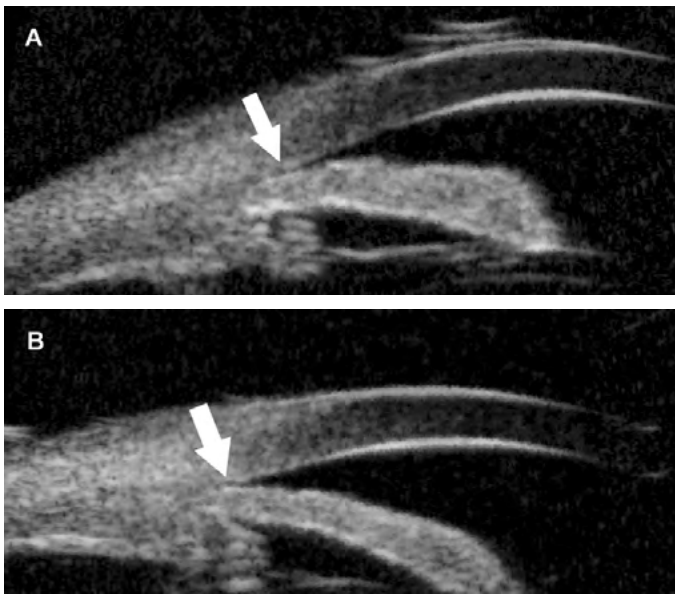


Fig. 1. Ultrasound biomicroscopic images of the superior angle of a patient with PACG in dark(A) and light(B) conditions. Angle posterior to scleral spur (white arrow) shows iridocorneal contact in dark (A); Angle posterior to the scleral spur (white arrow) shows slight opening in light but the angle recess is still closed (B).

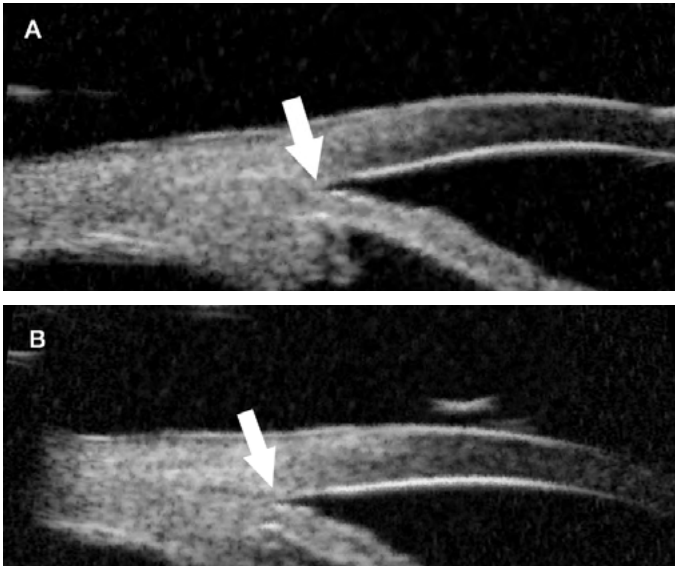


Fig. 2. Ultrasound biomicroscopic images of the inferior angle of a patient with POAG in dark(A) and light(B) conditions. Angles posterior to scleral spur (white arrow) are open.

A customized software (Anterior Segment Analysis Program, ASAP, National University Health System, Singapore) was used in this study. This was coded as a plug-in software under ImageJ (version 1.38x), which is a public domain Java program (available at <http://rsb.info.nih.gov/ij>; National Institutes of Health, Bethesda, MD). ASAP automatically calculated anterior segment parameters using the scleral spur as reference point by a single observer.

Measurements made included anterior chamber depth (ACD), axial length (AL), and angle opening distance (AOD-500 and AOD-750), defined as linear distance between trabecular meshwork and iris at 500 μ m and 750 μ m anterior to the scleral spur (Fig. 3). In addition, trabecular-iris space area (TISA-500 and TISA-750) was measured, defined as a trapezoidal area with the following boundaries: anteriorly as the AOD 500 or AOD 750; posteriorly as a line drawn from the scleral spur perpendicular to the plane of the inner scleral wall to the opposing iris; superiorly as the inner corneoscleral wall; inferiorly as the iris surface.

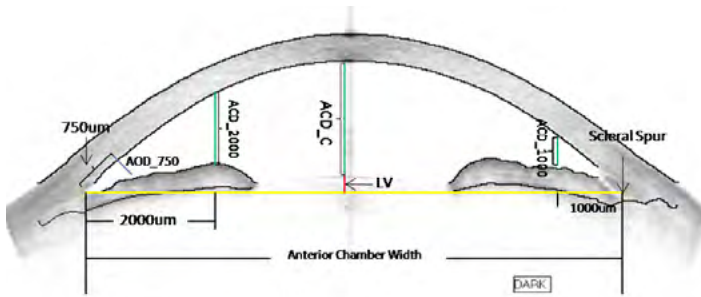


Fig. 3. Diagrammatic representation of anterior segment cross section.

Results

The mean age of PACG patients was 67.6 ± 9.6 years and POAG patients 62.1 ± 13.9 years. The proportion of male and females among PACG patients was 40.0% and 60.0%, and among POAG patients 68.8% and 31.2%, respectively. Among our patients, 8.2% had a family history of glaucoma. The IOP at presentation (mmHg) was 24.50 ± 3.30 for POAG eyes and 26.90 ± 6.90 for PACG eyes. Best-corrected visual acuity (logMAR) for POAG and PACG eyes were 0.15 ± 0.19 and 0.17 ± 0.16 respectively. Corneal thickness (mm) was 0.45 ± 0.23 and 0.57 ± 0.40 for POAG and PACG eyes correspondingly. The mean ACD (2.70 ± 0.53 mm) in PACG patients was significantly different from that (3.32 ± 0.52 mm) of POAG patients ($p < 0.0001$). There were also significant differences ($p = 0.0004$) in the mean AL of PACG (22.91 ± 0.86 mm) and POAG (24.47 ± 1.67 mm) patients.

Table 1 shows the difference in anterior segment parameters of POAG and PACG in dark condition, while Table 2 shows that in light condition. Significant differences between POAG and PACG eyes were found for TISA-500, TISA-750, AOD-500 and AOD-750 in both light and dark conditions ($p < 0.001$ for all).

Table 1. Difference in anterior segment parameters of POAG and PACG in dark condition.

	PACG	POAG	Mean difference (C.I)	p
TISA-500 ($10^{-3}\mu\text{m}$)	3.0 (9.01)	41.8 (38.10)	-38.87 (-45.94, -31.79)	< 0.001
TISA-750 ($10^{-3}\mu\text{m}$)	16.7 (87.10)	94.9 (72.75)	-78.15 (-98.72, -57.58)	< 0.001
AOD-500 ($10^{-3}\mu\text{m}$)	24.9 (62.65)	205.4 (137.10)	-180.56 (-207.79, -153.33)	< 0.001
AOD-750 ($10^{-3}\mu\text{m}$)	71.3 (206.41)	368.8 (204.90)	-297.42 (-350.06, -244.78)	< 0.001

Table 2. Difference in anterior segment parameters of POAG and PACG in light condition.

	PACG	POAG	Mean difference (C.I)	p
TISA-500 (10⁻³µm)	4.2 (12,27)	44.8 (41.26)	-40.60 (-48.44, -32.77)	< 0.001
TISA-750 (10⁻³µm)	19.9 (89.13)	104.6 (80.57)	-84.73 (-106.53, -62.94)	< 0.001
AOD-500 (10⁻³µm)	28.4 (67.36)	210.0 (139.69)	-181.59 (-209.77, -153.41)	< 0.001
AOD-750 (10⁻³µm)	71.0 (139.82)	404.4 (204.88)	-333.41 (-378.43, -288.39)	< 0.001

The univariate analyses for anterior segment parameters in dark and light conditions are shown in Tables 3 and 4, respectively. The β coefficient of age was negative and significant ($p < 0.05$) for all parameters, indicating that increasing age was associated with decreasing TISA-500, TISA-750, AOD-500 and AOD-750 values. The β coefficient of AL and ACD were positive and significant for all parameters, implying that increasing AL and ACD led to increasing TISA-500, TISA-750, AOD-500 and AOD-750 values. Similarly, the last column of diagnosis revealed that patients with POAG had larger TISA-500, TISA-750, AOD-500 and AOD-750 compared with PACG patients. In contrast, the p-values of gender showed that gender did not have a significant influence on TISA-500, TISA-750, AOD-500 and AOD-750.

Table 5 shows the light minus dark difference for anterior segment parameters in POAG and PACG eyes. The light-dark differences in PACG eyes were smaller than that of POAG eyes for all AOD and TISA values in the inferior, superior, nasal and temporal quadrants. However, with the exception of AOD-750 in the inferior quadrant ($p = 0.0524$), there were no significant differences in light-dark changes between POAG and PACG eyes for all parameters in the four quadrants.

Table 3. Univariate analysis for anterior segment parameters in dark condition.

	Univariate Linear regression analysis β coefficient (p-value)*									
	Age		Gender		AL		ACD		Diagnosis	
	β	p-value	β	p-value	β	p-value	β	p-value	β	p-value
TISA-500	-0.001	0.031	0.009	0.231	0.007	0.011	0.022	< 0.001	0.038	< 0.001
TISA-750	-0.002	0.029	0.011	0.530	0.016	0.014	0.045	< 0.001	0.076	< 0.001
AOD-500	-0.003	0.015	0.059	0.048	0.023	0.047	0.076	< 0.001	0.168	< 0.001
AOD-750	-0.006	< 0.001	0.042	0.424	0.048	0.017	0.131	< 0.001	0.282	< 0.001

Table 4. Univariate analysis for anterior segment parameters in light condition.

	Univariate Linear regression analysis β coefficient (p-value)*									
	Age		Gender		AL		ACD		Diagnosis	
	β	p-value	β	p-value	β	p-value	β	p-value	β	p-value
TISA-500	0.000	0.274	0.010	0.230	0.008	0.013	0.023	< 0.001	0.040	< 0.001
TISA-750	-0.001	0.169	0.029	0.125	0.020	0.004	0.045	0.013	0.079	< 0.001
AOD-500	-0.002	0.163	0.046	0.134	0.025	0.041	0.072	0.011	0.177	< 0.001
AOD-750	-0.004	0.081	0.088	0.109	0.053	0.012	0.147	0.003	0.319	< 0.001

Table 5. Light minus dark difference for anterior segment parameters in PACG and POAG eyes.

		Light minus dark difference for PACG	Light minus dark difference for POAG	p
		Mean ± sd	Mean ± sd	
Inferior (µm)	TISA500	0.0003468 ± 0.005891	0.005264 ± 0.03829	0.514
	AOD500	0.002738 ± 0.05647	0.05234 ± 0.1922	0.1949
	TISA750	0.00001724 ± 0.01280	0.01194 ± 0.08463	0.4708
	AOD750	0.001566 ± 0.09141	0.1008 ± 0.2488	0.0524
Superior (µm)	TISA500	-0.0004967 ± 0.0124	0.005264 ± 0.03829	0.6928
	AOD500	-0.01060 ± 0.04441	0.02037 ± 0.1530	0.2914
	TISA750	0.0008567 ± 0.2424	0.01860 ± 0.06145	0.7122
	AOD750	-0.03687 ± 0.3998	0.04158 ± 0.2033	0.3668
Nasal (µm)	TISA500	-0.001036 ± 0.005803	-0.002475 ± 0.03350	0.8193
	AOD500	0.003453 ± 0.02903	-0.02670 ± 0.1519	0.2959
	TISA750	-0.0007300 ± 0.01319	-0.003983 ± 0.06541	0.7916
	AOD750	-0.002480 ± 0.1207	0.01481 ± 0.2553	0.7312
Temporal (µm)	TISA500	0.005980 ± 0.01677	0.006687 ± 0.04489	0.9274
	AOD500	0.01935 ± 0.09473	-0.02573 ± 0.1546	0.1216
	TISA750	0.01276 ± 0.03275	0.01242 ± 0.09082	0.9834
	AOD750	0.03873 ± 0.1607	-0.01445 ± 0.2528	0.3103

Discussion

Assessment of the anterior segment plays a major role in the diagnosis and treatment of glaucoma. Traditional tools for the assessment of the angle and anterior segment are the slit-lamp and gonioscopy.¹³ Several newer technologies now exist for imaging of the anterior segment, including scanning Scheimpflug and scanning slit-lamp systems.^{5,14} While these visible light systems are undoubtedly useful, especially for screening for narrow angles, OCT and UBM systems allow imaging of the full-angle anatomy and, in the case of UBM, visualization of retro-iridal structures and the ciliary body. Thus, these technologies provide optimal means for the assessment of the anterior segment in glaucoma.³

There are some advantages of OCT, especially in the case of spectral-domain systems, owing to its superb resolution, high speed and non-invasive character.² Compared to OCT, UBM has several limitations. A coupling medium is required

such that scanning must be performed through an immersion bath. As it requires contact with the globe, it may be unpleasant for the patient, induce artifacts, and cause a risk of infection or corneal abrasion.¹⁵ The procedure also requires trained and experienced technicians and is time consuming.

Despite the above, UBM is advantageous in that it provides better penetration through opaque or cloudy media than OCT, allowing improved depiction of the ciliary body, retro-iridal structures and the anterior chamber in the presence of corneal edema, scars or hyphema.^{7,8} In a study by Radhakrishnan *et al.*, OCT and UBM provided similar mean values for various anterior segment parameters, with equal reproducibility between the two.² UBM showed excellent discriminative value for the detection of narrow angles that was comparable to OCT.²

There have been reports on the use of UBM and OCT to characterize PACG eyes alone or comparing them to normal subjects.⁶⁻⁹ However, to our knowledge there has been no previous study comparing the anterior segment parameters of POAG and PACG eyes with UBM. Over the last decade there has been much research investigating the early diagnosis and treatment of PACG in Asian populations, including the use of potential screening tests.¹⁶⁻¹⁸ Both POAG and PACG have important clinical significance in many populations, and our study complements the information available by looking at the differences between POAG and PACG eyes with UBM, a useful and reliable anterior segment assessment tool. In addition, there has yet been any study on differences between POAG and normal eyes. This study could spearhead future studies looking at UBM differences between POAG and normal eyes, which would allow better understanding of the significance of the UBM data.

In our study, as expected, POAG and PACG eyes had significant differences in both dark and light conditions for all parameters: TISA-500, TISA-750, AOD-500, AOD-750, each representing the mean of a four quadrants measured. This was true for both dark and light conditions. While this is not an unexpected finding, it confirms our knowledge that the anatomical structures for patients with the two different types of glaucoma are significantly different. If we get more UBM data for both POAG and PACG eyes, the range of data available could serve as a guide for each condition, and could be used in future for either for screening or diagnostic purposes.

Our univariate analyses for anterior segment parameters in dark and light conditions showed age having an inverse association with TISA-500, TISA-750, AOD-500 and AOD-750. This correlates with previous studies which showed older patients to have significantly lower values of various quantitative parameters.¹⁹⁻²² It has been postulated that increments in lens thickness and a forward shift of the lens position induced by zonular weakness may cause these changes during aging.²⁰ These findings suggest that old age may be a significant risk factor for PACG, because narrow anterior chamber angle parameters are associated with angle closure.

As expected, univariate analysis showed AL and ACD to have a positive correlation with TISA-500, TISA-750, AOD-500 and AOD-750 values. This was not unexpected, as a similar association was found in another study.²³ However, the univariate analysis for gender showed it did not have a significant influence on all parameters.

This was similar to findings in other studies,^{19,22,24} although literature has reported that female subjects display a smaller ACD than male subjects in almost all age groups, but these differences were minor and not statistically significant.²¹

Unsurprisingly, TISA-500, TISA-750, AOD-500 and AOD-750 were smaller in PACG than POAG patients. According to the classic view, the anterior chamber in patients with PACG is shallow, due to a combination of several factors, namely, a smaller cornea,²⁵ a shorter eye,²⁵⁻²⁷ and, above all, a thicker lens,^{27,28} located more anteriorly than normal.^{29,30} This gives rise to 'crowding' of the anterior segment in PACG patients and results in the decreased anterior chamber angle parameters in PACG, as confirmed in our study.

Finally, our study looked at light-dark differences in PACG and POAG eyes and compared these differences. Other studies have investigated the differences in anterior chamber angle measurements in light and dark conditions with UBM and ASOCT, and found these parameters to be significantly greater in the dark compared to light.³¹⁻³³ In addition to these known findings, we were interested in examining if there were any significant differences in light-dark changes between POAG and PACG eyes, which has not been investigated previously with UBM. We found that light-dark differences in PACG eyes were smaller than that of POAG eyes for all AOD and TISA values in the inferior, superior, nasal and temporal quadrants. However, with the exception of AOD-750 in the inferior quadrant ($p = 0.0524$), there were no significant difference in these light-dark differences for all parameters in the four quadrants between POAG and PACG eyes. Based on these findings, more research on a larger population would be useful for future detection and characterization of the different types of glaucomas.

Conclusion

Our study showed significant differences in mean AL and ACD between PACG and POAG eyes. TISA-500, TISA-750, AOD-500 and AOD-750 were significantly different for POAG and PACG eyes in both light and dark conditions. Light-dark difference in PACG eyes was smaller than that of POAG eyes for all AOD and TISA values in all four quadrants. However, except for AOD-750 in inferior quadrant, there was no significant difference between PACG and POAG eyes in terms of light-dark difference in anterior segment parameters. Further evaluation of the above findings could be done in future with a larger population, for better characterization of differences in anterior segment parameters in POAG and PACG eyes.


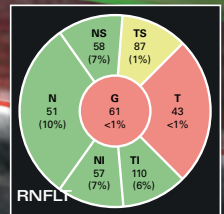
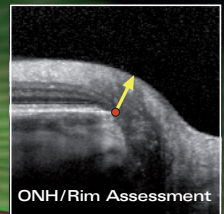
References

1. Ishikawa H, Liebmann JM, Ritch R. Quantitative assessment of the anterior segment using ultrasound biomicroscopy. *Curr Opin Ophthalmol* 2000;11:133-139.
2. Radhakrishnan S, Goldsmith J, Westphal V, et al. Comparison of coherence tomography and ultrasound biomicroscopy for detection of narrow anterior chamber angles. *Arch Ophthalmol* 2005;123:1053-1059.
3. Ursea R, Silverman RH. Anterior segment imaging for assessment of glaucoma. *Expert Rev Ophthalmol* 2010;5:59-74.

4. Kashiwagi K, Kashiwagi F, Toda Y, Osada K, Tsumura T, Tsukahara S. A newly developed peripheral anterior chamber depth analysis system: principle, accuracy, and reproducibility. *Br J Ophthalmol* 2004;88:1030-1035.
5. Friedman DS, He M. Anterior chamber angle assessment techniques. *Surv Ophthalmol* 2008;53:250-273.
6. Nolan WP, See JL, Chew PTK, Friedman DS, Smith SD, Radhakrishnan S, Zheng C, Foster PJ, Aung T. Detection of Primary Angle Closure Using Anterior Segment Optical Coherence Tomography in Asian Eyes. *Ophthalmology* 2007;114:33-39.
7. Marchini G, Pagliaruso A, Toscano A, Tosi R, Brunelli C, Bonomi L. Ultrasound biomicroscopic and conventional ultrasonographic study of ocular dimensions in primary angle-closure glaucoma. *Ophthalmology* 1998;105:2091-2098.
8. Sakuma T, Sawada A, Yamamoto T, Kitazawa Y. Appositional angle closure in eyes with narrow angles: an ultrasound biomicroscopic study. *J Glaucoma* 1997;6:165-169.
9. Marchini G, Pagliaruso A, Toscano A, et al. Ultrasound biomicroscopic and conventional ultrasonographic study of ocular dimensions in primary angle-closure glaucoma. *Ophthalmology* 1998;105:2091-2098.
10. Foster PJ, Buhmann R, Quigley HA, et al. The definition and classification of glaucoma in prevalence surveys. *Br J Ophthalmol* 2002;86:238-242.
11. Foster PJ, Aung T, Nolan WP, et al. Defining 'occludable' angles in population surveys: drainage angle width, peripheral anterior synechiae, and glaucomatous optic neuropathy in east Asian people. *Br J Ophthalmol* 2004;88:486-490.
12. Saw SM, Gazzard G, Au Eong KG, Oen F, Seah S. Utility values in Singapore Chinese adults with primary open-angle and primary angle-closure glaucoma. *J Glaucoma* 2005;14:455-462.
13. Shaffer RN. A new classification of the glaucomas. *Trans Am Ophthalmol Soc* 1960;58:219-225.
14. Rabsilber TM, Khoramnia R, Auffarth GU. Anterior chamber measurements using Pentacam rotating Scheimpflug camera. *J Cat Refr Surg* 2006;32:456-459.
15. Ishikawa H, Inazumi K, Liebmann JM, Ritch R. Inadvertent corneal indentation can cause artifactual widening of the iridocorneal angle on ultrasound biomicroscopy. *Ophthalmic Surg Lasers* 2000;31:342-345.
16. Congdon N, Wang F, Tielsch JM. Issues in the epidemiology and population-based screening of primary angle-closure glaucoma. *Surv Ophthalmol* 1992;36:411-423.
17. Devereux JG, Foster PJ, Baasanh J, et al. Anterior chamber depth measurement as a screening tool for primary angle-closure glaucoma in an East Asian population. *Arch Ophthalmol* 2000;118:257-263.
18. Foster PJ, Devereux JG, Alsbirk PH, et al. Detection of gonioscopically occludable angles and primary angle closure glaucoma by estimation of limbal chamber depth in Asians: modified grading scheme. *Br J Ophthalmol* 2000;84:186-192.
19. He M, Huang W, Zheng Y, Alsbirk PH, Foster PJ. Anterior chamber depth in elderly Chinese: the Liwan eye study. *Ophthalmology* 1998;115:1286-1290.
20. Cheon MH, Sung KR, Choi EH, et al. Effect of age on anterior chamber angle configuration in Asians determined by anterior segment optical coherence tomography; clinic-based study. *Acta Ophthalmol* 2010;88:e205-e210.
21. Rufer F, Schroder A, Klettner A, et al. Anterior chamber depth and iridocorneal angle in healthy White subjects: effects of age, gender and refraction. *Acta Ophthalmol* 2010;88:885-890.
22. Xu L, Cao WF, Wang YX, Chen CX, Jonas JB. Anterior chamber depth and chamber angle and their associations with ocular and general parameters: the Beijing Eye Study. *Am J Ophthalmol* 2008;145:929-936.
23. Dorairaj S, Liebmann JM, Ritch R. Quantitative evaluation of anterior segment parameters in the era of imaging. *Trans Am Ophthalmol Soc* 2007;105:99-110.
24. Shufelt C, Fraser-Bell S, Ying-Lai M, Torres M, Varma R; the Los Angeles Latino Eye Study Group. Refractive error, ocular biometry, and lens opalescence in an adult population: the Los Angeles Latino Eye Study. *Invest Ophthalmol Vis Sci* 2005;46:4450-4460.
25. Tomlinson A, Leighton DA. Ocular dimensions in the heredity of angle-closure glaucoma. *Br J Ophthalmol* 1973;57:475-486.

26. Lowe RF. Primary angle-closure glaucoma: a review of ocular biometry. Aust J Ophthalmol 1977;5:9-14.
27. Alsbirk PH. Primary angle-closure glaucoma. Oculometry, epidemiology and genetics in a high risk population. Acta Ophthalmol Suppl 1976;127:5-31.
28. Markowitz SN, Morin JD. Angle-closure glaucoma: relation between lens thickness, anterior chamber depth and age. Can J Ophthalmol 1984;19:300-302.
29. Saxena S, Agrawal PK, Pratap VB, et al. The predictive value of the relative lens position in primary angle-closure glaucoma. Ann Ophthalmol 1993;25:453-456.
30. Salmon JF, Swanevelter SA, Donald MA. The dimensions of eyes with chronic angle-closure glaucoma. J Glaucoma 1994;3:237-243.
31. Woo EK, Pavlin CJ, Slomovic A, et al. Ultrasound biomicroscopic quantitative analysis of light-dark changes associated with pupillary block. Am J Ophthalmol 1999;127:43-47.
32. Leung CK, Cheung CYL, Li H, et al. Dynamic Analysis of Dark-Light Changes of the Anterior Chamber Angle with Anterior Segment OCT. IOVS 2007;48:4116-4122.
33. Ishikawa H, Esaki K, Liebmann JM, et al. Ultrasound biomicroscopy dark room provocative testing: a quantitative method for estimating anterior chamber angle width. Jpn J Ophthalmol 1999;43:526-534.

The Comprehensive Glaucoma Solution with SPECTRALIS



SPECTRALIS

Glaucoma Module Premium Edition

The new comprehensive **Glaucoma Module Premium Edition** for SPECTRALIS OCT offers a precise optic nerve head (ONH) analysis of the minimum rim width, highly reproducible retinal nerve fiber layer thickness (RNFLT) measurements as well as an innovative Posterior Pole Asymmetry Analysis.

The Anatomic Positioning System (APS) aligns all OCT scans to the individual anatomy of the patient.

The module is available for all SPECTRALIS models.

