

Bilateral lightning induced electric cataract and optic neuropathy

David Mathew¹, Saurabh Kumar Sarma¹, Jennifer Basaiawmoit¹

¹Bansara Eye Care Centre, Laitumkhrah, Shillong, India

Abstract

We report the case of a 17-year-old male with decreased vision in both eyes for one month. He had sustained a lightning-related injury two months back while he was operating a charging mobile phone. On examination, he had bilateral cataract and secondary optic atrophy. He underwent cataract surgery in both eyes with good immediate visual outcome. Later, he required laser posterior capsulotomy for significant posterior capsular opacification in both eyes. Electric cataracts can progress quickly and may be prone to developing PCO postoperatively. The surgeon should keep in mind the possibility of posterior segment changes and their implications on the final visual outcome while managing such cataracts.

Keywords: electric cataracts, lightning injury, Nd:YAG capsulotomy, posterior capsular opacification

Introduction

Electric cataracts are rare and lightning-related cataracts and optic neuropathy are rarer still. Visual prognosis in such cataracts depends on the extent of posterior segment involvement, if any. Not infrequently, a total cataract can preclude visualization of the fundus thus affecting prognostication. Postoperatively, there may be a higher incidence of posterior capsular opacification (PCO). We present a case of bilateral electric cataract exploring its progression over time. Management included cataract surgery and post-operative Neodymium: Yttrium Aluminium Garnet (Nd:YAG) laser posterior capsulotomy.

Case description

A 17-year-old male student presented with decreased vision in both eyes for one month. He had sustained a lightning-related injury two months back while he was operating a charging mobile phone. The mobile phone was in his left hand at the time of the incident. He subsequently fell backwards on the floor with minimal scalp injury. He received treatment from a local hospital for the scalp injury and hand burns.

On examination, best corrected visual acuity was 6/12 N6 in the right eye and 6/24 N36 in the left eye. Pupils were reacting well to light but the pupillary reaction was less brisk on the right. There was no relative afferent pupillary defect. He had a faint anterior subcapsular (Fig. 1A) and thick posterior subcapsular cataract

Correspondence: David J Mathew, Bansara Eye Care Centre, Lady Veronica Lane, Laitumkhrah, Shillong 793003, India
E-mail: davidmathew123@gmail.com

(Fig. 1B), which was more in the left eye. Fundus revealed optic disc pallor with irregular margins and arteriolar attenuation with sheathing at the peripapillary region suggestive of secondary optic atrophy. The fundus changes were more marked in the right eye (Fig. 2).

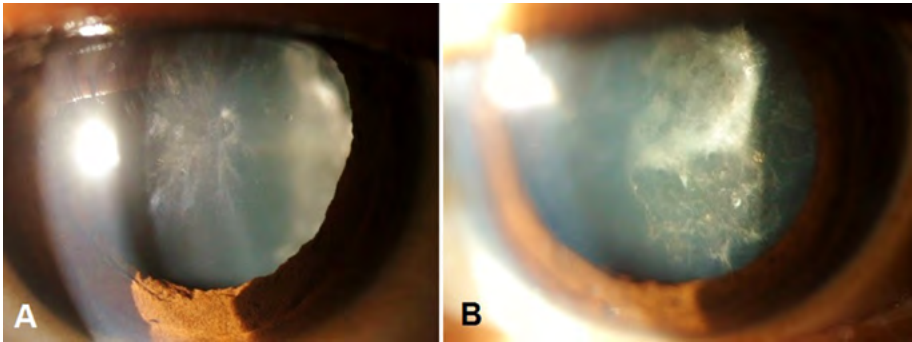


Fig. 1. (A) Slit lamp beam focused on the anterior capsule showing a faint anterior subcapsular cataract in the right eye. (B) Thick, roughly stellate posterior subcapsular cataract in the left eye.

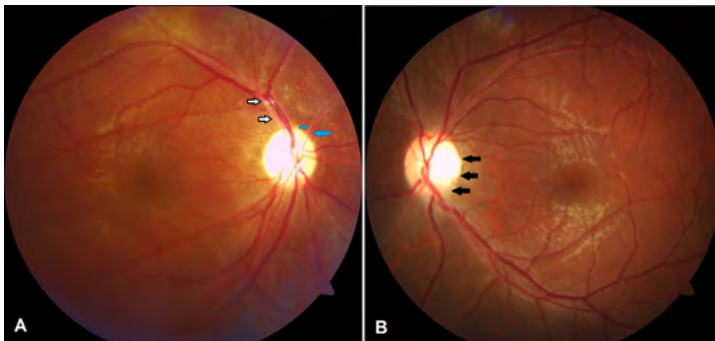


Fig. 2. (A and B) Optic disc pallor with slightly irregular margins (black arrows) and arteriolar attenuation (white arrows) with sheathing at the peripapillary region (blue arrows) suggestive of secondary optic atrophy. The fundus changes were more marked in the right eye.

Color vision was assessed using the Ishihara pseudo-isochromatic plates. The patient could identify all the plates but took longer than normal. Identification of the plates using the right eye was slower than the left. Visual fields were highly unreliable. He underwent cataract surgery in the left eye. He A continuous curvilinear capsulorrhexis was done with difficulty as the anterior capsule was very elastic. Lens matter aspiration was then carried out. A thick plaque was present at the posterior subcapsular region which had to be mechanically lifted and peeled gently off the posterior capsule. A foldable hydrophobic intraocular lens was implanted in the capsular bag. Unaided visual acuity improved to 6/9 and near vision to N6 with correction in the left eye. He was subsequently lost to follow-up till five months later when he presented with a vision of counting fingers close

to the face in the right eye. Left eye vision was stable at 6/9. The cataract in the right eye had increased with a dense posterior subcapsular cataract with no view to the fundus. There was minimal posterior capsular opacification in the left eye. He underwent cataract surgery in the right eye with foldable intraocular lens implantation. Post-operatively, best corrected visual acuity was 6/12 N6 in the right eye. The patient required Nd:YAG laser capsulotomy in both eyes three months later to clear significant PCO. The energy settings used were 1.0 to 1.8 mJ. The number of laser applications was 15 and ten in the right and left eye respectively.

The postoperative target was emmetropia for distance in both eyes after a discussion with the patient. He was amenable to using glasses after surgery for reading. However, the postoperative refraction turned out to be +1.50 DS in the right eye and -0.50 D at 100 degrees in the left eye. The best corrected visual acuity stabilized at 6/12 N6 in the right eye and 6/9 N6 in the left eye.

Discussion

Lightning-related injuries are more common in the developing countries. Use of mobile phones per se during a lightning storm is deemed safe if the user is not outdoors. However, the use of a charging mobile phone during a lightning storm carries the same risk as using a corded phone. Lightning shocks can be considered as high-current electric shocks. When lightning hits a building, it can take more than one path to reach the ground. As it branches, it prefers the electrical lines and the pipes of the building. It can even pass through air between two of its paths (side flash). Talking on a corded phone or a charging phone can put a person at high risk of electric injury as he or she is in the path of the current. As the electric current passes through the body, the amount of damage inflicted depends mainly on the duration of exposure, intensity of the electric current and the resistance offered by the tissue. Nerves, blood, mucous membranes and muscles offer the least resistance, dry skin offers intermediate resistance and tendon, fat and bone offer the maximum resistance. The thermal damage caused by electric current is directly proportional to the resistance offered.¹

The onset of decreased vision due to cataract is often a month after the injury. Presentations as late as two years after the injury have also been reported.² Lightning related cataracts are usually asymmetric at presentation. Apart from cataract, other ocular damage can include corneal injury, chorioretinal atrophy, optic neuritis, optic atrophy, choroidal rupture, macular cyst, macular hole and retinal detachment to name some.¹ Patients are expected to regain good vision after cataract surgery provided there is no other ocular involvement. Hence, a thorough ocular evaluation is mandatory before commenting on the visual outcome.

The pathogenesis of cataract following electric injury has been attributed to decreased permeability of the capsule, coagulation of lens proteins, concussion due to excessive contraction of ciliary muscle and scar tissue formation with hyaloid deposition in the anterior capsule leading to disturbed lens nutrition.³ These cataracts generally progress to maturity quickly. Rarely, they can remain stable for up to two years.⁴ It is not surprising that many cases present as total cataracts, thus

preventing the care giver from examining the fundus. In such cases, it is prudent to perform a B-scan pre-operatively to rule out retinal detachment and do the cataract surgery under guarded visual prognosis.

Optic neuropathy may be secondary to coagulative necrosis, injury to its vascular supply, damage to myelin sheath and progressive edema leading to compartment syndrome.¹ In our case, secondary optic atrophy could have resulted from optic disc edema which is known to occur in electric ocular injury.⁵

There is no current literature to the best of our knowledge which explores the development of PCO following surgery for electric cataract. However, the role of electric fields in the migration and proliferation of lens epithelial cells has been well-documented.⁶ Younger age of the patient in this case may also have contributed to the development of PCO.

In summary, we report a case of bilateral electric cataract and secondary optic atrophy with a satisfactory visual outcome after cataract surgery and Nd:YAG laser posterior capsulotomy. Electric cataracts can progress quickly and may be prone to developing PCO postoperatively. The surgeon should keep in mind the possibility of posterior segment changes and their implications on the final visual outcome while managing such cataracts.

References

1. Price T, Cooper MA. Electrical and Lightning Injuries. In: Rosen's Emergency Medicine, Concepts and Clinical Practices, 6th ed. Philadelphia: Elsevier Saunders 2006.
2. Hanna C, Fraunfelder FT. Electric cataracts. II. Ultrastructural lens changes. *Arch Ophthalmol* 1972;87(2):184-191.
3. Hashemi H, Jabbarvand M, Mohammadpour M. Bilateral electric cataracts: Clinicopathologic report. *J Cataract Refract Surg* 2008;34:1409-1412. doi:10.1016/j.jcrs.2008.03.044.
4. Duke-Elder S, MacFaul PA. Injuries; Non-Mechanical Injuries. In: Duke-Elder (Ed.), *System of Ophthalmology*, Vol XIV, Part 2, pp. 813-835. London: Henry Kimpton and the C.V. Mosby Co. 1972.
5. Izzy S, Deeb W, Peters GB, Mitchell A. Isolated optic nerve oedema as unusual presentation of electric injury. *BMJ Case Rep* 2014;2014. doi:10.1136/bcr-2014-205016.
6. Zhao M, Chalmers L, Cao L, Viera AC, Mannis M, Reid B. Electrical signaling in control of ocular cell behaviors. *Prog Retin Eye Res* 2012;31:65-88. doi:10.1016/j.preteyeres.2011.10.001.