

# Combined Möbius syndrome and tarsal kink syndrome — A unique presentation

Anuradha Raj, R.C. Nagpal, Renu Dhasmana, Amit Maitreya

Department of Ophthalmology, Himalayan Institute of Medical Sciences,  
Swami Rama Himalayan University, Swami Ram Nagar, Jolly Grant, Dehradun,  
Uttarakhand

## Abstract

A two-year-old girl presented with complaints of watering from the left eye since birth. On examination the child had entropion of both lids of the left eye. She was unable to close her lids firmly besides limitation in abduction in both eyes. On the basis of clinical examination it was opined to be a case of Möbius syndrome with its association of tarsal kink syndrome — an extremely rare presentation. The surgery was performed for the left upper and lower lids comprising of tarsotomy, marginal rotation and levator suturing with tarsal plate for upper lid and strengthening the inferior lid retractors by its advancement to the lower tarsal plate for lower lid entropion.

**Keywords:** Möbius syndrome, tarsal kink syndrome, congenital entropion

## Introduction

The tarsal kink syndrome (TKS), a rare and severe form of congenital upper eyelid entropion with a marked kink in the entire horizontal length of the upper tarsal plate with resultant inversion of the eyelid margin, was described in 1948.<sup>1</sup>

The etiology of tarsal kink may be attributed to overacting orbicularis fibers, an aponeurotic defect, a primary tarsal defect or an exogenous mechanical force *in utero*.<sup>2</sup> Secondary blepharospasm and an absent eyelid crease are landmark features of this syndrome. The folded edge of the upper tarsus or the inturned eyelashes may traumatize the cornea and cause corneal abrasion, ulceration, keratitis and stromal opacification. Surgery is usually required to prevent corneal damage.

Paul Julius Möbius, a German neurologist, in 1888 first described a clinical entity of bilateral combined palsies of the 6<sup>th</sup> and 7<sup>th</sup> cranial nerves that subsequently carried his name.<sup>3</sup> Möbius syndrome (MS) results due to underdevelopment of the abducent and facial cranial nerves.<sup>4</sup> The etiology of MS is multifactorial with most supported factor of transient ischemic or hypoxic insult to the fetus.<sup>8</sup> Infectious, genetic etiologies and the use of misoprostol, a prostaglandin-E1 analog and abortifacient during pregnancy has also been implicated.<sup>5</sup> We report a case of unilateral TKS of the upper eyelid and entropion of both lids in a case of MS which has not been reported in literature yet.

**Correspondence:** Dr. Anuradha Raj, Assistant Professor, Department of Ophthalmology, Himalayan Institute of Medical Sciences, Swami Rama Himalayan University, Swami Ram Nagar, Jolly Grant, Dehradun, Uttarakhand.  
E-mail: [dranuradha\\_sagar@yahoo.com](mailto:dranuradha_sagar@yahoo.com)

## Case Report

A two-year-old girl presented with tearing from left eye since birth and found to have inturned lashes in both upper and lower lids. She was unable to move her eye laterally and could not close the eye completely. The child was born at full term by Caesarian section after an uncomplicated pregnancy. There was no family history of muscular or neurological disease and no consanguinity. Pediatric examination showed dysmorphic facial features, flat left hemifacies with delayed milestones.

She had a history of difficulty in sucking the milk from bottle or swallow food but could feed from the breast. On facial examination her upper lip was stiff and retracted and she was not able to smile or wrinkle her face. She had mask like facies. She was unable to close her eyes fully, smile, frown or raise her eyebrows. Bell's phenomenon was good. The mouth opening was very small with a normal-sized tongue which could not be protruded. The lower jaw had micrognathia or retrognathia. The front teeth were touching the lower lip while closing the mouth because of incomplete formation of the maxilla, which is called an anterior open bite (Fig. 1). No evidence of a high arched palate or cleft palate was seen. On ophthalmological examination, the child had esotropia of 40 prism dioptre and extraocular movement examination revealed limitation of abduction of  $-4$  on either side. Retinoscopy was  $-5DSph/-1.75D\text{ cyl }180^\circ$  and  $+0.75DSph/-4.0D\text{ cyl }75^\circ$  for the right and left eye respectively. She was turning her head to see the objects in temporal fields. Dolls-eye movements were absent and no nystagmus was observed. The left eye had entropion with mild ptosis, epicanthal fold with inturned cilia of both upper and lower lids (Fig. 2). On palpation a ridge was felt three mm away from the upper lid margin. On eversion of upper lid tarsal kink was seen as a concavity of the tarsus beneath the conjunctiva. Superficial punctate keratopathy was seen in the central part of cornea as a result of entropion of both lids.

The rest of the anterior and posterior segment examination was unremarkable. The nasolacrimal duct was patent on syringing. MRI brain, echocardiography and auditory examination were unremarkable.

Diagnosis of MS with unilateral TKS and lower lid entropion oculus sinister was established. Surgical management was planned in view of corneal involvement as described by Dilek *et al.*<sup>6</sup>

The surgery was performed under general anesthesia. The procedure adopted for upper lid entropion and tarsal kink was as follows: A horizontal skin incision was made at the symmetrical level of the fellow eye. The tarsal plate was exposed and a horizontal half-thickness incision was made over the tarsal kink. The wound was closed with three double-armed Vicryl 6-0 sutures.

Firstly, the levator aponeurosis was anchored to the tarsal plate involving both edges of the tarsotomy and the sutures were tied firmly. Secondly, these needles were taken out through full thickness of skin incision and tied in a fashion so as to relieve the entropion.


For lower lid entropion, a horizontal incision was made in the skin of the lid about four mm below the upper border of the lower tarsal plate. Inferior retractors were identified and strengthened by anchoring them to the tarsal plate just below its

upper border. Skin sutures were tied in a fashion to make the lids slightly everted.

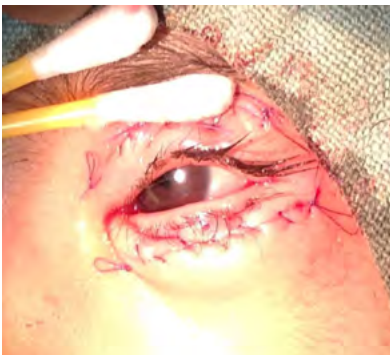Correction of entropion of both lids was achieved on the table (Fig. 3). Topical broad spectrum antibiotic ointment and lubricating eye drops were used postoperatively. Follow-up was done the tenth day and the third month. The child was relieved of both lids entropion and its problems of watering, irritation and pain (Fig. 4).



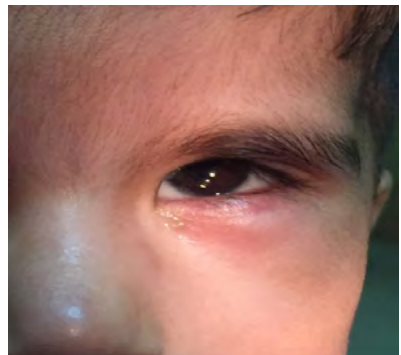**Fig. 1.** Image showing left facial palsy, bilateral esotropia, retrognathia, upper lip retraction, anterior open bite with right head turn.



**Fig. 2.** Image showing Left upper and lower lid entropion with epicanthal fold.



**Fig. 3.** Close-up image showing corrected both lids entropion on table.



**Fig. 4.** Postoperative follow up after three months

## Discussion

MS is a rare condition characterized by sixth and seventh nerve palsies. Although it is often diagnosed later, it can be recognized in infants with 'mask-like' expressionless facies noticed during crying and by an inability to suck while nursing because of seventh cranial nerve palsy. Due to sixth nerve palsy, the patient cannot follow objects by moving their eyes outwards. Instead, they turn their head. Abramson *et al.*<sup>8</sup> actually classified and graded the MS on the basis of the clinical findings of cranial nerve palsies and musculoskeletal anomalies by using the acronym CLUFT (cranial nerve, lower limb, upper limb, face and thorax). This grading system included cranial nerve features of either partial or complete sixth or seventh nerve palsies or both; lower extremity findings of talipes equinovaris, ankylosis, longitudinal or transverse deficits; upper extremity involvement with digital hypoplasia or failure of formation; structural facial findings of cleft palate, micrognathia or microtia and thoracic findings of scoliosis, pectoral hypoplasia or other chest wall deformity. CT and MR imaging findings include pons hypoplasia, depression of the fourth ventricle, absence of the medial colliculus at the level of the pons, hypoglossal nuclei hypoplasia, calcification in the pons in the region of the abducens nuclei and cerebellar hypoplasia.<sup>9</sup>

Congenital horizontal tarsal kink as described by Callahan is a rare form of upper eyelid entropion characterized by a horizontal kink within the upper tarsal plate.<sup>7</sup> Early recognition and appropriate management of congenital horizontal tarsal kink by the pediatrician or primary ophthalmologist are important as permanent corneal scarring in newborns can lead to amblyopia. Congenital entropion with tarsal kink can easily be overlooked because of tightly closed lids and difficult eversion of the upper lid in the crying infants. Corneal opacity at birth, absence of upper eyelid crease and lack of visibility of the upper eyelid margin are important clues. Corneal infiltrates were noted in 50% of cases in the collective analysis of prior reports.<sup>2</sup>

Congenital tarsal kink observed in the neonatal period is more severe than at later age as reported by Naik *et al.*<sup>10</sup> It is assumed that the tarsal kink flattens with time.

Zak *et al.*<sup>11</sup> observed multiple cardiovascular, musculoskeletal, and central nervous system abnormalities in a child with congenital primary upper eyelid entropion.

The surgical goal involves weakening the kink with margin rotation and eyelid crease formation which can be corrected by partial thickness horizontal tarsal incision with marginal rotation and strengthening the levator muscle by reattaching it to the tarsal plate and skin edges.<sup>6</sup>

In the present case, upper lid tarsal kink with both lids entropion was corrected in order to prevent corneal pathology and subsequent amblyopia. Its association with MS made this case a unique presentation. In the present available literature, no such case has been reported yet. Physical, occupational and speech therapy will be planned for improving her motor skills and coordination which will lead to better control of speaking and eating abilities. Amblyopia therapy will soon be started and subsequently surgery for esotropia will be planned. The relationship between the congenital entropion of both lids of one eye with tarsal kink of upper lid and MS

is hypothetical issue which could be due to the musculoskeletal involvement. The lower lid entropion can be due to imbalance between orbicularis oculi and lower lid retractors due to facial palsy.<sup>12</sup>

## Conclusion

MS, TKS and lower lid entropion are different in their genesis and their coexistence is unique. In future, such reports may frame some clue in regard to the genesis of this unique combination.

## References

1. Kettesy A. Entropion in infancy caused by folding of the tarsus: report of a case. *Arch Ophthalmol* 1948;39:640-642.
2. Sires BS. Congenital horizontal tarsal kink: clinical characteristics from a large series. *Ophthal Plast Reconstr Surg* 1999;15:355-359.
3. Möbius PJ. Ueber angeborene doppelseitige Abducens-Facialis-Lähmung. *Münchener Medizinische Wochenschrift* 1988;35:91-94.
4. Briegel W. Neuropsychiatric findings of Möbius sequence - a review. *Clin Genet* 2006;70(2):91-97.
5. Pastuszak AL, Schuler L, Speck-Martins CE, et al. Use of misoprostol during pregnancy and Möbius syndrome in infants. *N Engl J Med* 1998;19:1553-1554.
6. Yuksel D, Kosker M. The Surgical Treatment of Congenital Tarsal Kink Syndrome Associated With Corneal Ulcer. *Ophthalmic Surg Lasers Imaging* 2011;42:e126-128.
7. Callahan A. *Reconstructive Surgery of the Eyelids and Ocular Adnexa*, pp. 37-40. Birmingham, AL: Aesculapius 1966.
8. Abramson DL, Cohen M, Mulliken JB. Möbius syndrome: classification and grading system. *Plast Reconstr Surg* 1998;102:961-967.
9. Pedraza S, Gamez J, Rovira A, et al. MRI findings in Möbius syndrome: correlation with clinical features. *Neurology* 2000;55:1058-1060.
10. Naik MN, Honavar SG, Bhaduri A, Linberg JV. Congenital horizontal tarsal kink - a single-center experience with 6 cases. *Ophthalmology* 2007;114:1564-1568.
11. Zak TA. Congenital primary upper eyelid entropion. *J Pediatr Ophthalmol Strabismus* 1984;21:69-73.
12. Pasco NY, Kikkawa DO, Korn BS, et al. Facial nerve paralysis: an unrecognized cause of lower eyelid entropion in the pediatric population. *Ophthal Plast Reconstr Surg* 2007;23(2):126-129.