

Anterior segment optical coherence tomography documentation of Reverse Pupillary Block

Devendra Maheshwari¹, Renagappa Ramakrishnan¹,
Neelam Pawar¹

¹Aravind Eye Hospital, Tirunelveli, Tamilnadu, India

Abstract

We report a 10-year-old boy with unusually dense, bilateral central posterior capsule pigmentation associated with the characteristic clinical features of pigment dispersion syndrome, including Krukenberg's spindle and dense trabecular pigmentation in both eyes. There was no history of trauma, laser or intraocular surgeries. The presence of posterior or backward bowing of iris suggested a reverse pupillary block mechanism of pigment dispersion syndrome. Nd Yag laser peripheral iridotomy was performed in both eyes to relieve reverse pupillary block. Anterior segment optical coherence tomography (AS-OCT) showed reversal of iris concavity after laser iridotomy.

Key words: Pigment dispersion syndrome; Pigmentation; Posterior capsule; Neodymium Yttrium Yag laser peripheral iridotomy. Anterior segment optical coherence tomography.

Pigment dispersion syndrome (PDS) typically develops in young adults and is most commonly diagnosed in the second to fourth decade. This clinical condition is typically seen in young, myopic males. PDS is characterized by the presence of Krukenberg spindles, iris trans-illumination defects, trabecular meshwork pigmentation and backward bowing of the iris.^{1,4}

PDS is unusual in a pediatric age, although it has been previously described in the western literature.⁵⁻⁸ To our best knowledge no PDS case has been reported in literature in Indian population.

We describe a case of typical pigment dispersion syndrome in 10-year-old Asian Indian child with elevated Intraocular pressure (IOP).

Case Report

A 10-year-old boy presented with complaint of defective vision of six month duration (Fig. 1). He had no history of trauma, surgery or any systemic illness. There was no history of headache, blurred vision or haloes. He had family history of glaucoma with grandmother being affected with primary open angle glaucoma. He had no history of any spectacle use previously.

On examination, his uncorrected visual acuity was 20/60 in both eyes. The best corrected visual acuity (BCVA) was 20/20 with -1.00 D cylinder x90 in right eye and -1.50 D cylinder x90 in left eye. He was not prescribed any spectacles previously. During examination clinical findings of PDS were noted.

Correspondence: **Correspondence:** Devendra Maheshwari, Medical Officer, Glaucoma Departement, Aravind Eye Hospital, Tirunelveli, Tamilnadu, India.
E-mail: drdev_ophthal@hotmail.com

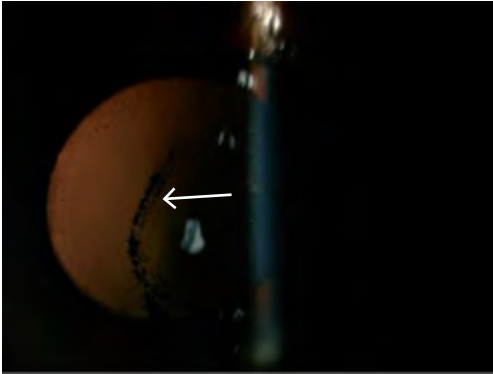


Fig. 1a. Pigmentation of posterior lens capsule, Pigment deposited on the posterior lens surface, Zentmayer's line. (white arrow)




Fig. 1b. Pigment accumulation occurring at the junction of the zonules and posterior capsule Scheie's line. (white arrow)

The IOP with Goldman Applanation tonometer was 36mm Hg in right eye and 39mmHg in left eye (adjusted according to CCT). On slit-lamp examination, a pigment deposition on the corneal endothelium in a spindle shaped manner (Krukenberg's spindle) along with deep anterior chambers with few pigments. Radial, slit like iris transillumination defects were noted in both eyes. These defects were typically located in the periphery of the iris. There was bilateral central posterior capsule pigmentation with evident Zentmeyers line and Scheies line (Fig. 2a & 2b). Gonioscopy revealed wide open angle grade 4 (Shaffers Grading) with 4+ pigmentation of the trabecular meshwork with iris concavity in midperiphery in both eyes. Corneal pachymetry was 665 um in right eye and 668 um in left eye. The horizontal corneal diameters were 12 mm and 12.5 mm in right and left eye respectively. Axial length was 24.00mm in right eye and 24.05 in left eye (Carl Zeiss IOL Master). The cup-disc ratio was 0.4 in both eyes with healthy neuroretinal rim and retinal nerve fiber.

Peripheral fundus examination showed lattice degeneration with multiple holes in both eyes for which prophylactic barrage laser was done. Humphrey visual fields (24-2) were normal in both eyes. Anterior segment optical coherence tomography (Visante 1000, Carl Zeiss Meditec Inc, and Dublin, CA, USA) showed a concave iris configuration in both eyes [Figure 2a and 2c].

Nd-Yag laser peripheral iridotomy was performed in the both eyes to relieve reverse pupillary block. Post iridotomy IOP was 32 mm in right eye and 34 mmHg in left eye after 1 week . He was prescribed Latanoprost (Latanoprost 0.005%, Sunpharma, India) and at one month IOP was 24 mmHg in both eye. AS-OCT showed reversal of iris concavity after laser iridotomy (Fig. 2b & 2d). There was significant difference in ASOCT parameters pre and post Laser PI (Table 1 and 2).

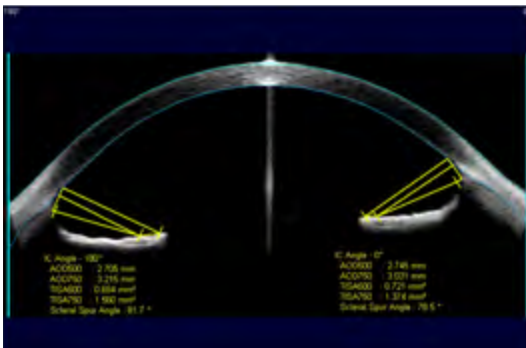


Fig. 2a. Showing Anterior segment optical coherence tomography (ASOCT) in right eye before Laser peripheral iridotomy (LPI).

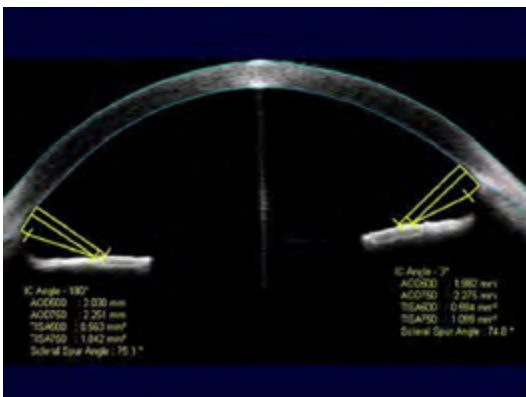


Fig. 2b. Anterior segment optical coherence tomography (ASOCT) showing flattening of iris post PI in right eye.

Table 1. AS OCT Parameters Pre and Post Laser PI in RE

AS OCT Parameters RE	IC Angle 180 Pre Laser PI	IC Angle 180 Post Laser PI	P-value	AS OCT Parameters RE	IC Angle 0 Pre Laser PI	IC Angle 0 Post Laser PI	P-value
AOD 500	2.705	2.030	0.043*	AOD 500	2.745	1.982	0.043*
AOD 750	3.215	2.251		AOD 750	3.031	2.275	
TISA500	0.694	0.563		TISA500	0.721	0.594	
TISA 750	1.56	1.042		TISA 750	1.374	1.069	
SSA	81.7	75.1		SSA	78.5	74.8	

*Wilcoxon signed-rank test

AOD -Angle opening distance (in mm), TISA(mm²) Trabecular Iris Space Area, SSA –Scleral Spur Angle

Table2. AS OCT Parameters Pre and Post Laser PI in LE

AS OCT Parameters LE	IC Angle 180 Pre Laser PI	IC Angle 180 Post Laser PI	P-value	IC Angle 0 Pre Laser PI	IC Angle 0 Post Laser PI	P-value
AOD 500	2.116	1.534		1.912	1.845	
AOD 750	2.408	1.768	0.043*	2.239	2.085	0.043*
TISA500	0.542	0.470		0.594	0.491	
TISA 750	1.073	0.882		1.158	0.993	
SSA	76.3	70.3		77.1	74.8	

*Wilcoxon signed-rank test

Discussion

Pigment dispersion syndrome is typically seen in the younger age group ranging from 20–40 years.^{1,2} It is quite unusual to find pigment dispersion syndrome in young child. Reports of PDS in the paediatric group is not so common, lack of symptoms despite high IOP in this age group may be reason of this paucity in literature.

The mechanism of the pigment dispersion was elucidated by Campbell, who provided evidence for a rubbing between lens zonules and iris pigment epithelium, with release of pigment granules.⁴

The backward bowing of the mid-peripheral iris, described by Campbell, is of key importance in the etiology of PDS. The presence of iris back bowing suggests a reverse pupillary block mechanism of pigment dispersion syndrome.⁴

Karickhoff also described a form of reverse pupillary block, in which he suggested

that the iris acted as a flap valve against the anterior lens surface. This so-called valve would allow aqueous to flow forward because of a pumping action of the mid-peripheral iris in association with ocular movement. However, the valve effect would prevent the aqueous from flowing backward, thereby increasing anterior chamber pressure and pushing the peripheral iris backward against the lens zonules, causing a further shedding of pigment.⁸ The similar iris configuration seen in PDS/PG led to Campbell's and Karickhoff's theory of reverse pupillary block.

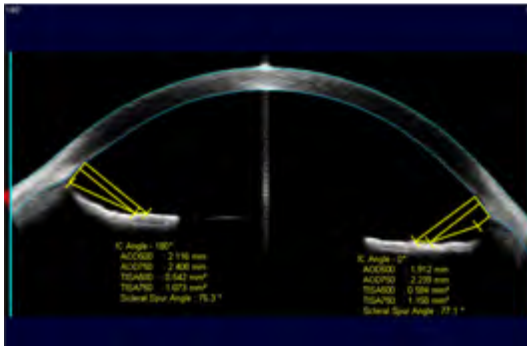


Fig. 2c. Showing Anterior segment optical coherence tomography (ASOCT) in left eye before LPI.

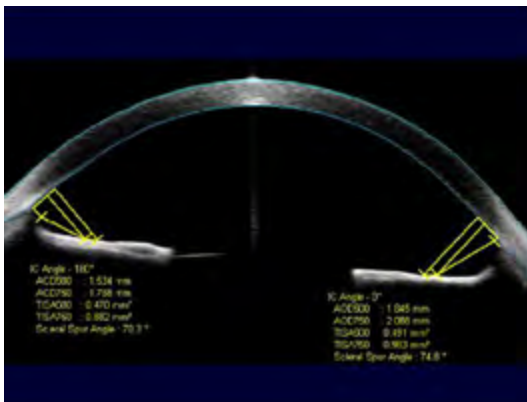


Fig. 2d. Anterior segment optical coherence tomography (ASOCT) showing flattening of iris post PI in left eye.

In a series of 407 pigment dispersion syndrome patients, the youngest age described was 14 years old; the youngest with accompanying elevated IOP was 25 years old.⁴ Lazaro Garcia and associates reported pigment dispersion syndrome with megalocornea in a 12-year-old child.⁵

Kaiser-Kupfer and associates described three brothers who developed pigment dispersion syndrome at an early age; Out of three one showed, iris transillumination defects at the age of 7 years.⁶

Grassi *et al.* described PDS, with atypical features in an 8 year old patient.⁷

Ritch *et al.* reported an 11-year-old girl with typical features of bilateral PDS and elevated intraocular pressure (IOP). They also described it in two 12-year-old boys, one with a more severe phenotype with both affected parents and the other having

a less severe phenotype single affected parent.⁸ Argon laser peripheral iridotomy was performed in both eyes of one boy and one eye of other.

Preliminary success of treatment by laser peripheral iridotomy (LPI) has been reported by Karickhoff and by Campbell and Schertzer.^{4,8} LPI is traditionally thought to be of benefit in PDS, because it is supposed to decrease the risk of development of pigmentary glaucoma. However Scott *et al.* in a prospective, randomized, controlled trial found there was no benefit of Nd: YAG LPI in preventing progression from PDS with ocular hypertension to pigmentary glaucoma. It is possible that the treatment may be effective in younger patients: those without irreversible trabecular meshwork damage or in those with documented increased iridozonular contact (iris concavity and more posterior iris root insertion).¹⁰

However, to the best of our knowledge, 10-year-old boy described in this report is the youngest and first Asian Indian with typical features of bilateral PDS and elevated IOP. Laser peripheral iridotomy relieved reverse pupillary block and additional antiglaucoma medication were needed to lower IOP.

References

1. Niyadurupola N, Broadway DC. Pigment dispersion syndrome and pigmentary glaucoma-a major review. *Clin Experiment Ophthalmol* 2008;36:868-82.
2. Sugar HS. Pigmentary glaucoma: a 25-year review. *Am J Ophthalmol* 1966;62:499-507.
3. Scheie HG, Cameron JD. Pigment dispersion syndrome: a clinical study. *Br J Ophthalmol* 1981;65:264-9.
4. Campbell DG. Pigmentary dispersion and glaucoma: a new theory. *Arch Ophthalmol* 1979;97:1667-72.
5. García CL, Feijoó JG, Sardiña JC, Gómez AC, Benítez Del Castillo JM, Benítez JM, *et al.* Pigment dispersion syndrome in a patient with megalocornea. *Arch Soc Esp Oftalmol* 2000;75:347-350.
6. Kaiser-Kupfer MI, Kupfer C, McCain L. Asymmetric pigment dispersion syndrome. *Trans Am Ophthalmol Soc* 1983;81:310-324.
7. Grassi MA, Alward WL, Verdick RL, Langlow EP, Kwon YH. Atypical pigment dispersion syndrome in a child. *Am J Ophthalmol* 2004;137:753-6.
8. Dorairaj SK, Robin A, Shihadeh W, Greenberg S, Liebmann JM, Ritch R. Phenotypic Variability of Pigment Dispersion Syndrome in Children. *Arch Ophthalmol* 2007;125:136-8.
9. Karickhoff JR. Pigmentary dispersion syndrome and pigmentary glaucoma: a new mechanism concept, a new treatment, and a new technique. *Ophthalmic Surg* 1992;23:269-77.
10. Scott A, Kotecha A, Bunce C, Balidis M, Garway-Heath DF, Miller MH, Wormald R. YAG laser peripheral iridotomy for the Prevention of Pigment Dispersion Glaucoma. *Ophthalmology* 2011;118:468-73.