

# Outcomes following orbital decompression surgery for dysthyroid optic neuropathy associated with Graves' ophthalmopathy

Jerome Ha<sup>1</sup>, James Leong<sup>1</sup>, Peter Martin<sup>1</sup>

<sup>1</sup>Sydney Eye Hospital, Sydney, Australia

## Abstract

**Purpose:** To investigate the outcomes of orbital decompression surgery for dysthyroid optic neuropathy associated with severe Graves' ophthalmopathy.

**Design:** Ten years (2000-2010) retrospective case series.

**Methods:** Thirty-eight orbits (with dysthyroid optic neuropathy) of 119 surgical orbital decompressions. Patients with dysthyroid optic neuropathy associated with Graves' ophthalmopathy, who underwent orbital decompression surgery at Sydney Eye Hospital (Sydney, Australia), were investigated for outcome measures.

**Results:** Thirty-five orbits were eligible for data analysis. Orbital decompression surgery improved visual acuity in 29 orbits and maintained visual acuity in four orbits. In patients with dysthyroid optic neuropathy, there was a statistically significant mean improvement in visual acuity of 2.8 lines postoperatively (standard deviation = 3.2; 95% confidence interval 3.9 to 1.7,  $p$ -value < 0.05). There were no statistically significant differences in visual acuity amongst different combinations of orbital walls being decompressed, with the majority of orbits had the medial orbital wall decompressed. This may reflect the small number of decompressions performed in each subgroup. Orbital decompression surgery reduced proptosis by a mean of 3.2 mm (standard deviation = 2.9; 95% confidence interval -4.32 to -2.07;  $p$ -value < 0.05). Medial and lateral orbital walls decompression resulted in the greatest mean reduction in proptosis. There were no severe visual impairment cases postoperatively (VA worse than 6/60). There were two patients with new onset diplopia postoperatively. There were three orbits with bleeding and one orbit with CSF leakage, all without major sequelae postoperatively.

**Conclusion:** Regardless of surgical access, orbital decompression surgery is effective and safe in the management of dysthyroid optic neuropathy and in reducing proptosis in patients with Graves' ophthalmopathy.

**Key words:** Dysthyroid optic neuropathy, surgical decompression, Graves' ophthalmopathy, visual acuity, Hertel's exophthalmometry, adverse outcomes

## Introduction

Dysthyroid optic neuropathy (DON) occurs in 5-6% of patients with Graves' ophthalmopathy{McNab, 1997 #33}{Leong, 2009 #10},<sup>1</sup> which could be threatening to vision.<sup>2</sup> Systemic glucocorticoids and orbital decompression surgery are

**Correspondence:** Peter Martin.

E-mail: [peteramartin@ozemail.com.au](mailto:peteramartin@ozemail.com.au)

This study was approved by the Human Research Ethics Committee of the Northern Hospital Network of New South Wales Health, New South Wales, Australia.

the treatment of choice for DON.<sup>2</sup> Orbital decompression surgery usually results in resolution of DON with a relatively acceptable adverse outcomes profile.<sup>2</sup>

Previous studies have demonstrated the efficacy and relative safety of surgical orbital decompression.<sup>3-6</sup> A systematic review recommended reporting of surgical outcomes based on one indication, in order to facilitate future meta-analysis of outcomes.<sup>7</sup>

With this in mind, the present study aims to report main outcome measures which include change in visual acuity, change in proptosis as measured by exophthalmometry measurements and new onset diplopia, after orbital decompression surgery for DON.

## Methods

Consecutive patients who underwent orbital decompressions for dysthyroid optic neuropathy at a single tertiary referral centre between January 2000 and December 2010 were retrospectively identified. The decision to operate on individual patients was made by the consultant surgeon in charge, if there were evidence of reduction in vision from baseline, reduction in color vision, presence of afferent pupillary defect and orbital imaging evidence of crowding of the orbital apex. Data was obtained by subsequent review of the medical records.

Patient information recorded included sex, age at the time of surgery, smoking status and thyroid status (thyroid function test). The surgical approach and any complications of surgery were also recorded. The main outcome measures include pre-operative and postoperative best corrected Snellen visual acuity, proptosis measurement using Hertel exophthalmometry (Zeiss, Jena, Germany) and the presence of diplopia. The Snellen visual acuity was converted to the log of the minimum angle of resolution (LogMAR) values in order to perform statistical analysis for visual acuity.<sup>8</sup>

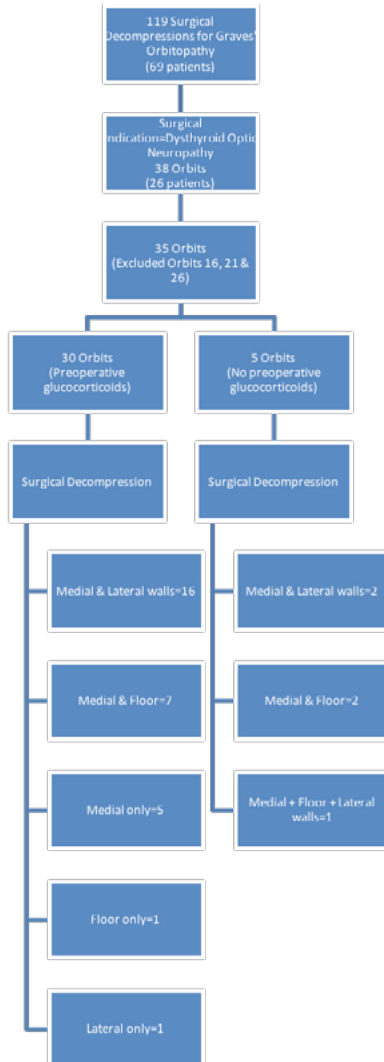
These data were analyzed for change in visual acuity, change in proptosis as measured by exophthalmometry measurements, new onset diplopia and other operative adverse events. The statistical analysis performed included paired T-test verified with the Wilcoxon Signed-Rank test. Subgroup analysis was performed using the two-sample T-test. Results were considered significant if  $P \leq 0.05$ .

The research questions are:

1. Does orbital decompression surgery preserve and/or improve visual acuity in patients with DON associated with Graves' ophthalmopathy and if so, is there any difference in visual outcome amongst subgroup of orbits (*i.e.*, comparisons of combinations of orbital wall(s) being decompressed)?
2. Does administration of preoperative glucocorticoids influence final visual outcome?
3. Does orbital decompression surgery reduces proptosis in patients with DON associated with Graves' ophthalmopathy and if so, which combination of orbital walls decompression results in the highest amount of reduction in proptosis?
4. What are the adverse outcomes in this cohort of patients?

## Results

Over the ten- years study period, there were a total of 119 surgical decompressions for Graves' ophthalmopathy on 69 patients (Fig. 1). Of these, there were a total of 38 orbits of 26 patients for which the indication for surgery was dysthyroid optic neuropathy (Fig 1). Thirty-five orbits were eligible for analysis. Two orbits were excluded due to incomplete visual acuity data. One orbit was excluded as this data was from a subsequent surgery (*i.e.*, the orbit required a second operation due to recurrence of dysthyroid optic neuropathy).



**Fig. 1.** Illustration of our case series of 35 orbits which underwent orbital decompression surgery for dysthyroid optic neuropathy associated with Graves' ophthalmopathy.

There were 20 female patients (31 orbits) and six male patients (seven orbits). The patients' age ranged from 28 years to 74 years, with an average age of 53.6 years. Fifteen patients had unilateral surgical decompression (16 orbits), one patient requiring repeated surgery on the same side. This patient had repeated surgery on the same side six weeks after the initial surgery due to recurrence of DON whilst steroids were weaned. Eleven patients had bilateral surgical decompressions (22 orbits). Within the bilateral surgical decompressions group, five patients had simultaneous surgery (on the same day) and six patients had sequential surgery (on different days, ranging from five days to three months). The average postoperative follow-up period was 9.9 weeks (range one to 36 weeks).

Preoperatively, the majority of orbits were treated with glucocorticoids (Fig 1). The mean preoperative VA within the group treated with glucocorticoids preoperatively was  $0.45 \pm 0.51$  LogMAR units (Snellen equivalent  $6/16.9 \pm 5.1$  lines). The mean postoperative VA within this group was  $0.14 \pm 0.30$  LogMAR units (Snellen equivalent  $6/8.3 \pm 3.0$  lines). Thus, there was an average improvement of  $3.1 \pm 3.2$  lines of VA. The oral prednisolone therapy was weaned off postoperatively. On the other hand, the mean preoperative VA within the group not treated with glucocorticoids preoperatively was  $0.28 \pm 0.17$  LogMAR units (Snellen equivalent  $6/11.4 \pm 1.7$  lines). The mean postoperative VA within this group was  $0.19 \pm 0.25$  LogMAR units (Snellen equivalent  $6/9.3 \pm 2.5$  lines). Thus, there was an average improvement of  $0.9 \pm 2.8$  lines of VA.

Of the orbits, 73.7% have had two walls decompressed (Table 1).

**Table 1. The proportion of orbital decompression surgeries involving different orbital walls.**

Orbital walls	Orbital fat		Number of orbits	Percentage of cases	
	Removed	Not Removed			
<b>Medial, Lateral &amp; Floor</b>	0	3	3		7.9%
<b>Medial &amp; Lateral</b>	0	18	18		47.4%
<b>Medial &amp; Floor</b>	5	5	10		26.3%
<b>Medial only</b>	1	4	5		13.2%
<b>Lateral only</b>	0	1	1		2.6%
<b>Floor only</b>	1	0	1		2.6%

### *Outcomes in visual acuity (after any orbital decompression surgery)*

Twenty-nine orbits showed improvement in VA postoperatively (Table 2), 24 out of 29 orbits (83%) with postoperative VA equal to or better than 6/9. Four orbits had maintained VA postoperatively (6/9; 6/18; 6/6; 6/6), with the majority with VA of 6/9 or better. Two orbits had worsened VA (6/12 to 6/24; 6/5 to 6/6). Three patients (orbits 16, 21 and 26; Fig. 1) were excluded due to aforementioned reasons.

VA will be converted into LogMAR to facilitate comparison and statistical analysis.<sup>8</sup> The LogMAR value will be subsequently converted back to the Snellen equivalent. The mean preoperative visual acuity was 0.43 LogMAR units (standard deviation = 0.48), whereas the mean postoperative visual acuity was 0.15 LogMAR units (standard deviation = 0.29). In Snellen notation, the mean preoperative visual acuity was 6/16 ± 4.8 lines; the mean postoperative visual acuity was 6/8.5 ± 2.9 lines.

Paired T-Test was performed to measure the overall outcome of VA following surgical decompression in DON. In patients with DON, there was a statistically significant mean improvement in VA of 2.8 lines postoperatively (standard deviation = 3.2; 95% confidence interval 3.9 to 1.7, p-value < 0.05). The power ( $\alpha = 0.05$ ) was 0.99. The Wilcoxon Signed-Rank Test confirmed the findings from the Paired T-Test. There was a positive correlation between pre-operative VA and postoperative VA (Correlation Coefficient = 0.75).

**Table 2. The outcomes in visual acuity after any type of orbital decompression surgery in this case series.**

<b>Outcomes in VA</b>	<b>Number of orbits</b>
<b>Improvement</b>	29
<b>Maintained</b>	4
<b>Worsened</b>	2
<b>Excluded</b>	3
<b>Total</b>	38

*Outcomes in VA (comparisons of different surgical techniques)*

Two-sample T-test was utilized to compare postoperative VA amongst four comparison groups (Table 3). There were no statistically significant differences amongst these comparison groups.

**Table 3. Two-sample T-test results of different comparison groups (outcomes in VA).**

Comparison groups	Mean difference (LogMAR units)	Standard deviation	95% Confidence Interval	P-value
<i>Orbital walls</i>				
<b>Medial &amp; Lateral vs. Medial &amp; Floor</b>	-0.07	0.35	-0.35 to 0.21	0.55
<b>Medial &amp; Lateral vs. Medial</b>	0.11	0.38	-0.29 to 0.52	0.57
<b>Medial &amp; Floor vs. Medial</b>	0.18	0.27	-0.14 to 0.50	0.24
<i>Orbital fat</i>				
<b>Orbital fat excision (n = 5) vs. No orbital fat excision (n = 5)</b>	<b>-0.22</b>	<b>0.21</b>	-0.52 to 0.08	0.13

*Outcomes in proptosis (after any orbital decompression surgery)*

Using the Paired T-Test, there was a statistically significant mean reduction in proptosis of 3.2 mm after orbital decompression surgery (standard deviation = 2.9; 95% confidence interval -4.32 to -2.07; p-value < 0.05). The power ( $\alpha = 0.05$ ) was 0.99. The Wilcoxon Signed-Rank Test confirmed the findings from the Paired T-Test. There was a positive correlation between pre-operative proptosis and postoperative proptosis (Correlation Coefficient = 0.70).

*Outcomes in proptosis (comparisons of different surgical techniques)*

Medial and lateral orbital walls decompression resulted in mean reduction of 3.9 mm in proptosis postoperatively, whereas medial wall and floor decompression resulted in mean reduction of 1.1 mm in proptosis postoperatively (Table 4). This is likely associated with incorporating the lateral orbital wall during decompression.

Using the Two-sample T-test, there was a statistically significant difference between these two subgroups (mean difference = -2.81; P-value < 0.05) (Table 5). There was no statistically significant difference between orbital fat excision and no orbital fat excision (mean difference = -0.73; P-value = 0.40) (Table 5).

**Table 4. Orbital decompression surgeries involving different orbital walls and the outcomes in proptosis.**

Orbital walls	Number of orbits	Mean change in proptosis postoperatively (mm)	Range	Standard deviation	95% Confidence Interval
<b>Medial &amp; Lateral</b>	18	-3.9	-11.0 to 1.0	3.2	-5.66 to -2.21
<b>Medial &amp; Floor</b>	10	-1.1	-2.5 to 1.0	1.1	-2.04 to -0.21

**Table 5. Two-sample T-test results of different comparison groups (outcomes in proptosis).**

Comparison groups	Mean difference	Standard deviation	95% Confidence interval	P-value	Power ( $\alpha = 0.05$ )
<i>Orbital walls</i> <b>Medial &amp; Lateral vs. Medial &amp; Floor</b>	-2.81	3.41	-4.68 to -0.94	< 0.05	0.85
<i>Orbital fat</i> <b>Orbital fat excision (n = 5) vs. No orbital fat excision (n = 3)</b>	-0.73	1.11	-2.71 to 1.25	0.40	

### Adverse outcomes

There were no severe visual impairment cases postoperatively (VA worse than 6/60) (9). There were also no cases of stroke postoperatively. There were two patients with new onset diplopia postoperatively. No patients within this cohort had pre-operative diplopia. There were three orbits which had bleeding (7.9%) and one orbit which had cerebrospinal fluid (CSF) leakage (2.6%), all without major sequelae postoperatively.

## Discussion

Graves' ophthalmopathy may be thought of as a heterogeneous autoimmune orbital reaction, characterized by the presence of thyroid stimulating immunoglobulins (TSIgG), typically affecting patients of middle ages.<sup>10</sup> Risk factors associated with severe forms of Graves' ophthalmopathy include genetic,<sup>11</sup> increasing age,<sup>12</sup> male sex<sup>13</sup> and high levels of thyrotropin receptor autoantibodies.<sup>14</sup> Cigarette smoking can affect the response to treatment (steroids and orbital irradiation) in a dose-dependent fashion.<sup>15</sup> Orbital decompression surgery may be considered when medical decompression has failed to relieve dysthyroid optic neuropathy associated with severe Graves' ophthalmopathy. Wakelkamp et al suggested that

in severe Graves' ophthalmopathy with compressive optic neuropathy, immediate orbital decompression surgery does not appear to result in better outcomes and therefore recommended immediate high doses of systemic glucocorticoids therapy.<sup>3</sup> Urgent orbital decompression surgery is considered if immunosuppressive therapy has failed to halt the progression of Graves' ophthalmopathy.<sup>10</sup> Urgent orbital decompression is considered on the basis of several important parameters including VA reduction, contrast sensitivity reduction, significant colour vision loss, pupil function and orbital imaging (looking for evidence of loss of fat effacement in the posterior orbit with significant extraocular muscles enlargement).

The surgical approaches were chosen pre-operatively and this may introduce bias in the analysis of outcomes. The chosen surgical approaches may be influenced by surgeons' preferences, orbital anatomy (assessed pre-operatively by imaging), visual acuity, amount of proptosis and anticipated complications (including new onset diplopia).

### VA outcomes

Orbital decompression surgery is effective in improving VA postoperatively. In our study, the majority of orbits had improved VA postoperatively and this was similar to previous report in the literature.<sup>16,17</sup> In our cohort of patients with DON, there was a statistically significant mean improvement in VA after orbital decompression surgery. Goh and McNab also reported significant improvement in median VA postoperatively in orbits with DON.<sup>5</sup>

There were no statistically significant differences amongst Medial & Lateral orbital walls decompression, Medial orbital wall & Floor decompression and Medial orbital wall decompression subgroups. Of note, all three groups had the medial orbital wall decompressed. In this case series, surgical access to the medial orbital wall is predominantly transcaruncular, with the remainder via endoscopic and cutaneous methods. We suggest that the medial orbital wall should be decompressed in orbits with DON, as this creates space for decompression of the optic nerve located at the postero-medial orbit. Cruz and Leme reported similar rate of reversal of optic neuropathy in both the inferomedial transforix/transcaruncular approach and inferomedial plus lateral coronal approach.<sup>18</sup> McNab also suggested that in patients with DON, the method of surgical decompression did not influence visual acuity.<sup>4</sup> {McNab, 1997 #33}{McNab, 1997 #33}{McNab, 1997 #33}{McNab, 1997 #33}In our study, there was no statistically significant difference between orbital fat and no orbital fat excision within the Medial orbital wall & Floor decompression subgroup (in relation to postoperative VA). Kazim *et al.* reported orbital fat decompression was successfully performed in eight orbits to reverse dysthyroid optic neuropathy.<sup>19</sup>

Glucocorticoids may have influenced the final visual outcome in patients who underwent orbital decompression surgery for CON. It should be noted that the group pretreated with glucocorticoids had worse mean preoperative VA compared to the group not pretreated with glucocorticoids. Therefore, perhaps within this cohort of patients with more severe CON, the surgeon might have prescribed preoperative glucocorticoids.



### *Proptosis outcomes*

Shepard *et al.* reported a mean improvement of proptosis by 4.9 mm in patients who had compressive optic neuropathy who underwent medial and extended lateral wall decompressions.<sup>20</sup> In our study, it appears that the mean reduction in proptosis was greater for the Medial & Lateral orbital walls decompression subgroup (3.9 mm) compared to that of the Medial orbital wall & Floor decompression subgroup (1.1 mm), with statistical significance (P-value < 0.05). These results suggest that incorporating the lateral orbital wall may result in higher reduction in proptosis. There was no statistically significant difference between orbital fat and no orbital fat excision within the Medial orbital wall & Floor decompression subgroup (in relation to postoperative proptosis). Adenis *et al.* reported a mean reduction in proptosis of 4.7 mm (standard deviation = 2.4) using the trans-septal approach to extraconal and intraconal fat excision.<sup>21</sup>

### *Adverse outcomes*

As previously mentioned, there were no cases of severe visual impairment (VA worse than 6/60). There were two patients with new onset diplopia postoperatively. Patient 1 had bilateral sequential orbital decompressions involving the medial and lateral walls. Subsequent bilateral medial rectus recession resulted in improvement in the diplopia. Patient 2 underwent bilateral sequential orbital decompressions involving the medial and floor (with orbital fat removal). This patient had persistent diplopia at six months postoperatively. Graham *et al.* reported a 10% rate of occurrence of new-onset diplopia in patients who had Medial & Lateral orbital walls decompression surgery.<sup>22</sup> There were three orbits which had self-resolving bleeding. The first orbit developed postoperative bleeding associated with fat resection after Medial orbital wall & Floor decompression surgery.

The second orbit developed postoperative bleeding after Medial & Lateral orbital walls decompression (no orbital fat excision). The patient has a history of hypertension (treated) and had labile blood pressure levels both intra-operatively and during recovery. Immediate exploration and drainage of hematoma occurred and there was no visual loss postoperatively. The third orbit developed perioperative ethmoidal bleeding during Medial orbital wall & Floor decompression (with orbital fat excision), which resolved spontaneously. The patient's VA improved from 6/12 to 6/6 postoperatively. Lund *et al.* reported three cases of moderate bleeding occurring out of 20 cases who underwent orbital decompression surgery by the external Patterson approach, all of which had resolved without any major issues.<sup>23</sup> There was one orbit which had CSF leakage during Medial & Lateral orbital walls decompression surgery (no orbital fat excision). During the Lateral orbital wall decompression, the bone was removed with a drill and the temporal fossa was opened postero-laterally. CSF leakage was seen from the postero-lateral wall and was controlled with a fat plug, without significant complications. The patient had a successful orbital decompression otherwise, with VA improved from 6/12 to 6/6 postoperatively. Graham *et al.* also had two cases of CSF leak which were repaired intra-operatively without further complications.<sup>22</sup>

Future research may include comparing outcomes of patients who had received medical intervention (high dose glucocorticoids) alone versus medical and surgical interventions, preferably with a prospective study design and with sufficient power to show a difference between the two groups.

## Conclusion

Our series of 35 orbits supports the established surgical approach of orbital decompression in sight threatening cases of dysthyroid compressive optic neuropathy. In most orbits, preoperative glucocorticoids were prescribed. Visual improvement occurred in the majority of cases. We further demonstrate that complications occurred rather uncommonly and when they do occur, they are usually self-limiting. Balanced medial and lateral orbital walls decompression demonstrate a greater reduction in proptosis compared to other techniques.

## References

1. Bartley GB, Fatourech V, Kadrmas EF, Jacobsen SJ, Ilstrup DM, Garrity JA, *et al.* Clinical features of Graves' ophthalmopathy in an incidence cohort. *Am J Ophthalmol* 1996;121(3):284-290.
2. Bartalena L, Baldeschi L, Dickinson AJ, Eckstein A, Kendall-Taylor P, Marcocci C, *et al.* Consensus Statement of the European Group on Graves' Orbitopathy (EUGOGO) on Management of Graves' Orbitopathy. *Thyroid* 2008;18(3):333-346.
3. Wakelkamp IMMJ, Baldeschi L, Saeed P, Mourits MP, Prummel MF, Wiersinga WM. Surgical or medical decompression as a first-line treatment of optic neuropathy in Graves' ophthalmopathy? A randomized controlled trial. *Clin Endocrinol* 2005;63(3):323-328.
4. McNab AA. Orbital decompression for thyroid orbitopathy. *Austr N Zeal J Ophthalmol* 1997;25(1):55-61.
5. Goh MSY, McNab AA. Orbital decompression in Graves' orbitopathy: efficacy and safety. *Internal Med J* 2005;35(10):586-591.
6. Choe CH, Cho RI, Elnor VM. Comparison of Lateral and Medial Orbital Decompression for the Treatment of Compressive Optic Neuropathy in Thyroid Eye Disease. *Ophthalmic Plast Reconstruct Surg* 2011;27(1):4-11.
7. Leong SC, Karkos PD, MacEwen CJ, White PS. A systematic review of outcomes following surgical decompression for dysthyroid orbitopathy. *Laryngoscope* 2009;119(6):1106-1115.
8. Holladay JT. Proper Method for Calculating Average Visual Acuity. *J Refract Surg* 1997;13:388-391.
9. Organisation WH. Change the definition of blindness. 2008; Available from: <http://www.who.int/blindness/Change%20the%20Definition%20of%20Blindness.pdf>.
10. Bothun ED, Scheurer RA, Harrison AR, Lee MS. Update on thyroid eye disease and management. *Clin Ophthalmol* 2009;3:543-551.
11. Bednarczuk T, Gopinath B, Ploski R, Wall JR. Susceptibility genes in Graves' ophthalmopathy: searching for a needle in a haystack? *Clin Endocrinol* 2007;67:3-19.
12. Perros P, Crombie AL, Matthews JNS, Kendall-Taylor P. Age and gender influence the severity of thyroid-associated ophthalmopathy: a study of 101 patients attending a combined thyroid-eye clinic. *Clin Endocrinol* 1993;38(4):367-372.
13. Manji N, Carr-Smith J, Boelaert K, Allahabadi A, Armitage M, Chatterjee V, *et al.* Influences of Age, Gender, Smoking, and Family History on Autoimmune Thyroid Disease Phenotype. *J Clin Endocrinol Metabol* 2006;91(12):4873-4880.
14. Eckstein AK, Plicht M, Lax H, Neuhäuser M, Mann K, Lederbogen S, *et al.* Thyrotropin Receptor Autoantibodies Are Independent Risk Factors for Graves' Ophthalmopathy and Help to Predict Severity and Outcome of the Disease. *J Clin Endocrinol Metabol* 2006;91(9):3464-3470.

15. Eckstein A, Quadbeck B, Mueller G, Rettenmeier AW, Hoermann R, Mann K, *et al.* Impact of smoking on the response to treatment of thyroid associated ophthalmopathy. *Brit J Ophthalmol* 2003;87(6):773-776.
16. Girod DA, Orcutt JC, Cummings CW. Orbital Decompression For Preservation Of Vision In Graves' Ophthalmopathy. *Arch Otolaryngol Head Neck Surg* 1993;119(2):229-233.
17. Schaefer SD, Solimanzadeh P, Della Rocca DA, Yoo GP, Maher EA, Milite JP, *et al.* Endoscopic and transconjunctival orbital decompression for thyroid-related orbital apex compression. *Laryngoscope* 2003;113(3):508-513.
18. Cruz AAV, Leme VR. Orbital Decompression: A Comparison Between Trans-Fornix/Transcaruncular Inferomedial and Coronal Inferomedial Plus Lateral Approaches. *Ophthalm Plast Reconstruct Surg* 2003;19(6):440-445.
19. Kazim M, Trokel SL, Acaroglu G, Elliott A. Reversal of dysthyroid optic neuropathy following orbital fat decompression. *Brit J Ophthalmol* 2000;84(6):600-605.
20. Shepard KG, Levin PS, Terris DJ. Balanced orbital decompression for graves' ophthalmopathy. *Laryngoscope* 1998;108(11):1648-1653.
21. Adenis JP, Robert PY, Lasudry JG, Dalloul Z. Treatment of proptosis with fat removal orbital decompression in Graves' ophthalmopathy. *Eur J Ophthalmol* 1998;8(4):246-252.
22. Graham SM, Brown CL, Carter KD, Song A, Nerad JA. Medial and Lateral Orbital Wall Surgery for Balanced Decompression in Thyroid Eye Disease. *Laryngoscope* 2003;113(7):1206-1209.
23. Lund VJ, Larkin G, Fells P, Adams G. Orbital decompression for thyroid eye disease: a comparison of external and endoscopic techniques. *J Laryngol Otol* 1997;111(11):1051-1055.