

# Non-surgical management of lacrimal canaliculitis following insertion of SmartPlug

Emmy Y. Li, Andy C. Cheng, Hunter K. Yuen

Department of Ophthalmology & Visual Sciences, The Chinese University of Hong Kong, Hong Kong, China and Hong Kong Eye Hospital, Hong Kong, China

**Abstract:** Punctal plugs are popular device used for treatment of dry eyes. The SmartPlug, with its special thermodynamic properties, has the advantage to conform to the shape of the punctal ampulla and proximal canaliculus, and offers effective occlusion. However, SmartPlug related complications are not uncommon and surgical interventions are often required for management of persistent infection. This is a report of two middle-aged Asian women who developed chronic lacrimal canaliculitis after insertion of the SmartPlug Punctal Plug. Attempts at removing the SmartPlug failed and prolonged topical antibiotics resulted only in partial resolution of the infection. Subsequent forced irrigation with penicillin solution via the affected puncta using large bore lacrimal canula successfully led to complete resolution of the canaliculitis.

**Key words:** Canaliculitis, punctal plug

## Introduction

The Medennium SmartPlug (Medennium Inc., Irvine, CA) is an intra-canalicular plug made of thermodynamic hydrophobic acrylic polymer for treatment of dry eyes. Upon insertion into the lacrimal canaliculus, the SmartPlug swells and softens to conform to the shape of the puncta and proximal canaliculus. This theoretically offers more effective occlusion of the entrance of the drainage system, and reduces the chance of migration of the punctal plug.<sup>1</sup>

However, complications following SmartPlug insertion are still possible. These include epiphora, pyogenic granuloma formation, lacrimal canaliculitis, recurrent acute dacryocystitis and nasal lacrimal duct obstruction.<sup>2</sup> Various management options have been described, including topical and oral broad-spectrum antibiotics, plug removal through retrograde massage, probing and forceful irrigation of the lacrimal system, canaliculotomy and dacryocystorhinostomy with silicone intubation.<sup>3</sup> To our knowledge, there have been no reports of penicillin solution irrigation for management of canaliculitis following SmartPlug insertion. Here we report two cases of SmartPlug related chronic lacrimal canaliculitis that were successfully treated with penicillin solution irrigation without the need for punctoplasty or canaliculotomy.

---

### Correspondence:

Emmy Y. Li, Department of Ophthalmology & Visual Sciences, The Chinese University of Hong Kong, University Eye Center, 3/F, Hong Kong Eye Hospital, 147K, Argyle Street, Kowloon, Hong Kong.  
E-mail: emmyli@gmail.com

## Case Report

**Case 1:** A 36-year-old woman developed bilateral lower canaliculitis two months after insertion of SmartPlugs in bilateral lower punta for treatment of dry eyes after LASIK. The attempt to remove the SmartPlug with retrograde massage was only successful for the left eye. She experienced persistent right eye epiphora and yellowish discharge despite prolonged treatment with topical moxifloxacin 0.5%, fluorometholone and multiple courses of oral moxifloxacin for over a year. She was noted to have chronic right lower canaliculitis upon referral to our unit with prominent pouting of the punctum. The canaliculus was non-patent on syringing with regurgitation of pus and blood-stained discharge. The discharge was sent for culture for aerobic and anaerobic bacteria, atypical mycobacterium and fungus, which were all negative. The second attempt to remove the SmartPlug by retrograde massage was successful. After discussion with the patient, forceful irrigation of the right lower canaliculus with penicillin solution (Benzylpenicillin sodium 1,000,000 I.U in 10 ml water for injection) with large bore lacrimal canula was performed. Topical penicillin four times daily, and a course of oral amoxicillin were also prescribed. The patient showed significant improvement after first irrigation. Repeated penicillin irrigation was performed twice weekly and the canaliculitis resolved completely after three weeks of irrigation. The patient was followed up for six months and no recurrence was noted.

**Case 2:** Another 34-year-old woman developed lacrimal canaliculitis in both her right upper and lower lacrimal canaliculi six months after insertion of SmartPlugs, which failed to respond to topical and oral antibiotics. The SmartPlug in the lower canailculus was removed but the upper one could not be retrieved. She was referred to us one year after her initial presentation. On examination, the right upper punctum was swollen and inflamed (Fig. 1). With the experience of the previous patient, forceful irrigation with penicillin solution was performed, together with topical penicillin, four times daily. Weekly irrigations were performed and the chronic canaliculitis resolved completely after four weeks of irrigation. The patient defaulted after four months and no recurrence was noted up till the last follow-up (Fig. 2).

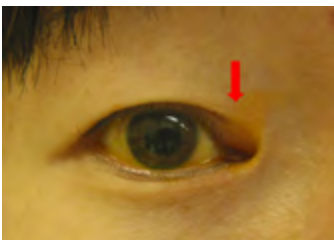


Fig. 1. The right upper punctum was inflamed with pouting.

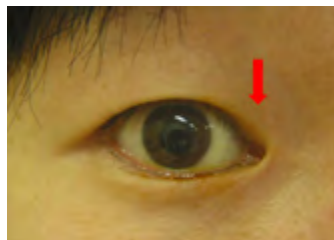


Fig. 2. After one month of repeated lacrimal irrigation with penicillin solution, together with topical and oral antibiotics, the right upper chronic canaliculitis resolved completely.

## Discussion

Canaliculitis associated with SmartPlugs insertion can be result of a foreign body reaction, superimposed infections or both. The presence of the intra-canalicular plug leads to stasis of tear flow which provides a perfect environment for formation of biofilm,<sup>4</sup> and the resulting infection is often resistant to topical treatment alone.

Theoretically, removal of the SmartPlug helps to hasten resolution of canaliculitis. However, it is not always feasible, as seen in our two patients. Retrograde massage to retrieve the plugs is especially difficult when the system is inflamed and swollen. Routine irrigation to flush out the SmartPlug may not be easy given its tight fit in the canaliculus. Dacryocystoscopy may be useful to for retrieval under direct visualization, yet it is not widely available.

Apart from removal of the SmartPlug, treatments with topical and oral antibiotics are also recommended. The SmartPlug Study Group suggested topical gatifloxacin 0.3%, topical moxifloxacin 0.5%, topical neomycin/polymyxin B, oral levofloxacin and oral penicillin with clavulenic acid.<sup>3</sup> However, the choices of antibiotics are purely empirical as there is limited published data that comment on the causative micro-organisms in canaliculitis associated with punctal plug insertion. Takemura et al. has successfully cultured *Actinomyces odontolyticus* from discharge collected from a patient with punctual-plug-related canaliculitis.<sup>5</sup>

With this background, we proposed forced benzylpenicillin solution irrigation to the lacrimal drainage system for the treatment of recalcitrant cases of SmartPlug-related canaliculitis. Forceful irrigation of penicillin with large bore lacrimal canula serves two purposes. Firstly, to dislodge the SmartPlug in the canaliculus. Secondly, to introduce a high concentration of penicillin in the lacrimal drainage system, which provides a targeted action towards any *Actinomyces* species, and also a direct bactericidal effect on the biofilm associated with the punctal plug. Although we do not have a definitive means to confirm that the Smartplugs have been flushed out by our irrigations, both patients showed significant improvement after the first irrigation and their canaliculitis eventually resolved without surgical intervention. No recurrence was observed in our series.

The report by the SmartPlug Study Group poses the concern that dislodgement of an inflamed plug into the lacrimal drainage system by irrigation may incite infection leading to dacryocystitis.<sup>3</sup> The use of penicillin solution as the irrigating agent may help to reduce such risk considering its bactericidal effect.

With the increasing use of the SmartPlug, we expect to see more SmartPlug-related complications. We hereby report a novel non-surgical treatment, lacrimal canalicular penicillin solution irrigation, for the management of lacrimal canaliculitis following insertion of SmartPlug before resorting to surgery.

## References

1. Burgess PI, Koay P, Clark P. SmartPlug versus silicone punctal plug therapy for dry eye: a prospective randomized trial. *Cornea* 2008;27(4):391-394.
2. Chen SX, Lee GA. SmartPlug in the management of severe dry eye syndrome. *Cornea* 2007;26(5):534-538.

3. SmartPlug Study Group. Management of complications after insertion of the SmartPlug punctal plug: a study of 28 patients. *Ophthalmology* 2006;113(10):1859.e1-6.
4. Sugita J, Yokoi N, Fullwood NJ, Quantock AJ, Takada Y, Nakamura Y, Kinoshita S. The detection of bacteria and bacterial biofilms in punctal plug holes. *Cornea* 2001;20(4):362-365.
5. Takemura M, Yokoi N, Nakamura Y, Komuro A, Sugita J, Kinoshita S. Canaliculitis caused by *Actinomyces* in a case of dry eye with punctal plug occlusion. *Nippon Ganka Gakkai Zasshi* 2002;106(7):416-419.