



APGC-2022 ABSTRACT BOOK

Supplement Volume 18 • Issue 2
• 2022 • ISSN: 1560-2133

KUGLER
PUBLICATIONS

Asian Journal of
OPHTHALMOLOGY
open access journal  est. 1998

JOIN THE ASIA-PACIFIC GLAUCOMA SOCIETY TODAY!

APGS membership is open to all glaucoma specialists, ophthalmologists, eye care health professionals, doctors with an interest in glaucoma/ophthalmology, researchers in glaucoma, and any incorporated association wishing to support the objectives of the Society.

MEMBERSHIPS STARTING FROM
AUD20

Membership benefits:



Free online access to the Journal of Glaucoma



A registration discount to attend the Asia-Pacific Glaucoma Congress while your membership remains valid



Access to APGS online education platform with recordings of APGS webinar series, APGS Masterclasses and surgical videos



APGS quarterly newsletter



Access to APGS Online Communities to network and advance a specific area of knowledge



Right to participate in the electoral process and the various committees of the APGS



Right to participate in the collaborative activities of the APGS with international affiliate societies and ophthalmic communities



Exciting and valuable professional networking opportunities



Eligibility for awards and recognition

Kick start your membership now! apglaucomasociety.org

Table of Contents

Introduction

Program overview

Welcome by the President

Asia Pacific Glaucoma Congress- Showcasing cutting edge glaucoma research

APGC oral abstract presentations

MSJOC oral abstract presentations

MSJOC OD oral abstract presentations

APGC Film Festival abstract presentations

APGC poster abstract presentations

MSJOC poster abstract presentations

Introduction

The 6th Asia-Pacific Glaucoma Congress in conjunction with the **12th Malaysian Society of Ophthalmology Annual Scientific Meeting (MSO-ASM)** and the **36th Malaysia-Singapore Joint Ophthalmic Congress (MSJOC)** will be held in a hybrid capacity for the first time in Kuala Lumpur, Malaysia, from **4 – 7 August 2022**.

The Asia-Pacific Glaucoma Congress brings together clinicians, scientists, students and other health practitioners from the Ophthalmology field with a focus on Glaucoma. The program provides a platform for delegates to collaborate, share experiences, knowledge and research results whilst also learning about world's best practice and the recent innovations helping us overcome challenges in clinical medicine and surgery.



Prof Ki Ho Park

President, Asia-Pacific Glaucoma Society



Dr Seng Kheong Fang

President-elect, Asia-Pacific Glaucoma Society
APGC 2022 Congress Chair



Prof Tanuj Dada

APGC 2022 Congress Scientific Program
Committee Chair



Prof Liza Sharmini Ahmad Tajudin

APGC 2022 Scientific Program Committee Co-
chair

Program overview

The Asia-Pacific Glaucoma Congress invited submissions for the official program over a broad range of themes including but not limited to basic research and pathogenesis, epidemiology and economic evaluation, glaucoma imaging and diagnosis, glaucoma surgery, laser treatment and medical treatment.

In 2022 abstracts were accepted on behalf of both the Asia-Pacific Glaucoma Congress and the Malaysia-Singapore Joint Ophthalmic Congress (MSJOC), resulting in over 360 abstract submissions being received.


All submissions were peer reviewed to ensure a fair and equitable process and ultimately 28 oral presentations, 3 on-demand oral presentations, 31 film festival presentations and 280 poster presentations were accepted in the official program.

We hope that you find value and ongoing education benefit from this publication of accepted oral, on-demand oral, film festival and poster presentation submissions.

Welcome by the President

Dear Colleagues and Friends,

We have been waiting for four years to have our biennial congress of the Asia Pacific Glaucoma Society (APGS), due to the unexpected outbreak of COVID-19 following the previous (2018) congress in Busan. Even though COVID-19 is still a problem, it is our great pleasure to be able to announce the 6th APGC (2022) in a hybrid on-line/off-line format in conjunction with the 12th Malaysian Society of Ophthalmology Annual Scientific Meeting (MSO-ASM) and the 36th Malaysia-Singapore Joint Ophthalmic Congress (MSJOC).



Glaucoma is one of the leading causes of blindness worldwide, and Asia accounts for 60% of the world's glaucoma cases. So, the role of the APGS is critical to prevention of blindness and maintenance of the quality of life of glaucoma patients. As it was impossible to have a physical congress during the COVID-19 pandemic period, the APGS organized a series of webinars and masterclasses to fulfill the educational needs of the membership. I believe that these online educational platforms have provided great opportunities to those with limited opportunities to travel or join physical meetings.

COVID-19 has changed not only our daily lifestyle but also the pattern of clinical eye care practice. Protecting both patients and healthcare providers became more important. Glaucoma specialists are at a higher risk of air-borne viral infective diseases given our need to measure intraocular pressure and look into the optic disc and anterior segment of the eye. In the context of the pandemic, telemedicine in glaucoma will surely become more common and popular, enabling optic nerve imaging, visual field testing, and intraocular pressure measurement at home or otherwise remotely. It may also make possible real-time communication between

patients and doctors. Artificial intelligence, moreover, may assist doctors' decision-making and help to keep patients better informed before consulting doctors. In APGC 2022's scientific program, you will be able to find topics related to telemedicine and the application of deep learning to glaucoma care. Even after the cessation of the COVID-19 pandemic, there is a high possibility that a new viral disease entity may affect us globally.

However, the importance of in-person meeting cannot be overemphasized. In the shared space of a physical congress, face-to-face and in-depth discussion is possible without the time restrictions of online meetings. We can catch our patients', friends' or colleagues' thoughts and emotions more clearly in-person than in communicating through a monitor and speaker. During the APGC welcome reception or group meeting, we may meet many people more efficiently and get to know each other more closely in addition to gaining new knowledge and information. We may have dinner and coffee or tea together with attendees, just as we do in our daily life. I hope that through this 6th APGC in Kuala Lumpur, we may go back to the time and place we enjoyed in previous congresses.

I thank the organizing committee members and scientific program committee members for their endeavors to make this hybrid APGC2022 congress a success. I also would like to express my gratitude to the executive members of the Malaysian Society of Ophthalmology for their time and effort to make this joint congress more fruitful.

I hope all of you will enjoy the 6th APGC and meet old and new friends.

Ki Ho Park

President of the APGS

Asia Pacific Glaucoma Congress- Showcasing cutting edge glaucoma research

The Asia Pacific Glaucoma Society (APGS) is one of the premier societies for clinician scientists with special interest in the field of glaucoma. This year the society is holding the 6th Asia-Pacific Glaucoma Congress (APGC) with a focus on promoting scientific research and collaboration. The

scientific programme includes lectures by top opinion leaders from across the globe with special symposia of the World Glaucoma Association, American Glaucoma Society, European Glaucoma Society and International Society of Glaucoma Surgery.



The scientific themes of the congress include both glaucoma basic and clinical sciences and broadly cover the following topics : Basic and laboratory science including glaucoma genetics; Epidemiology, quality of life and health economics; Glaucoma imaging and use of artificial intelligence ; medical and laser therapies for glaucoma and surgical modalities including conventional filtering surgery as well as recent advances in minimally invasive glaucoma surgery. There is also a video assisted skill transfer on glaucoma surgery and wet lab on new glaucoma surgical techniques.

The congress invites young researchers from across the globe to submit their original research in the form of structured abstracts. All eligible abstracts then undergo blinded peer review and scoring by at least two APGS committee members and then the scores are averaged. The scoring is based on the originality & clinical significance of the work, the level of evidence , use of appropriate and ethically sound methodology and conclusions based on data presented with statistical validity. We have received 300 scientific abstracts submissions out of

which top scoring 20 abstracts have been selected for oral presentations and 217 as poster presentations. APGS scientific committee will judge the oral presentations and select the best presentations for APGS awards.

In addition, we have invited abstracts for surgical videos to promote skill transfer and to encourage innovations in glaucoma surgery. These are again peer reviewed and selected for viewing during the congress film festival.

This special issue of the Asian Journal of Ophthalmology includes the scientific abstracts included in the congress and promises to be an exciting read, generating new ideas and innovations for alleviating the glaucoma disease burden worldwide. I congratulate the Editors for this initiative and Kugler publications for bringing out this valuable edition in print.

Tanuj Dada MD

APGC 2022 Scientific Programme Committee Chair

APGC oral abstract presentations

Effect of Trans-resveratrol on NMDA Induced Retinal Injury: Involvement of AA1R

Aiman A¹, Abdul Nasir N¹, Razali N¹, Nikolayevich Iezhitsa I², Agarwal R²

¹Faculty Of Medicine , Uitm Sungai Buloh, Sungai Buloh, Malaysia, ²School of Medicine, International Medical University, Kuala Lumpur, Malaysia

Introduction

Excitotoxicity through N-methyl-d-aspartate receptors (NMDARs) is associated with retinal ganglion cells death RGC) in glaucoma¹. *Trans-resveratrol* (TR) that is shown to have agonistic action to adenosine A1 receptors² (AA1R), may counteracts the effect of NMDA toxicity and prevent RGC death. Hence, this study investigated if the effects of TR against NMDA-induced retinal injury involve AA1R in rats.

Methods

Thirty-two Sprague-Dawley rats were divided into 4 groups that received bilateral intravitreal injection of PBS, NMDA (160 nmol), NMDA (160 nmol)+TR (4 nmol), and NMDA (160 nmol)+TR (4nmol)+DPCPX (AA1R antagonist, 8 nmol). Seven days post-injection, rats were euthanized, and retinae were isolated for haematoxylin and eosin staining whilst optic nerves were isolated for toluidine blue staining.

Results

Retinal morphometric measurements showed significantly lower fractional ganglion cell layer (GCL) thickness within inner retina (IR), lower numeric retinal cell density within GCL and IR and the linear retinal cell density within GCL in NMDA group compared to PBS- treated groups ($p < 0.05$) but the same in TR-treated group were comparable to that in PBS-treated group. The effects of TR were not evident in the group receiving DPCPX with TR . In accordance, optic nerve morphology in

TR-treated groups was well preserved compared to NMDA group ($p<0.05$). In the group receiving DPCPX with TR, optic nerve degeneration was as severe as in NMDA group.

Conclusion

TR protects retinal and optic nerve morphology against NMDA-induced excitotoxicity through stimulation of the AA1R in rats

References

1. Markus H. Kuehn, John H. Fingert, Young H. Kwon (2005), Retinal Ganglion Cell Death in Glaucoma: Mechanisms and Neuroprotective Strategies, *Ophthalmol Clin N Am* 18 (383 – 395)
2. Noor Azliza Wani Abd. Aziz, Igor Iezhitsa, Renu Agarwal, Roqiah Fatmawati Abdul Kadir, Azian Abd. Latiff & Nafeeza Mohd Ismail (2020): Neuroprotection by trans-resveratrol against collagenase-induced neurological and neurobehavioural deficits in rats involves adenosine A1 receptors, *Neurological Research*

Figures

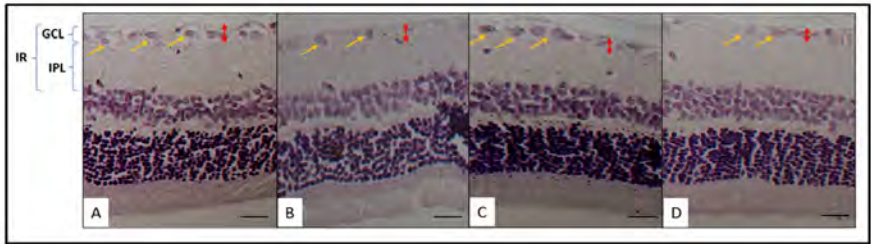


Figure 1: Representative microphotographs of rat retinal sections stained with H&E: (A) Vehicle (B) NMDA 160 nmol group, (C) TR ; (D) TR + DPCPX respectively. Scale bar represents 100 μm. Ganglion cell layer (GCL); Inner plexiform layer (IPL); Inner retina (IR)

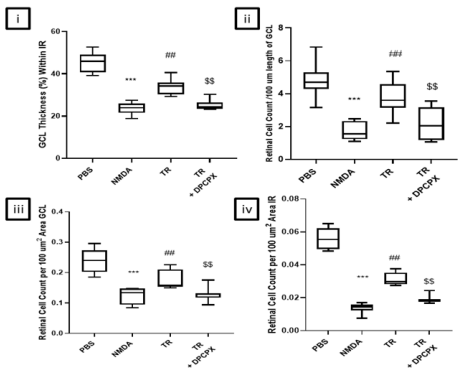


Figure 2: Quantitative estimation of morphological changes in inner retina showing effect of TR against NMDA-induced retinal damage. (i) GCL Thickness within IR; (ii)retinal cell count per 100 μm length of GCL, (iii) retinal cell count per 100 μm² area GCL; (iv) retinal cell count per 100 μm² area of IR.* P<0.001 vs PBS, ^{##}P<0.01 vs NMDA, ^{##}P<0.01 vs TR (N=8). Bars represent mean ± SD; all data were analysed using one-way analysis of variance followed by Tukey's post-hoc analysis**

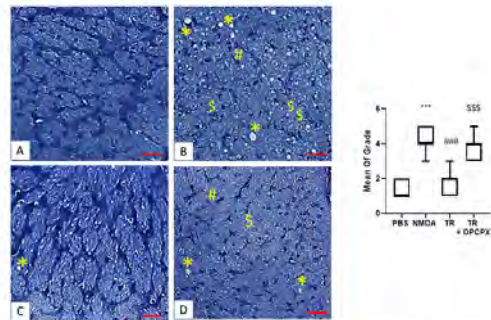


Figure 3: Representative microphotographs of optic nerve semi-thin sections stained with toluidine blue; (A): The PBS treated group ;(B): Group treated with NMDA 160 nmol; (C): TR 4 nmol; (D) TR+ DPCPX respectively. Yellow asterisk: vacuolation (*); nuclear clearing (S);early mild lesions with axonal swelling and appearance of glial cell ;axonal swelling and degeneration axons across optic nerve(#).The bar show mean of grade of optic nerve (Scale bar represents 50 μ m)

Prospective Multicentre Trial of iStent infinite Trabecular Micro-Bypass in Glaucoma Uncontrolled by Prior Surgical or Medical Therapy

[Ang R¹](#)

¹Asian Eye Institute, Makati City, Philippines

Introduction

The iStent infinite Trabecular Micro-Bypass System (Glaukos Corp.) aims to apply the micro-invasive safety profile of trabecular micro-bypass stenting to achieve effective standalone IOP lowering in OAG patients inadequately controlled on maximally tolerated medical therapy (MTMT) or by prior surgical procedures. iStent infinite consists of three micro-scale wide-flange (model G2-W) stents that are designed to be implanted ab interno in three separate areas of the trabecular meshwork. A prospective, multicentre, single-arm trial was conducted to evaluate safety and effectiveness of the iStent infinite Trabecular Micro-Bypass System in open-angle glaucoma (OAG) uncontrolled by prior surgical or medical therapy.

Methods

Surgery with iStent infinite (3 G2-W stents) was performed as a standalone procedure in eyes with OAG uncontrolled by prior incisional or cilioabative surgeries or on maximally-tolerated medical therapy (MTMT). Effectiveness endpoints were proportion of eyes achieving $\geq 20\%$ mean diurnal intraocular pressure (MDIOP) reduction from Baseline to Month 12 on the same or fewer glaucoma medication classes (responder endpoint), and mean change in MDIOP from Baseline to Month 12.

Results

Seventy-two eyes of 72 patients (mean age 71.9 years) with preoperative mean medicated MDIOP of 23.4 ± 2.8 mmHg on 3.1 ± 0.9 mean medication classes were enrolled, including 61 eyes having failed prior surgery (FS subgroup) and 11 eyes uncontrolled on MTMT. 76.1% met the responder endpoint, with mean change (SE) in MDIOP of $-5.9(0.6)$ mmHg. 53.0% of eyes without surgical interventions/other

events on the same or fewer medication classes achieved $\geq 30\%$ MDIOP reduction at Month 12. No explants, infection, or device-related interventions or hypotony were reported.

Conclusion

iStent Infinite standalone surgery achieved robust, clinically significant IOP reduction and demonstrated favorable safety in patients with OAG uncontrolled by prior therapy

Complications and Post-operative Interventions after XEN45 Gel Stent Implantation in the Treatment of Open Angle Glaucoma – A Meta Analysis

Ang B^{1,2}, [Betzler B](#)³, Lim S⁴

¹Department of Ophthalmology, Tan Tock Seng Hospital, , Singapore, ²Department of Ophthalmology, Woodlands Health Campus, Singapore, ³Yong Loo Lin School of Medicine, National University of Singapore, Singapore, ⁴Army Medical Services, Singapore Armed Forces, Singapore

Introduction

The XEN45 Gel Stent is a sub-conjunctival bleb-forming minimally invasive glaucoma surgery (MIGS) device that has demonstrated promising safety and efficacy. This meta-analysis quantitatively evaluates complications and interventions reported after XEN45 Gel Stent implantation in the treatment of open angle glaucoma (OAG).

Methods

Pilot, cohort, observational studies, and randomized controlled trials that included at least 10 patients undergoing XEN45 Gel Stent implantation, with or without concomitant phacoemulsification, for the treatment of OAG were deemed to be eligible for inclusion. 152 studies were identified on initial literature search, from which 33 studies were included in final analysis. Data was pooled using random-effects model. Meta-analysis of proportions was performed using the meta routine in R v3.2.1.

Results

Numerical hypotony was the most common post-operative complication, involving 20% of patients (95%CI: 10-31%). Post-operative hyphema occurred in 14% (95%CI: 7-22%). Postoperative transient IOP spike occurred in 13% (95%CI: 4-27%). Stent exposure occurred in 3% (95%CI: 1-5%). Stent migration occurred in 1% (95%CI: 0-3%). XEN45 revision or a second XEN45 implantation was performed in 5% of patients (95%CI: 3-7%). Stent relocation was performed in 4% (95%CI: 1-9%).

A second glaucoma procedure was performed in 12% (95%CI: 8-18%). 26% underwent one bleb needling (95%CI: 17-36%), 13% underwent two needlings (95%CI: 5-24%) while 4% underwent three needlings (95%CI: 2-6%). 35% of patients (95%CI: 29-40%) required at least 1 needling up to the end of the study follow-up period. The average rate of needling per patient was 0.42 (95%CI: 0.22-0.64).

Conclusion

XEN45 Gel Stent implantation is safe in the treatment of OAG, with a low incidence of complications. However, more than a third of eyes required at least one post-operative bleb needling procedure.

Incidence and factors associated with brimonidine allergy

Chansangpetch S^{1,2}, Pongpisitkul P^{1,2}, Tipparut K², Ratanawongphaibul K^{1,2}, Ittipanichpong R^{1,2}, Manassakorn A^{1,2}, Tantisevi V^{1,2}, Rojanapongpun P^{1,2}

¹Glaucoma Research Unit, Department of Ophthalmology, Chulalongkorn University and King Chulalongkorn Memorial Hospital, Thai Red Cross Society, Thailand, ²Faculty of Medicine, Chulalongkorn University, Thailand

Introduction

Brimonidine was discovered to have a high rate of ocular allergy. Several studies reported risk factors associated with brimonidine allergy. The objective of this study was to evaluate the incidence of brimonidine allergy and factors associated with brimonidine allergy. The clinical characteristics and management of brimonidine allergy were also described.

Methods

A retrospective chart review of 2,850 patients who used brimonidine during 2019 to 2020 was conducted. The subjects were divided into 2 groups including brimonidine allergic and non-allergic group. Demographic and clinical variables were collected and compared between the 2 groups.

Results

Incidence of brimonidine allergy was 5.5% (157 of 2,850 patients). The onset of allergic signs and symptoms showed interquartile range of 15 to 72 weeks with a median of 32 weeks. Conditional multivariable logistic regression analysis showed that brimonidine allergy was associated with concurrent topical steroid use (OR=0.18, 95%CI 0.38-0.87, $p=0.033$), concurrent artificial tear use (OR=3.07, 95%CI 1.36-6.93, $p=0.007$), concurrent Tafluprost use (OR=3.63, 95%CI 1.04-12.63, $p=0.043$) and the duration of brimonidine use (OR=0.99, 95%CI 0.99-0.98, $p<0.001$). The patients mostly experienced red eye (73.8%) (and itching) (50.0%). Discontinuation of brimonidine was done mostly (98.7%). Their symptoms and signs improved after a median of 5.5 weeks of treatment.

Conclusion

Approximately 5.5% of brimonidine users developed brimonidine allergy, which typically manifested at 32 weeks. Concurrent artificial tear use, and concurrent Tafluprost use increased the risk of brimonidine allergy, whereas concomitant use of topical steroid lowered the risk. The chance of getting brimonidine allergy decreased with time.

Caregiver burden in Childhood Glaucoma

Chauhan N¹, Verma R², Yadav N¹, Sharma V¹, Dada T¹

¹R.P.CENTRE AIIMS DELHI, Delhi, INDIA, ²Department of Psychiatry AIIMS DELHI, DELHI, INDIA

Introduction

Childhood glaucoma accounts for 4.2-5% for childhood blindness (1,2). Caregivers are often overshadowed by the meticulous and chronic care required by childhood glaucoma patients. Caregiver burden is defined as the strain borne by a person who cares for a chronically ill, disabled or elderly person (3).

Methods

Thirty primary caregivers of children diagnosed with Primary Congenital Glaucoma (PCG) were evaluated in this study. The burden experienced by the primary caregivers was assessed using caregiver burden self-assessment questionnaire, Zarit burden Interview comprising of 22 questions. The magnitude of aggregate burden was graded as mild, moderate, or severe depending on the cumulative score. The participants were evaluated for symptoms of depression using Patient Health Questionnaire-9 (PHQ-9) consisting of 9 items.

Results

The mean age of the study participants was 30.96 years (+/- 12.71 years) (24 females, 6 males). Eleven participants experienced mild to moderate aggregate burden (36.6%), seventeen participants felt moderate to severe aggregate burden (56.6 %) and 2 (6.6%) had severe aggregate burden. Fourteen (46.6%) participants were noted to have mild depression, twelve (40%) had moderate depression and 4 (13.3%) participants had severe depression.

Conclusion

More than half of the primary caregivers of children suffering from PCG experience at least a moderate amount of physical, social and psychological burden as well as depression. Psychological counselling and mind body therapies to alleviate burden may be recommended for such population.

References

1. Dandona L, Williams JD, Williams BC, Rao GN. Population-based assessment of childhood blindness in southern India. *Arch Ophthalmol* 1998; 116: 545-6.
2. Gilbert CE, Rahi JS, Quinn GE. Visual impairment and blindness in children. In: Johnson GJ, Minassian DC, Weale RA, West SK, eds. *The Epidemiology of Eye Disease*, 2nd ed. London: Hodder Arnold; 2003: 260-86.
3. Chaudhuri KR, Titova N. Societal Burden and Persisting Unmet Needs of Parkinson's Disease. *Eur Neur Rev*. 2019;14(1):28–35.

Combined Ab-interno Canaloplasty (ABiC) in open and angle closure glaucoma: 12 month outcomes

Cheng J¹

¹University Of New South Wales, Sydney, Australia, ²Liverpool Hospital, Liverpool, Australia, ³Sydney Eye Hospital, Sydney, Australia, ⁴University of Western Sydney, Liverpool, Australia

Introduction

Ab-interno Canaloplasty (ABiC) is a minimally invasive glaucoma surgery using an iTrack(TM) microcatheter to viscodilate Schlem's canal and improve physiological outflow. This prospective study assesses the safety and efficacy of combined phacoemulsification with ABiC in both open and closed angle glaucoma.

Methods

Prospective case series of 54 eyes of 44 patients from who underwent combined phacoemulsification with ABiC by a single surgeon. Outcome measures included intraocular pressure (IOP), visual acuity (VA), glaucoma medications and adverse outcomes.

Results

Of the 54 eyes, 38 had primary open angle glaucoma (POAG) (70.3%), 14 had primary angle closure glaucoma (PACG) (25.9%) and 2 had pseudoexfoliation glaucoma (3.7%). Mean IOP reduced from 17.7+/-4.5mmHg baseline to 12.7+/-3.8mmHg at 6 months (n=44 p<0.05) and 14.3+/-5.5mmHg at 12 months (n=28 p<0.05) follow up, mean number of medications reduced from 0.93+/-1.2 (n=44 p<0.05) at 6 months and 2.2+/-1.1 to 0.9+/-1.3 (n=28 p<0.05) at 12 months follow up. Mean VA improved from 0.62 to 0.07 (n=28 p<0.05) and 61% (n=28) of eyes were medication free at 12 months after surgery. The procedure had good IOP reductions for both POAG (3.6+/-1.0mmHg) and PACG (5.14+/-0.4mmHg) eyes. 21 eyes (38.9%) experienced hyphema in the immediate post operative period with

gross hyphema (>10% anterior chamber fill) in 4 eyes, that resolved within 1 month.

Conclusion

ABiC combined with phacoemulsification resulted in significant and safe, IOP and medication reductions with most eyes medication free at 12 months for eyes with both POAG and PACG.

Combined phaco-emulsification and trabecular micro-bypass stent (iStent inject) for management of cataract and glaucoma: prospective longitudinal outcomes from the Fight Glaucoma Blindness Registry

Clement C, Danks J, Howes F, Lawlor M, Lee V, Nguyen V

Purpose

To analyse the efficacy and safety of trabecular micro-bypass stents (iStent *inject*[®]) with phacoemulsification derived from the Fight Glaucoma Blindness Registry (FGB).

Materials and Methods

This point-of-care study of iStent *inject* implantation with phacoemulsification was conducted using data extracted from the FGB. Eyes with cataract and mild to advanced glaucoma. Study assessments included intraocular pressure (IOP); number of ocular hypotensive medications and adverse events including secondary surgeries.

Results

A total of 1650 eyes underwent surgery and were assessed at 6 months (n=1118), 12 months (n=969), 24 months (n=558) and 36-months (n=239). At 6 months IOP had reduced by 16.7% ($p<0.001$) to 13.5mmHg with the comparable reduction at 36 months being 7.1% ($p=0.012$). Medication reduction at 6-months was 0.8 and this was persistent out to 36 months. Higher baseline IOP was associated with an increased likelihood of significant IOP lowering Adverse events were few with the most frequent item “subsequent procedure” occurring in 9.7% of eyes.

Conclusion

This is the largest study to date on the efficacy and safety of trabecular micro-bypass stents (iStent *inject*[®]) with phacoemulsification. It demonstrates that in a large heterogeneous cohort at point-of-care, this treatment is associated with both IOP and medication reduction up to 36 months after surgery. Results were

favourable across different glaucoma subtypes (including POAG, ACG, NTG, OHT) and severities. These results underscore the real-world safety, efficacy, and utility of iStent *inject* implantation as a treatment modality.

Comparative study of 2-year outcomes for Hydrus or iStent inject microinvasive glaucoma surgery implants with cataract surgery

Holmes D², Clement C¹, Nguyen V¹, Healey P¹, Lim R¹, White A¹, Yuen J³, Lawlor M¹

¹University of Sydney, Sydney, Australia, ²Royal Victorian Eye and Ear Hospital, Melbourne, Australia, ³Applecross Eye Clinic, Ardross, Australia

Introduction

The iStent inject and the Hydrus Microstent have been shown to provide additional IOP lowering over that provided by cataract surgery alone. This study reports the real-world outcomes of combined phacoemulsification and either iStent inject or Hydrus Microstent for reduction of IOP and medication use after 24 months.

Methods

Analysis of data from the Fight Glaucoma Blindness international registry. Anonymized data from 344 eyes with mild to moderate open angle glaucoma, normal tension glaucoma or ocular hypertension that underwent phacoemulsification combined with either iStent inject (224) or Hydrus Microstent (120) were included. The primary endpoint was a comparison of mean IOP at 24 months.

Results

At 24 months, there was no significant difference in IOP reduction between the two groups, consistent across all analyses. The matched cohort showed iStent inject achieved 3.1mmHg reduction and Hydrus a 2.3mmHg reduction ($p=0.530$) and a mean medication reduction of 1.0 for iStent inject vs 0.5 for Hydrus ($p=0.081$). 5.4% of eyes in the iStent inject group and 7.5% of eyes in the Hydrus group required subsequent procedures to improve IOP control within 24 months. Complications were rare with no significant differences between the groups.

Conclusion

24-month outcomes showed sustained IOP reduction with a good safety profile for both groups. There was no significant difference in IOP outcomes between the groups. There may be a small additional reduction in glaucoma medication usage following cataract surgery with iStent inject compared to Hydrus

Comparison of Extended Depth of Focus and Monofocal Intraocular Lenses in Glaucomatous Eyes

Kerr N^{1,2}, Lim S²

¹Centre For Eye Research Australia, Melbourne, Australia, ²Eye Surgery Associates, Melbourne, Australia

Introduction

To evaluate and compare the visual outcomes, spectacle independence, and patient satisfaction of bilaterally implanted extended depth of focus (EDOF) or monofocal intraocular lenses (IOLs) after cataract surgery in patients with glaucoma.

Methods

In this retrospective, non-randomised, interventional cohort study, patients with glaucoma undergoing cataract surgery received bilateral implantation of either EDOF (AcrySof IQ Vivity; Alcon) or monofocal (Clareon/SN6ATx/SN60WF; Alcon) IOLs. The primary outcome was binocular and monocular uncorrected distance (UDVA), intermediate (UIVA), and near (UNVA) visual acuity. The secondary outcomes were spectacle independence, patient satisfaction, and photic phenomena.

Results

A total of 66 eyes from 33 patients, including 32 eyes in the EDOF group and 34 eyes in the monofocal group, were included in the study. There was no difference in uncorrected and corrected distance visual acuity outcomes between the groups ($P > 0.05$), however both uncorrected intermediate visual acuity and uncorrected near visual acuity outcomes were significantly better in the EDOF group ($P < 0.01$). Spectacle independence was high in the EDOF group with only 11.1% always requiring reading spectacles compared to 71.9% in the monofocal group ($P < 0.001$). Patient satisfaction scores were significantly higher in the EDOF group with 100% very satisfied with their unaided intermediate vision and 77.8% very satisfied

with their unaided near vision compared to 50% and 12.5% in the monofocal group respectively ($P = 0.01$). There were no differences in self-reported photic phenomena, which were infrequent in both groups ($P > 0.05$).

Conclusion

Bilaterally implanted EDOF IOLs provide excellent distance vision and better intermediate and near vision compared to monofocal IOLs in patients with glaucoma. Spectacle independence and patient satisfaction is significantly higher in patients who receive an EDOF IOL. Photic phenomena are rare and seldom bothersome.

Reduced intradisc vessel density is associated with optic disc hemorrhage in eyes with primary open-angle glaucoma

Kim K¹, Sung K¹, Lee J¹, Shin J¹, Kim J²

¹Asan Medical Center, University of Ulsan, College of Medicine, Seoul, South Korea,

²Kangbuk Samsung Hospital, Sungkyunkwan University School of Medicine, Seoul, South Korea

Introduction

We sought to investigate the association between optic nerve head (ONH)/choroidal microvasculature perfusion and optic disc hemorrhage (ODH) in eyes with primary open-angle glaucoma (POAG) using swept-source optical coherence tomography angiography (SS-OCTA).

Methods

This retrospective study included 266 POAG eyes consists of 59 with a single instance of ODH, 40 with a history of recurrent ODH, and 167 eyes without ODH. Intradisc vessel density (VD), parapapillary choroidal VD, optic disc microvascular dropout (MvD), and choroidal microvascular dropout (CMvD), were evaluated on a 3 x 3 mm SS-OCTA image of ONH and compared between eyes with and without ODH. Univariate and multivariate logistic regression analyses were performed to investigate factors associated with ODH.

Results

The prevalence of CMvD, optic disc MvD, and β -peripapillary atrophy were not different among the no ODH, single ODH, and recurrent ODH groups. Eyes with ODH had lower intradisc VDs than those without ODH ($P = 0.021$), but no difference was found in intradisc VDs between the single and recurrent ODH groups ($P = 0.977$). Better VF MD at baseline (odds ratio [OR], 1.150; 95% confidence interval [CI], 1.055–1.254; $P = 0.002$) and lower intradisc VD (OR, 0.863; 95% CI, 0.812–0.918; $P < 0.001$) were associated with ODH occurrence.

Conclusion

Among POAG eyes, those with ODH had lower intradisc VDs than those without ODH. POAG eyes in an earlier disease stage or those with lower intradisc VDs should be monitored for the possibility of ODH occurrence.

PreserFlo™ Microshunt: Safety and Efficacy Outcomes in Uveitic Glaucoma

Au L¹, [Kirk J](#)¹

¹Manchester Royal Eye Hospital, United Kingdom

Introduction

We report efficacy and safety outcomes of the PreserFlo™ microshunt in uveitic glaucoma.

Methods

Retrospective case series of eyes with medically-uncontrolled glaucoma secondary to uveitis, treated using PreserFlo microshunt implantation in a single centre (Manchester Royal Eye Hospital) since April 2019, with more than 6 months follow-up.

Primary outcome was complete success at 1 year, with failure defined as intraocular pressure (IOP) above 21mm Hg or <20% reduced; IOP 5 or lower with decreased vision at 2 consecutive visits; reoperation; or loss of light perception. Secondary outcomes included: IOP, medication number, visual acuity, complications, interventions. Pre- and postoperative data were collected.

Results

35 eyes of 27 patients with median age 53 (range: 21 to 84) and mean follow-up of 21.3 months (range: 6 to 35 months) were identified. Preoperatively, 83.8% of eyes received 3 or more glaucoma drops, 45.9% received oral acetazolamide. Mean preoperative IOP was 29.9 (\pm SD 9.6) on an average of 3.16 (\pm SD 0.81) drops. Mean postoperative IOP at last review was 11.4mm Hg on an average 0.11 (\pm SD 0.40) drops: a 97% reduction in glaucoma medication.

72.4% eyes achieved complete success at 12 months postoperatively. 5-fluorouracil bleb needling was performed in 3 eyes (8.6%). Complications included: bleb leak (2.8%; n=1); hyphema (2.8%; n=1); iris-microshunt occlusion (2.8%, n=1); clinical hypotony (cystoid macular oedema; 2.8%; n=1). 9 eyes (25.7%) had

transient numerical hypotony (IOP ≤ 5 mm Hg) without sequelae. 4 eyes (11.4%) failed, requiring revision or tube drainage surgery.

Conclusions

PreserFlo™ microshunt is an effective, safe surgical treatment for uveitic glaucoma, significantly reducing IOP and medication requirement. Complication rates and incidence of numerical hypotony were comparable to recently-published multicentre PreserFlo studies. Clinical hypotony incidence was remarkably low, and lower than in series of other glaucoma procedures published by our centre.

Comparison of Short-Term Clinical Outcome between Ahmed Valve Implant versus Non-valved Paul implant in Malaysian Glaucoma patients

Loh S^{1,2}, Wang M¹, Ch'ng T¹, Ng H¹, Wan Ab Kadir A², Khaliddin N²

¹Department of Ophthalmology, Hospital Raja Permaisuri Bainun, Ipoh, Malaysia,

²University Malaya Eye Research Centre, Department of Ophthalmology, Pusat Perubatan University Malaya, Kuala Lumpur, Malaysia

Introduction

Ahmed Valve Implant (AVI) is a valved glaucoma drainage device (GDD) that frequently used in uncontrolled glaucoma especially when a low intraocular pressure (IOP) is needed in immediate post-operative period. Non-valved GDD has been documented to be more successful in long-term compared to AVI, however, to achieve immediate target of post-operative IOP reduction could be a challenge with higher risk of sight-threatening complication. The objective of our study was to compare the immediate and short-term clinical outcome between AVI and Paul Glaucoma Implant (PGI), a relatively novel non-valved GDD in our glaucoma patients.

Methods

Retrospective study.

Results

A total of 21 eyes with AVI and 15 eyes with PGI were recruited with median age of 59.5-year-old (IQR:20.25). Pre-operative intraocular pressure (IOP) in AVI and PGI was 31.3 ± 10.2 mmHg and 31.2 ± 5.3 mmHg respectively ($p=0.250$). Percentage of IOP reduction was similar between AVI and PGI at post-operative one-day (53.6% vs 57.4%) ($p=0.150$) and post-operative one-month (38.7% vs 36.5%) ($p=0.470$). Pre-operative number of glaucoma medications was 4.7 ± 0.6 (AVI) and 4.6 ± 0.4 (PGI) ($p=0.370$) and reduced to 1.3 ± 0.2 (AVI) and 0.5 ± 0.2 (PGI) ($p=0.009$) at post-operative one-month. In term of complication, AVI recorded two eyes with

hyphema, two eyes with hypotony and one eyes with retinal detachment, whereas PGI group recorded one eye with hyphema.

Conclusion

Non-valved PGI had similar efficacy with valved AVI in reduction of IOP and number of medications in immediate and short-term post-operative period. PGI group showed lower complication rate in our study.

References

1. Tan MC, HY CC, Aquino MC, Sng CC, Lim DK, Loon SC. Two Year Outcomes of the Paul Glaucoma Implant for Treatment of Glaucoma. *Journal of Glaucoma*. 2022 Feb 18.
2. José P, Barão RC, Teixeira FJ, Marques RE, Peschiera R, Barata A, Pinto LA. One-Year Efficacy and Safety of the PAUL Glaucoma Implant Using a Standardized Surgical Protocol. *Journal of Glaucoma*. 2022 Mar 1;31(3):201-5.
3. Vallabh NA, Mason F, Yu JT, Yau K, Fenerty CH, Mercieca K, Spencer AF, Au L. Surgical technique, perioperative management and early outcome data of the PAUL® glaucoma drainage device. *Eye*. 2021 Sep 20;1-6.
4. Posarelli C, Toro MD, Rejdak R, Żarnowski T, Pożarowska D, Longo A, Miccoli M, Nardi M, Figus M. Safety and efficacy of second ahmed valve implant in refractory glaucoma. *Journal of Clinical Medicine*. 2020 Jul;9(7):2039.
5. Dawson EF, Rosenberg NC, Meyer AM, Culpepper BE, Bolch CA, Wilson MK, Nguyen PT, Rodgers CD, Smith RJ, Blake CR, Sherwood MB. Comparison of outcomes of glaucoma drainage implant surgery with or without prior failed trabeculectomy. *Journal of Glaucoma*. 2021 Jul 10;30(7):585-95.

Intraocular Pressure Control After Trabeculectomy with Intraoperative Subtenon Injection of Mitomycin – C

Mahar P¹

¹Aga Khan University Hospital, Karachi, Pakistan

Purpose

To evaluate the efficacy of trabeculectomy with intraoperative subtenon injection of Mitomycin C (MMC) in terms of control of Intraocular pressure post-operatively.

Study design

Retrospective, observational.

Methods

A total of 49 patient's medical records that underwent trabeculectomy with intraoperative subtenon injection of MMC with diagnosis of Primary Open Angle Glaucoma (POAG) from January 2017 to December 2018 were evaluated to see the post-operative outcomes in terms of control of Intraocular Pressure (IOP) with 12 months follow-up. The medical records were retrieved using the hospital information system. Age, gender, pre-operative IOP, Best Corrected Visual Acuity (BCVA), co-morbid, previous surgery, Central Corneal Thickness (CCT), fundus findings, number of glaucoma medications and postoperative complications were obtained by using a proforma.

Results

Total 72 eyes of 49 patient records were evaluated to see post-operative outcomes at three; six and twelve months follow up. The mean IOP preoperatively was 24.68 ± 13.66 mm Hg with maximum anti-glaucoma treatment. After the surgery at 3 months follow-up, the mean IOP was 13.69 ± 6.68 mmHg, which was slightly changed at six and twelve months as 12.68 ± 4.04 and 13.33 ± 4.8 mmHg respectively (p-value 0.001). Preoperatively mean CCT was 529.81 ± 28.75 and at 12

months follow-up after surgery was 530.45 ± 29.43 with p-value 0.245. BCVA outcomes were seen at each follow-up and results were found to be statistically significant (p-value ≤ 0.05).

Conclusion

Twelve months follow-up of trabeculectomy show that intraoperative subtenon injection of MMC is effective in terms of control of IOP postoperatively with minimal complications in patients with POAG. Accepted February 09, 2021

Keywords

Mitomycin C, Trabeculectomy, Intraocular pressure, Glaucoma

Assessment of the Anterior Chamber Angle and Central Biometric Parameters with Hyperparallel Optical Coherence Tomography

Natalia Porporato^{1,2}, Binyao Tan^{1,3,4}, Yu Q. Chang⁵, Tin A. Tun^{1,2}, Shamira Perera^{1,2}, Rahat Husain^{1,2}, Rehena Sultana², Jonathan Crowston^{1,2}, Tin Aung^{1,2,6}, Leopold Schemetterer^{1,2,3,4,7,8,9}

¹Singapore Eye Research Institute, Singapore National Eye Centre, ²DUKE-NUS Medical School, Singapore, ³School of Chemical and Biomedical Engineering, Nanyang Technological University, Singapore, ⁴SERI-NTU Advanced Ocular Engineering (STANCE), Singapore, Singapore, ⁵Royal College of Surgeons in Ireland, Dublin, Ireland, ⁶Yong Loo Lin School of Medicine, National University of Singapore, ⁷Department of Clinical Pharmacology, Medical University of Vienna, Austria, ⁸Center for Medical Physics and Biomedical Engineering, Medical University of Vienna, Austria, ⁹Institute of Molecular and Clinical Ophthalmology, Basel, Switzerland

Introduction

The new and ultrafast hyperparallel optical coherence tomography (HP-OCT, Cylite Optics, Melbourne, Australia) can image the 360° of the anterior chamber angle (ACA) and measure central biometric parameters, such as anterior chamber depth (ACD), lens thickness (LT) and axial length (AL). The aim of this study was to evaluate its repeatability and agreement in the qualitative assessment of the ACA compared to swept-source OCT (SS-OCT, CASIA SS-1000, Tomey Corporation, Nagoya, Japan) and gonioscopy, and in the measurement of central biometric parameters compared to IOL Master (CarlZeiss Meditec AG, Jena, Germany).

Methods

Cross-sectional study with consecutive recruitment from a single tertiary eye hospital (Singapore National Eye Hospital). Each subject underwent IOL Master, SS-OCT, HP-OCT and gonioscopy on the same day prior to pupillary dilation in a dark room (0 lux). Angle closure in anterior segment OCT imaging was defined as

the presence of iridotrabecular contact above the scleral spur (Figure 1). A gonioscopic quadrant closed was defined as the non-visibility of the posterior trabecular meshwork.

Results

77 subjects were analysed (62 open and 15 closed angles). The localization of the scleral spur and qualitative assessment of the ACA was possible in 94.8% (73/77). Two scans did not yield AL measurements (IOL Master AL were 29.15 and 31.04mm). The test-re test agreement of the qualitative ACA assessment was excellent (AC1 0.95 for the temporal angle and 1 for the nasal). There were no significant measurement differences between the two sets of HP-OCT scans for any of the central biometric parameters. The agreement between HP-OCT and SS-OCT was very good (AC1 >0.8) while between HP-OCT and gonioscopy was good (>0.6-<0.8, Table 1). Lens thickness showed a significant mean difference of 0.07 mm when measured by HP-OCT in comparison to IOL Master ($p < 0.0001$, Figure 2).

Conclusion

HP-OCT is a reliable tool for ACA qualitative assessment, showing a good agreement with previous technologies (SS-OCT) and current gold standard (gonioscopy). However, LT can be underestimated when compared to IOL Master.

Figures and tables

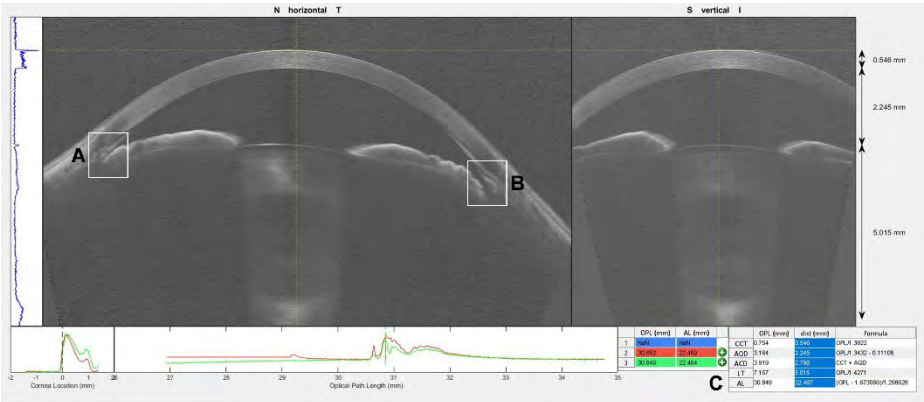


Figure 1. HP-OCT output. A) Closed angle B) Open angle C) Central biometric parameters.

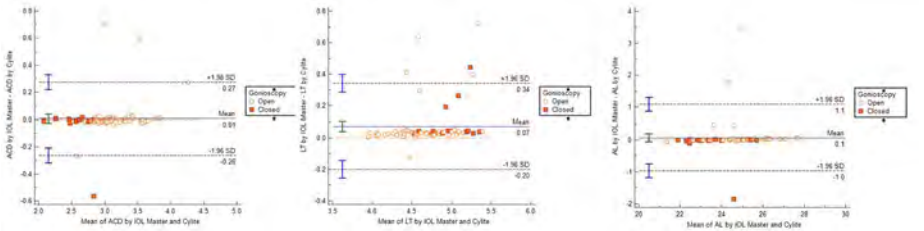


Figure 2. Bland-Altman plots HP-OCT vs IOL Master.

Table 1. Interdevice agreement

HP-OCT	SS-OCT		Gonioscopy	
Temporal Angle	Open	Closed	Open	Closed

Open	43	8	47	4
Closed	1	20	16	5
AC1	0.88 (0.63 to 0.92)		0.71 (0.35 to 0.75)	
Nasal Angle	Open	Closed	Open	Closed
Open	42	9	48	3
Closed	5	16	13	9
AC1	0.81 (0.45 to 0.84)		0.78 (0.48 to 0.83)	

Dual Blade Goniotomy in Addition to Usual Fenestrating Slits to Enhance Early Intraocular Pressure Lowering in Non-Valved Aqueous Shunt Surgery for Primary Open Angle Glaucoma

Qiu M¹, Khanna S¹, Theophanous C¹, Si Z¹

¹University Of Chicago, Chicago, United States

Introduction

To describe our experience with dual blade goniotomy in addition to usual fenestrating slits to enhance early IOP lowering in non-valved aqueous shunt surgery in primary open angle glaucoma.

Methods

A retrospective chart review was conducted of all non-valved tubes with usual fenestrating slits with additional dual blade goniotomy performed by a single surgeon between 10/1/2019-10/1/2021 in eyes with POAG. Eyes with prior traditional glaucoma surgery or cyclophotocoagulation were excluded. All cases were Baerveldt-350s and stented with a 3-0 Prolene ripcord, ligated with 7-0 Polysorb, and fenestrated 3 times with a spatulated SE-160-8 needle. This analysis focuses on the early post-operative period before the ligature dissolves.

Results

Eleven eyes from 11 patients were included; mean age was 69.2 years, 5/11 were female, 11/11 were African American, 11/11 had severe stage POAG. Concurrent cataract surgery was performed in 7/11 eyes, the other 4/11 were already pseudophakic. Mean pre-op IOP was 22.2 mmHg on 3.9 meds. Mean IOP on POD1 was 17.1 mmHg, mean IOP on POW1 was 16.5 mmHg on 4.0 meds, mean IOP on POW4 was 15.5 mmHg on 4.0 meds. After the ligature dissolved at POW6, mean IOP was 11.2 mmHg on 4.0 meds. Two eyes had hyphemas ≤ 1.0 mm at POD1 which resolved by POW1, and there were no reflux hyphemas at POW6 when the ligature dissolved. One eye had IOP spike >30 mmHg at POD1 and a different eye had IOP

spike at POW1; there were no IOP spikes at POW4 or POW6. No eyes had shallow AC or other hypotony associated complications.

Conclusion

Large fenestrating slits and/or early ripcord removal in non-valved tubes may carry a risk of hypotony associated complications. We demonstrate our novel surgical strategy of performing a goniotomy at the time of non-valved tubes, in addition to usual small fenestrations, to enhance IOP-lowering in the early postoperative period before the ligature dissolves. The additional goniotomy enhances IOP lowering without risk of hypotony-associated complications, since the additional aqueous outflow from the goniotomy is via the physiologic outflow pathway.

References

1. Lloyd MA, Baerveldt G, Heuer DK, et al. Initial clinical experience with the baerveldt implant in complicated glaucomas. *Ophthalmology* 1994;101:640–650.
2. Patel S, Pasquale LR. Glaucoma Drainage Devices: A Review of the Past, Present, and Future. *Semin Ophthalmol* 2010;25:265–270.
3. Siegnier SW, Netland PA, Urban RC, et al. Clinical Experience with the Baerveldt Glaucoma Drainage Implant. *Ophthalmology* 1995;102:1298–1307.
4. Wang Q, Thau A, Levin AV, Lee D. Ocular hypotony: A comprehensive review. *Surv Ophthalmol* 2019;64:619–638.
5. Sharkawi E, Artes PH, Oleszczuk JD, et al. Systematic Occlusion of Shunts: Control of Early Postoperative IOP and Hypotony-related Complications Following Glaucoma Shunt Surgery. *J Glaucoma* 2016;25:54–61.
6. Gedde SJ, Schiffman JC, Feuer WJ, et al. Treatment Outcomes in the Tube Versus Trabeculectomy (TVT) Study After Five Years of Follow-up. *Am J Ophthalmol* 2012;153:789-803.e2.
7. Christakis PG, Tsai JC, Kalenak JW, et al. The Ahmed Versus Baerveldt Study: Three-Year Treatment Outcomes. *Ophthalmology* 2013;120:2232–2240.

8. Fellman RL, Mattox C, Singh K, et al. American Glaucoma Society Position Paper: Microinvasive Glaucoma Surgery. *Ophthalmol Glaucoma* 2020;3:1–6.
9. Esfandiari H, Hassanpour K, Knowlton P, et al. Combining Baerveldt Implant with Trabectome Negates Tube Fenestration: A Coarsened-matched Comparison. *J Ophthalmic Vis Res* 2020;15:509–516.
10. Kersey JP, Broadway DC. Corticosteroid-induced glaucoma: a review of the literature. *Eye* 2006;20:407–416.
11. Honda R, Kasuga T, Murakami A, Matsuda A. Effects of the Numbers and the Shapes of Venting Slits on Intraocular Pressure after Baerveldt Glaucoma Drainage Implant. *Curr Eye Res* 2019;44:921–924.
12. Sheha H, Tello C, Al-Aswad LA, et al. Outcomes of the Shunt Tube Exposure Prevention Study: A Randomized Clinical Trial. *Ophthalmol Glaucoma* 2019;2:392–401.
13. Kansal S, Moster MR, Kim D, et al. Effectiveness of Nonocclusive Ligature and Fenestration Used in Baerveldt Aqueous Shunts for Early Postoperative Intraocular Pressure Control. *J Glaucoma* 2002;11:65–70.
14. Anon. The Effect of Suture Wick Technique on Early Intraocular Pressure Control After Nonvalved (Baerveldt 350) Glaucoma Drainage Device Surgery. Available at: <https://oce-ovid-com.proxy.uchicago.edu/article/00061198-201812000-00019/HTML> [Accessed July 14, 2021].
15. An SJ, Wen JC, Quist MS, et al. Scheduled Postoperative Ripcord Removal in Baerveldt 350 Implants: A Prospective, Randomized Trial. *J Glaucoma* 2019;28:165–171.
16. Law SK, Kornmann HL, Giaconi JA, et al. Early Aqueous Suppressant Therapy on Hypertensive Phase Following Glaucoma Drainage Device Procedure: A Randomized Prospective Trial. *J Glaucoma* 2016;25:248–257.
17. Popovic V. Early hypotony after trabeculectomy. *Acta Ophthalmol Scand* 1995;73:255–260.
18. Sit AJ, McLaren JW. Measurement of episcleral venous pressure. *Exp Eye Res* 2011;93:291–298.
19. Clark AF, Wordinger RJ. The role of steroids in outflow resistance. *Exp Eye Res* 2009;88:752–759.

20. Anon. Postoperative Management of Glaucoma Drainage Implants - Kahook's Essentials Of Glaucoma Therapy. Available at: https://www.keogt.com/Postoperative_Management_of_Glaucoma_Drainage_Implants [Accessed July 18, 2021].
21. Miller VJ, Young CEC, SooHoo JR, et al. Efficacy of Goniotomy With Kahook Dual Blade in Patients With Uveitis-associated Ocular Hypertension. *J Glaucoma* 2019;28:744–748.
22. Barry M, Alahmadi MW, Alahmadi M, et al. The Safety of the Kahook Dual Blade in the Surgical Treatment of Glaucoma. *Cureus* 2020;12:e6682.

Table

Table 1. Goniotomy at the time of non-valved aqueous shunt to enhance early IOP lowering before the ligature dissolves		
Timepoint	IOP in mm Hg (mean)	Number of medications (mean)
Preoperative	22.2 mmHg	3.9 meds
POD1	17.1 mmHg	N/A
POW1	16.5 mmHg	4.0 meds
POW4	15.5 mmHg	4.0 meds
POW6	11.2 mmHg	4.0 meds

Comparison of choroidal thickness after topical prostaglandin therapy in primary open angle glaucoma patients- a case series

S.G¹, Guliani B¹, Abrol S¹

¹Department of Ophthalmology, VMMC & Safdarjung Hospital, New Delhi, India

Introduction

The choroid contains more than 70% of the eye's circulatory blood and the majority of the choroidal thickness is contributed by vascular tissue ^[1]. The choroid plays a significant role in ocular blood flow, which explains its dominance in the pathophysiology of glaucoma. Thus measuring choroidal thickness implicates the perfusion status of the outer retina and ONH ^[2]. The choroidal thickness can be altered by antiglaucoma medications. In our study we analysed the subfoveal choroidal thickness of primary open angle glaucoma patient after prostaglandin therapy.

Methods

Treatment naive 10 primary open-angle glaucoma patients to be started on one anti glaucoma drug were recruited and their subfoveal choroidal thickness was measured by spectral-domain OCT at first visit and at third month after Travoprost(0.004%) therapy.

Results

In our study, an increase in choroidal thickness and reduction in IOP was noted after 3 months of Travoprost therapy.

Conclusion

This study concludes that prostaglandin analogue (Travoprost) is effective in increasing the choroidal thickness thereby enhancing the ONH perfusion in open angle glaucoma patients.

Keywords: ONH – Optic nerve head, POAG – Primary open angle glaucoma.

References

1. Song YJ, Kim YK. Assessment of Open-Angle Glaucoma Peripapillary and Macular Choroidal Thickness Using Swept-Source Optical Coherence Tomography (SS-OCT). Paul F, editor. PLoS ONE. 2016 Jun 16; 11(6):e0157333.
2. Bayraktar S, Cebeci Z. The effect of glaucoma medication on choroidal thickness measured with enhanced depth-imaging optical coherence tomography. Medical Hypothesis, Discovery and Innovation in Ophthalmology. 2019; 8(1):44.

Online Perimetry: Validation, comparison with standard automated perimetry and patient appraisal

Meyerov J¹, Deng L¹, Bigirimana D², [Skalicky S^{1,2}](#)

¹University of Melbourne, Melbourne, Australia, ²Royal Victorian Eye and Ear Hospital, Australia, East Melbourne, Australia

Introduction

Online perimetry via personal computers improves accessibility and affordability of perimetry, clinic flow and opens opportunities for at-home glaucoma monitoring and online screening.¹⁻³ We designed a novel system for 24-degree, 52-loci online circular contrast perimetry (OCCP). We validate and compare its diagnostic accuracy and patient appraisal to standard automated perimetry (SAP).

Methods

233 participants (135 controls, 98 open-angle glaucoma patients) completed OCCP, SAP and optical coherence tomography (OCT) for retinal nerve fiber layer (RNFL) and macular ganglion cell complex inner plexiform layer (GCC+IPL). Of these, 89 participants (40 controls, 49 glaucoma patients) completed a user experience survey.

Results

Pointwise sensitivity for OCCP was less than SAP by 4.233 dB (95% confidence interval 3.44 to 5.03); 95% limits of agreement ranged from -9.72 to 1.26. OCCP mean deviation (MD) area under receiver operating curve (AUC) was 0.884 ± 0.08 , similar to other instruments' parameters with the highest AUC: SAP MD (0.840 ± 0.08), OCT RNFL mean thickness (MT) (0.882 ± 0.08), OCT GCC+IPL inferior thickness (IT) (0.849 ± 0.08) (Figure 1). At best cut-off, OCCP MD sensitivity/specificity were comparable to SAP (87/77 vs 90/65) for detecting glaucoma. Cohen's Kappa demonstrated good agreement with SAP MD (0.76), OCT RNFL MT (0.71) and OCT GCC+IPL IT (0.70). 81.7% of participants preferred OCCP over SAP overall, and across 8/10 survey parameters ($P < 0.00001$; Figure 2). Rasch

analysis demonstrated no differential item functioning for clinical group, gender, or age.

Conclusion

With similar diagnostic accuracy to SAP and an improved user experience, OCCP holds potential for utilization in glaucoma monitoring (in-clinic and at-home) and screening.

References

1. Aboobakar IF, Friedman DS. Home Monitoring for Glaucoma: Current Applications and Future Directions. *Semin Ophthalmol.* 2021;36(4):310-314.
2. Jones PR, Campbell P, Callaghan T, et al. Glaucoma Home Monitoring Using a Tablet-Based Visual Field Test (Eyecatcher): An Assessment of Accuracy and Adherence Over 6 Months. *Am J Ophthalmol.* 2021;223:42-52.
3. Prea SM, Kong GYX, Guymer RH, Vingrys AJ. Uptake, Persistence, and Performance of Weekly Home Monitoring of Visual Field in a Large Cohort of Patients With Glaucoma. *Am J Ophthalmol.* 2021;223:286-295.
4. Lowry EA, Hou J, Hennein L, et al. Comparison of Peristat Online Perimetry with the Humphrey Perimetry in a Clinic-Based Setting. *Transl Vis Sci Technol.* 2016;5(4):4. Published 2016 Jul 19.

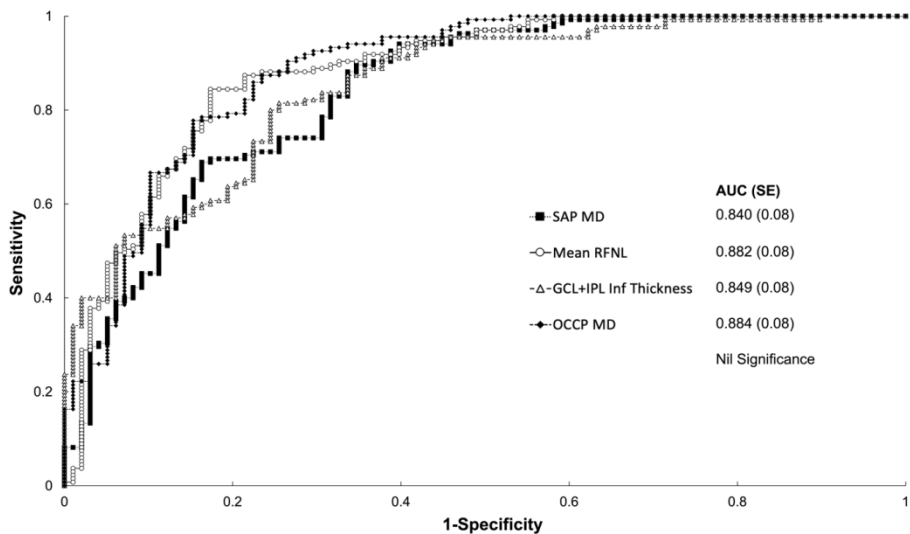


Figure 1. Instrument parameters with the highest AUC.

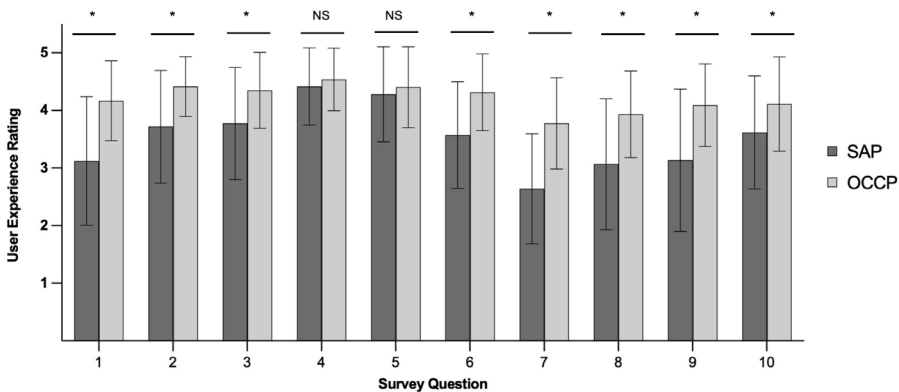


Figure 2. User experience ratings for OCCP vs SAP from 10 survey questions.

*P<0.00001.

The efficacy and safety of prostaglandin analogues/ timolol fixed combinations in glaucoma and ocular hypertension: a systematic review and meta-analysis

Sujipinyo P¹, Trabwongwitaya P¹, Chongpison Y², Tantisevi V³

¹Faculty of Medicine, Chulalongkorn University, Bangkok, Thailand, ²Biostatistics Excellence Center, Research Affairs, Faculty of Medicine, Chulalongkorn University, Bangkok, Thailand, ³Department of Ophthalmology, Faculty of Medicine, Chulalongkorn University, Bangkok, Thailand

Introduction

Fixed-dose combinations (FDC) of prostaglandin analogues (PGA) and timolol (TIM) are efficacious hypotensive agents, help improve better compliance of patients who need multiple medications. However, benzalkonium chloride (BAK), the common preservatives in FDCs, could lead to ocular side effects. This study aims to compare efficacy and safety among the FDCs and evaluate safety of BAK-containing formulations.

Methods

A meta-analysis focused on IOP lowering efficacy and incidence of ocular adverse events among FDCs. Randomized controlled trials (RCT) directly comparing the commercially available FDCs (latanoprost, travoprost, bimatoprost, tafluprost, and timolol; with or without BAK) were systematically searched via PubMed, SCOPUS, Cochrane Library, and clinicaltrials.gov. The primary outcome was mean IOP differences (MeD) at the end of studies from baseline. The secondary outcome were incidences of ocular side effects.

Results

Sixteen randomized controlled trials were included (n=2,229 patients). No significant difference of MeD among all comparisons of FDCs was found (BIM/TIM vs LAT/TIM, 95% CI -0.13-2.82 mmHg, p=0.07; BIM/TIM vs TRA/TIM, 95% CI -0.18-

2.09 mmHg, $p=0.10$; TRA/TIM vs LAT/TIM, 95% CI -0.88-0.36 mmHg, $p=0.41$). The relative risks of conjunctival hyperaemia among all comparisons were not significantly different (BIM/TIM vs TRA/TIM, 95% CI 0.64-3.43, $p=0.36$; LAT/TIM vs TRA/TIM, 95% CI 0.17-1.30, $p=0.15$; BIM/TIM vs LAT/TIM, 95% CI 0.99-2.04, $p=0.05$). Most of side effects (ocular hyperaemia, eye irritation, eye pain, foreign body sensation, dry eyes, conjunctival hyperaemia, keratitis) were not significantly different between the BAK-preserved and BAK-free FDCs except for eye pruritus (RR=2.01; 95% CI 1.02-3.97; $p=0.04$) favouring BAK-containing formulations.

Conclusion

There was no significant difference of IOP lowering effect and incidence of side effects among 4 PGA-TIM FDCs. BAK-preserved PGA-TIM FDCs did not significantly show greater side effects. Conversely, non-BAK-containing formulations showed higher incidence of eye pruritus.

Iridolenticular Contact Area, Pupil Block and Primary Angle Closure

Tun T^{1,2}, Nongpiur M^{1,2}, Wang X³, Aung T^{1,2,4}

¹Singapore Eye Research Institute and Singapore National Eye Centre, Singapore, Singapore, ²Duke-NUS Medical School, Singapore, Singapore, ³Beijing Advanced Innovation Center for Biomedical Engineering, School of Biological Science and Medical Engineering, Beihang University, Beijing, China, ⁴Department of Ophthalmology, Yong Loo Lin School of Medicine, National University of Singapore, Singapore, Singapore, Singapore

Introduction

Although it was hypothesized that larger iridolenticular contact area (ILCA) between the iris and the lens blocks aqueous flow at the level of the pupil leading to the pupillary block¹, this was not corroborated in studies conducted with ultrasound biomicroscopy.^{2,3} The aim of this study was to characterize the swept-source optical coherence tomography (SSOCT) derived parameter, ILCA and its association with primary angle closure.

Methods

Right eyes of 465 consecutive subjects from a population-based study underwent SSOCT (SS-1000, CASIA, Tomey Corporation, Nagoya, Japan) angle imaging and indentation gonioscopy in the dark. Out of 128 cross-sectional images, 8 frames (22.5 degrees apart) were selected for analysis. We used Matlab (Matworks Inc, MA, USA) to measure the ILCA, defined as the circumferential contact area between the iris and the anterior surface of the lens.

Results

The majority of the recruited subjects were female (77.6%) with a mean age of 62±6.6 years and 143 subjects had closed angles. The ILCA was significantly smaller in eyes with closed angles compared to those with open angles (7.06±2.59 mm² vs 9.04±3.9 mm², P<0.001). ILCA decreased significantly with increasing number of

gonioscopic closed quadrants (P for trend <0.001). In multivariable regression analysis, the ILCA of the whole cohort was associated with pupil diameter (PD) ($\beta=-3.22$, $P<0.001$), iris thickness at 750 μ m from the scleral spur ($\beta=-6.96$, $P=0.028$), iris curvature ($\beta=-19.53$, $P<0.001$), and the presence of gonioscopic angle closure ($\beta=-1.1$, $P<0.001$). After adjusting for age, gender and PD, the odds ratio for the presence of angle closure based on ILCA was 1.34 (95% confidence interval, 1.23, 1.46).

Conclusions

ILCA was reduced in the eyes with closed angles, those with more curved and thicker peripheral iris, larger pupil and increasing number of closed quadrants. ILCA may be a novel risk indicator for primary angle closure.

References

1. Lowe RF, Angle-closure, pupil dilatation, and pupil block. *Br J Ophthalmol*, 1966. **50**(7): p. 385-9.
2. Cronemberger S, Calixto N, de Andrade AO, and Merula RV, New considerations on pupillary block mechanism. *Arq Bras Oftalmol*, 2010. **73**(1): p. 9-15.
3. Woo EK, Pavlin CJ, Slomovic A, Taback N, Buys YM. Ultrasound biomicroscopic quantitative analysis of light-dark changes associated with pupillary block. *Am J Ophthalmol*. 1999 Jan;127(1):43-7.

Incidence of Hypotony Post Glaucoma Drainage Device Implantation: Paul vs Baerveldt

Wang M¹, Lai Y¹, Ch'ng T¹, Ng H, Adeline K¹, Ramli N², Choo M²

¹Hospital Raja Permaisuri Bainun, Department of Ophthalmology, 30450 Ipoh, Malaysia, ²University Malaya Eye Research Centre, Department of Ophthalmology, Pusat Perubatan University Malaya, 59100 Kuala Lumpur, Malaysia

Introduction

Paul Glaucoma Implant (PGI) is a non-valved Glaucoma Drainage Device (GDD) with a smaller internal diameter as compared to Baerveldt Glaucoma Implant (BGI). The objective of our study was to compare the incidence of hypotony and postoperative complications as well as the clinical efficacy at 6 months between PGI and BGI.

Methods

Retrospective cohort study

Results

A total of 15 eyes in PGI and 14 in BGI were included in this study. Mean preoperative IOP in PGI was 31.2 ± 5.3 mmHg, with mean of 4.6 ± 0.4 antiglaucoma medications, and 23.6 ± 6.9 mmHg, with mean of 4.4 ± 0.8 medications in BGI. At 6months follow-up, the mean postoperative IOP was lower in PGI, 13.8 ± 2.6 mmHg (55.6 % reduction) compared to BGI, 16.67 ± 6.72 mmHg (31.8% reduction) ($P=0.045$). At 6 months postoperative, mean medications used were 0.4 ± 0.9 in PGI group and 1.1 ± 1.0 in BGI ($P < 0.05$). PGI had shorter postoperative hospitalization length of 1.5 ± 0.9 days compared to BGI, 3 ± 2.4 days ($P=0.042$). No significant change in visual acuity (VA) was demonstrated in both groups as mean postoperative VA measured (LogMAR) was 0.55 ± 0.27 in PGI and 1.2 ± 1 in BGI. ($P=0.110$). Both groups had comparable success rates, with PGI achieving 86.6% and BGI recording 86.0% (complete and qualified success). Most frequently observed

complication in BGI was postoperative hypotony which occurred in 21% (n=5) of eyes with 57% (n=8) requiring reintervention. No hypotony was observed in PGI.

Conclusion

PGI showed similar efficacy compared to BGI in terms of IOP and glaucoma medication reduction. Furthermore, PGI appeared to be safer as hypotony was not observed.

References

1. Vinod K, Gedde SJ, Feuer WJ, Panarelli JF, Chang TC, Chen PP, et al. Practice preferences for glaucoma surgery: a survey of the American Glaucoma Society. *J Glaucoma*. 2017;26:687–93.
2. Christakis PG, Kalenak JW, Zurakowski D, et al. The Ahmed Versus Baerveldt study: one-year treatment outcomes. *Ophthalmology*. 2011;118(11):2180–2189.
3. Vallabh, N.A., Mason, F., Yu, J.T.S. *et al*. Surgical technique, perioperative management and early outcome data of the PAUL® glaucoma drainage device. *Eye* (2021).

Low Optic Disc Perfusion Evaluated with Swept Source Optical Coherence Tomography Angiography is Associated with Visual Field Progression in Open Angle Glaucoma

Yoon J¹, Lee J¹, Shin J², Kim K¹, Kim J³, Sung K¹

¹Asan Medical Center, Seoul, South Korea, ²J'S Retina Clinic, Gangneung, South Korea, ³Kangbuk Samsung Hospital, Seoul, South Korea

Introduction

This study aimed to assess the microvascular perfusion measured with the swept source OCTA (SS-OCTA) in the optic nerve head (ONH) region of primary open angle glaucoma (OAG) eyes with and without visual field (VF) progression.

Methods

In a retrospective study, the 3.0x3.0mm ONH image of SS-OCTA was used to evaluate the parapapillary choroidal vessel density (VD), intradisc VD, choroidal microvascular dropout (CMvD), and optic disc MvD. 266 eyes of 266 OAG patients were divided into VF progressor and non-progressor. Cox proportional hazard analysis was performed to identify the clinical factors associated with VF progression.

Results

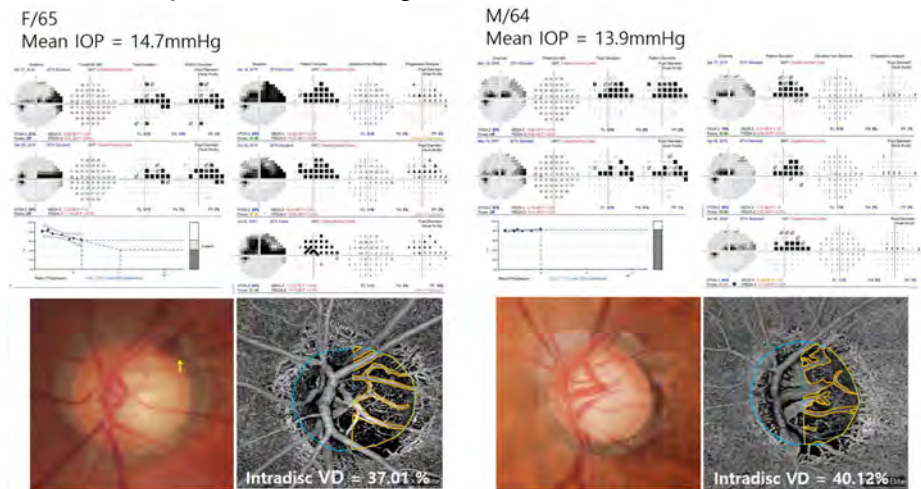
80 eyes (30.1%) out of 266 OAG eyes showed glaucomatous VF progression during the 5.4 years of follow-up. Young age, presence of optic disc hemorrhage (DH) during follow-up, presence of CMvD and optic disc MvD, lower intradisc VD and lower parapapillary choroidal VD was associated with VF progression. Intradisc VD reduction was associated with the presence of DH during follow-up, presence of CMvD, and lower parapapillary choroidal VD.

Conclusion

The optic disc perfusion, represented as intradisc VD and parapapillary choroidal VD in SS-OCTA, was significantly decreased in OAG eyes with VF progression.

Figure

The eye with DH and low intradisc VD shows VF progression, while the VF MD and IOP matched eye with no DH and higher intradisc VD shows stable VF.



MSJOC oral abstract presentations

Dry eye management with diquafosol 3% eyedrops before and after cataract surgery

[Lee M¹](#)

¹LEC Eye Centre, Ipoh, Malaysia

Introduction

To evaluate the efficacy of diquafosol sodium 3% eyedrops for dry eye management in patients with pre-existing dry eye disease before and after cataract surgery.

Methods

Prospective observational case series of patients with pre-existing dry eye disease treated with diquafosol sodium 3% 1 month prior to cataract surgery and continued for 3 months after cataract surgery. Tear Break Up Time (TBUT), National Eye Institute Corneal and Conjunctival Fluorescein staining score (CFS), Standard Patient Evaluation of Eye Dryness (SPEED) score, uncorrected (UCDA) and best corrected distance visual acuities (BCDA) were measured preoperatively, on the day of surgery (Preop) then at 1 month and 3 months postoperatively.

Results

Compared to baseline measurements, the mean TBUT did not show significant improvement at Preop ($p=0.197$) but was significantly better at 1 month ($p=0.001$) and 3 months ($p=0.012$) postoperatively. The mean CFS score was significantly better at Preop ($p=0.009$), 1 month ($p=0.0005$) and 3 months ($p<0.0001$). Mean SPEED scores showed significant improvement at Preop ($p<0.0001$), 1 month ($p<0.0001$) and 3 months ($p<0.0001$). The mean CFS score was significantly better at 3 months compared to 1 month postoperatively ($p=0.016$). Postoperative UCDA and BCDA were significantly better at 3 months ($p<0.0001$, $p=0.0002$).

Diquafosol sodium 3% was well tolerated and there were no severe adverse reactions observed.

Conclusion

In patients with pre-existing dry eye disease undergoing cataract surgery, this study shows that diquafosol sodium 3% reduces signs and symptoms of dry eye when started at least a month prior to surgery and continued for at least 3 months postoperatively.

Machine Learning for Predicting Childhood Myopia Progression

Yong Li^{1,2}, Daniel Ting^{1,2}, Marcus Ang^{1,2*}

¹Singapore National Eye Centre, Singapore Eye Research Institute, Singapore

²Duke-NUS Medical School, National University of Singapore, Singapore

Introduction

Prevention of myopia onset and early intervention to control progression in childhood are key strategies to reduce high myopia that could lead to visual impairment in adulthood. We performed a retrospective, observational clinical study to develop artificial intelligence algorithms that can predict childhood myopia progression.

Methods

A total of 701 patients (1236 eyes) aged 6-12 years were included, 346 patients from the atropine for the treatment of childhood myopia (ATOM) 1 study and 355 patients from the ATOM 2 study. Patients were treated with placebo eye drops, 0.01%, 0.1%, 0.5%, or 1% of atropine and followed-up for two years. Their baseline demographics were recorded, baseline cycloplegic and noncycloplegic autorefractometry were performed, baseline ocular biometry parameters were measured. Myopia progression within the two years was classified as mild (<0.5 D), moderate (0.5-0.99 D), or severe (≥ 1.0 D) by spherical equivalent (SE) change as the primary outcome; and mild (<0.2 mm), moderate (0.2-0.49 mm), or severe (≥ 0.5 mm) by axial length (AL) change as the secondary outcome. With these baseline parameters, we use machine learning to develop algorithms to predict myopia progression.

Results

We build two models for predicting myopia progression with baseline parameters. For the primary outcome of SE change, with baseline age, gender, atropine treatment, cycloplegic refraction SE, AL, anterior chamber depth, our model

achieved area under receiver operating characteristics (ROC) curve (AUC) of 0.807. For the secondary outcome of AL change, our model achieved AUC of 0.799.

Conclusion

Machine learning models based on baseline parameters achieved promising results for the prediction of childhood myopia progression. Our models can provide clinicians with insights about the children's risk of developing high myopia in adulthood and taking early interventions to control progression in childhood, including different concentration of atropine to be adopted.

Conditioned Media from Mesenchymal Stem Cells Upregulates Corneal Epithelial Genes Expression on PHA

Shaharuddin B¹, Salih M², Kumar S³

¹Universiti Sains Malaysia, Kepala Batas, Malaysia, ²National University Sudan, Khartoum, Sudan, ³School of Biological Sciences, Minden, Malaysia

Introduction

Corneal grafts or corneal transplantation are limited by graft rejection, disease transmission and scarcity of donor supply. The major type of stem cells used in regenerative medicine is mesenchymal stem cells (MSC) which promotes wound healing by its paracrine factors and anti-inflammatory effects. PHA polymer is biocompatible, biodegradable, non-toxic polymer, which is produced by many microorganisms, and present a huge potential as tissue scaffold.

Methods

Conditioned media (CdM) from WJ-MSC was generated for HTCEC cultures. PHA (3HB-co- 4HB- co- 5HV- co- 3HHx) was successfully biosynthesized as a tissue scaffold. HTCEC viability was tested using Presto Blue cell viability assay. The effect of CdM on HTCEC grown on PHA scaffold was evaluated by characterization of corneal gene expressions using qPCR.

Results

MSC-conditioned media (CdM) improved the cell viability and gene expression of HTCEC on PHA significantly ($p < 0.05$). All corneal genes expressions were significantly upregulated when the cells were cultured on PHA and treated with CdM for 3 days, the corneal genes studied here were integrin- β (ITGB1), ATP-binding cassette super-family (ABC)- G member 2 (ABCG2) and - B member 5 (ABCB5), cytokeratin (CK) -3 and 12, connexin -43 (CX43) and delta N-p63 alpha ($\Delta Np63\alpha$). There is no significant difference in cell viability or corneal gene expression of cultures grown on control surface or PHA alone.

Conclusion

These findings suggested that use of conditioned media from MSC as a cell-free therapy with and without PHA scaffold are novel strategies for corneal regeneration.

Acknowledgement

USM Research University (Individual) grant: 1001/CIPPT/8012263 and Cryocord (M) Sdn Bhd for human MSC provision.

In vitro and in vivo Biodegradation of PHA polymer: Regenerative Strategy for Corneal Application

[Shaharuddin B¹](#), Salih M², Kumar S³

¹Universiti Sains Malaysia, Kepala Batas, Malaysia, ²National University Sudan, Khartoum, Sudan, ³School of Biological Sciences, Minden, Malaysia

Introduction

Limitations in the current corneal grafts and transplantation warrants further exploration into tissue-engineered strategies for corneal wound healing and replacement. Biological scaffolds are commonly used as a carrier for corneal cell sheet transplantation. Polyhydroxyalkanoate (PHA) polymer has been used for many biomedical applications. This study aims to evaluate biodegradation of PHA *in vitro* and *in vivo* to justify its biomedical application in the cornea.

Methods

P(3HB-co-4HB-co-5HV-co-3HHx) was biosynthesized for *in vitro* and *in vivo* biodegradation evaluation. For *in vitro*, the films were subjected to porcine lipase degradation, determined by measuring the weight loss of the films after 5 days. *In vivo* biodegradation was conducted in Sprague Dawley rats. A single PHA film (17 x 22 mm diameter) was placed on the anterior surface of one eye. The upper and lower lids were then closed with vicryl 6/0 sutures. Standard post-operative eye care and observation of the general condition of the rats and the eyes were performed daily until end points – post op day 1, 3, 5, and 7. PHA films explanted from the eyes at each end point were assessed using scanning electron microscopy (SEM) under 3000 X magnification.

Results

PHA films lost up to 77% of its weight ($p < 0.05$) after 5 days treatment with lipase. *In vivo* biodegraded films explanted from the rats showed clear surface degradation increasing with time on SEM compared to controls.

Conclusion

PHA polymer proves to be rapidly biodegradable *in vitro* and *in vivo* and shows good potential for a safe corneal biomedical application.

Acknowledgement:

USM Research University (Individual) grant: 1001/CIPPT/8012263.

Retinal Neural Dysfunction in Diabetes Revealed with Handheld Chromatic Pupillometry

Tien-En Tan^{1,2}, Maxwell T. Finkelstein¹, Gavin Siew Wei Tan^{1,2}, Anna Cheng Sim Tan^{1,2}, Choi Mun Chan^{1,2}, Ranjana Mathur^{1,2}, Edmund Yick Mun Wong^{1,2}, Chui Ming Gemmy Cheung^{1,2}, Tien Yin Wong^{1,2}, Dan Milea^{1,2}, Raymond P. Najjar^{1,2,3}

¹Singapore Eye Research Institute, Singapore, Singapore National Eye Centre, Singapore

²Duke-National University of Singapore Medical School, Singapore

³Department of Ophthalmology, Yong Loo Lin School of Medicine, National University of Singapore, Singapore

Introduction

Evidence from structural imaging and functional testing modalities demonstrates retinal neural dysfunction in diabetes, which may have important pathophysiologic and prognostic implications. The aim of this study was to evaluate the ability of handheld chromatic pupillometry to reveal and localize retinal neural dysfunction in diabetic patients with and without diabetic retinopathy (DR).

Methods

This cross-sectional study included 82 diabetics (DM) and 93 controls (60.4 ± 8.4 years, 44.1% males). DM patients included those without ($n=25$, 64.7 ± 6.3 years, 44.0% males) and with DR ($n=57$, 60.3 ± 8.5 years, 64.9% males). Changes in pupil diameter in response to blue (469nm) and red (640nm) light stimuli were assessed monocularly, in clinics, using a custom-built handheld pupillometer. Pupillometric features (phasic constriction [from outer retina], maximal constriction [from inner and outer retina] and post-illumination pupillary responses [PIPRs; from inner retina]) were extracted from baseline-adjusted pupillary traces and compared between controls, DM without DR, and DR. Net PIPR was the difference between blue and red PIPR.

Results

Phasic constriction amplitudes to blue and red lights were decreased in DR compared to controls ($p<0.001$; $p<0.001$). Maximal constriction amplitudes to blue and red lights were decreased in DR compared to DM without DR ($p<0.001$; $p=0.02$), and in DM without DR compared to controls ($p<0.001$; $p=0.006$). Net PIPR was decreased in both DR and DM without DR compared to controls ($p=0.02$; $p=0.03$), suggesting a wavelength-dependent (and hence retinal) pupillometric dysfunction in diabetic patients with or without DR.

Conclusion

Handheld chromatic pupillometry can reveal retinal neural dysfunction in diabetes, even without DR. Patients with DM but no DR displayed primarily inner retinal dysfunction, while patients with DR showed both inner and outer retinal dysfunction.

Intra-arterial Chemotherapy for Retinoblastoma: 7-years outcomes in Malaysia

Wai Y^{1,2}, Radhakrishnan D², Lingam G³, Hamzah N², Rahmat J^{1,2}

¹Ophthalmology Department, Hospital Tunku Azizah, Malaysia

²Radiology Department, Hospital Tunku Azizah, Malaysia

Introduction

To analyse our 7-year experience of intra-arterial chemotherapy (IAC) for retinoblastoma. We aimed to examine the tumour response, globe salvage, mortality and safety profile of IAC in the Malaysian profile.

Methods

A total of 22 eyes of 20 patients with retinoblastoma underwent IAC using melphalan and topotecan from 2015 to 2021 in Hospital Kuala Lumpur were retrospectively reviewed. Tumour response, globe salvage, mortality and safety profile of IAC were compared based on International Classification of Retinoblastoma (ICRB).

Results

The mean patient age at IAC was 21.3 months. An overall globe salvage rate of 63.6% was observed: and more specifically, 100% for Group A, 75% for Groups B and C, 66.7% (Group D) and 42.9% (Group E). Poor tumour response after IAC was significantly associated with a lesser chance of globe salvage ($p=0.045$). Overall good tumour response followed IAC was 77.3%. Specifically, good responses for Group A (100%), Group B (75%), Group C (75%), Group D (83.3%) and Group E (71.4%). The mortality rate was 10%. Complications (per-catheterisation) included cerebral infarct (2.2%), oxygen desaturation (2.2%), vomiting (26.1%), periorbital oedema (8.8%), ptosis (6.5%), fever, femoral hematoma and hyperpigmentation over lid (4.4% each).

Conclusion

7-year experience showed that IAC is a safe and effective method for retinoblastoma management. Patients with a poor response after IAC may have a lower chance for globe salvage. Careful patient selection is of utmost importance to achieve the best outcome in a setting of limited healthcare resources.

Umbilical Cord Plasma Therapy for recalcitrant dry eye disease in a local Singaporean context

Wong L.Y.J.¹, Gayathri G¹, Arun P², Louis T¹

¹Singapore National Eye Centre, Singapore

²Singapore Cord Blood Bank, Singapore

Introduction

Dry eye disease is a significant medical problem and there is currently no satisfactory treatment for moderate to severe dry eye. We aimed to evaluate the effectiveness of using a closed method of preparing umbilical cord plasma eyedrops for treatment of recalcitrant dry eye.

Methods

An observational prospective case study conducted at Singapore National Eye Centre. Eligibility criteria include dry eye patients who did not show continuing improvement in signs and symptoms after conventional therapy with artificial tear, anti-inflammatory, diquafosol eyedrops or punctal plugs.

Results

We evaluated 34 patients with moderate to severe dry eyes, receiving cord plasma therapy over a duration of 1-8 months. Treatment markers were monitored pre and post treatment, namely (VA, TBUT, Schirmer's, punctate staining (punctate epithelial erosions). Based on our preliminary findings of 17 patients who have returned for review visits, in terms of punctate staining 88% improved, 6% remained the same. In terms of VA, 35% improved, 41% stabilised 24% worsened. Punctate staining showed significant improvement, with most patients improving from diffuse PEE to inferior PEE.

Conclusion

Cord plasma is a promising and effective treatment for moderate- severe dry eyes.

MSJOC OD oral abstract presentations

Slow Coagulation Transscleral Cyclophotocoagulation: Practicality in Seeing Eye versus Blind Eye

Hui Wen L¹, Suyi S¹, Ismail H¹, Ariffin N¹, Ismail M¹, Vendargon F¹

¹Hospital Sultanah Aminah Johor Bahru, Johor Bahru, Malaysia

Introduction

Slow coagulation transcleral cyclophotocoagulation (TSCPC) has shown good efficacy and safety profile for the seeing eyes. To evaluate the suitability of slow coagulation technique in the painful blind eye, we further analysed the outcome in both seeing and blind eye among patients at Hospital Sultanah Aminah, Johor Bahru.

Methods

Retrospective case series. This single center study reviewed 53 patients (n=59 eyes) who received slow coagulation continuous wave TSCPC (1000–1500 mW power and 4-second duration) between January 2018 until June 2020. These patients were divided into two main groups by indications of TSCPC: (1) refractory glaucoma (n=27) and (2) painful blind eye (n=31). They were followed up to 6 months post intervention. The primary outcome measured was laser success defined as an intraocular pressure (IOP) <21mmHg or >30% reduction from baseline with no repeated procedure. Secondary outcomes measured include reduction of required anti-glaucoma medication, visual acuity (VA) and complications.

Results

The power delivered was 4.9 ± 0.5 J for group 1 and 5.1 ± 0.6 J for group 2. IOP decreased from 35.1 ± 8.5 mmHg and 46.3 ± 13.7 mmHg to 23.9 ± 10.2 mmHg and 28.2 ± 12.2 mmHg ($p < 0.001$), yielding treatment success rates of 66.7% and 67.7% at

final index visit, for group 1 and group 2 respectively. The mean reduction in the number of anti-glaucoma medications was 0.6 ± 1.4 in group 1 ($p=0.036$) and 0.8 ± 2.1 in group 2 ($p=0.035$). There was no significant difference between pre- and post-treatment VA and complication rates in both groups. The only complication documented was transient hypotony.

Conclusion

Whenever TSCPC is indicated, slow coagulation setting should be considered regardless of VA status based on the proven short term effectiveness and safety profile.

References

1. Chan, J. C., Chow, S. C., & Lai, J. S. (2020). Effectiveness and Safety of Long Duration versus Short Duration Diode Laser Transscleral Cyclophotocoagulation. *Clinical ophthalmology (Auckland, N.Z.)*, 14, 197–204. <https://doi.org/10.2147/OPTH.S228910>
2. Fong, Y. Y., Wong, B. K., Li, F. C., & Young, A. L. (2019). A retrospective study of transcleral cyclophotocoagulation using the slow coagulation technique for the treatment of refractory glaucoma. *Seminars in Ophthalmology*, 34(5), 398–402. <https://doi.org/10.1080/08820538.2019.1638946>

APGC Film Festival abstract presentations

Inferior Ahmed glaucoma valve implantation in an eye with silicone oil & encircling band

Acosta P¹, Tumbocon J¹

¹St. Luke's Medical Center , Quezon City, Philippines

This is a case of Ahmed glaucoma valve implantation in a 14 year old male with refractory secondary ocular hypertension post pars plana vitrectomy with silicone oil, encircling band and lensectomy on the left eye for idiopathic exudative retinal detachment unresponsive to systemic, topical and periocular steroids. The intraocular pressure (IOP) post-retina surgery was persistently above 50 mmHg in spite of partial silicone oil extraction, maximum systemic and topical glaucoma medications. Inferior sub-conjunctival and sub-Tenon's dissection was done up to the encircling band and its capsule further dissected to the expose the band itself. The anterior edge of the band was located 8 mm. posterior to the limbus and an inferotemporal Watzke sleeve was present. Inferonasal placement of the Ahmed plate was chosen due to less impediments. The Ahmed plate was positioned 8 mm. posterior to the limbus, on the encircling band, and anchored to both the sclera and band using interrupted nylon sutures. Ophthalmic Viscoelastic Device was injected in the anterior chamber to prevent silicone oil migration into the anterior chamber (AC). Residual AC silicone oil micelles were removed with manual aspiration with a cannula and syringe. The tube was inserted into the anterior chamber and was covered by a donor scleral patch graft. The conjunctiva was closed with nylon 10-0 and vicryl 8-0 sutures. Early topical aqueous suppression was initiated after surgery to decrease the risk of a "hypertensive phase". IOP was maintained between 11 to 13 mmHg up to 9 weeks post-op.

Novel Use of the Intra-Operative Optical Coherence Tomography in Trabecular Bypass Minimally Invasive Glaucoma Surgery

Ang B^{1,2}, Lim S³, Betzler B⁴

¹Department of Ophthalmology, Tan Tock Seng Hospital, , Singapore, ²Department of Ophthalmology, Woodlands Health Campus, , Singapore, ³Army Medical Services, Singapore Armed Forces, , Singapore, ⁴Yong Loo Lin School of Medicine, National University of Singapore, , Singapore

The use of intra-operative optical coherence tomography (iOCT) has been gaining popularity in glaucoma surgery and more recently, in minimally invasive glaucoma surgery (MIGS), with the aim of improving intra-operative visualization and achieving better post-operative outcomes^{1,2}. In angle-based MIGS, surgical precision is critical yet challenging, given the difficulty in intra-operative visualization within the small space of the angle. With real-life case examples, this film demonstrates how the iOCT may be used to aid the implantation and optimal placement of two trabecular bypass MIGS devices – the iStent Inject W and the Hydrus Microstent, and correlates iOCT images to the appearance of these devices in-situ.

Introduction

1. Intra-operative optical coherence tomography (iOCT) is gaining popularity in glaucoma surgery and minimally invasive glaucoma surgery (MIGS)
 2. Angle-based trabecular-bypass MIGS, in particular, would benefit from adjunct iOCT during surgery
-

iOCT use in iStent inject W implantation

1. Overview of device
2. The importance of optimal device placement
3. Challenges in device placement – over- and under-implantation
4. How the iOCT can aid optimal device placement – by visualization of the device flange in relation to the surface of the trabecular meshwork and visualization of reflux bleeding
5. Correlation between iOCT images and device in-situ in the angle

iOCT use in Hydrus Microstent implantation

1. Overview of device
2. The importance of optimal device placement
3. Challenges in device placement – difficult visualization of the microstent windows behind dense iris processes or heavily-pigmented trabecular meshworks
4. How the iOCT can aid optimal device placement – by visualization of the microstent in the Schlemm's canal
5. Correlation between iOCT images and device in-situ in the angle

Conclusion

1. Future avenues for iOCT application and research in MIGS
2. Summary of learning points

References

1. Kan JT, Betzler BK, Lim SY, Ang BCH. Anterior segment imaging in minimally invasive glaucoma surgery - A systematic review. *Acta Ophthalmol*. 2021 Jul 11. doi: 10.1111/aos.14962.
2. Ang BCH, Lim SY, Dorairaj S. Intra-operative optical coherence tomography in glaucoma surgery-a systematic review. *Eye (Lond)*. 2020 Jan;34(1):168-177.

Glaucoma Blindness Rescue Operation

[Bhatnagar K¹](#), [Shakrawal J¹](#)

¹All India Institute of Medical Sciences, Jodhpur, Jodhpur, India

The video aims to showcase the role of medical fraternity for glaucoma prevention, diagnosis and treatment, which is a “*silent thief of sight*.” It highlights the versatile ways to increase glaucoma awareness in entire health care workers and patients. It features celebration of “*World Glaucoma Week*” which includes various mentioned activities; hospital decorations with posters & rangoli, public lectures & pamphlet distribution, vision chariot in entire city & puppet show in local language.

The video offers a versatile way to spark the conversation about glaucoma in creative ways.

Our goal is to educate, inspire and encourage a change, to eliminate blindness and visual disability due to glaucoma around the country.

Surgical techniques for management of hypotonic maculopathy

Chauhan N¹, Bukke, A¹, Verma S¹, Satpute K¹, Sharma N¹, Dada T¹

¹R.P. Centre AIIMS Delhi, Delhi, India

Hypotony caused by excess filtration after trabeculectomy can lead to permanent visual loss if not corrected in time. In this video presentation we present special surgical techniques which can be used to reverse hypotony. Hypotony due to over filtration without any bleb leak can be managed by using transconjunctival sutures or compression sutures. Eyes with ischemic blebs can be managed with epithelial debridement and conjunctival overlay while eyes with scleral defects require use of scleral patch grafts / lamellar scleral grafts or the use of biodegradable collagen implants for tectonic support. In eyes where adequate conjunctiva cannot be mobilized to cover the area of the excised bleb, conjunctival autografts or pedicle rotation grafts can be used.

Understanding the various methods of intervention to deal with hypotony tailored on a case to basis depending on the requirement for conjunctival or scleral support helps to restore the anatomic and functional integrity of the globe and prevents further visual loss.

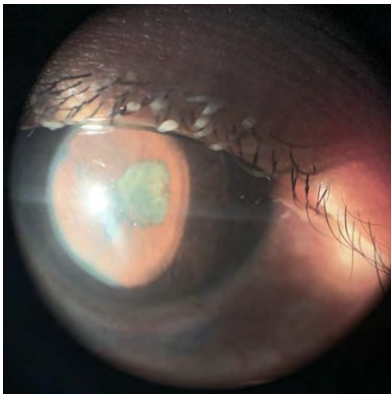
Combine Phacoemulsification and Trabeculectomy with Synechiolysis in case of Closed Angle Uveitic Glaucoma

Natali Christine R¹, Nicholas Dwiki Tanong¹

¹Ophthalmology Department Medicine Faculty Universitas Kristen Indonesia, Jakarta, Indonesia

A 38 year-old male patient came with blurred vision and pain in the left eye. Eight months prior, the patient had been treated for anterior uveitis and got secondary glaucoma about 1 month ago. Examination on the left eye revealed a visual acuity of hand movement, shallow anterior chamber with almost 360° posterior synechia, cloudy lens, and Intra Ocular Pressure (IOP) of 43 mmHg. After 1 month of Anti-Glaucoma drugs, target IOP was not achieved. Oral prednisolone was given 2 week prior to surgery. Mannitol intravein was given 1 hour preoperative and the IOP decreased to 25 mmHg. Intraoperative challenge included an undilated pupil after synechiolysis, hence an iris retractor was used. Combine Phacoemulsification and trabeculectomy was done and a three-piece IOL was implanted. The following day after the surgery; visual acuity of 0.3 with corneal edema, anterior chamber deepened, IOP of 20 mmHg, and well-functioning diffuse bleb

Figure



Modified surgical steps of trabeculectomy and deep sclerectomy

Karim M¹, Hoque H¹

¹Chevron Eye Hospital & Research Institute, Chattogram, Bangladesh

Post operative IOP control is better with trabeculectomy or superior when mitomycin C is used. Even with these added advantages it still remains a costly alternative for average patient in developing countries, such as Bangladesh. Also there is chances of failure to control post operative IOP.

Hence, when a glaucoma patient visits our hospital, we thought of constructing a modified technique along with trabeculectomy to create a potential space between superficial scleral flap and deep scleral bed that will act as a deep scleral lake for maintaining decreased post operative IOP levels(with or without mitomycin C).

Thus, overshadowing the superiority of trabeculectomy with or without mitomycin C in the maintenance of IOP levels. Our measure of success is constrained towards the consideration that even without the use of mitomycin C , majority of our patients achieved well maintained postoperative IOP levels without use of medications and had few complications.

How to do Guided Implantation of Ahmed Glaucoma Valve and Its Usefulness

Lee C¹, Choi J¹

¹Ulsan University Hospital, University of Ulsan College of Medicine, Ulsan, Korea,
Democratic Republic of

Ahmed glaucoma valve (AGV) is commonly used to manage complex and refractory glaucoma. AGV implantation is performed with increasing frequency in glaucoma patients because of its postoperative safety and maintenance of stable surgical results.

One of the rare but serious complication after AGV implantation, which has recently attracted the attention of many glaucoma surgeons, is corneal endothelial damage that can lead to subsequent corneal decompensation. Considerable efforts have been made to minimize corneal endothelial damage after AGV implantation. Conventionally, many surgeons try to shorten the length of the tube and place it as parallel and close to the iris as possible. However, the tube is often inaccurately positioned where not intended, and induces complications such as hyphema, iridodialysis, and cyclodialysis in the process of insertion. As a result, inappropriate tube position could cause corneal endothelial damage.

Therefore, this video shows how surgeon can insert AGV tube in the anterior chamber easily and accurately with 4-0 nylon guide and spatula, and compared the effect of guided verses non-guided (conventional method) implantation of AGV on corneal endothelial damage.

Finally, guided implantation of AGV will be an accurate and safe adjuvant surgical technique which is effective in reducing corneal endothelial cell loss compared to conventional non-guided implantation technique.

Intraoperative Gonioscopy for Beginner

Lim S¹

¹Daegu Veterans Health Service Medical Center, Dalseo-gu, South Korea

Introduction

Gonioscopy is an essential examination for diagnosis and treatment of glaucoma. This method allows that directly observes the anterior chamber angle with an aqueous humor outflow pathway. Recently, minimally invasive glaucoma surgery, MIGS, have been used widely in clinical setting. However, it has relatively difficult learning curve and key to successful angle surgery requires optimal visualization of angle.

Methods

In this video, I will present some surgical tips and tricks of intraoperative gonioscopy for successful glaucoma surgery, so called “ABCs DO” methods.

Results

A, Angle Anatomy; you should be familiar with the **landmark** of angle anatomy. First, you can find the brightest white line, **scleral spur**. And then, anteriorly located **trabecular meshwork**, and posteriorly located **ciliary body** can be identified. These findings are essential anatomy for MIGS.

B, Baseline Examination; *Preoperative office-based gonioscopic examination is essential for surgical planning.*

C. First ‘C’ is “Cooperation”. Second ‘C’ is “Corneal incision”.

S, stabilization

D, Docking of goniolens is difficult and challenge, because non-dominant hand usage make too much pressure to cornea.

O, OVD usage and other surgical skills

Conclusion

In Summary, Angle Anatomy, Baseline Examination, Cooperation and Corneal incision, and Stabilization of eye are important. And understanding Surgical Instruments, Docking of Goniolens, Proper use of OVD and operation skill yield the successful intraoperative gonioscopy.

XEN Resuscitation: Management of complications

[Lim S¹](#)

¹Daegu Veterans Health Service Medical Center, Dalseo-gu, South Korea

Introduction

The XEN gel stent is a widely used micro-invasive glaucoma surgery (MIGS) device to reduce intraocular pressure in glaucoma, by creating a shunt from the anterior chamber to the subconjunctival space. Most reported complications after XEN gel stent implantation are minor and inherent in the surgical techniques. Moreover, we always evaluate the **“bleb height”**, **“vascularity”**, and **“stent position”**. Despite its proven effectiveness and safety profile, the XEN gel stent may still have problems and sometimes need surgical revision.

Methods

Film Festival, This video demonstrates a number of common ‘complications’ after XEN implantation, and management.

Results

This video share surgical experiences on

1. Surgical Revision (open XEN revision) for flat bleb (subconjunctival fibrosis) after needling revision.
2. XEN implant Fracture after Rubbing and Exchange of XEN gel stents using ab Externo technique
3. Trans-conjunctival compression sutures for a nasally expanding bleb causing dysesthesia
4. Combined argon laser iridoplasty and Nd:YAG laser therapy for Recurrent XEN gel stent obstruction due to iris incarceration
5. XEN-Cortex occlusion after Phaco-XEN surgery: Recanalization of XEN gel stent using Nd:YAG shockwave treatment.

Conclusion

In the rapidly evolving era of less invasive glaucoma surgeries, XEN gel stent offers a new means of lowering IOP for patients. However, in some cases, we should pay attention to resuscitate XEN implant.

Early bleb leak - You are in for a surprise!

Manapakkam M¹, [Lakshminarayana R¹](#), Mohan N¹

¹Aravind Eye Hospital, Chennai, Chennai, India

In a 40yr old male patient who underwent Trabeculectomy with Mitomycin-C, an early bleb leak with conjunctival retraction was noted after 2weeks.

The intraocular pressure was normal and the anterior chamber was well formed. Diagnosis of conjunctival retraction with early bleb leak was made and bandage contact lens(BCL) was applied. After 1week, BCL was removed and seidel's test was still positive. As there was a brisk leak, patient was taken up for conjunctival re-suturing. The surprise element found on surgical table was the scleral flap button hole. A scleral patch graft was used and leak was secured. Conjunctiva was advanced and sutured.

Early bleb leak with conjunctival retraction might not always be as it appears - should be prepared for surprises on table.

Look out for flap related complications!!

Always have a scleral patch graft as a backup while taking up the patient for re-surgery post Trabeculectomy.

Releasable Suture in Trabeculectomy - A Boon to Glaucoma

Manapakkam M¹, Gurumoorthy P¹, Lakshminarayana R¹, Mohan N¹

¹Aravind Eye Hospital, Chennai, Chennai, India

Interrupted, externalised releasable suture in trabeculectomy allows control of Intraocular pressure during early postoperative period. In a country like India, trabeculectomies are being performed in small towns where the access to argon laser suturolysis is not available and hence might can be challenging.

This technique was first described by Shaffer et al and there are various other techniques like Wilsons technique, Cohen's etc. Each surgeon follows the technique they feel comfortable and which works best for them. The commonly used technique is making a slipknot with four loops and one open end is exteriorised which can be accessed. Main problems of underfiltration and overfiltration are regulated with this technique. The drawback is the patient has irritation in the postoperative period.

Releasable sutures are one of the most economical and best way used for the effective functioning of the bleb by titrating the intraocular pressure and to prevent complications in early post operative period.

Challenging case scenarios in Ahmed Glaucoma valve implantation

Maddu S¹, Angmo D¹

¹Dr Rajendra Prasad Centre for Ophthalmic Sciences Aims New Delhi, New Delhi, India

Introduction

Standard techniques of an Ahmed glaucoma valve implantation were described earlier. In this video we would like to describe our modifications in AGV implantation according to respective case scenarios.

Case 1

A 45-year-old female diagnosed with RE secondary glaucoma with operated vitreoretinal surgery.

Modification

As it's a case of post VR surgery keeping in mind the amount of conjunctival scarring, a primary AGV implantation was executed.

Case 2

A 9-year-old male diagnosed with RE secondary glaucoma with failed trabeculectomy.

Modification

We noticed in younger age group incidence of tube corneal touch is high; to overcome this we used a scleral patch graft beneath the tube to bolster it.

Case 3

A 22-year-old male diagnosed with BE Microcornea with aphakia with RE operated vitreoretinal surgery with secondary glaucoma; with axial length of either eye around 22mm.

Modification

We planned for a primary AGV implantation; given it's a small eye i.e microcornea and axial length; we placed a pediatric AGV model instead of the adult one.

Case 4

A 58-year-old female diagnosed as RE mixed mechanism glaucoma with failed trabeculectomy.

Modification

AGV implantation done through direct scleral tunnel by passing the step of scleral flap.

Intraoperative Optical Coherence tomography guided Glaucoma surgery

Maddu S¹, Angmo D¹

¹Dr R. P. Centre for Ophthalmic Sciences AiiMS New Delhi, New Delhi, India

Introduction

iOCT with heads up display (HUD) allows rapid visualization of the area of interest and provides the surgeon with information regarding instrument-tissue interactions; with its finer resolution' OCT is able to present detailed view of the bleb wall, sclera and assessment of the location and extent of the bleb structure. In this video we describe iOCT guided glaucoma surgery by two procedures.

A. iOCT guided Bleb Needling [1]

In this procedure we describe how under the direct visualization of iOCT bleb needling is done with minimal tissue damage and post needling resulting in a functional bleb.

B. iOCT guided Bleb sparing epithelial exchange [BSEX][2]

The original procedure as described by Sihota et al [3]. Similar procedure was done under the guidance of iOCT and trypan blue dye to stain the epithelium further aiding in BSEX, this helps in preventing inadvertent damage to bleb structures.

References

1. Dada T, Angmo D, Midha N, Sidhu T. Intraoperative optical coherence tomography guided bleb needling. J Ophthalmic Vis Res 2016;11:452-4.
2. Angmo D, Shakrawal J, Sihota R. Intraoperative Optical Coherence Tomography-Guided Bleb-sparing Epithelial Exchange: A Modified Approach. J Ophthalmic Vis Res 2021;16:1-7.
3. Sihota R, Angmo D, Sen S, Gupta V, Dada T, M. Pandey R. The Long-term Outcome of Primary "Bleb-sparing, Epithelial Exchange" in Dysfunctional Filtering Blebs J Glaucoma 2016;25:571-578

Affordable MIGS- Training & Surgery

[Narayanan S¹](#), Balamurali R, Bhaskaran J, Jayachandran M, Viswam V

¹Regional Institute of Ophthalmology, Thiruvananthapuram, India

Introduction

The juxtacanalicular trabecular meshwork has long been thought to be the site of greatest resistance to aqueous outflow. Incision /or removal of the trabecular meshwork by ab-interno Goniotomy/ trabeculotomy has been successfully used to lower IOP in congenital glaucoma for years and more recently has been shown to be advantageous in adult POAG as well. GATT surgery using 5-0 prolene suture has caught the imagination of surgeons in developing countries due to its simplicity, safety and cost effectiveness.

Method

The first part of this video shows how to assemble a practice eye for GATT using leftovers from the operating room. Steps to ensure smooth learning curve will be demonstrated.

The second part of this video demonstrates fashioning a goniotomy knife for Bent Ab-interno Needle Goniotomy from multiple needles which will mimic Kahook dual blade for ab-interno trabeculectomy.

Results

A safe route to mastering low cost MIGS is described.

Conclusion

Systematic MIGS training followed by real surgery can be done safely and cost effectively.

References

1. Guo CY, Qi XH, Qi JM. Systematic review and Meta-analysis of treating open angle glaucoma with gonioscopy-assisted transluminal trabeculotomy. *Int J Ophthalmol*. 2020 Feb 18;13(2):317-324. doi: 10.18240/ijo.2020.02.17.
2. Bicket AK, Le JT, Azuara-Blanco A, Gazzard G, Wormald R, Bunce C, Hu K, Jayaram H, King A, Otárola F, Nikita E, Shah A, Stead R, Tóth M, Li T. Minimally Invasive Glaucoma Surgical Techniques for Open-Angle Glaucoma: An Overview of Cochrane Systematic Reviews and Network Meta-analysis. *JAMA Ophthalmol*. 2021 Sep 1;139(9):983-989. doi: 10.1001/jamaophthalmol.2021.2351.
3. Yook E, Vinod K, Panarelli JF. Complications of micro-invasive glaucoma surgery. *Curr Opin Ophthalmol*. 2018 Mar;29(2):147-154. doi: 10.1097/ICU.0000000000000457.

Tailoring the Tube – Managing complications of Glaucoma Drainage Devices.[Pandey A¹](#)¹Centre For Sight, Surat, India

This video demonstrates the management of 3 different complication scenarios not uncommonly encountered after glaucoma drainage device surgery. The first part of the video describes a method of in-situ shortening of a tube in the anterior chamber to prevent recurrent anterior uveitis and potential corneal endothelial damage due to excessively long tube. The second part includes a low cost method of extending the silicon tube of an Ahmed Glaucoma Valve which got retracted during the early post operative period. A 22G Angio catheter was used to extend the tube without completely removing the implant. The last part of the video demonstrates the surgical technique to remove an anteriorly dislocated non-valved glaucoma implant causing severe pain and discomfort in a painful blind eye. The removal was done in toto to ensure no remnants of the implant were left behind.

Bleb Needling - An effective procedure for saving a failing bleb.

[PorwalA¹](#)

¹Choithram Netralaya, Indore, India

Trabeculectomy is highly performed glaucoma surgery globally, but a proportion of these procedures fail. Failing or failed bleb are the ones that have Increased Vascularity - Cork screw Vessels, high IOP, encapsulated high dome appearance, flat localized or absence of microcyst. These blebs fail cause of rapid wound healing response in terms of subconjunctival fibrosis or sub tenons encapsulation of bleb. Bleb needling combined with antimetabolite injection is an effective procedure to save these blebs at any stage. Goal of bleb needling is to re-establish the fistula from the anterior chamber to a subconjunctival space, where aqueous humor may be reabsorbed. It can be performed in OPD or OT. It is more effective if performed within four months from the time of trabeculectomy and is Less effective if pre-needling IOP > 30mmHg, immediate post-needling IOP > 10mmHg, trabeculectomy performed without MMC. Factors such as the time period after the initial trabeculectomy and the degree of scarring will greatly affect the outcome. Varying success rates, ranging from 30% to 94% with good long-term control is reported. It is repeatable with minimal risk in the management of glaucoma patients. In this video I will be demonstrating various tips and tricks of performing bleb needling both in OPD and in operation theatre along with the pre and post needling anterior segment OCT pictures of the blebs.

Combined surgery: Manual small incision cataract surgery plus trabeculectomy a boom for developing countries.

[Porwal A¹](#)

¹Choithram Netralaya, Indore, India

Globally cataract and glaucoma are the main reason for visual impairment and blindness. In developing countries incidence of these combined disease is much more because of limited resources, manpower and finances. In this video I showcase the technique of tackling both the disease in one go by performing a combined procedure that is Manual small incision cataract surgery (MSICS) combined with trabeculectomy. MSICS is economically cheaper when we compare with phacoemulsification requiring very less instrumentation and avoiding the cost of the Phaco machines. Combining trabeculectomy with MSICS in the same sitting when needed gives comparable results with Phacotrab. This procedure is easy to master and can be performed in high volumes with less surgical time, minimal complications and resources. This is the reason that MSICS combined with Trabeculectomy is a boom in developing countries. In this video I will showcase the various techniques of MSICS Plus Trabeculectomy.

Ahmed to Baerveldt exchange and repositioning from AC to pars plana with autologous capsular autograft.

Qiu M¹

¹University Of Chicago, Chicago, United States

This is a video of an Ahmed to Baerveldt exchange and repositioning with capsular autograft. This eye with NVG and a 3 piece IOL in the sulcus had a prior failed Ahmed. Instead of implanting a 2nd aqueous shunt in this monocular eye, we performed an Ahmed to Baerveldt 350 (BGI350) exchange with the tube in the pars plana combined with vitrectomy with endolaser. The capsule from the Ahmed was to be used as a patch graft. The conjunctiva was opened superotemporally. A 6-0 Traction suture was placed in the superior sclera. The old tube was pulled out of the AC and the track was sutured shut on a 8-0 Vicryl on a BV needle. A more posterior traction suture was placed. The Ahmed capsule was incised along the anterior edge of the plate. Anchoring stalks were severed. A fibrovascular stalk of tissue had grown into the valve mechanism and was blocking aqueous outflow. This was severed and removed. The remaining 3 anchoring stalks were severed. The Ahmed plate and tube were removed. The entire Ahmed capsule, front and back, was bluntly dissected off of the bare sclera with a strumming motion. The muscles were hooked and a new BGI 350 was implanted into the superotemporal quadrant in the usual fashion. The tube was trimmed with an anterior bevel and inserted into the pars plana. A piece of Ahmed capsule tissue was cut to size and used as an autologous patch graft for the new BGI350. The conjunctiva was closed at the limbus. The 3-0 Prolene was buried in the inferior fornix. Post op week 4 photos are shown.

Cataract Surgery + DSEK with Basket Retention Suture + Tube repositioning from Anterior Chamber to Ciliary Sulcus

Qiu M¹, Farooq A¹

¹University Of Chicago, Chicago, United States

This is a video of a combo case with the cornea service of a phaco, DSEK, and tube repositioning. The conjunctiva was opened in the superotemporal quadrant. Blunt dissection was performed to lyse the sub conjunctival adhesions from the prior tube surgery. The temporal sclera was to be used for a scleral tunnel. A para was made. Trypan was used to stain the capsule. The AC was filled with viscoat. The previous corneal patch graft was removed. The old tube was removed from the AC and the track was sutured with 8-0 Vicryl on a BV needle to provide a water tight seal. The tube was tucked under the conjunctiva, out of the way for the cataract. The sclera was cauterized and a scleral tunnel was made temporally. The epithelium was debrided to improve the view. The rhexis was created in the usual fashion. The phaco was uneventful. A 1 piece IOL was injected into the bag. The sclera was cauterized at the new tube entry site. The tube was re-trimmed with a posterior bevel. A 23G needle was used to make an entry into the ciliary sulcus superotemporally. The tube was inserted in front of the IOL into the sulcus. A scleral tutoplast patch graft was sutured over the tube entry site. The cornea service performed a DSEK as usual, with an extra 6-0 prolene basket retention suture since the eye is at risk of hypotony due to the tube. Post op photos at POW1 are shown.

The Do-It-Yourself, Novel, Safe & Cost-Effective Diagnostic Cubicle for Glaucoma Practice in the COVID-19 Era

Ramesh P¹

¹Mahathma Eye Hospital Private Limited, Trichy, India

The coronicle (corona + cubicle) innovated by us, provides state-of-the-art features required for holistic glaucoma evaluation. Assembling this cubicle requires acrylic sheets, aluminium beading, fevicol, araldite paste and jigsaw cutting blade. Dimensions of the cubicle are 16*16*8 feet with a total area of only 256 sq. feet; thus restricting patient movement inside hospital. Social distancing with 3 feet between machines, were incorporated while installing the gadgets within the cubicle. The cubicle encompasses slit-lamps with applanation tonometer, fundus capture device, optical coherence tomography, optical biometry (CCT) and gonioscopy. Customised openings in the cubicle were made in front of each device for patient's head and chin rest; and can be closed with sliding doors during times of disuse. An acrylic groove was provided to accommodate the patient's feet. Coronicle has helped instil, both patient and medical personal safety during COVID-19; thus serving as a novel glaucoma diagnostic cubicle. In this film video, we have also shown the economics involved in setting up the diagnostic cubicle; and have also shown the validation of the cubicle's utility, in terms of the quantitative usage of ophthalmic gadgets present inside the cubicle versus outside the cubicle for the past 20 months (May 2020 - December 2021), since the installation of the cubicle; along with the cubicle's additive highlights and its role after the pandemic is over.

The Photoreal New-Age Innovative Counselling Tool for Glaucoma with 3D Augmented Reality (Eye MG AR)

Ramesh P¹

¹Mahathma Eye Hospital Private Limited, Trichy, India

The highlight of this film festival video is the augmented reality (AR) program named, 'Eye MG AR' innovated by us, to show different anatomical/pathological parts of the eye pertaining to glaucoma, from multiple customised angles of the patient's choice to simplify glaucoma counselling. Procedures ranging from, a simple YAG peripheral iridotomy to a complex trabeculectomy/tube surgery can be counselled with this app. Also complex structures such as the angles of the anterior chamber and optic nerve head, are constructed in advanced real-time three-dimensional (3D) photoreal visuals for immersive patient counselling experiences. This AR tool aims to reinvent approach to glaucoma counselling with 'Unreal Engine' software, and is constructed in a patient friendly approach. It is available free of cost from the Google Play Store for Android users, and is currently under development for iPhones. Incepting 3D counselling with AR in glaucoma, with deep visualisation has never been reported and can pave the way for a new age in glaucoma counselling.

If only

[Rifqi K¹](#), [Prabowo S¹](#), [Zhafira D¹](#), [Anastasia R¹](#), [Nurwasis N¹](#), [Komaratih E¹](#),
[Primitasari Y¹](#)

¹Department of Ophthalmology, Faculty of Medicine, Universitas Airlangga,
Surabaya, Indonesia

Asti, a mother of a little girl named Hana has a simple life-goal: to build a future warm and caring family to live with. She did not miss a single thing since Hana's day one. Her life was just as happy as any other mother in her neighbourhood, until one day she began to bump into her surroundings constantly. As Hana grew older, Asti started to feel like seeing through a tunnel, yet she always delayed her doctor appointment. Time by time, in Hana's remarkable memories, the visual field is getting narrower.

If time could be turned back, how crucial it was to be aware of the glaucoma's early sign. If only she went to ophthalmologist earlier, the progressivity of the disease might be managed. This short movie has a purpose to tell viewers that by taking care of the sight, we also take care of valuable moments.

A start to Trabectome Surgery: Must know tips and tricks!

[Sethi S¹](#), Sethi A¹

¹Arunodaya Deseret Eye Hospital, Gurugram, India

This video showcases step by step demonstration to approaching a trabectome surgery. MIGS has attracted a lot of attention of late due to the freedom from medications and a respectable control of intraocular pressure. It can be practiced in mild to moderate open angle glaucomas. This video demonstrates highly useful tips and tricks for young ophthalmologists and practitioners who are looking to upgrade their skills by venturing into newer surgical modalities. Positioning of the patient, working and settings of the machine, gonio lenses required, aligning the lens with respect to the eye, holding and movement of the probe, surgical challenges, possible complications, how to avoid them and the post-operative management are some of the aspects that need expert guidance and will be touched upon. Through this video, I am hoping to encourage glaucoma practitioners to start trabectome surgery as although it has a learning curve, is not an unsurmountable task.

Innovative glaucoma awareness strategies: Need of the hour in developing countries!

Sethi S¹, Sethi A¹

¹Arunodaya Deseret Eye Hospital, Gurugram, India

In India, around 12 million people suffer from glaucoma, and 1.5 million are blind due to it, making it the third most common cause of blindness. More than 75% of glaucoma are undiagnosed, which perhaps represent the submerged portion of the iceberg phenomenon of the traditional disease explanations.

Infact, there is a large gap between the prevailing burden of glaucoma and services being delivered towards its prevention compared to other leading causes of blindness in India. For a resource-limited country, where mass population based-screening programs are not feasible, alternative methods like facility-based opportunistic screening and referring the high-risk groups for early detection and treatment are being done in a limited capacity in the country.

We came up with innovative ways to educate a larger target audience at once and boast of increased followability and compliance. This included radio talks, sensitization to various smart phone glaucoma applications, video-based demonstrations, breaking myths about glaucoma, free medication camps etc. This video showcases the work we have done and the ways adopted by us in the past 2 years towards this cause. These strategies can be adopted world-wide for reversing the tide of irreversible blindness caused by glaucoma.

Trabeculectomy in Microcornea eye with use of Light Pipe guided transillumination for demarcation of angle landmarks for surgery, and other safety and success oriented measures

TR¹

¹Sankar Foundation Eye Institute & Hospital, Visakhapatnam, India

We present trabeculectomy in 9 year old Male child with Microcornea Cataract Syndrome, with aphakic glaucoma.

The ostium position is crucial for success of trabeculectomy. Microcornea condition makes the “surgical limbus” ill-defined with potential anatomical variations to position of scleral spur with respect to anterior extent of conjunctiva.

The light pipe transillumination effect marked the anterior extent of ciliary processes, and likely position of scleral spur. Gentian violet pen was used to mark the landmarks on conjunctiva. The landmarks were found to be 2.5 mm behind the insertion of conjunctiva. The plan for location of the scleral flap and ostium was then made using the estimated position of the scleral spur.

Fornix based conjunctival flap was raised and the conjunctival marks matched on to sclera to define the Trabeculectomy flap; 350 micron guarded blade and “irrigating crescent blade” (innovatively avoiding cautery) was used to fashion the triangular scleral flap.

AC maintainer, connected to Phaco IV pole, was used to control intra-operative IOP and minimize the period of hypotony at time of ostium creation and peripheral iridectomy.

3 x 10-0 nylon interrupted sutures were applied for the trabeculectomy flap with the ACM still connected and flow controlled from the IV bottle height mechanism of phacoemulsification machine.

Conjunctival bogginess form ACM flow was minimized by use of intermittent momentary flow of fluid into the AC by initiating momentarily the ACM flow as and when tendency to softening of eye was noticed.

Post operative images and gonio video are also presented.

Does Size Matter?

Wai Y¹, Teh S¹

¹Selayang Hospital, Batu Caves, Malaysia

Introduction

XEN® gel stent is a small permanent and flexible tube used to drain aqueous fluid from the anterior chamber to the subconjunctival space. It is one of the widely used Micro-Invasive Glaucoma Surgery (MIGS) devices to date however complications can arise such as intraluminal obstruction.

Methods

A video demonstration on how the XEN® gel stent intraluminal obstruction is relieved using Nylon 9/0

Results

This is a surgical video of an open revision of the XEN® gel stent. Conjunctiva peritomy was done and all scar tissue surrounding the gel stent was removed with careful multilayer dissection. After removal of scar tissue, the stent does not seem to filter therefore the lumen of the stent was reopened using a 10/0 nylon filament suture and inserted all the way into the anterior chamber and later removed. This however did not restore the flow of the XEN® gel stent and we proceeded with trabeculectomy. One last attempt was made using Nylon 9/0 instead to reopen the lumen of the XEN® gel stent and flow can be seen after removal of the 9/0 filament suture.

Conclusion

XEN® gel stent intraluminal obstruction has been reported and restoring flow can be achieved by open revision using Nylon 9/0 instead of Nylon 10/0.

References

1. Management of Nonfiltering XEN gel stent by Somar Hassan
<https://www.aao.org/clinical-video/management-of-nonfiltrating-xen-gel-stent>
2. XEN® Gel Stent: A Comprehensive Review on Its Use as a Treatment Option for Refractory Glaucoma [Clin Ophthalmol](#). 2020; 14: 1805–1832.
doi: [10.2147/OPTH.S178348](https://doi.org/10.2147/OPTH.S178348)

APGC poster abstract presentations

2 Years Retrospective Review of Lens Induced Glaucoma in Hospital Taiping, Perak, Malaysia

Abd Rahman Z^{1,2,3}, Lai Chan F¹, Sok Lin N¹, Abdul Hamid H², Mohamad S³

¹Department of Ophthalmology, Hospital Taiping, Taiping, Malaysia, ²Department of Ophthalmology, Hospital Sultan Abd Halim, Sungai Petani, Malaysia,

³Department of Ophthalmology and Visual Science, School of Medical Sciences, Universiti Sains Malaysia, Kubang Kerian, Malaysia

Introduction

Lens induced glaucoma (LIG) is an important cause of secondary glaucoma that can lead to blindness if left untreated. We aimed to describe demographic data, clinical presentation and outcomes of LIG.

Methods

A retrospective review of patients who were diagnosed with LIG and underwent cataract surgery in Hospital Taiping from January 2019 until December 2020.

Results

A total of 24 patients fulfilling the diagnostic criteria for LIG were included in the study. There were 14 cases diagnosed as phacomorphic (58.33%) and 10 cases as phacolytic glaucoma (41.67%). The mean age was 66±12 years old. Female and male were equally affected with a ratio of 1:1.18. Majority of patients were Malay (75%), followed with Chinese (16.67%) and Indian (8.33%). Eleven patients presented with visual acuity of hand movement (16.67%). The mean IOP on presentation was 47.5±13.66 mmHg. Post operatively, the mean IOP was 15.08±8.09 mmHg and the best corrected visual acuity (BCVA) of 6/15 was achieved

in 20 cases (83.33%). Ten cases (41.67%) who presented with initial IOP of more than 40mmHg were found to have glaucomatous disc changes.

Conclusion

Glaucomatous optic neuropathy occurs in eyes with IOP more than 40mmHg during presentation. Early cataract surgery is therefore necessary for a better visual outcome.

References

1. Pin GP, Salowi MA, Adnan TH, Sa'at N. The 8th Report of the National Eye Database 2014. National Eye Database (NED). 2016 Jun.
2. Sitoula RP, Sarkar I, Nayak D, Singh SK. Lens induced glaucoma: an experience in tertiary eye care center in eastern Nepal. Nepalese Journal of Ophthalmology. 2016;8(2):161-6.
3. Pradhan D, Hennig A, Kumar J, Foster A. A prospective study of 413 cases of lens-induced glaucoma in Nepal. Indian journal of ophthalmology. 2001 Apr 1;49(2):103.
4. Prajna NV, Ramakrishnan R, Krishnadas R, Manoharan N. Lens induced glaucomas-visual results and risk factors for final visual acuity. Indian Journal of Ophthalmology. 1996 Jul 1;44(3):149.

A patient with large intracranial tumor presenting to glaucoma clinic

Abdullah A¹, Natan P²

¹Faculty Of Medicine Universitas Brawijaya, Malang, Indonesia, ²Glaucoma Clinic Lavalette Hospital , Malang, Indonesia

Introduction

Patients with intracranial tumour sometimes present to ophthalmology clinic with ocular problems as their complaint, however it is rare that large intracranial tumour with prominent space occupying mass encountered at a glaucoma outpatient setting. The purpose of this report is to describe a case of intracranial Meningioma with bilateral visual loss as the main initial finding.

Methods

Case report of a patient who presented to outpatient glaucoma clinic at Lavalette Hospital, Malang. Diagnosis was based on history taking, general and ocular examination, and a CT-scan with contrast.

Results

A female, 49-year-old patient came to glaucoma clinic with chief complaint bilateral visual loss gradually worsening in the last four months. Further history taking revealed other symptoms including relapsing headache and general weakness. The visual acuity on both eyes were already no light perception at the initial visit. Anterior segment was calm but the pupil was dilated with no light reflexes. Fundus examination revealed a bilateral pale optic nerve heads but with sharp circular edges. Intraocular pressures were 14 mmHg. A CT-scan with contrast was urgently performed which revealed a massive 7.7 x 7.6 x 4.5 cm intracranial mass in the frontal region. Radiological reading suggested a Meningioma with cerebral oedema and subfalcine herniation. The patient was immediately referred to surgical neurology unit.

Conclusion

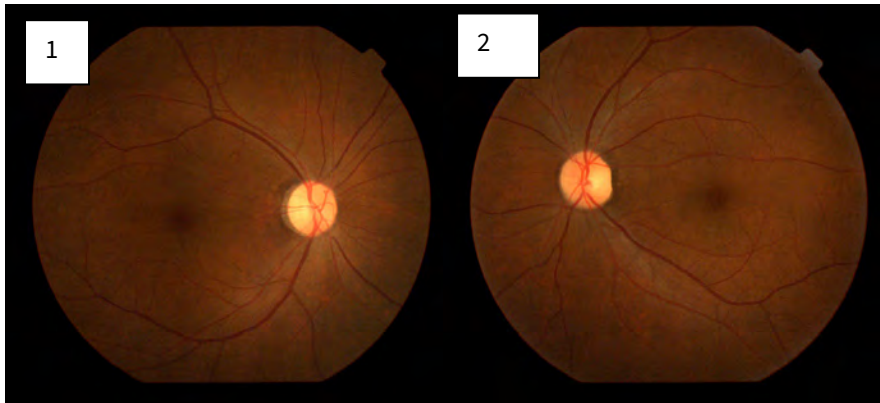
A patient with slow growing intracranial Meningioma may come quite late to seek medical attention and sometimes primarily on ocular complaint. Ophthalmologist must be aware and consider intracranial tumour as a cause of visual loss and therefore not to delay its management.

References

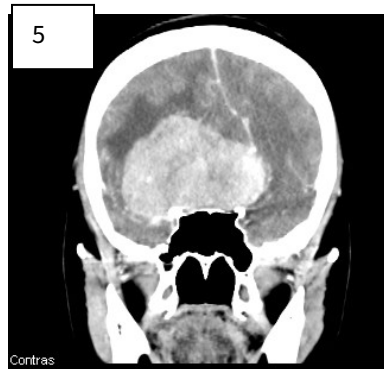
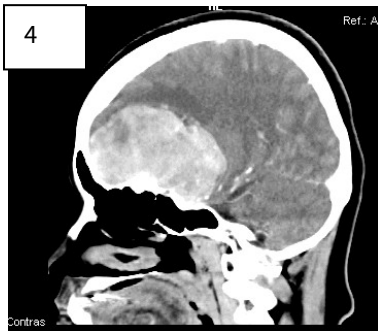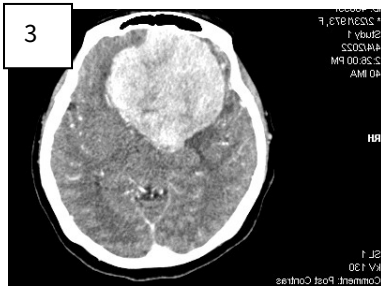Bowling, B. (2015). *Kanski's clinical ophthalmology* (8th ed.). W B Saunders.

FIGURES

Figures 1, 2. Fundus photography showing bilateral optic atrophy



Figures 3, 4, and 5. CT-scans with contrast showing large intracranial tumour



Trans-Resveratrol and RU-615 Attenuate Steroid-Induced Collagen Deposition in Human Trabecular Meshwork Cells

Abu Bakar A^{1,2}, Agarwal R³, Iethitsa I^{3,4}, Spasov A⁴, Zhukovskaya O⁵, Razali N^{1,2}

¹Pharmacology Department, Faculty of Medicine, UiTM Sungai Buloh Campus, Sungai Buloh, Malaysia, ²Institute of Medical Molecular Biotechnology (IMMB), UiTM Sungai Buloh Campus, Sungai Buloh, Malaysia, ³School of Medicine, International Medical University (IMU), Bukit Jalil, Malaysia, ⁴Department of Pharmacology and Bioinformatics, Volgograd State Medical University, Volgograd, Russia, ⁵Southern Federal University, Research Institute of Physical and Organic Chemistry, Rostov-on-Don, Russia

Introduction

Collagen is a major fibrous protein within extracellular matrix (ECM) with multiple functions. In glaucoma, increase in ECM deposition at the trabecular meshwork leads to aqueous outflow resistance. In previous studies, *trans*-resveratrol (TR) and RU-615 (derivative of imidazo[1,2-a]benzimidazole) reduced the intraocular pressure of steroid-induced ocular hypertensive rats. However, whether this effect is mediated by reduction of ECM deposition is yet to be elucidated. This study aims to investigate the effects of TR and RU-615 on the expression of collagen proteins induced by dexamethasone in the human trabecular meshwork cells (HTMCs).

Methods

Primary HTMCs in passage 5 were incubated with TR and RU-615 with or without dexamethasone (Dexa). The culture media were collected after 7 days for protein measurement using ELISA.

Results

Dexa produced significant upregulation of collagen type I (COLI), collagen type III (COLIII) and collagen type IV (COLIV) proteins compared to vehicle-treated group. TR reduced the Dexa-induced increase in the expression of COLI, COLIII and COLIV

by 11.35, 0.02, 26.66-folds, respectively ($p<0.05$). The same effect of RU-615 amounted to 10.44, 0.02, 26.36-folds, respectively ($p<0.05$).

Conclusion

Treatment with TR and RU-615 reduced the dexamethasone-induced increase in collagen expression by HTMC. The mechanisms leading to these effects of both agents are yet to be elucidated. This study is supported by grant 600-IRMI/FRGS 5/3 (413/2019).

[299 words]

Intraocular Pressure Outcome in Pediatric Glaucoma : A Case Series

[Alaydrus S¹](#), Ekowati L, Novitasari A

¹Perdami Jawa Tengah, Semarang, Indonesia

Introduction

The goal of treating pediatric glaucoma is achieved best by controlling intraocular pressure (IOP), measuring IOP is the cornerstone of a comprehensive glaucoma examination even for primary glaucoma congenital. Aim of this case series was to present intraocular pressure outcome in cases of primary congenital glaucoma.

Methods

This study was retrospective with descriptive approach and conducted from January 2020 until July 2021. Samples were noted from medical records. All patients aged under 18 years with glaucoma were included. Glaucoma was established based on history taking, ophthalmology examination (visual acuity, IOP, blue sclera, megalocornea, Haab striae, corneal edema) and other examinations (funduscopy and USG B-scan). IOP were measured using Tonometry Schiottz before surgery, one day, one-week, one-month and three-months after surgery, respectively.

Results

A total of eight cases were included. The patients were four congenital glaucoma, two juvenile glaucoma and two were secondary glaucoma, aged between 1 month–14 years (mean 2.92). Five patients (62.5%) were treated with trabeculectomy and trabeculotomy followed by iridectomy, only three patients (37.5%) were treated with GDD implant. IOP before surgery was ranged from 27.2–50.6 mmHg (mean 37.03 mmHg) and decreased in 3 months after surgery with ranged from 10.08–18.5 mmHg (mean 13.46 mmHg).

Conclusion

All pediatric glaucoma patients have IOP improvement in three months after

surgery with varying values depending on each patients.

References

1. Giangiacomo A, Beck A. Pediatric glaucoma: review of recent literature. *Curr Opin Ophthalmol*. 2017;28(2):199-203.
2. Fayed MA, Chen TC. Pediatric intraocular pressure measurements: Tonometers, central corneal thickness, and anesthesia. *Surv Ophthalmol*. 2019;64(6):810-825. doi:10.1016/j.survophthal.2019.03

Glaucoma Impact on Quality of Life: What We Know?

[Alberta](#)¹, Sarsono M¹, Kuswidyati C²

¹Faculty Of Medicine, Atma Jaya Catholic University Of Indonesia, Jakarta Utara, Indonesia, ²Department of Ophthalmology, Atma Jaya Hospital, Jakarta, Jakarta Utara, Indonesia

Introduction

Glaucoma is a chronic eye disease that requires continuous and long-term use of topical drugs. The main goal of glaucoma treatment is to prevent vision loss. Clinical signs might be found even with good compliance; have we ever thought of other aspects that contribute to patients' quality of life (QoL)?

Methods

This study reviews articles about the impact of glaucoma on patients' QoL. We include full text studies, published in the last 10 years.

Results

Glaucoma affects visual quality by visual impairment, visual fields, and color contrast sensitivity ($p<0.005$). The psychological effects come from fear of blindness, fear of being a family burden, anxiety, and depression ($p<0.05$). The long term management can affect treatment compliance and arise side-effects from cumulative use of anti-glaucoma drugs ($p<0.05$). The economic burden occurs directly by cost of treatment and indirectly by absenteeism ($p<0.05$).

Conclusion

Glaucoma affects quality of life significantly through visual, psychological, long-term treatment, and economic burdens. Clinicians need to be vigilant and aware of each patient's well-being and functionality.

References

1. Pelfcifa G, et al. Glaucoma, depression and quality of life: multiple comorbidities, multiple assessments and multidisciplinary plan treatment. *Psychiatr Danub*. 2017 Sep;29(3):351-359.
2. Dhawan M, et al. Evaluation of vision-related quality of life in patients with glaucoma: A hospital-based study. *J Curr Glaucoma Pract*. 2019;13(1):9-15.
3. Huang W, et al. The adverse impact of glaucoma on psychological function and daily physical activity. *J Ophthalmol*. 2020 Apr;2020:9606420.
4. Lazcano-Gomez G, et al. Cost of glaucoma treatment in a developing country over a 5-year period. *Medicine (Baltimore)*. 2016 Nov;95(47):e5341

Glaucoma Treatment Modalities by Race

Allison K¹, Sadhra H

¹Flaum Eye Institute, University of Rochester, Hewlett, United States

Introduction

Glaucoma was estimated to affect 52.7 million people in 2020, with current experts anticipating this number to rise to 79.8 million by 2040.¹ Researchers have found that of any racial group, Black individuals had the highest prevalence rate of POAG at 3.4% as compared with White individuals at 1.7%.² To our knowledge, few studies exist that compare the effectiveness of different treatment modalities may vary by race. Our literature review identifies studies since that evaluated how response to various glaucoma treatment modalities may differ by race.

Methods

This literature review searched clinical trials from the year 2000 to 2022 on PubMed using MeSH terms used to identify relevant clinical trials. Terms included “Glaucoma, treatment outcome, therapy, laser therapy, ophthalmic solutions, ophthalmologic surgical procedures.” MeSH Terms used to identify trials that focused on race as outcome were “racial groups and race factors.” We excluded studies conducted outside the United States.

Results

Of the 50 PubMed query results, we identified that studied medication, laser, or surgical treatments in the context of race (Figure 1). In black individuals, 3 studies found prostaglandins were superior compared to beta-blockers for reducing IOP, while one study found no difference. One study found that sequence of laser and surgical treatments yielded different results in black patients when compared to white patients. Only 1 study compared medication, laser, and surgery finding no difference between race. 25% were African American when considering studies that compared different racial groups. (Figure 2).

Conclusion

Glaucoma occurs five times more often in African American individuals, causes blindness six times more often, and has an earlier onset by 10 years compared to other ethnic populations.³ To understand the best way address this growing need, more studies with higher representation of African American individuals are needed comparing laser and surgical treatment options.

References

1. Weinreb, R. N., Aung, T., & Medeiros, F. A. (2014). The pathophysiology and treatment of glaucoma. *JAMA*, 311(18), 1901.
<https://doi.org/10.1001/jama.2014.3192>
2. U.S. Department of Health and Human Services. (n.d.). *Glaucoma data and statistics*. National Eye Institute. Retrieved April 12, 2022, from <https://www.nei.nih.gov/learn-about-eye-health/resources-for-health-educators/eye-health-data-and-statistics/glaucoma-data-and-statistics>
3. Katz, Joanne, and David S Friedman. "African Americans and Glaucoma." *Glaucoma Research Foundation*,
<https://www.glaucoma.org/glaucoma/african-americans-and-glaucoma.php#:~:text=Blindness%20from%20glaucoma%20is%20about,two%20years%20after%20age%2035>.

Figure 1: Literature Review Flow Diagram

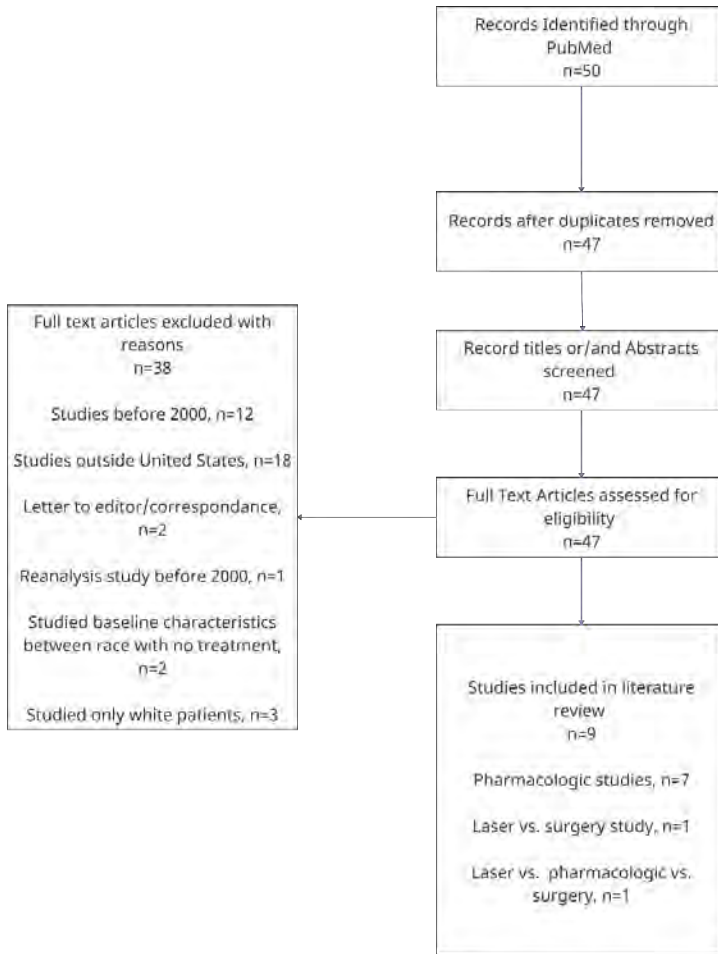


Figure 2: Literature Review Studies Racial Makeup

Study Name, Author, Year	Type of study	Americans exclusively?	Sample size (Patients)	Black/African American studied (if applicable)
Pharmacologic (7 studies)				
Bimatoprost 0.03% versus travoprost 0.004% in black Americans with glaucoma or ocular hypertension. Noecker, 2003	Randomized, investigator masked, multicentre study	Yes	31	31 (100%)
Comparing bimatoprost and travoprost in black Americans. Noecker, 2006	Prospective, randomized, investigator-masked trial	Yes	94	94 (100%)
The effect of latanoprost compared with timolol in African American, Asian, Caucasian, and Mexican open-angle glaucoma or ocular hypertensive patients. Hedman, 2002	Systematic review	No	268	64 (24%)
Efficacy of latanoprost and timolol maleate in black and white patients. Kitnarong, 2004	Double-masked, randomized, 2-period crossover study	No	22	11 (50%)
Projected impact of travoprost versus both timolol and latanoprost on visual field deficit progression and costs among black glaucoma subjects. Halpern, 2002	Double-masked randomized, four-arm study	Yes	132	132 (100%)
Response to travoprost in black and nonblack patients with open-angle glaucoma or ocular hypertension. (2 trials), Netland, 2003	Prospective, controlled, multicentre, double-masked studies	No	594	63 (11%)
			787	177 (22%)
Comparison of initial intraocular pressure response with topical beta-adrenergic antagonists and prostaglandin analogues in African American and white individuals in the Ocular Hypertension Treatment Study. Mansberger, 2007	Multicenter, randomized clinical trial	No	536	134 (25%)
Laser vs. Surgical Treatments (1 study)				
The Advanced Glaucoma Intervention Study (AGIS): 13. Comparison of treatment outcomes within race: 10-year results. Ederer, 2004	Randomized controlled trial	No	581	331 (57%)
Laser vs. Pharmacologic vs. Surgical (1 study)				
Impact of treatment strategies for open angle glaucoma on intraocular pressure: the RIGOR study	Prospective observational study	No	1977	394 (20%)
		Sum of all studies	5972	1431 (24%)
		Sum of all studies comparing different race groups	4796	1176 (25%)

Unique Roberts syndrome presentation with bilateral congenital glaucoma in a Saudi Baby; a case report

Almulhim A¹, Osman E¹, Alsirrhy E¹, AlMoallem B¹

¹Department of Ophthalmology, College of Medicine, King Saud University, Riyadh, Saudi Arabia

Introduction

We are presenting a rare case of one week old baby with Roberts syndrome associated with bilateral congenital glaucoma (Figure 1), general body system examination within normal limits except left-hand rudimentary digits (Figure 2) and right ectopic kidney (Figure 3). Bilateral non-penetrating glaucoma surgery done with good control of intraocular pressure for more than six months.

Method

Case report.

Results

Non penetrating Deep Sclerectomy plus Mitomycin C was performed for both eyes and intraocular pressure was stable for more than 6 months. Molecular analysis showed no abnormality. To the best of our knowledge, this is the first case reported with phocomelia, bilateral congenital glaucoma, and unilateral ectopic kidney without any detected genetic abnormality.

Conclusion

We recommend full ophthalmic evaluation for any suspected case of Roberts syndrome to rule out any ocular involvement including congenital glaucoma to stave off any potential damage for the eye.

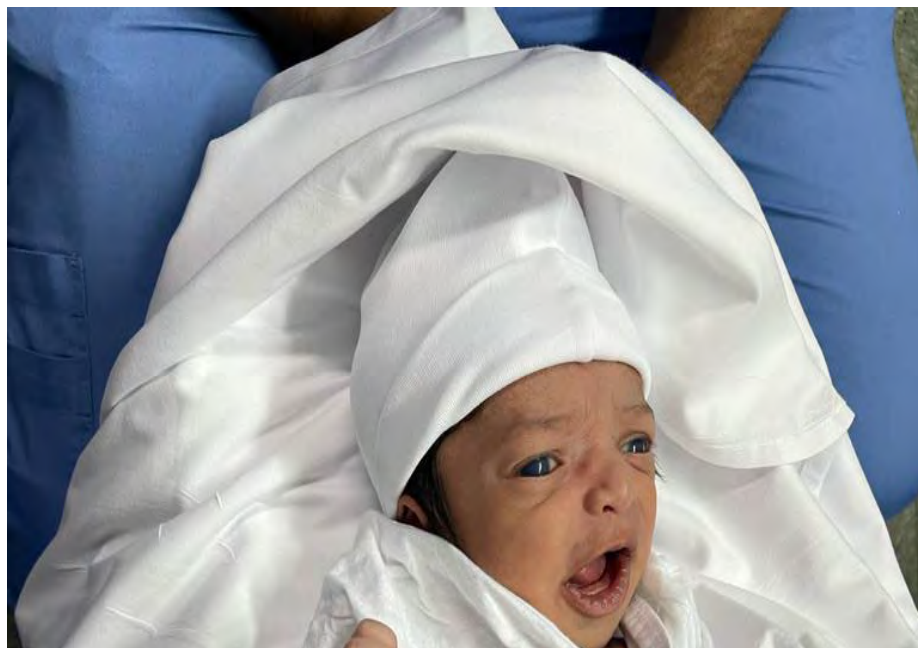

Figure 1: bilateral buphthalmos and corneal haze.

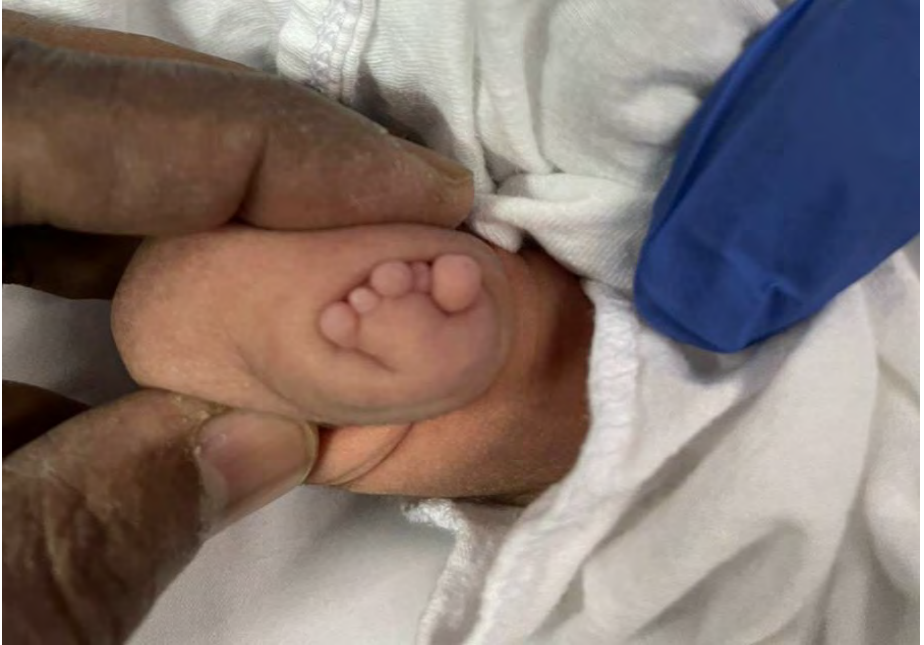

Figure 2: left-hand rudimentary digits.

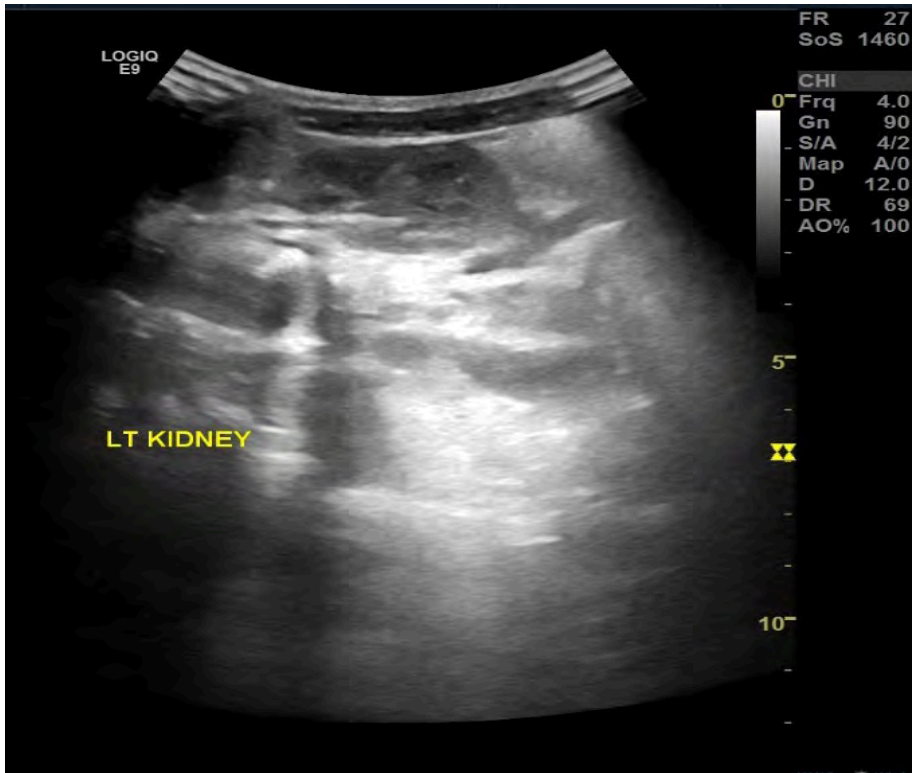


Figure 3: Abdominal ultrasound showed right ectopic kidney located in the ipsilateral pelvic region (instead of the normal location which is the lumbar region).

“Unveiling curtain”, surgical pupilloplasty for iatrogenic updrawn pupil

Alsagoff S¹, Othman O¹, Nasaruddin R¹

¹Pusat Perubatan Universiti Kebangsaan Malaysia, Kajang, Malaysia

Introduction

Pupilloplasty is to change the form of a pupil that doesn't conform to normal pupillary dimensions, and there are several techniques surgeons can use to enhance outcomes for patients, such as laser, cautery or surgical sutures (Pupilloplasty, 2022). Pupil repair is among the foremost rewarding procedures in ophthalmology. This case report is to highlight the novel surgical technique use to correct updrawn pupil.

Methods

Case report

Results

A 54-year-old lady underwent phacoemulsification, complicated with posterior capsule rent requiring conversion to extra-capsular cataract extraction, post operation later patient developed updrawn pupil due to peripheral anterior synechiae that occurs superiorly, the best corrected vision was 1/60. She undergoes surgical pupilloplasty. Intraoperatively the pupil was brought downward using 3 set of double arms prolene sutured in c loop shape created at 3,6 and 9 clock hours. In addition, 2 sphincterotomy was done at 4 and 2 clock hours to enhance the centralization of the pupil. Post operatively patient was well and regain a best corrected vision of 6/12 with no severe complication.

Conclusion

We have shown an effective and cost wise approach of pupilloplasty for updrawn pupil.

References

Pupilloplasty. (2022). Pupilloplasty. *Encyclopedia*, 3–5.

Figures, and illustrations

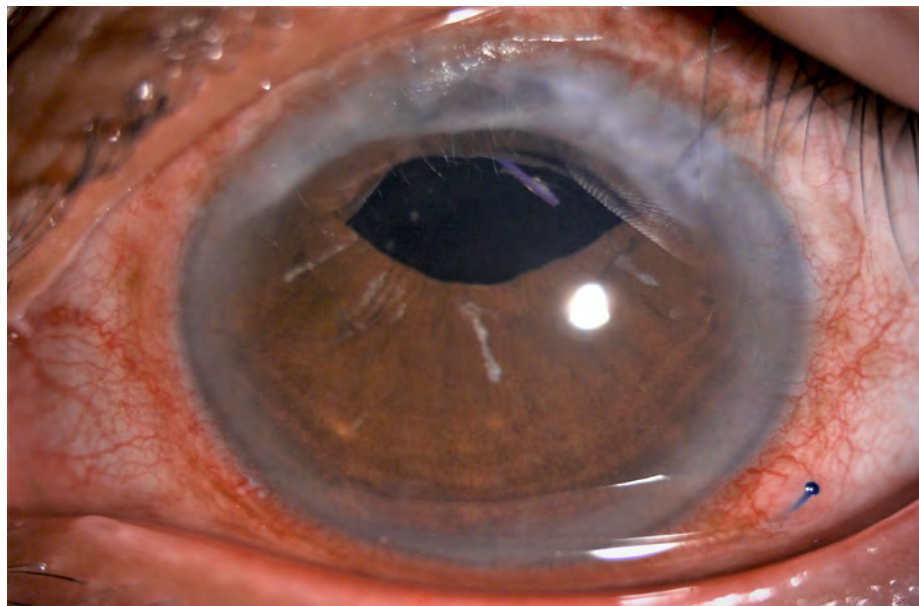


Figure 2. Preoperative. Showing the updrawn pupil.

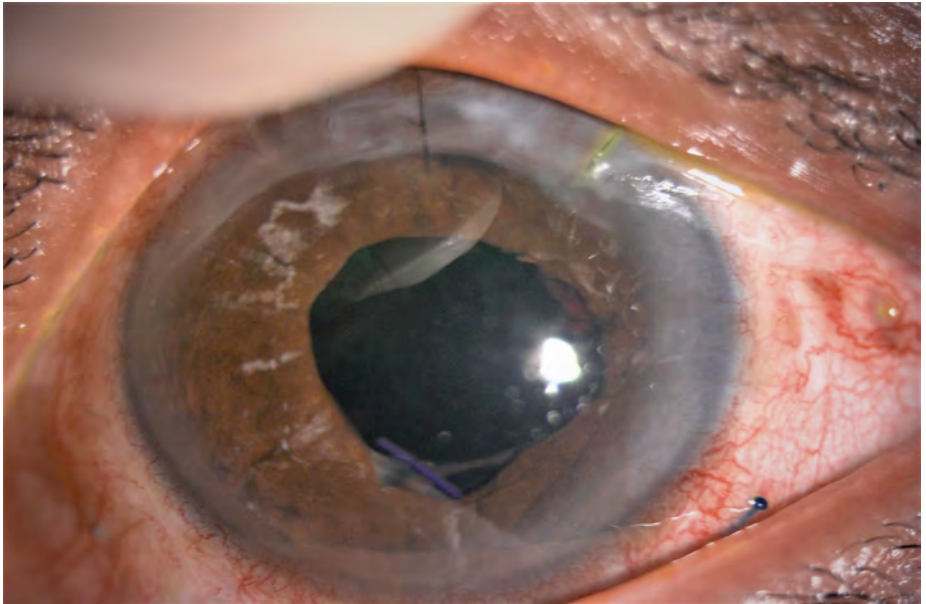


Figure 3. Postoperative. Showing nice and Central pupil.

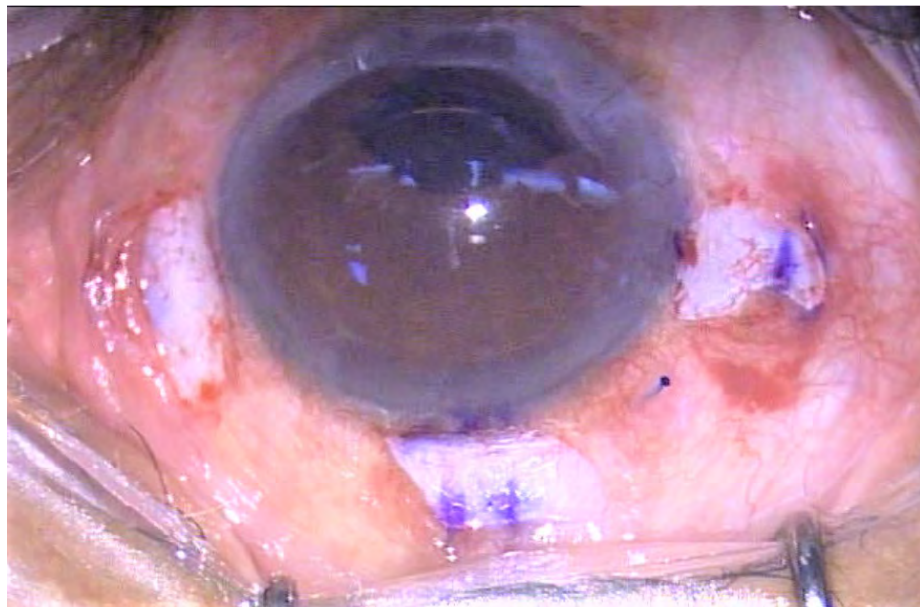


Figure 4. Intraoperative, 3 area of interest was marked.

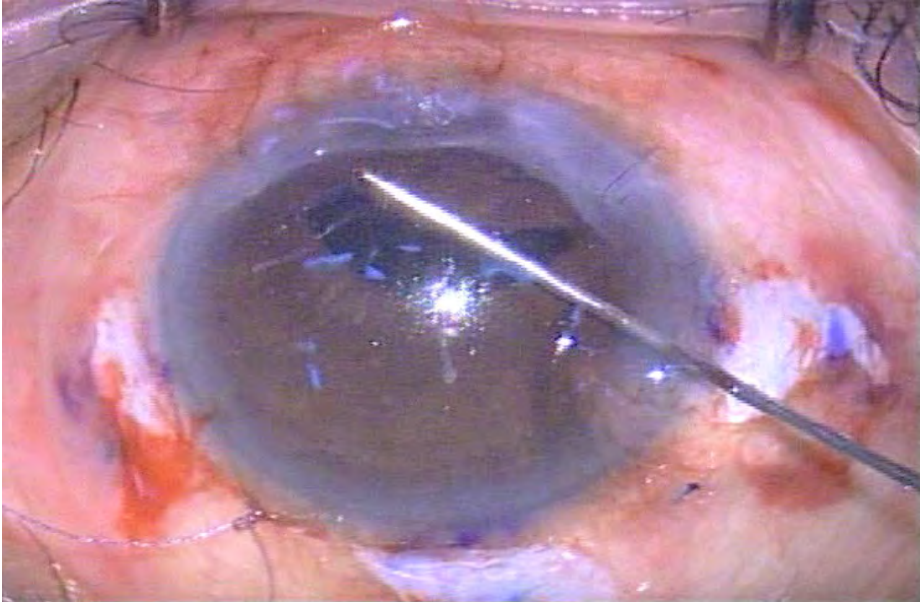


Figure 5. intraoperative, viscoelastic was used to release synechiae

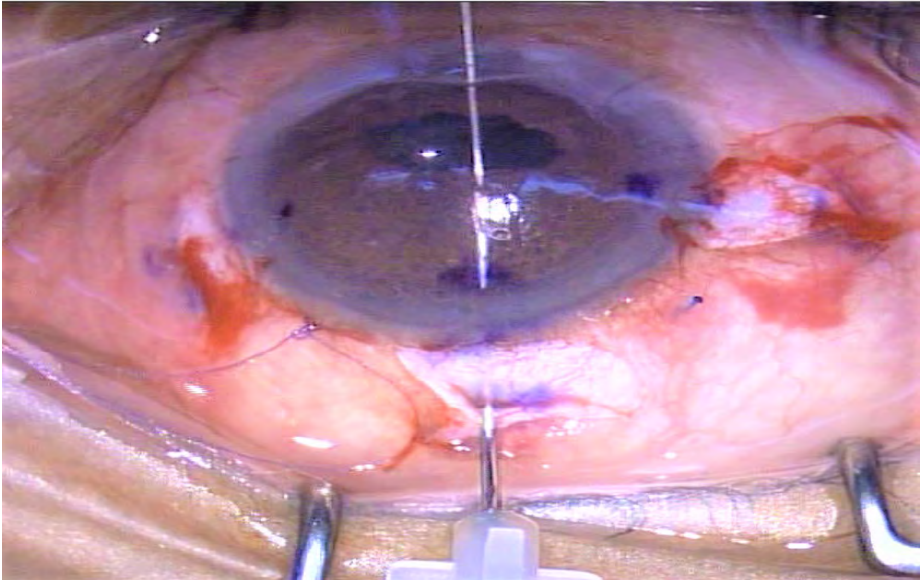


Figure 6. intraoperative, bent needle of 27 G was used to enter the anterior chamber from the pars plana area and received the 10'0 prolene needle. Similar step was repeated for the nasal and temporal part as in Figure 6 and 7.

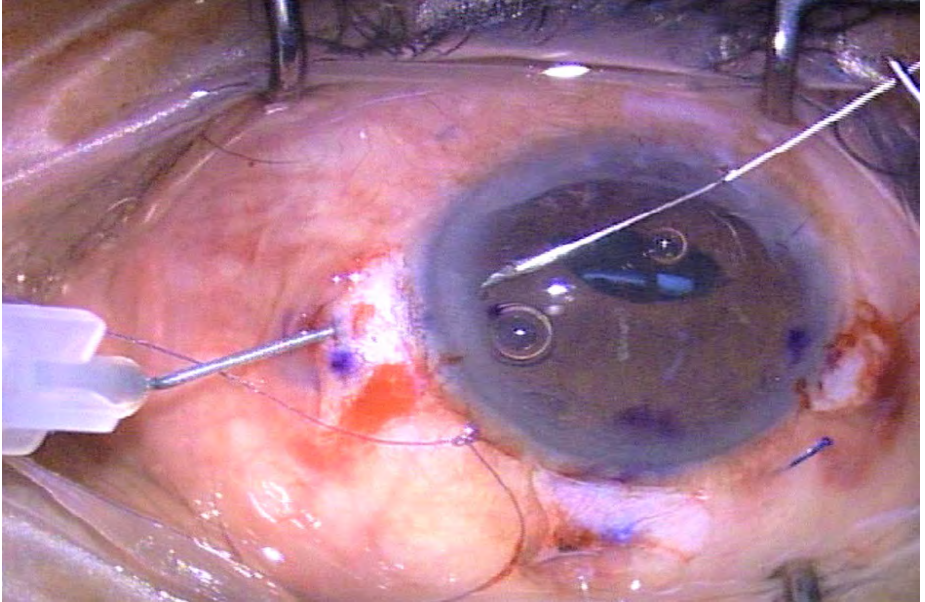


Figure 7

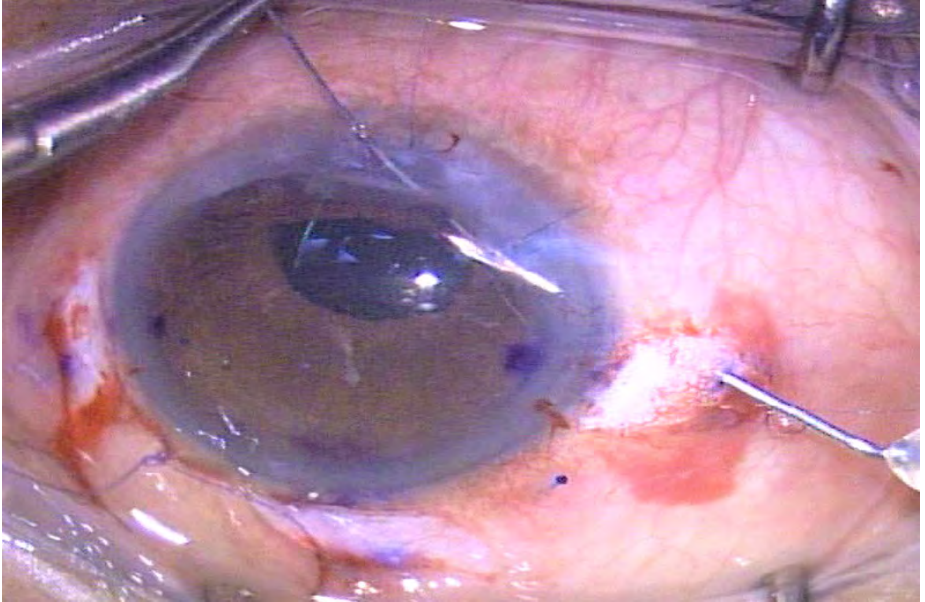


Figure 8

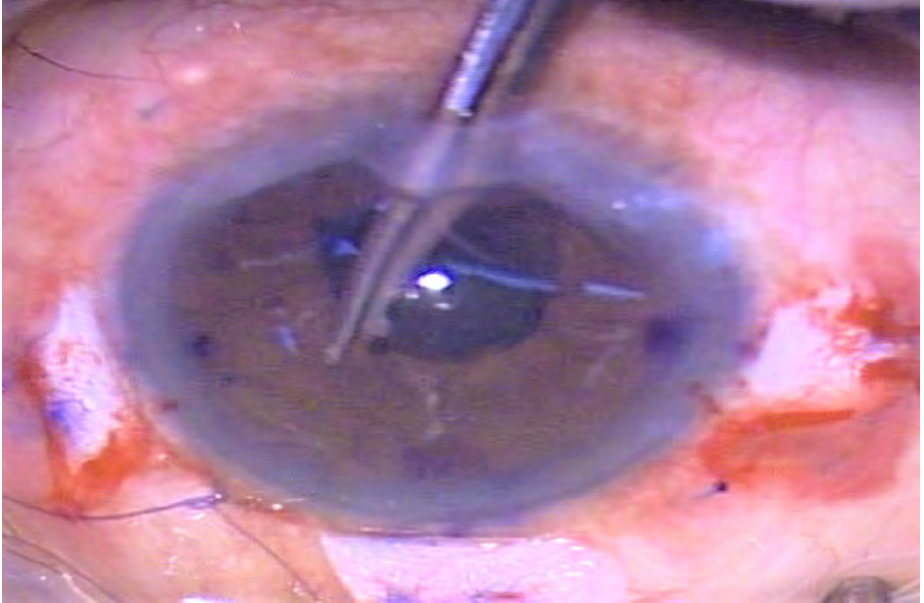


Figure 9. sphincterotomy

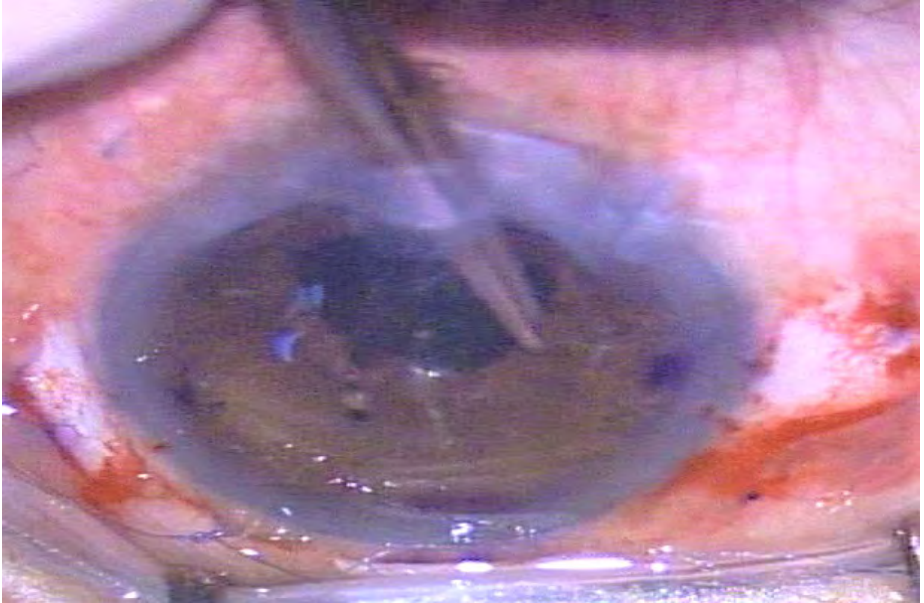


Figure 10. another sphincterotomy

Anterior Segment Imaging in Minimally Invasive Glaucoma Surgery – A Systematic Review

Ang B^{1,2}, Kan J¹, Betzler B³, Lim S⁴

¹Department of Ophthalmology, Tan Tock Seng Hospital, Singapore, Singapore,

²Department of Ophthalmology, Woodlands Health Campus, Singapore,

Singapore, ³Yong Loo Lin School of Medicine, National University of Singapore,

Singapore, Singapore, ⁴Army Medical Services, Singapore Armed Forces, Singapore, Singapore

Introduction

Minimally Invasive Glaucoma Surgery (MIGS) has grown in popularity in recent years. This systematic review explores the pre-, intra- and post-operative application of anterior segment (AS) imaging in MIGS.

Methods

A search across the PubMed, Embase and CINAHL databases was conducted, with inclusion criteria restricted to MIGS that received US Food and Drug Administration (FDA) premarket approval, FDA 510(K) premarket notification, or were listed as a class 1 device exempt from FDA approval or notification.

Results

21 unique studies on MIGS devices, including the XEN45 Gel Stent, Trabectome, iStent Inject, 1st generation iStent and the Kahook Dual Blade (KDB), were identified. AS imaging modalities evaluated included the AS optical coherence tomography (OCT), ultrasound biomicroscopy, aqueous angiography, OCT volumetric scans and in-vivo confocal microscopy. In angle-based MIGS, evaluation of aqueous outflow pathways may aid in pre-operative patient selection. Intra-operatively, AS imaging facilitates visualization of angle anatomy and more precise evaluation of surgical endpoints. In subconjunctival MIGS, AS imaging better delineates implant location and characterizes the post-

implantation structural impact of MIGS devices, facilitating management of bleb scarring. The initial user learning curve, variable quality of images, and optical interference from surgical instruments are current limitations of this technology.

Conclusion

Current literature demonstrates the feasibility of AS imaging application in the pre-, intra- and post-operative phases of angle-based and subconjunctival MIGS. However, further studies are needed to elucidate its impact on surgical outcomes.

References

1. Teus MA, et al. (2019): Optical coherence tomography analysis of filtering blebs after long-term, functioning trabeculectomy and XEN® stent implant. *Graefes Arch Clin Exp Ophthalmol* 257:1005-1011.
2. Junker B, et al. (2017): Intraoperative optical coherence tomography and ab interno trabecular meshwork surgery with the Trabectome. *Clin. Ophthalmol.* 11:1755-1760.

Evaluation of structural and functional changes in Ocular Hypertension (OHT) over time

[Angmo D¹](#), Prakash S¹, Gupta V¹, Dada T¹, P A¹, Mishra S¹, Azad S¹

¹Dr RP Centre for Ophthalmic Sciences, AIIMS, New Delhi, India

Introduction

To evaluate and compare the diagnostic ability of macular ganglion cell complex layer (mGCC) and peripapillary retinal nerve fiber layer (pRNFL) thickness changes on Spectral Domain-Optical coherence tomography (SD-OCT), macular and peripapillary perfusion changes using Optical coherence tomography angiography (OCTA) and Changes in Microperimetry of macula in Ocular Hypertension (OHT).

Methods

56 eyes of 56 OHT patients were examined at baseline, 6mths, 12mths and 18mths. The average thickness of mGCPL and pRNFL on OCT¹ and macular vessel density and peripapillary perfusion and flux index on OCTA using CIRRUSTM HD-OCT (Zeiss) and Microperimetry of central 10 degrees using MAIA² were evaluated.

Results

The mean age was 45.4±8 yrs. The mean baseline IOP (mmHG) was 25.3±2.9. The mean CCT was 547 ±30.4 in OHT. 11.5% (6/56) patients had family history of glaucoma. 15.3% (8/56) patients had systemic history of either diabetes/hypertension. The mean RNFL thickness was 87.69±9.2um at baseline and was 80.7±10.6um at 12mths (p<0.001). The mean GCC thickness was 76.09±9.83um at baseline and 68.00±11.2um at 12mths (p<0.001). The mean macular vessel density was 12.46±4.35 mm/mm² at baseline and 10.93±2.69 mm/mm² at 12mths (p=0.008). The mean ONH perfusion was 43.70±1.76% at baseline and 41.68±1.39% at 12mths (p<0.001). The mean average threshold on Microperimetry at baseline was 24.37±5.15Db and was 22.88±3.68 dB at 12mths (p=0.005). However, on HVF 10-2, the mean MD was -2.61dB at baseline and -2.56dB at 12mths (p=0.72)

Conclusion

The average pRNFL and GCC thickness worsened over time ($p<0.001$). The OCTA parameters and microperimetry also worsened overtime ($p<0.05$). However, HVF 10-2 parameters did not show significant change over time. Therefore, implying that OCT, OCTA and microperimetry are helpful in early detection of progression as compared to HVF.

References

1. King BJ, Swanson WH, Klemencic SA, et al. Assessing the Impact of En Face Retinal Nerve Fiber Layer Imaging on Clinical Decision Making for Glaucoma Suspects. *Optom Vis Sci.* 2020;97(2):54-61. doi:10.1097/OPX.0000000000001479
2. Yusuf IH, Jolly JK, Ratnarajan G, Salmon JF. Microperimetry and optical coherence tomography imaging in the fellow eye of patients with unilateral focal ischaemic glaucoma. *Eye (Lond).* 2018;32(8):1372-1379. doi:10.1038/s41433-018-0094-3

Intraoperative Optical Coherence tomography (iOCT) guided Glaucoma surgery

[Angmo D¹](#), Maddu S¹

¹Dr RP Centre for Ophthalmic Sciences, AIIMS, New Delhi, India

Introduction

iOCT with heads up display (HUD) allows rapid visualization of the area of interest and provides the surgeon with information regarding instrument-tissue interactions. Because of its finer resolution, OCT is able to present detailed view of the bleb wall, sclera and an accurate assessment of the location and extent of the bleb structure. This permits better manoeuvring, better dissection of the anterior and posterior bleb wall under visualization and thereby reducing the risk of complications. We describe iOCT guided glaucoma surgery in different scenarios

A. iOCT guided Bleb Needling [1]

In this procedure we describe how under the direct visualization of iOCT bleb needling is done with minimal tissue damage and post needling resulting in a functional bleb.

B. iOCT guided Bleb sparing epithelial exchange [BSEX][2]

The original procedure as described by Sihota et al[3], in which we remove the tissue showing an abnormality, that is, the epithelium over the bleb, with advancement of the surrounding normal conjunctiva, without any manipulation of the bleb itself. Similar procedure was done under the guidance of iOCT and trypan blue dye to stain the epithelium further aiding in BSEX, this helps in preventing inadvertent damage to bleb structures.

C. iOCT guided Glaucoma drainage device tube insertion

References

1. Dada T, Angmo D, Midha N, Sidhu T. Intraoperative optical coherence tomography guided bleb needling. J Ophthalmic Vis Res 2016;11:452-4.
2. Angmo D, Shakrawal J, Sihota R. Intraoperative Optical Coherence Tomography-Guided Bleb-sparing Epithelial Exchange: A Modified Approach. J Ophthalmic Vis Res 2021;16:1–7.
3. Sihota R, Angmo D, Sen S, Gupta V, Dada T, M. Pandey R. The Long-term Outcome of Primary “Bleb-sparing, Epithelial Exchange” in Dysfunctional Filtering Blebs J Glaucoma 2016;25:571–578

One-year retrospective analysis of retinal nerve fiber layer of glaucoma patients in Yogyakarta

[Angsana N¹](#), Ekantini R, Gani T, Jati K

¹Universitas Gadjah Mada, Sleman, Indonesia

Introduction

Retinal nerve fiber layer (RNFL) measurement is clinically important because RNFL thinning precedes visual field loss in glaucoma. Optical Coherence Tomography (OCT) provides an objective measurement of optic disc and RNFL. This study aims to analyse the RNFL measurement and the correlation between age, sex, refractive error, and RNFL thickness of Indonesia's glaucoma patients.

Methods

A retrospective cross-sectional medical record review at Dr. Sardjito General Hospital, Yogyakarta conducted in 2021. The subjects were all patients who were diagnosed with glaucoma by the ophthalmologist and had met the inclusion and exclusion criteria. One randomly selected eye per subject was used. The RNFL thickness was measured by Zeiss Cirrus HD-OCT 5000.

Results

The total subjects were 436 glaucoma patients from 9 to 82 years of age. Female subjects were 259 (59.40%) and males 177 (40.60%). The lowest RNFL average thickness was found in primary angle closure glaucoma (PACG) (76.26 ± 22.27). The RNFL thickness was associated with age in normal tension group ($r_s = -0.2601$, $p = 0.0023$) and high tension group ($r_s = -0.3573$, $p = 0.0000$). The difference between male and female RNFL thickness in normal tension group is not statistically significant ($p = 0.4344$), but significant in high tension group ($p = 0.0054$). The refractive error was not associated with RNFL thickness in normal tension group ($r_s = 0.0559$, $p = 0.5199$) and high tension group ($r_s = -0.0660$, $p = 0.2533$).

Conclusion

The thinnest RNFL average was found in PACG patients. Thinner RNFL was associated with older age in both normal tension and high tension group. There was no significant correlation between refractive error and RNFL thickness in both normal tension and high tension group.

References

1. Kim NR, Lee ES, Seong GJ, Choi EH, Hong S, Kim CY. Spectral-domain optical coherence tomography for detection of localized retinal nerve fiber layer defects in patients with open-angle glaucoma. *Arch Ophthalmol*.2010;128(9):1121-1128. doi:10.1001/archophthalmol.2010.204
2. Lamirel C. Optical coherence tomography. In: Aminoff MJ, Daroff RB, eds. *Encyclopedia of The Neurological Sciences*.2nd 2 2nd ed. Elsevier; 2014:660-668.s

Tables, figures, and illustrations

Table 1. Patient demographics

Parameter			Total
Total Patient			436
Age (year, Mean \pm SD)			44.10 \pm 18.92
Sex	Male		177 (40.60%)
	Female		259 (59,40%)
Diagnosis	Normal Tension	NTG	
			135 (30.96%)
	High Tension	POAG	190 (43.58%)
		PACG	38 (8.72%)
		JOAG	43 (9.86%)
		SACG	7 (1.61%)

SOAG

23 (5.28%)

BCVA (decimals, Mean \pm SD)0.71 \pm 0.34IOP (mmHg, Mean \pm SD)14.72 \pm 6.34RNFL thickness (μ m, Mean \pm SD)90.10 \pm 20.88

Note: NTG: normal tension glaucoma, POAG: primary angle glaucoma, PACG: primary angle closure glaucoma, JOAG: juvenile open angle glaucoma, SOAG: secondary open angle glaucoma, SACG: secondary angle closure glaucoma, BCVA: best corrected visual acuity, IOP: intraocular pressure, RNFL: retinal nerve fiber layer

OCT Parameter	Glaucoma Group					
	POAG (Mean \pm SD)	NTG (Mean \pm SD)	PACG (Mean \pm SD)	JOAG (Mean \pm SD)	SOAG (Mean \pm SD)	SACG (Mean \pm SD)
Average						
RNFL						
thickness	88.49 \pm	96.17 \pm	76.26 \pm	95.44 \pm	92.65 \pm	76.71 \pm
(μ m)	19.91	15.49	22.27	21.99	22.41	17.74
RNFL						
symmetry	58.13 \pm	73.98 \pm	41.54 \pm	77.76 \pm	67.90 \pm	37.25
(%)	35.93	28.52	31.47	25.82	27.66	\pm 66.81
Rim area	1.07 \pm	1.18 \pm	0.93 \pm	1.23 \pm	1.30 \pm	0.96 \pm
(mm ²)	0.42	0.29	0.46	0.38	0.59	0.47
Disc area	2.27 \pm	2.30 \pm	2.27 \pm	2.27 \pm	2.07 \pm	1.64 \pm
(mm ²)	0.50	0.45	0.51	0.65	0.55	0.20
Vertical C/D	0.66 \pm	0.64 \pm	0.67 \pm	0.62 \pm	0.58 \pm	0.56 \pm
ratio	0.18	0.10	0.25	0.17	0.20	0.31
Clock hours	37.74 \pm	48.89 \pm	118.42 \pm	153.49 \pm	65.22 \pm	111.43 \pm
(degrees)	75.60	79.44	91.99	121.63	98.94	78.83

Table 2. Retinal Nerve Fiber Layer (RNFL) Measurement using Cirrus HD-OCT

Note: one clock hour represents 30 degrees RNFL defect areas.

Table 3. The correlation between Age and RNFL Thickness Measurement in Normal Tension and High Tension Group

Glaucoma Group	Parameter	Mean \pm SD	Correlation Coefficient (r_s)	P-value
Normal Tension	RNFL Thickness (μm)	96.17 \pm 15.49	-0.2601	0.0023*
	Age (year)	39.65 \pm 17.65		
High Tension	RNFL Thickness	87.98 \pm 21.26	-0.3573	0.0000*
	Age (year)	46.05 \pm 19.16		

*statistically significant $p < 0.05$

Table 4. The Comparison of Sex towards RNFL Thickness Measurement in Normal Tension and High Tension Group

Glaucoma Group	Sex	Number of patients	RNFL Thickness (mean \pm SD)	P-value
Normal Tension Group	Male	54	94.69 \pm 1.93	0.4344
	Female	81	97.16 \pm 1.81	
High Tension Group	Male	123	83.93 \pm 1.93	0.0054*
	Female	178	90.79 \pm 1.55	

*statistically significant $p < 0.05$

Table 5. The Correlation between Refractive Error and RNFL Thickness Measurement in Normal Tension and High Tension Group

Glaucoma Group	Parameter	Mean ± SD	Correlation Coefficient (r_s)	P-value
Normal Tension	RNFL Thickness (μm)	96.17 ± 15.49	0.0559	0.5199
	Spherical equivalent refraction (diopetre)	-1.53 ± 5.62		
High Tension	RNFL Thickness (μm)	87.98 ± 21.26	-0.0660	0.2533
	Spherical equivalent (diopetre)	-0.66 ± 2.03		

5-year Outcomes of XEN 45 gel stent in primary open angle glaucoma

Ansari E¹

¹Maidstone & Tunbridge Wells NHS Trust, Maidstone, United Kingdom, ²Institute of Medical Science, Christ Church Canterbury University, Canterbury, UK

Introduction

The rapid uptake of MIGs technologies for surgical treatment of glaucoma has outpaced their assessment particularly in the long-term. For a chronic, progressive disorder such as glaucoma, durability of any treatment is important. Studies of XEN gel stent have been conducted up to 3 years so far ¹⁻⁴. This is the first 5-year study of the efficacy and safety of XEN gel stent in advanced cases of POAG.

Methods

Single centre, single surgeon retrospective case notes review of 90 consecutive OAG patients who underwent ab-interno gel stent placement combined with phacoemulsification. Surgeries were performed between 2014 and 2016. Primary outcome measures: mean reduction in intraocular pressure (IOP) and change in number of ocular hypotensive medications from baseline through to 5 years. Secondary outcome measure: change in visual field mean deviation (VFMD) through to 5 years. Safety data included intraoperative and post-operative complications and adverse events. Failure rate was defined by the need for further laser or surgical intervention.

Results

Text: 90 eyes were included (table 1). Mean (SD) IOP and medications decreased from 20.1 (6.5) mmHg and 2.8 (1.0) at baseline to 15.6 (3.7) mmHg and 2.5 (1.4) medications (n = 32) at 5 years. Mean change from baseline IOP and medications were statistically significant at all time points through to 5 years (figure A). There was a statistically significant change in VFMD through to 5 years (mean reduction of 1.4dB over 5 years). Fifteen (7.1%) eyes had intraoperative complications, 11

(12.2%) experienced postoperative AEs, and 9 (10%) required secondary surgical intervention (SSI).

Conclusion

The Xen 45 gel stent combined with phacoemulsification was effective in reducing IOP and medications over 5 years, with a satisfactory safety profile. Visual field change was clinically acceptable through to 5 years. There were no cases of visual loss >2 lines of Snellen acuity.

References

1. Reitsamer H, Sng C, Vera V, et al (2019): Two-year results of a multicenter study of the ab interno gelatin implant in medically uncontrolled primary open-angle glaucoma. *Graefes Arch Clin Exp Ophthalmol* 257: 983–996.
2. Gabbay IE, Allen F, Morley C, et al (2020): Efficacy and safety data for the XEN45 implant at 2 years: a retrospective analysis. *Br J Ophthalmol* 104: 1125–1130.
3. Gillmann K, Bravetti GE, Rao HL, et al (2020a): Combined and stand-alone XEN 45 gel stent implantation: 3-year outcomes and success predictors. *Acta Ophthalmol*. <https://doi.org/10.1111/aos.14605>.
4. Reitsamer H, Vera V, Ruben S, et al. Three-year effectiveness and safety of the XEN gel stent as a solo procedure or in combination with phacoemulsification in open-angle glaucoma: a multi-centre study. *Acta Ophthalmologica* 2021; 100(1): e233-e245 DOI: [10.1111/aos.14886](https://doi.org/10.1111/aos.14886) PMID: 33973370

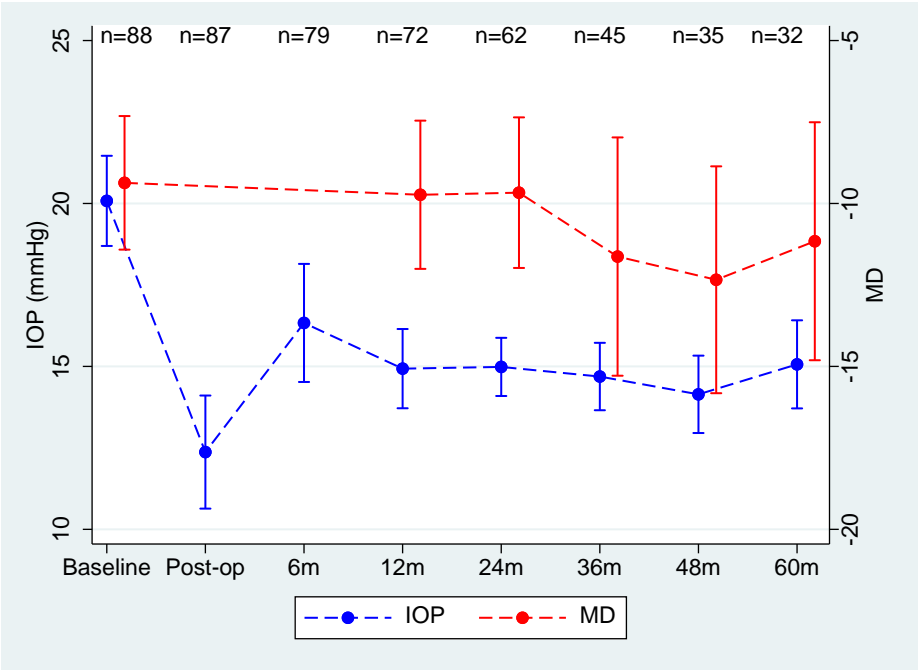
Table 1: Demographic and baseline summaries

Variable	N. eyes	Category	Summary
Age at procedure	87	-	75.5 ± 12.1 {26.4, 92.4}
Eye	89	Left Right	42 (47%) 47 (53%)

Vision (decimalised Snellen)	baseline	86	-	0.68 ± 0.26 {0.05, 1.20}
IOP baseline (mmHg)		88	-	20.1 ± 6.5 {8, 38}
Visual Field baseline		64		-9.4 ± 8.2 {-33.2, 0.1}
Number meds. pre-op		88	-	2.8 ± 1.0 {0, 5}

Summary statistics are mean \pm standard deviation {range}, or number (percentage)

Figure A: Mean (95% CI) IOP and MD over time



Early Glaucoma Surgery Outcomes in Dr. Kariadi General Hospital during the COVID-19 Pandemic

Arlanbi N¹, Maharani², Puspasari D², Rahmi F²

¹Medical Faculty of Diponegoro University, Semarang, Indonesia, ²Ophthalmology Department of Diponegoro University, Dr.Kariadi Hospital, Semarang, Indonesia

Introduction

This study aimed to investigate the early glaucoma surgery outcomes during the pandemic era at one of Indonesia's tertiary referral centre, Dr.Kariadi Hospital.

Methods

This was a retrospective, observational study of glaucoma surgery outcomes on postoperative days 1 and 7 from March 2020 to September 2021. The intraocular pressure (IOP), visual acuity (VA), cup disc ratio (CDR), and early complications were assessed.

Results

Out of 312 patients, 107 (34.3%) had trabeculectomy, 128 (41%) had phacotrabeculectomy, 53 (17%) had phacoemulsification, and 24 (7.3%) had glaucoma drainage device (GDD) implantation. Preoperative IOP in the trabeculectomy group was 34.19 ± 12.13 mmHg, 9.72 ± 7.02 mmHg on day 1, and 13.02 ± 11.3 mmHg on day 7. Preoperative IOP in the phacotrabeculectomy group was 31.71 ± 12.01 mmHg, 12.8 ± 7.4 mmHg on day 1, and 14.32 ± 1 mmHg on day 7. Preoperative IOP in the GDD group was 31.58 ± 8.34 mmHg, 11.56 ± 8.72 mmHg on day 1, and 14.86 ± 10.22 mmHg on day 7. The phacoemulsification group had stable IOP pre and postoperatively. The phacoemulsification and phacotrabeculectomy groups had increased VA. The CDR remained stable in all groups. The early complications included hyphema, shallow anterior chamber, hypotony, bleb leakage, retinal hemorrhage, and tube iris touch.

Conclusion

Trabeculectomy, phacotrabeculectomy, and GDD implantation appeared to have good outcomes in decreasing IOP in the early phase. Long-term follow-up is recommended.

References

1. American Academy of Ophthalmology. Glaucoma Basic and Clinical Science Course.2020
2. Holland L, Kirwan J, Mercieca K. Effect of COVID-19 pandemic on glaucoma surgical practices in the UK. British Journal of Ophthalmology.2021;1-5.

Risk Factors for Tube Exposure as a Complication of Glaucoma Drainage Devices

Arsianti E¹

¹Dr YAP Eye Hospital, Yogyakarta, Indonesia

Introduction

Glaucoma drainage implant exposure is one of the serious complications arising after glaucoma drainage devices (GDD) surgery. This study aims to evaluate the risk factors for tube exposure after the implantation of GDD at “Dr YAP” Eye Hospital, Yogyakarta, Indonesia

Methods

This is a retrospective review of the medical record of all patients who underwent all types of GDD such as Ahmed, AADI and Virna implant with tubes covered by various types of patch graft materials between January 1, 2018 to June 30, 2021 with a six-months follow-up after surgery.

Results

Of the 67 patients having GDD surgery, 9 patient experienced exposure of tube devices. The average time to exposure was 11.78 ± 9.23 month. Of the patients with tube exposure, four patients had secondary glaucoma, one had congenital glaucoma and five had neovascular glaucoma. The mean age of patients with GDD is 51.82 ± 15.06 yo. There were no significant differences between the variants in this study. However, in terms of gender, men were more likely than women to experience exposure of GDD (OR 2.8 (95% CI 0.54-14.87)). Furthermore, disease history of stroke was also associated with increased risk of GDD exposure (OR 3.5 (95% CI 0.28-43.16)).

Conclusion

Men are more than two times more likely to experience GDD exposure than women. Stroke is also included as a risk factor for GDD tube exposure

References

1. Budenz DL, Feuer WJ, Barton K, Schiffman J, et al. Postoperative complications in the Ahmed Baerveldt comparison study during five years of follow-up. *Am J Ophthalmol.* 2016;163:75–82.
2. Ayaka Edo, Koji Jian, Yoshiaki Kiuchi, Risk Factors for Exposure of Baerveldt Glaucoma Drainage Implants: a case control study, 2020 20-364.

Neovascular glaucoma from ocular ischemic syndrome treated with a combination of monthly intravitreal bevacizumab and panretinal photocoagulation

Asif H¹, Si Z¹, Quan S¹, Amin P¹, Dao D¹, Shaw L¹, Skondra D¹, Qiu M¹

¹University of Chicago Department of Ophthalmology and Visual Sciences, Chicago, United States

Introduction

While many studies show advantages in combining panretinal photocoagulation (PRP) with anti-vascular endothelial growth factor (VEGF) injections to treat neovascular glaucoma (NVG), there is little data regarding this combination on NVG secondary to ocular ischemic syndrome (OIS). This report of a patient with NVG secondary to OIS treated with a combination of anti-VEGF and PRP demonstrates that combination of treatment can lead to good outcomes.

Methods

Case report of a patient with NVG secondary to OIS treated with monthly anti-VEGF injections and PRP sessions interspersed.

Results

A 66-year-old man presented with an intraocular pressure (IOP) of 42 mmHg and anterior segment neovascularization OD. As shown in Table 1, he was treated with a first course of six monthly anti-VEGF injections interspersed with four PRP sessions, a second course of four monthly injections and four PRP sessions, and a third course of ongoing monthly injections. His IOP normalized and anterior segment neovascularization regressed at the end of the first two courses, but despite a total of over 4,000 spots of PRP, his eye had two recurrences of elevated IOP and neovascularization when it did not undergo an anti-VEGF injection for more than one month.

Conclusion

In patients with NVG secondary to OIS, monthly anti-VEGF injections may be necessary in combination with PRP to suppress neovascular drive, regress anterior segment neovascularization, and maintain physiologic IOP.

References

Ehlers JP, Spirn MJ, Lam A, Sivalingam A, Samuel MA, Tasman W. Combination intravitreal bevacizumab/panretinal photocoagulation versus panretinal photocoagulation alone in the treatment of neovascular glaucoma. *Retina*. 2008 May;28(5):696-702. doi: 10.1097/IAE.0b013e3181679c0b. PMID: 18463512.

Table 1: Details of Anti-Neovascular and Intraocular Pressure Treatment Course					
Weeks presentation	After	Treatment	IOP (mmHg)	# Meds	Service(s)
First Course					
0		IVB #1	42	0	O-> G -> R
1		None	9	3	G
4		IVB #2	10	2	R
5		None	10	2	G
6		PRP #1 (1118 spots, 225mW)	19	0	R
8		IVB #3	19	0	R
10		PRP #2 (596 spots, 275mW)	21	0	R
12		IVB #4	17	0	R
14		PRP #3 (193 spots, 225mW)	N/A	0	R

16	IVB #5	14	0	R
20	IVB #6	15	0	R
22	PRP #4 (462 spots, 200mW)	N/A	0	R
24	None	19	0	G
Second Course				
30	IVB #1	22	0	G -> R
31	PRP #1 (322 spots, 375mW)	16	0	R
34	IVB #2	16	0	R
35	PRP #2 (411 spots, 200mW)	13	0	R
38	IVB #3	10	0	R
40	PRP #3 (560 spots, 200mW)	N/A	0	R
42	IVB #4	18	0	R
46	PRP #4 (866 spots, 200mW)	22	0	R
48	None	20	0	G
Third Course				
52	IVB #1	27	0	R
54	None	14	1	G
56	IVB #2	13	0	R
Future	Ongoing serial monthly IVB			

IVB: Intravitreal bevacizumab 1.25mg in 0.05ml. PRP: Panretinal photocoagulation.

O: Optometry, G: Glaucoma, R: Retina

Spot size for PRP was 400 microns in first course of treatment and 200 microns in 2nd course of treatment. Duration was 0.5-0.7 seconds.

Variations in the Sub-foveal Choroidal thickness in primary open-angle glaucoma patients treated with prostaglandins analogues

Ausin-gonzalez E¹, Pana I², Quijada Angeli S¹, Colas T¹, Martin Herrero A¹

¹Hospital Universitario infanta Leonor, Madrid, Spain, ²Hospital Universitario Puerta de Hierro, Majadahonda, Spain

Introduction

Compare the macular Sub-foveal choroidal thickness (SFCT) in primary open angle glaucoma (POAG) patients before and after having being treated with topical prostaglandin analogues (PGs) using swept source optical coherence tomography (SS-OCT).

Methods

27 eyes with POAG treated with topical PGs. For functional evaluation, we use mean deviation (MD) obtained with Humphrey perimeter® (Carl Zeiss, Meditec, Inc.). Horizontal and vertical scans were obtained, of foveal choroid measuring SFCT from the posterior edge of the retinal pigmentary epithelium to the choroidal-scleral interface. Three determinations were performed at successive points 1000 µm nasal, five determinations temporally, superiorly and inferiorly to the fovea each one separated by 1000 µm. Two independent observers measured the SFCT. The follow-up was performed every six months for one year after discontinuing the topical treatment with PGs and changes in SFCT were measured.

Results

Mean age was 65±10 years. Mean pachymetry was 556.04±24.04 µm. Mean MD was -0.931±1.18dB and - 0.087±1.11dB before and after discontinuing topical treatment with PGs respectively. We have found a decrease in SFCT in all the measured points with statistical significance, except in the three nasal ones. The agreement between two observers was excellent (ICC>0.90).

Conclusion

Discontinuing treatment with PGs induce decrease in SFCT profile except in the nasal sector. Larger and bigger studies are needed to confirm our findings and if there is clinical correspondence.

References

1. Sahinoglu-Kesked, N; Canan H. Effect of Latanoprost on Choroidal Thickness. Journal of Glaucoma 2018; 27:635- 637.
2. Zhang X, Cole E, Pillar A, et al. The effect of change in intraocular pressure on choroidal structure in glaucomatous eyes. Invest Ophthalmol Vis Sci 2017;58: 3278-3285.

Correlation of Axial Length with AS-OCT Parameters in Myopes, Emmetropes, and Hyperopes

B.S.¹, Behera G¹, Kaliaperumal S¹

¹Jawaharlal Institute of Postgraduate Medical Education & Research, Pondicherry, India

Introduction

To analyze the association between spherical equivalent (SE) and ocular biometry measures/central corneal thickness (CCT) with anterior segment optical coherence tomography (AS-OCT) and SD-OCT parameters in emmetropia and in low refractive error.

Methods

A hospital-based observational study was conducted and 225 subjects aged between 18-35 years were enrolled. All participants underwent refraction, ocular biometry and central corneal thickness. AS-OCT parameters were measured using Cirrus HD-OCT (Carl Zeiss, Dublin, CA, USA). Only right eyes were considered for analysis. Posterior segment imaging for retinal nerve fiber layer (RNFL) thickness and ganglion cell complex (GCC) analysis was also done.

Results

Among the participants, there were 14 hypermetropes, 110 myopes, and 101 emmetropes; Average SE: Hypermetropes: 1.32 ± 0.50 , myopes: -3.49 ± 2.62 , emmetropes: -0.33 ± 0.35 ($p=0.001$). There was a strong positive correlation between SE with nasal and temporal anterior chamber angle (ACA) ($r=0.477$, $r=0.438$; $p<0.001$). There was a strong positive correlation between axial length (AL) with nasal and temporal ACA ($r=0.238$, $r=0.282$; $p<0.001$). There was a strong negative correlation between CCT with nasal and temporal ACA ($r=-0.375$, $r=-0.381$; $p<0.001$). The temporal trabecular iris surface area (TISA) 500 showed negative correlations with SE and CCT ($r=-0.253$; $p<0.001$) and ($r=-0.210$; $p=0.002$). The AL

showed strong negative correlation with RNFL thickness and GCC thickness measures.

Conclusion

The AL had a positive correlation, and SE and CCT had a negative correlation with ACA. This indicates progressively broader angle and thinner CCT with increasing myopia. The disc area too correlated positively with AL, indicating progressively increasing disc size with increasing myopia. However, the RNFL thickness and GCC parameters showed greater thinning with increasing myopia.

Factors Associated With Differences in the Initial Location of Structural Progression in Normal-Tension Glaucoma

Bae H¹, Lee S¹, Yang H², Lee J¹, Choi W¹, Kim C¹

¹Yonsei University College of Medicine, Seoul, South Korea, ²Kong Eye Center, Seoul, South Korea

Introduction

The aim was to investigate the underlying clinical parameters affecting the location of the initial structural progression of glaucoma in patients with normal-tension glaucoma (NTG).

Methods

This retrospective study included 228 eyes of 228 patients with NTG. In total, 130 eyes of 130 patients demonstrated structural progression (as determined by event-based guided progression analysis using Cirrus HD-optical coherence tomography) in the peripapillary retinal nerve fiber layer (ppRNFL) or macular ganglion cell inner plexiform layer (mGCIPL). Depending on where the progression occurred first, it was defined as either ppRNFL first progression or mGCIPL first progression. Clinical parameters associated with each first progression were identified using logistic regression.

Results

In total, 50 eyes showed ppRNFL first progression and 64 eyes showed mGCIPL first progression. ppRNFL first progression was significantly associated with female sex [odds ratio (OR)=5.705, P=0.015], lack of systemic hypertension (OR=0.199, P=0.014), disc hemorrhage (OR=4.188, P=0.029), higher mean intraocular pressure (OR=1.300, P=0.03), and lower pattern SD (OR=0.784, P=0.028). In contrast, male sex (OR=0.450, P=0.043), lower central corneal thickness (OR=0.987, P=0.032), higher intraocular pressure fluctuation (OR=1.753, P=0.047), lower systolic blood pressure fluctuation (OR=0.839, P=0.002), and higher diastolic blood pressure

fluctuation (OR=1.208, P=0.015) were significantly associated with mGCIPL first progression.

Conclusion

Different clinical factors were associated with the initial site of structural glaucoma progression in patients with NTG depending on its peripapillary or macular location, and these findings suggest possible differences in underlying mechanisms of glaucoma damage.

Glaucoma, 2300 years under pressure: The History of glaucoma from the antiquity to the dawn of the 20th century

Balanikas G¹, Pirounides D¹, Christodoulou D², Karampatakis V³

¹AHEPA Hospital, Aristotle University Of Thessaloniki, Thessaloniki, Greece,

²Laboratory of History of Medicine, Medical School, Aristotle University,

Thessaloniki, Greece, ³Laboratory of Experimental Medicine, Medical School, Aristotle University, Thessaloniki, Greece

Introduction

The term 'glaucoma' was a mystery when it appeared in antiquity. In this presentation, we will discuss the origins of the medical terms, the meaning, and the knowledge.

Methods

There are a number of ancient physicians who use the Greek terms γλαυκός, γλαύκωσις, γλαυκόματτος (Homer, Aristotle, Hippocrates, Galenus and Dioscorides. Their works tries to clarify the meaning of these terms and the correlation with glaucoma. We follow the evolution of the medicine through the centuries: the roman and byzantine era, Arabic period, renaissance and finally the 19th century when the symptoms and etiology became more understandable.

Results

During antiquity, the doctors were aware of conditions similar to 'glaucomata', and often complicated the terms 'γλαυκός' with manifestations not necessarily correlated with glaucoma. The Greek physicians were suspected of an insidious medical condition that caused blindness.

Conclusion

The journey of knowledge from antiquity to the dawn of the 20th century has been adventurous and extremely interesting. Glaucoma, a disease that previously lurked

behind other eye medical conditions, has complicated its picture and diagnosis by the first physicians of humanity. His revelation and adventure continue.

References

1. Henry G. Liddell & Robert Scott, *Lexicon of Greek Language* Volume One, 1897.
2. Sir Thomas Coar, *The Aphorisms of Hippocrates*, with a translation into Latin and English, J. Valpy, London, 1822.
3. Aristotle, *On Sense and the Sensible*, 2004.
4. S. Little Jr. *A Manual of the Diseases of the Eye*, J. S. Littell, Philadelphia, 1837.
5. William Lawrence, *A Treatise on the Diseases of the Eye*, John Churchill, London, 1832.
6. William McKenzie, *A Practical Treatise of The Diseases of The Eye*, Longman, London, 1830.

Ahmed Glaucoma Valve Implantation in Uveitic Glaucoma

Başçiftçi B¹, Takmaz T¹

¹University Of Health Sciences, Ankara City Hospital, Ankara, Turkey

Introduction

Secondary glaucoma, cataracts, synechiae, band keratopathy and macular edema are some of the complications of uveitis (1). In uveitic glaucoma; in order to reduce the risk of excessive damage to the optic nerve and retinal nerve fiber layer; detailed examination, rapid treatment and careful follow up are necessary (2,3). Conditions such as uveitic glaucoma, failure of trabeculectomy, neovascular glaucoma, congenital glaucoma, inadequate conjunctiva are the primary indications of the Ahmed Glaucoma Valve implantation. We present a case of uveitic glaucoma who underwent implantation of the Ahmed Glaucoma Valve and benefited.

Methods

Case Report

Results

An 8-year-old girl with the diagnosis of juvenile idiopathic arthritis and followed up with the diagnosis of uveitis, an increase in intraocular pressure occurs during the follow-up. The BCVA was 0.4 on the right and 0.5 on the left. Despite the use of latanoprost 1x1, brimonidine 2x1, dorzolamide-timolol 2x1 in both eyes, the intraocular pressure value measured by applanation tonometry was 27 mmHg on the right and 23 mmHg on the left. In the slit-lamp examination, +1 cell in the anterior chamber and posterior subcapsular cataract was present bilaterally. We performed an Ahmed Glaucoma Valve implantation first in the right eye and then in the left eye with an interval of 2 months. Intraocular pressure values were within the normal range (10-20 mmHg) during follow-up. At the follow-up 1 year later, the BCVA decreased to 0.2 on the right and 0.1 on the left due to the progression of the cataract. Thereupon, we performed cataract surgery on the left eye and then on

the right eye, one week apart. At our last examination, the patient's BCVA was 1.0 on the right and 0.9 on the left, while both drug-free intraocular pressure values were 11 mmHg by applanation tonometry. The AGV tip was open and pseudophakic bilaterally.

Figure 1. The intraocular pressure was 27 mmHg on the right preoperatively and we see the intraocular pressure values in the right eye after the AGV implantation.

Figure 2. The intraocular pressure was 23 mmHg on the left preoperatively and we see the intraocular pressure values in the left eye after the AGV implantation.

Conclusion

The evaluation, treatment and management of uveitis in children is immensely challenging for the ophthalmologists that have to confront this clinical matter, whereas glaucoma in children is a likely blinding condition. In such a case, we should consider AGV as the primary indication.

References

1. Holland GN, Stiehm ER. Special considerations in the evaluation and management of uveitis in children. *Am J Ophthalmol.* 2003;135:867-878.
2. Kaur S, Kaushik S, Singh Pandav S. Pediatric Uveitic Glaucoma. *J Curr Glaucoma Pract.* 2013;7:115-117.
3. Kalogeropoulos D, Kalogeropoulos C, Moschos MM, Sung V. The Management of Uveitic Glaucoma in Children. *Turk J Ophthalmol.* 2019 Oct 24;49(5):283-293.

Angle closure Glaucoma in Patient with Nanophthalmos Eye. Does clear lens extraction matters A case report.

Bhandari R¹

¹Dhangadhi Netralaya, Dhangadhi, Nepal

Background

Glaucoma surgery in nanophthalmos has an extremely high complication rate with disastrous visual results (1). Late choroidal effusion occurs in up to 50% of patients after trabeculectomy with mitomycin C (2).

A recent study of phacoemulsification and IOL in these patients shows that the results have improved and choroidal effusion is less likely to occur (5%), but that complications (for example malignant glaucoma and severe uveitis) are still common (3). Persistent choroidal effusion can be successfully treated by partial thickness sclerectomy, which suggests that reduced scleral permeability to protein secondary to thickened sclera plays a pathophysiological role in this complication.

Glaucoma surgery in nanophthalmos has an extremely high complication rate with disastrous visual results (1). Late choroidal effusion occurs in up to 50% of patients after trabeculectomy with mitomycin C (2).

A recent study of phacoemulsification and IOL in these patients shows that the results have improved and choroidal effusion is less likely to occur (5%), but that complications (for example malignant glaucoma and severe uveitis) are still common (3). Persistent choroidal effusion can be successfully treated by partial thickness sclerectomy, which suggests that reduced scleral permeability to protein secondary to thickened sclera plays a pathophysiological role in this complication.

Objective

To determine the reduction of intra ocular pressure, after clear lens extraction in patient with Nanophthalmos.

Methods/ Results

In this case report, we treated two eyes of one patient with nanophthalmos with Glaucoma, with clear lens extraction and posterior intraocular lens (IOL) implantation.

Case 1:

34 years old Male came to our hospital with complain of diminution of vision in both eyes since 5 years. He was previously diagnosed as Nanophthalmos with angle closer glaucoma and was using Combigan (Timolol+ brimonidine) e/d BD, Dorzox (Dorzolamide) e/d BD and Bimat LS (Bimatoprost) e/d HS in both eyes since 5 years from hospital in India. His best corrected visual acuity (BCVA) in Right eye (RE) was 6/60 and 5/60 in Left eye (LE). On slit light examination- Right Eye- Conjunctiva showed circum corneal congestion, small cornea with epithelial edema with shallow anterior chamber and lens was clear, pupil had sluggish reaction to light. Left eye – small cornea with shallow anterior chamber with superior peripheral iridotomy, no bleb noticed, and lens was clear, pupil was reacting to light. LE peripheral iridotomy was done 4 years back and was patent. Intra Ocular Pressure (IOP) was 44mm hg in RE and 23 mm hg. Gonio revealed closed angle in both eyes (BE). Axial length in RE was 20 and LE was 19 mm hg. Funduscopy revealed RE 0.9:1 cup to disc ratio (CDR) with disc pallor and dull foveal reflex and LE 0.9:1 CDR.

Patient underwent clear lens extraction with IOL implantation (Phaco aspiration with Foldable IOL implantation) in RE under topical anesthesia under I/V mannitol.

On 1st Post operative day (POD) RE- visual acuity improved to 6/24 and LE was same. Slit lamp examination- Right Eye- Sub conjunctival hemorrhage inferiorly, Cornea clear, AC moderate depth with cells ++, lens-Pseudophakia, pupil- sluggish reaction to light. Left eye was same. IOP in RE was 14 mm hg and LE 22 mm hg. Patient was discharged under topical antibiotic and steroids in RE and was advised to continue same treatment in LE.

Patient came for checkup after 3 weeks. His BCVA in RE was 6/18 and LE was 5/60. On slit light examination- Right Eye- Cornea was clear, AC moderate depth, quiet, lens-Pseudophakia, pupil sluggish reaction to light. Left eye was same. IOP in RE was 12 mm hg and LE was 21 mm hg.

He was admitted and operated for clear lens extraction (phaco with foldable IOL implantation) under topical anesthesia in LE under I/V mannitol. On 1st POD LE- visual acuity was 6/18. Slit lamp examination- Left Eye- Conjunctival congestion, Cornea was clear, AC moderate depth with cells ++, lens-Pseudophakia, pupil was reacting to light. IOP in RE was 14 mm hg and LE 10 mm hg. Patient was discharged under topical antibiotic and steroids in LE and advised same treatment in RE.

Patient came for checkup after 3 weeks. His BCVA in RE was 6/18 and LE was 6/12. On slit light examination- Right Eye- Cornea was clear, AC- moderate depth, quiet, lens-Pseudophakia, pupil- sluggish reaction to light. Left eye- Cornea was clear, AC moderate depth, quiet, lens-Pseudophakia, pupil- reacting to light. IOP in RE was 12 mm hg and LE was 15 mm hg. He was tapered steroid in BE and antibiotic was continued for one month and was advised to follow up after one month.

There was loss of follow up and patient came to our hospital 4 months after the surgery. His BCVA in RE was 6/18 and LE was 6/12. On slit light examination- Right Eye- Cornea was clear, AC moderate depth, quiet, lens-Pseudophakia, pupil- sluggish reaction to light. Left eye- Cornea was clear, AC- moderate depth, quiet,

lens-Pseudophakia, pupil- reacting to light. IOP in RE was 14 mm hg and LE was 12 mm hg. Gonioscopy revealed Grade I-II narrow angles in BE. Funduscopy showed RE 0.9:1 CDR with disc pallor and dull foveal reflex and LE 0.9:1 CDR. Visual field (HFA 10-2) revealed tunnel vision in BE.

After one year and two months patient came to our hospital with complain of itching in both eyes sometimes in afternoon. His BCVA in RE was 6/36 and LE was 6/12. On slit light examination- Right Eye- Palpebral conjunctiva showed few papillae along with follicles, cornea was clear, AC moderate depth, quiet, lens-Pseudophakia with PCO, pupil- sluggish reaction to light. Left eye- Cornea was clear, AC moderate depth, quiet, lens-Pseudophakia, pupil- reacting to light. IOP in RE was 16 mm hg and LE was 17 mm hg. Funduscopy showed RE 0.9:1 CDR with disc pallor and dull foveal reflex and LE 0.9:1 CDR, Visual field (HFA 10-2) revealed tunnel vision in BE. Patient was advised for YAG capsulotomy in RE. The patient was given anti allergic eye drops and advised to follow up after 6 months.

After one year and nine months patient came to our hospital for checkup. His BCVA in RE was 6/24 and LE was 6/12. On slit light examination- Right Eye- cornea was clear, AC moderate depth, quiet, lens-Pseudophakia with YAG opening, pupil-sluggish reaction to light. Left eye- Cornea was clear, AC moderate depth, quiet, lens-Pseudophakia, pupil- reacting to light. IOP in RE was 17 mmHg and LE was 18 mm hg. Funduscopy showed RE 0.9:1 CDR with disc pallor and dull foveal reflex and LE 0.9:1 CDR, Visual field (HFA 10-2) revealed tunnel vision in BE. The patient was given anti allergic eye drops and advised to follow up after 6 months.

Discussion

Nanophthalmos is a rare disorder of eye development characterized by extreme hyperopia (far sightedness), with refractive error in the range of -8.00 to -25.00 diopters. Because the cornea and lens are normal in size and shape, hyperopia occurs because insufficient growth along the visual axis places these lensing components too close to the retina.⁵

Medical management is difficult as IOP remains high in most of the patient with Nanophthalmos. As well Prophylactic miotics are contraindicated because of the possibility of producing relative pupillary block. If glaucoma develops, a peripheral iridectomy with tight closure should be performed following which miotics could be used if necessary.⁵

Wishart and Atkinson were among the earliest groups who recommended cataract extraction as the first procedure in eyes with cataract and PACG, rather than combined cataract and filtering surgery.⁶

It is often easier to justify lens extraction in PACG eyes with co-existing cataract, while it is always more controversial when there is no co-existing cataract. Tham et al., in their randomized controlled trial, compared the clinical effects of clear lens extraction versus trabeculectomy with mitomycin C in treating medically uncontrolled iridotomized PACG eyes. This showed that clear lens extraction alone could reduce the mean IOP by 34% (reducing mean pre-operative IOP of 24.1 mmHg to 15.9 mmHg post-operatively) and reduce the mean number of drugs by 60.4% (reducing from 3.69 drugs pre-operatively to 1.46 drugs post-operatively), over 24 months.⁷

Lens extraction deepens the anterior chamber, widens the drainage angle, and reverses the anatomical predisposing factors of angle closure. Tham CC et al showed increase in anterior chamber depth after lens extraction, they measured the anterior chamber depth with ultrasound biomicroscopy (UBM) which showed that the mean anterior chamber depth was increased significantly from 1799 to 3528 microns after cataract extraction alone, similarly the mean angle opening distance at 500 microns from scleral spur was increased significantly from 208 to 468 microns after cataract extraction in PACG eyes.⁸

After clear lens extraction there was a significant decrease in intraocular pressure, reason may be the iris lens diaphragm fell down after surgery and the angles were open due to which there was reduction of intra ocular pressure.

Conclusion

It is difficult to perform glaucoma surgery (trabeculectomy or a combined surgery involving Trabeculectomy with phacoemulsification and IOL implantation), as well post-operative period is difficult to manage. We need to perform sclerotomy before performing Trabeculectomy or a combined procedure. As well IOP reduction is important before surgery.

Clear lens extraction with IOL implantation helps in deepening the anterior chamber which results in opening of the angle due to which there is an increased outflow of fluid from anterior chamber and thereby reducing IOP and saving sight of the patient with less complication.

Consent

Patient consent was taken to publish this case.

References

1. Thapa SS, Poudel G. Choroidal effusion following laser peripheral iridotomy for the treatment of angle closure glaucoma in a patient with nanophthalmos. Nepal Med Coll J. 2005 Jun;7(1):81-2.
2. Utman SAK. Small Eyes Big Problems: Is Cataract Surgery the Best Option for the Nanophthalmic Eyes? J Coll Physicians Surg Pak. 2013 Sep;23(9):653-6.
3. Alexander C. Day, Robert E. MacLaren, Catey Bunce, Julian D. Stevens, Paul J. Foster, Outcomes of phacoemulsification and intraocular lens implantation in microphthalmos and nanophthalmos. J Cataract Refract Surg. 2013 Jan; 39(1):87-96.
4. Olof H. Sundina, Gregory S. Lepperta, Eduardo D. Silvaa, et al. Extreme hyperopia is the result of null mutations in MFRP, which encodes a Frizzled-related protein. PNAS. July 5, 2005, vol.102, no. 27 9553–9558
5. F. Phinzy Calhoun, Jr. The Management of Glaucoma in Nanophthalmos. Tr. Am. Ophth. Soc., Vol. Lxxiii, 1975.
6. Wishart P.K., Atkinson P.L. Extracapsular cataract extraction and posterior chamber lens implantation in patients with primary chronic angle-closure

glaucoma: effect on intraocular pressure control. *Eye (Lond.)* 1989; 3 (Pt 6):706–712. doi: 10.1038/eye.1989.109.

7. Tham C.C., Kwong Y.Y., Baig N., Leung D.Y., Li F.C., Lam D.S. Phacoemulsification *versus* trabeculectomy in medically uncontrolled chronic angle-closure glaucoma without cataract. *Ophthalmology*.2013; 120(1):62–67. doi: 10.1016/j.ophtha.2012.07.021.
8. Tham C.C., Leung D.Y., Kwong Y.Y., Li F.C., Lai J.S., Lam D.S. Effects of phacoemulsification *versus* combined phacotrabeculectomy on drainage angle status in primary angle closure glaucoma (PACG). *J. Glaucoma*.2010;19(2):119–123.

Glaucoma Screening in Family members of Glaucoma patients at a Tertiary Eye Hospital in Eastern Region of Nepal

Bhandari R²

¹Dhangadhi Netralaya, Dhangadhi, Nepal, ²Srikrishna Aankha Aspatal, Tikapur, Nepal

Introduction

The second most common cause of blindness in the world is glaucoma. Family history plays an important role in early detection and management of patients with glaucoma. The main objective of this study was to determine the prevalence of glaucoma in first degree relatives of Primary open angle glaucoma (POAG) and Primary angle closure glaucoma (PACG) patients. Glaucoma awareness among the first degree relatives was also assessed.

Materials and Methods

A cross sectional hospital based study was designed to examine and diagnose glaucoma among first degree relatives of patients with POAG and PACG, attending the outpatient department at Ramlal Golchha Eye Hospital in the Eastern region of Nepal from June 2016 to May 2017. A comprehensive eye examination was conducted by a glaucoma specialist at the hospital. All subjects underwent vision screening, refraction, slit lamp biomicroscopy, intraocular pressure measurement, gonioscopy and a dilated fundus examination. All glaucoma suspects and those diagnosed with glaucoma were enrolled for visual field examination.

Results

Two hundred and twenty-seven first degree relatives of 72 patients were invited for the examination. Out of 227 individuals, 131 (males 67.94%, females 32.06%) agreed to participate in the study. A total of 23 (17.56%) individuals were diagnosed with glaucoma, 10 (43.47%) as POAG and 13 (56.52%) as PACG. Fourteen percent of parents, 22% of siblings and 9% of off-springs had open angle glaucoma. Among 13 PACG participants, 26.08% of parents, 26.08% of siblings and

4.34% of off-springs had angle closure glaucoma. Awareness among first degree relatives diagnosed with glaucoma was 21.74%.

Conclusion

The prevalence of glaucoma among first degree relatives of glaucoma patients was higher than individuals without family history of glaucoma. Promoting awareness on glaucoma and the timely screening of family members can lead to early detection and prevention of blindness from the disease.

Keywords

Family history, First degree relatives, Primary angle closure glaucoma, Primary open angle glaucoma.

Financial Interest

Nil

Efficacy of Pascal Laser Trabeculoplasty in Lowering Intraocular Pressures In patients on Maximal tolerated anti-glaucoma topicals

Bhansali S¹, Bhansali S², Mathai M³, Bhansali S⁴

¹Wrightington Wigan and Leigh NHS teaching hospital, Wigan, United Kingdom,

²Manchester University, Greater Manchester, United Kingdom, ³Wrightington

Wigan and Leigh NHS teaching hospital, Wigan, United Kingdom, ⁴Wrightington

Wigan and Leigh NHS teaching hospital, Wigan, United kingdom

Introduction

To determine the efficacy of using PLT for lowering IOP in patients with open-angle glaucoma and comparing these results against the use of selective laser trabeculoplasty (SLT).

Methods

A retrospective analysis was conducted using 58 eyes from 48 subjects with a confirmed diagnosis of primary and secondary open angle glaucoma, and normal tension glaucoma. Subjects underwent PLT at the Ophthalmology Department, NHS Wrightington, Wigan, and Leigh Teaching Foundation Trust Hospitals between January 2014 and December 2019. Baseline IOP and IOP on follow up visits following the procedure at 1, 6, 12, 24, 36 months were measured.

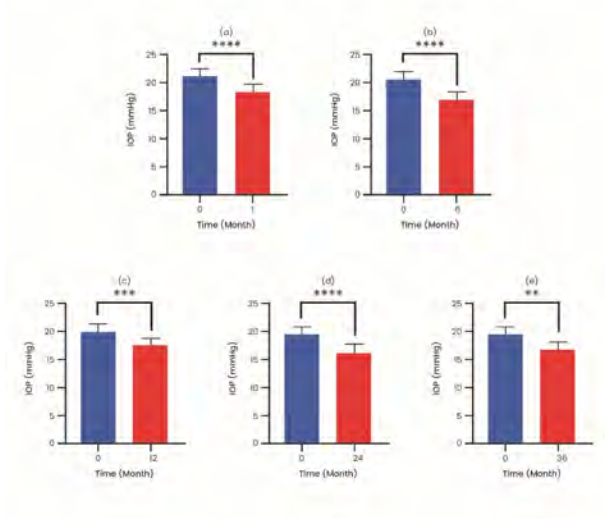
Results

The baseline IOP was measured as 20.6 ± 0.6 mmHg. The greatest reductions in IOP occurred at 1, 6, and 24 months. At 1 month, a reduction in IOP of 13.1% was measured at 18.5 ± 1.0 mmHg ($P < 0.0001$). At 6 months, a reduction in IOP of 17.0% was noted at 17.6 ± 1.0 mmHg ($P < 0.0001$), and at 24months, a reduction of 18.7% at 16.5 ± 1.1 mmHg ($P < 0.0001$) was recorded.

Conclusion

Our results demonstrate that PLT is a safe, fast, and effective treatment for open-angle glaucoma, similar to the published data for SLT. However, PLT is not as popular as other laser options like SLT or ALT due to a lack of sufficient publications and studies in this field.

Figure



(a) Baseline IOP compared to 1 month IOP (n = 52). (b) Baseline IOP measurement 6 month IOP (n = 31). (c) Baseline IOP measurement 12 month IOP (n = 41). (d) Baseline IOP measurement 24 month IOP (n = 32). (e) Baseline IOP measurement 36 month IOP (n = 20).

Clinical Profile and Investigational Characteristics of Glaucoma Patients: A Retrospective Analysis

Bhatnagar K¹, Shakrawal J¹

¹All India Institute of Medical Sciences, Jodhpur, Jodhpur, India

Introduction

The study was conducted to determine the demographic/clinical profile of glaucoma managed at a tertiary care hospital in western Rajasthan in COVID-19 era.

Methods

Retrospective analysis 176 glaucoma eyes from March 2019 to 2020 with minimal follow-up of 1 year were included in the study.

Results

Majority of the patients were males (65.50%) & were having bilateral involvement (81.44%), with a mean age of 56.04 years with equal presentations of POAG & PACG. There was significant association between age and family history with risk of glaucoma. There was more primary glaucoma (86.93%). The mean baseline IOP was 25.34mmHg with highest for JOAG (36 mmHg) & PACG (29.39 mmHg), and mean CDR was 0.82±0.21. 54.33% had severe field defects, majority PACG. Medical treatment was the most common initial management given due to pandemic spread. Limited required surgeries were done in 12.50%. The mean IOP on last visit was 14.61mmHg. The success rates were 51.70%, 71.59% & 86.36% for IOP≤12, 15, 18mmHg. The reduction in IOP was 42.34% at last review. 85.03% were perimetrically stable. There was a negative correlation between MD & baseline IOP.

Text:

Conclusion

Primary open angle glaucoma is the most common form of glaucoma commonly managed initially with medical treatment with significant success rate.

Effect of Moringa Oleifera leaf extract on extracellular matrix trabecular meshwork of glaucoma model Wistar rats

Cahyono M¹, Rahmi F¹, Prihatningtias R¹, wildan a¹, Istiadi H¹

¹Indonesian Glaucoma Society, Semarang, Indonesia

Introduction

High intraocular pressure (IOP) is considered an important risk factor for glaucoma and is still the only risk factor that can be controlled. Exposure to mechanical injury to the trabecular meshwork (TM), one of which is an increase in IOP, can cause remodeling of TM extracellular matrix (ECM). It is this remodeling of ECM that influences the permanent outflow of aqueous humor. Moringa oleifera leaf extract has been studied to have antioxidant effects. The aim of this study was to prove the effect of Moringa oleifera leaf extract on the ECM of the TM of glaucoma models of Wistar rats compared to controls

Methods

It was a laboratory experimental study that uses a glaucoma model Wistar rats given treatment of Moringa oleifera leaf extract for 4 weeks at dose of 300 mg/kg body weight as experimental group. Thickness of the ECM was examined with hematoxylin eosin staining. Statistical analysis was using a parametric t-test. p-Values of less than 0.05 were statistically significant

Results

Mean thickness of extracellular matrix TM experimental group and control group were 149.70µm and 215.69µm respectively. Extracellular matrix TM experimental group statistically significant thinner than control group (p.044)

Conclusion

Moringa oleifera could protect TM from damage cause by high intraocular pressure

References

1. Vranka JA et al. Extracellular matrix in the trabecular meshwork: Intraocular pressure regulation and dysregulation in glaucoma. *Experimental eye research*. 2015: 112-125
2. Owolabi JO et al. Exploring Moringa Oleifera Usefulness in Ameliorating Induced Retinopathy in Experimental Animals. *Journal of Pharmacy and Biological Sciences*. Volume 12, Issue 5. III. 2017; 21-29.

Glaucoma Drainage Device Implantation: After 8 Years Successful Trabeculectomy

Intan Cendana Sari¹, IGA Ratna²; Kusumadjaja, I Made Agus²

¹Resident of Ophthalmology Study Program, Faculty of Medicine Udayana University-Sanglah Hospital, Denpasar, Bali

²Ophthalmologists, Department of Ophthalmology, Faculty of Medicine Udayana University-Sanglah Hospital Denpasar, Bali

Introduction

In eyes where trabeculectomy has failed, some are indicated for plate-based tube shunt surgery. This case report describes a case of primary angle-closure that underwent a glaucoma drainage device implantation procedure after a trabeculectomy.

Methods

A case report

Results

A 47-year-old male complained a gradual blurred vision for a year. History of RLE glaucoma and LE trabeculectomy 8 years ago. Eye trauma or steroid drugs use was denied. LE VA was 6/18 PH 6/12, IOP 32 mmHg. The bleb was diffuse with low vascularity. The patient was diagnosed with RLE PACG and immature senile cataract. Subsequently, a GDD was implanted after needling with 5-FU had failed, then IOP was again under control.

Conclusion

After 8 years of successful trabeculectomy, the patient required a GDD implant to maintain IOP control for a longer time.

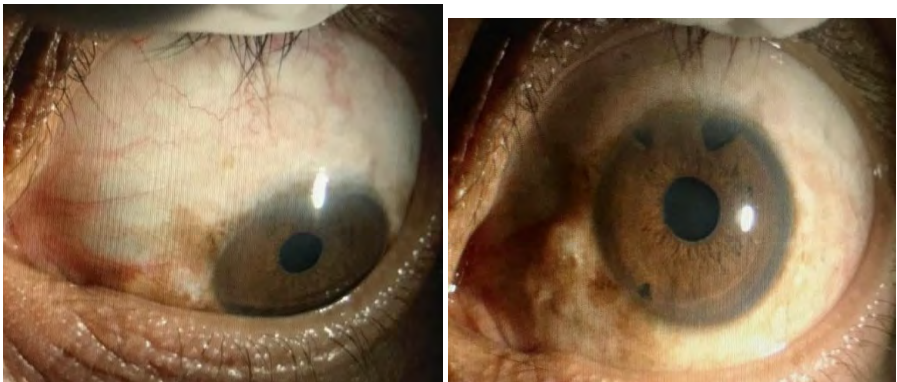
Keywords

primary angle-closure glaucoma, glaucoma drainage device, trabeculectomy

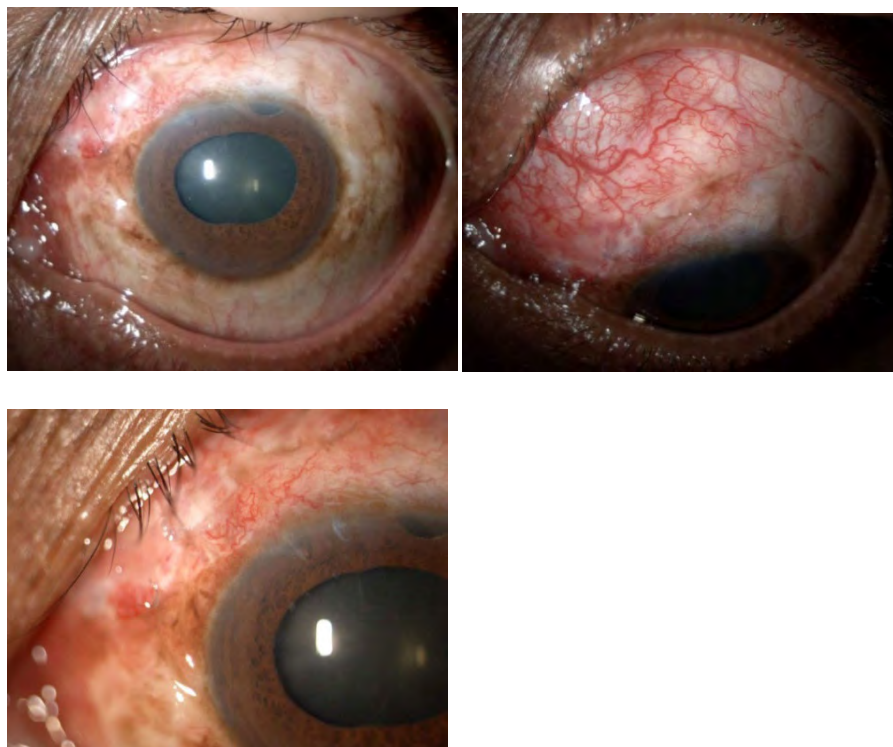
References

1. AAO. 2020-2021 BCSC Section 10: Glaucoma. San Francisco: AAO. 2021.
2. Wright, C., Tawfik, M. A., Waisbourd, M., Katz, L. J., Primary angle-closure glaucoma: an update. *Acta Ophthalmol.* 2016 May;94(3):217-25. doi: 10.1111/aos.12784. Epub 2015 Jun 27.
3. Sihota, R., Gupta, V., Agarwal, C. H. Long-term evaluation of trabeculectomy in primary open angle glaucoma and chronic primary angle closure glaucoma in an Asian population. *Clin Exp Ophthalmol.* 2004 Feb;32(1):23-8. doi: 10.1046/j.1442-9071.2004.00752.x.

Tables, figures, and illustrations



Picture 1. On the first visit, mild bleb and low vascularity appears on LE.



Picture 2. After LE GDD implant, tube appears in supero nasal.

Using the Glaucoma Medications Intensity Index (GMII) to predict trabeculectomy outcome

Wong J¹, Leung T¹, Lai J¹, [Chan J¹](#)

¹University Of Hong Kong, Hong Kong, Hong Kong

Introduction

Previous studies have reported that greater number and/or duration of preoperative topical glaucoma medications are associated with poorer trabeculectomy outcome, but the amount of exposure has never been accurately quantified. We aim to investigate the relationship between preoperative exposure to topical glaucoma medications and trabeculectomy outcome, using a new and more precise method for quantifying accumulated exposure.

Methods

Consecutive patients with primary open-angle glaucoma or normal-tension glaucoma who underwent primary trabeculectomy from 2013-2017 at a single centre were reviewed. The Glaucoma Medications Intensity Index (GMII) was calculated for each eye by multiplying number of drops per week by duration of use (in years). The relationship between GMII and postoperative outcome in terms of success rates and survival time was analyzed.

Results

Fifty-five eyes from 40 patients followed for 2.72 ± 1.46 years after primary trabeculectomy were analyzed. The GMII for successful eyes ($n=41$), 111.71 ± 78.59 , was significantly lower than for failed eyes ($n=14$), 167.41 ± 85.04 ($P=0.03$). Univariate regression analysis of age, gender, cup-disc ratio, previous phacoemulsification, diabetes, hypertension, dyslipidemia, preoperative number of glaucoma medications / treatment duration / intraocular pressure, and GMII showed age and GMII as possible predictor for failure. On subsequent multivariate analysis, only GMII was correlated with failure (OR 1.021, CI 1.00-1.05, $P=0.05$). When $GMII \geq 80$, the postoperative survival time was shorter ($P=0.02$), the 1-year

IOP, number of glaucoma medications, and number of needling performed were higher ($P=0.03$, <0.01 , 0.03 , respectively), while reduction in glaucoma medication was less ($P=0.02$).

Conclusion

The GMII can help identify eyes with higher predicted risk for trabeculectomy failure, that may benefit from additional peri-operative intervention or treatment.

Micropulse Laser Therapy in Primary Angle Closure Glaucoma

Chauhan D¹

¹Dr. RP Centre For Ophthalmic Sciences, AIIMS, New Delhi, New Delhi, India

Introduction

This study evaluates the efficacy of MP-TSCPC in primary angle-closure glaucoma(PACG) where filtering surgeries have higher complications compared to Primary open-angle glaucoma.

Methods

Thirty two (21 patients) advanced PACG eyes with uncontrolled IOP on maximum tolerable ocular hypotensive medications, scheduled for trabeculectomy, were given a trial of MP-TSCPC [810nm laser, 31.3% duty cycle, 2000mw power for 180 seconds, 360 degrees]. Absolute (without medications) and qualified (with medications) success at IOP 15mmHg and 18mmHg were defined. Treatment failure determined as need for any additional intervention.

Results

At 6 months, with 18mmHg as cut off, 68.75%(n=22) of eyes achieved qualified success and 6.25%(n=2) had absolute success. With 15mmHg as cut off, 21.8%(n=7) had qualified success and 3.1%(n=1) had absolute success. Significant reduction in mean IOP from 23.56±6.46mmHg (4.4±0.8 medications) to 15.1±3.3mmHg (p<0.001) on post-operative week 1 with 1.5±1.02 medications; 15.5±3.62mmHg (p<0.001) at 3months with 2.1±1.3 medications and 16.94±3.33mmHg(p<0.001) at 6months with 2.5±1.22 medications noted. At 6 months, percentage IOP reduction was 28.1% and medication reduction was 43.18%. Treatment failure was seen in 3 eyes (9.37%): 2eyes(6.25%) requiring an additional filtering procedure, 1 eye(3.125%) requiring an additional MP-TSCPC session. On pentacam, increase in

pupillary diameter was noted from 2.61 to 2.8 mm ($p>0.05$). No significant change in vision acuity($p>0.05$) on LogMAR scale(pre-laser- 0.4 ± 0.48 ; post-laser- 0.44 ± 0.57) and central macular thickness($p>0.05$), on optical coherence tomography. Besides drop of visual acuity > 2 lines in one patient (factor-cystoid macular edema), no major post-laser complications noted.

Conclusion

MP-TSCPC can be used to reduce IOP in PACG eyes in the short-term. However, long term efficacy requires further evaluation.

A challenging case of exposed glaucoma drainage device: multiple modalities used to repair tube exposure

Chee S¹, Teh S¹, Embong Z²

¹Department of Ophthalmology, Hospital Selayang, Batu Caves, Malaysia, ².

Department of Ophthalmology and Visual Science, School of Medical Sciences, Universiti Sains Malaysia, Kubang Kerian, Malaysia

Introduction

Glaucoma drainage device (GDD) is used to reduce intraocular pressure (IOP) in glaucoma patients by diverting aqueous humour to an external reservoir. One of the most dreaded complications is tube exposure, which poses significant risk for endophthalmitis. We report a case of exposed GDD in a precious eye and its management.

Methods

Case report

Results

A 45-year-old man, known case of juvenile glaucoma had two GDD implanted for right eye (RE). His left eye (LE) was eviscerated because of painful blind eye. 7 years post GDD, his supero-nasal tube in the RE was exposed, and it was repaired by amniotic membrane transplant (AMT). However, the surgery failed, and he was referred to us for further management. On examination, his RE visual acuity was CF and IOP was 11 mmHg. The supero-temporal tube was intact. The supero-nasal tube was exposed with a length of 3.2 mm with scarred and stiffened conjunctiva but there was no leaking. Thus, he was treated with autologous plasma eyedrops, antibiotics eyedrops, oral doxycycline and scleral bandage contact lens. The first 6th-months review, the length of exposed tube was reduced to 1.0 mm. However, on the 8th-month review, the length of exposed tube had increased to 2.0 mm. In view of precious eye, patient underwent tube repair with corneal patch graft and

double-layer AMT. On his 6th-month post-operative review, there was no re-exposure of the GDD and no sign of conjunctival erosion.

Conclusion

Exposure of the tube after GDD implantation surgery is a potentially sight-threatening condition as it can lead to serious sequelae such as endophthalmitis. It can be successfully managed by using corneal patch graft and double-layer amniotic membrane.

Clinical Characteristics and Prognostic Factors Influencing Visual Outcome of Intraocular Foreign Body

Chee S^{1,2}, Khor S¹, Chong K¹, Embong Z²

¹Department of Ophthalmology, Hospital Selayang, Batu Caves, Malaysia,

²Department of Ophthalmology and Visual Science, School of Medical Sciences, Universiti Sains Malaysia, Kubang Kerian, Malaysia

Introduction

Penetrating ocular injury can result in severe visual loss in working-age adults in developing countries. Intraocular foreign body (IOFB) accounts for up to half of these cases. We aim to identify the clinical characteristics and to define the prognostic factors affecting visual outcomes of IOFB in a tertiary centre.

Methods

25 patients with IOFB between January 2020 to December 2021 were identified and retrospectively reviewed. The pre- and postoperative visual acuity, mechanism of trauma, material and size of the foreign body, entry site, time from trauma to surgical removal, IOFB location, associated ocular findings, choice of vitreous tamponade agent and complications were recorded. Univariate analyses were performed to evaluate the prognostic factors.

Results

24 patients were male and the mean age was 36.76 ± 12.57 . The nature of IOFBs was mainly metal (76.0%). The main mechanism of injury was hammering metal (36.0%). The mean preoperative VA was 2.30 logMAR, and mean final VA was 1.85 logMAR. Majority of IOFB entered via cornea (76.0%). IOFB was most commonly found at the inferior retina (44.0%) followed by vitreous (20.0%). Few complications from IOFB injury were endophthalmitis, retinal detachment, secondary glaucoma and proliferative vitreous retinopathy. There were no significant prognostic factors identified. However, patients with poor visual acuity

initially ($p=0.23$) and endophthalmitis ($p=0.18$) had a relatively poorer outcome as compared to other factors.

Conclusion

IOFB is a common industrial injury. Although there were no significant prognostic factors identified, the prognosis of an IOFB injury is generally poor due to a complex combination of issues. Timely surgical intervention is required to prevent further deterioration and complications from occurring.

Topical “paradise” turns into a nightmare. A rare case of over-the-counter eyedrops abuse that leads to evisceration

Chee S¹, Hakim I¹, Embong Z²

¹Department of Ophthalmology, Hospital Selayang, Batu Caves, Malaysia,

²Department of Ophthalmology and Visual Science, School of Medical Sciences, Universiti Sains Malaysia, Kubang Kerian, Malaysia

Introduction

The abuse of topical anaesthetic and steroids is not uncommon. However, it's rare to have an eye eviscerated due to complications from abusing topical anaesthetics and steroids. We report a case of left eye (LE) severe corneal ulcer with panophthalmitis secondary to abuse of over-the-counter topical proparacaine and topical dexamethasone that eventually leads to evisceration.

Methods

Case report

Results

A 70-year-old man known case of diabetes mellitus was diagnosed with carotid-cavernous fistula in the LE two years ago and successfully treated with embolization. He defaulted follow-up subsequently but continued using over-the-counter topical proparacaine and dexamethasone irregularly in both eyes for bilateral eyes discomfort. The problem started six months ago when he noticed a central whitish spot over his LE and started increasing the frequency of both eye-drops instillation to three times daily in the LE. He presented with history of LE pain, redness, and loss of vision for one month. LE examination revealed his vision was no-perception-of-light with positive reverse relative afferent pupillary defect and total ophthalmoplegia. There was presence of severe cornea ulcer with endothelial plaque. The LE intraocular pressure (IOP) was 6 mmHg. B scan of the LE showed dense vitritis, loculation and posterior scleral thickening. Right eye (RE) examination revealed 6/12 visual acuity with normal anterior segment. The RE IOP

was high at 30 mmHg. He was treated with antiglaucoma eye-drops for RE steroid responder. His LE was diagnosed as severe corneal ulcer with panophthalmitis and evisceration was performed due to painful blind eye.

Conclusion

Topical anaesthetic and steroids abuse can lead to serious complications such as chronic keratitis and endophthalmitis. The availability of topical anaesthetics and steroids over-the-counter must be re-evaluated to prevent such complications.

Micropulse transscleral cyclophotocoagulation in a Taiwanese population: 2-year clinical outcomes and prognostic factors

Chen H¹, Yeh P¹, Su W¹, Lee Y¹, Wu W¹

¹Chang Gung Memorial Hospital, Taipei, Taiwan

Introduction

To evaluate the 2-year efficacy and safety of micropulse transscleral cyclophotocoagulation (MP-TSCPC) in Taiwanese patients with glaucoma.

Methods

We included the patients who received standardized MP-TSCPC with follow-up examinations on a regular basis for 24 months. Treatment success was defined as the attainment of a postoperative intraocular pressure (IOP) between 6 and 21 mmHg or a $\geq 20\%$ reduction in IOP from baseline without an increase in glaucoma medications.

Results

A total of 60 eyes from 56 patients who underwent MP-TSCPC for refractory glaucoma were included. The percentage of treatment success was 88.3% at 3 months, 83.3% at 6 months, 78.3% at 12 months, and 75.0% at 24 months. The mean baseline IOP prior to MP-TSCPC was 34 ± 11.9 mmHg (range 14–56 mmHg). The mean postoperative IOP decreased to 20.9 ± 10.0 mmHg, 18.0 ± 7.8 mmHg, 17.5 ± 6.4 mmHg, and 18.2 ± 7.1 mmHg after 3 months, 6 months, 12 months, and 24 months, respectively, in successful cases. The mean number of glaucoma medications at baseline was 3.8 ± 0.2 , and the mean numbers of glaucoma medications at postoperative months 3, 6, 12, and 24 were 2.6 ± 0.7 , 2.8 ± 0.6 , 2.5 ± 1.4 and 2.6 ± 1.4 , respectively, in successful cases. Younger age and prior continuous wave -TSCPC significantly contributed to surgical failure in the multivariate model. Transient complications included mild iritis, hypotony, and mydriasis. None of the eyes developed vitreous hemorrhage, cystoid macular edema, or phthisis bulbi in the late postoperative period.

Conclusion

MP-TSCPC might be safe and effective for refractory glaucoma patients with maximal antiglaucoma medications.

Diagnostic Value of Spectralis OCT in Early Glaucoma detection in a Taiwan Chinese population

Chen H^{1,2}, Wu C^{3,4}, Chang⁵

¹Department of Ophthalmology, Fu Jen Catholic University Hospital, New Taipei City, Taiwan, ²School of Medicine, College of Medicine, Fu Jen Catholic University, New Taipei City, Taiwan, ³Graduate Institute of Medicine, College of Medicine, Kaohsiung Medical University, Kaohsiung, Taiwan, ⁴Department of Ophthalmology, Kaohsiung Medical University Hospital, Kaohsiung Medical University, Kaohsiung, Taiwan, ⁵Department of Mathematics, Tamkang University, New Taipei City, Taiwan

Introduction

To investigate the diagnostic capability of Spectralis optical coherence tomography (OCT) in early glaucomatous eye in a Taiwan Chinese population with varying glaucoma types.

Methods

One eye each was chosen from 113 normal subjects, 125 glaucoma suspect (GS) patients, and 156 glaucoma patients (87 primary open angle glaucoma (POAG), 50 primary angle-closure glaucoma (PACG), 19 normal tension glaucoma (NTG)). Early glaucoma was defined as mean deviation greater than -6 dB in the visual field test. Sectoral and global thickness of peripapillary retinal nerve fiber layer (ppRNFL), Bruch's membrane opening-minimum rim width (BMO-MRW) and macular parameters including macular retinal nerve fiber layer (mRNFL), ganglion cell layer (mGCL) and inner plexiform layer (mGCL) were measured using Spectralis OCT with Glaucoma Premium Module Edition (GPME). The area under the receiver operator characteristic (AUC) was used to assess the diagnostic ability of each parameter to distinguish normal eyes from early glaucomatous eyes in GS, POAG, PACG, NTG type.

Results

For normal versus POAG, the best AUC was the temporal inferior BMO-MRW (AUC = 0.847). For normal versus PACG, the best AUC was the inner temporal macular ganglion cell layers (mGCL) (AUC = 0.770). For normal versus NTG, the best AUC was the temporal superior ppRNFL (AUC = 0.861). For normal versus GS eyes, the best AUC was the mean global BMO-MRW (AUC = 0.768). The mGCL reveals the best diagnostic ability among macular parameters but is still inferior to ppRNFL and BMO-MRW in POAG and NTG type except PACG.

Conclusion

Spectralis OCT shows promising in early glaucoma detection in POAG, PACG and NTG group but not in GS group in Taiwan Chinese population. Further studies are needed to validate these findings.

Ab-externo implantation of XEN gel stent for refractory glaucoma in single-eye patients

Chen M^{1,2}, Chen Y¹

¹Taipei Veterans General Hospital, Taipei, Taiwan, ²National Yang Ming Chiao Tung University, Taipei, Taiwan

Introduction

It is challenging to perform filtering surgery for refractory glaucoma in single-eye patients. XEN gel stent is a new option. However, the original designed ab-interno approach may increase potential risk in single-eye patients due to multiple intraocular manipulations. Here, we aim to describe XEN gel stent implantation via ab-externo approach for such cases.

Methods

After topical anesthesia, the XEN injector needle was inserted 7 mm behind the limbus with the bevel up, directly beneath the conjunctiva and advanced to the marked 2.5 mm scleral entry wound. The needle then pierced the sclera until the needle tip was just visible in the anterior chamber. The slider was then pushed forward until the tip of the XEN stent was seen in the anterior chamber. The injector was slowly withdrawn when the slider was pushed to complete stent deployment. Subconjunctival mitomycin C 0.02% was then injected posterior to the bleb.

Results

The first case is a 41-year-old male with advanced open-angle glaucoma in both eyes and total blind in the right eye. His left eye experienced progression with poor intraocular pressure (IOP) control despite maximal medical treatment. After XEN gel stent implantation via ab-externo approach, his IOP dropped from 31 mmHg to 11 mmHg 1 week post-operatively, and maintained an IOP of 16 mmHg until 12 months post-operatively. The second case is an 86-year-old male with diabetic neovascular glaucoma in both eyes and total blind in the right eye. His left eye

developed an IOP of 50 mmHg despite intravitreal anti-VEGF injection and maximal medical treatment. After XEN gel stent implantation via ab-externo approach, his IOP decreased to 18 mmHg 1 week post-operatively, and maintained an IOP of 17 mmHg until 12 months post-operatively.

Conclusion

XEN gel stent implantation via ab-externo approach appears to be safe and efficacious in control IOP for refractory glaucoma in single-eye patients.

Severe visual field defects in young myopic patients with newly diagnosed primary open-angle glaucoma

CHEN Y^{1,2}, Tu P¹

¹Cathay General Hospital, Taipei, Taiwan, China, ²School of Medicine, College of Medicine, Fu Jen Catholic University, Taipei, Taiwan

Introduction

We described a series of young to middle-aged myopic subjects with newly diagnosed primary open-angle glaucoma (POAG) who presented with severe visual field (VF) defects at initial presentation.

Methods

We performed a retrospective chart review of myopic subjects with POAG. The subjects diagnosed younger than 51 years of age were included. Severe VF defect was defined as a MD of -10 dB or worse in at least one eye. The clinical characteristics of VF-defect eyes and fellow eyes were compared using the independent t test for continuous variables.

Results

We included 20 eyes of 18 myopic subjects with POAG (Mean age: 41.7 ± 7.7 years) (Table 1). The mean SE was -6.85 ± 2.86 D. The mean initial VF MD was -14.75 ± 3.97 dB. The mean initial intraocular pressure (IOP) was 21.1 ± 11.4 mmHg. There were six subjects who presented with unilateral VF defect (Table 2). The mean initial IOP was higher in VF defect eyes (25 ± 8.4 mmHg) compared to fellow eyes without VF defect (19.6 ± 8.4 mmHg) (Table 3). Two representative cases of subjects with unilateral VF defect were shown in Figure 1 and 2.

Conclusion

The POAG with severe VF defect may occur in myopic subjects, especially high myopia, in younger age. POAG screening should be performed earlier in subjects with high myopia than is suggested by traditional guidelines.

References

1. Bak E, Kim YK, Ha A, et al. Association of Intereye Visual-Sensitivity Asymmetry With Progression of Primary Open-Angle Glaucoma. *Invest Ophthalmol Vis Sci*. 2021 Jul 1;62(9):4.
2. Tham YC, Aung T, Fan Q, et al. Joint Effects of Intraocular Pressure and Myopia on Risk of Primary Open-Angle Glaucoma: The Singapore Epidemiology of Eye Diseases Study. *Sci Rep*. 2016 Jan 13;6:19320.

Table 1. Demographics of All Subjects

Case No. (n=18)	Age of initial presentation	Gender	Spherical equivalence (D)	Initial VA	Initial VF MD (dB)	Initial VF pattern	Initial IOP (mmHg)	Mean treated IOP (mmHg)	Optic disc tilt ratio	Optic disc absolute rotational degree	Beta-zone PPA to disc area ratio	Received trabeculectomy	Family history of glaucoma
1	40	Male	-6.25	0.80	-14.80	Superior	20	10.9	1.28	16.1	1.06	No	Sister
1	40	Male	-6.25	0.60	-18.80	Both	15	12.2	1.39	2.8	0.85	No	Sister
2	43	Male	-8.00	0.60	-17.18	Both	49	17.8	1.09	3.2	0.72	Yes	No
3	21	Female	-7.25	0.40	-26.13	Both	29	15.0	1.21	19.2	0.12	Yes	No
4	28	Male	-9.13	0.03	-18.84	Both	11	13.0	1.10	3.9	0.39	Yes	No
5	50	Male	-6.13	0.80	-12.80	Both	50	21.3	1.22	2.0	0.43	Yes	No
6	39	Male	-7.63	0.05	-18.80	Both	26	16.1	1.11	3.6	0.30	No	Cousin
6	39	Male	-8.13	0.20	-17.70	Both	33	11.1	1.06	11.7	0.07	Yes	Cousin
7	41	Male	-10.38	0.80	-10.37	Superior	23	19.0	1.35	20.6	1.65	No	No
8	46	Male	-6.88	1.00	-12.60	Both	19	15.3	1.29	2.2	1.06	No	No
9	50	Male	-6.15	0.60	-16.00	Both	14	12.8	1.78	9.5	2.05	No	No
10	33	Male	-3.75	0.90	-11.00	Both	15	12.0	1.20	19.0	0.66	No	No
11	45	Female	-12.50	0.50	-16.90	Both	15	11.0	1.53	5.3	1.03	No	Father
12	49	Male	-3.93	0.40	-12.90	Both	12	10.3	1.44	11.3	1.50	No	No
13	38	Female	-0.63	0.80	-12.00	Both	19	17.5	1.57	8.9	1.44	No	No
14	45	Female	-5.63	0.60	-11.50	Superior	16	15.2	1.53	11.9	1.34	No	No
15	47	Male	-7.00	0.70	-11.90	Both	13	11.2	1.43	5.5	1.20	No	No
16	49	Female	-12.13	0.80	-12.20	Both	12	10.3	1.09	19.7	0.25	No	No
17	43	Male	-6.25	0.90	-12.20	Superior	13	16.6	1.40	29.3	1.93	No	No
18	43	Male	-3.13	1.00	-10.92	Superior	17	14.5	1.38	25.0	0.58	No	No
AVE ± STDEV			41.7 ± 7.7	MF=13.5	-6.85 ± 2.86	0.62 ± 0.29	-14.75 ± 3.97	21.1 ± 11.4	14.2 ± 3.1	1.32 ± 0.19	11.5 ± 8.3	0.93 ± 0.59	

No. = number, VA = Visual acuity, VF = visual field, MD = mean deviation, IOP = intraocular pressure, PPA = peripapillary atrophy, AVE = average, STDEV = standard deviation.

DM = diabetes mellitus, HTN = hypertension, CAD = coronary artery disease, COPD = chronic obstructive pulmonary disease.

Table 1: Demographics of all myopic subjects with POAG.

Case No. (n = 6)	Age of initial presentation	Gender	Spherical equivalence (D)	Initial VA	Initial VF MD (dB)	Initial VF pattern	Pre-OP IOP (mmHg)	Post-OP IOP (mmHg)	Optic disc tilt ratio	Optic disc absolute rotational degree	Beta-zone PPA to disc area ratio	Received trabeculectomy
2	43	Male	-7.00	0.60	-17.18	Both	39.5	18.5	1.09	3.16	0.72	Yes
2	43	Male	-7.75	0.90	-0.67	None	15.3		0.99	13.75	0.51	No
3	21	Female	-7.25	0.60	-2.38	None	35.8	15.0	1.19	4.78	0.12	Yes
3	21	Female	-8.50	0.60	-26.13	Both	25.5	19.2	1.21	19.18	0.12	Yes
4	26	Male	-9.00	0.03	-18.84	Both	25.9	13.0	1.10	3.90	0.39	Yes
4	28	Male	-7.50	1.00	-0.03	None	17.3		1.25	12.75	0.72	No
5	50	Male	-5.00	0.90	-3.40	None	18.6		1.31	8.50	0.72	No
5	50	Male	-5.25	0.80	-12.80	Both	25.8	18.4	1.22	2.01	0.43	Yes
13	38	Female	-1.50	1.00	-1.70	None	19.1		1.46	4.22	1.14	No
13	38	Female	-0.63	0.80	-12.00	Both	17.5		1.57	8.88	1.44	No
18	43	Male	-3.00	1.00	-10.92	Superior	16.0		1.38	24.96	0.58	No
18	43	Male	-3.75	1.00	-3.29	None	11.5		1.13	3.81	0.41	No
AVE ± STDEV			37 ± 10.3	M:F=4:2	-5.51 ± 2.78	0.77 ± 0.28	-9.11 ± 8.50	22.3 ± 8.5	16.8 ± 2.7	1.25 ± 0.17	9.16 ± 7.21	0.61 ± 0.38

No. = number, VA = Visual acuity, VF = visual field, MD = mean deviation, IOP = intraocular pressure, PPA = peripapillary atrophy, AVE = average, STDEV = standard deviation.

Table 2: Demographics of six subjects who presented with unilateral VF defect.

	Eyes with VF defect (n=6)	Fellow eye (n=6)	P value
Spherical equivalence (D)	-5.56 ± 3.27	-5.46 ± 2.51	0.9515
Initial VA	0.64 ± 0.33	0.90 ± 0.15	0.1119
Initial VF MD (dB)	-16.31 ± 5.72	-1.91 ± 1.38	0.0001*
Initial VF pattern (Both: Superior: inferior)	5:1:0	0:0:6	
Pre-OP IOP (mmHg)	25 ± 8.4	19.6 ± 8.4	0.2877
Post-OP IOP (mmHg)	17.3 ± 2.87	15	
Optic disc tilt ratio	1.26 ± 1.19	1.22 ± 0.16	0.6964
Optic disc absolute rotational degree	10.4 ± 9.6	8.0 ± 4.4	0.5922
Beta-zone PPA to disc area ratio	0.61 ± 0.45	0.60 ± 0.34	0.9665
Received trabeculectomy (Yes: No)	4:2	1:5	

VA = Visual acuity, VF = visual field, MD = mean deviation, OP = operation, IOP = intraocular pressure, PPA = peripapillary atrophy.
Comparisons were performed by using independent t-test.
* P < 0.05

Table 3: Comparison of the eyes with VF defect and the fellow eye in subjects with unilateral VF defect.

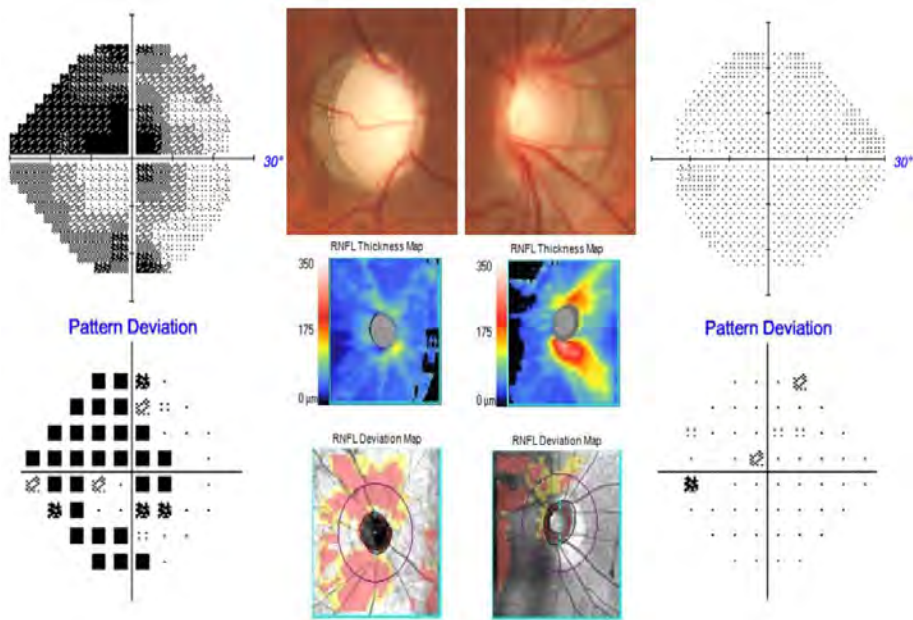


Figure 1: Representative case of a 28-year-old male with unilateral VF defect.

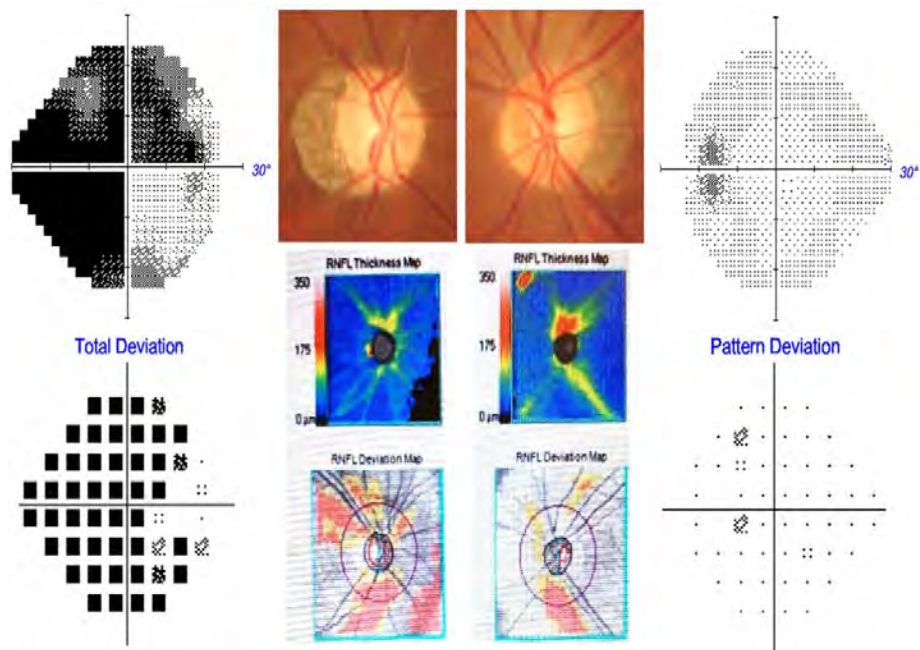


Figure 2: Representative case of a 43-year-old male with unilateral VF defect.

Topographic relationship between decreased parapapillary retinal microvasculature and retinal nerve fiber layer defect in myopic eyes with primary open-angle glaucoma

Chen Y^{1,2}, Tu P¹, Hung C¹

¹Cathay General Hospital, Taipei, Taiwan, China, ²School of Medicine, College of Medicine, Fu Jen Catholic University, Taipei, Taiwan

Introduction

To investigate the topographic relationship between the decreased parapapillary retinal microvasculature as assessed by OCTA and retinal nerve fiber layer (RNFL) defect in myopic eyes with primary open-angle glaucoma (POAG) and hemifield visual field (VF) defects.

Methods

A vascular impairment (VI) was identified in radial peripapillary capillary angiogram by the presence of a sign indicating decreased microvasculature. The topographic correlation between the VI and the RNFL defect was determined in the hemifields with corresponding VF defects. The topographic correlation between VI and a localized RNFL defect was assessed using Pearson's correlation coefficient. The correlations between the extent of VI/RNFL and VF severity (MD/VFI) were also analyzed. A *P* value of less than 0.05 was considered statistically significant.

Results

We included 22 eyes of 22 myopic subjects with POAG. The VI exhibited topographic correlations with the RNFL defect in terms of both the circumferential location ($r = 0.986$, $P < 0.01$) and the extent ($r = 0.400$, $P = 0.065$). There were no significant correlations between the extent of VI/RNFL and VF severity (MD/VFI) except the correlation between the extent of VI and VFI ($r = -0.413$, $P = 0.056$).

Conclusion

The decreased parapapillary retinal microvasculature had a good topographic relationship with the area of RNFL defect in myopic eyes with POAG. The extent of decreased parapapillary retinal microvasculature was associated with the severity of VF damage.

References

1. Akagi T, Iida Y, Nakanishi H, et al. Microvascular density in glaucomatous eyes with hemifield visual field defects: an optical coherence tomography angiography study. *Am J Ophthalmol*. 2016;168:237–249.
2. Lee EJ, Lee KM, Lee SH, Kim TW. OCT Angiography of the Peripapillary Retina in Primary Open-Angle Glaucoma. *Invest Ophthalmol Vis Sci*. 2016 Nov 1;57(14):6265-6270.

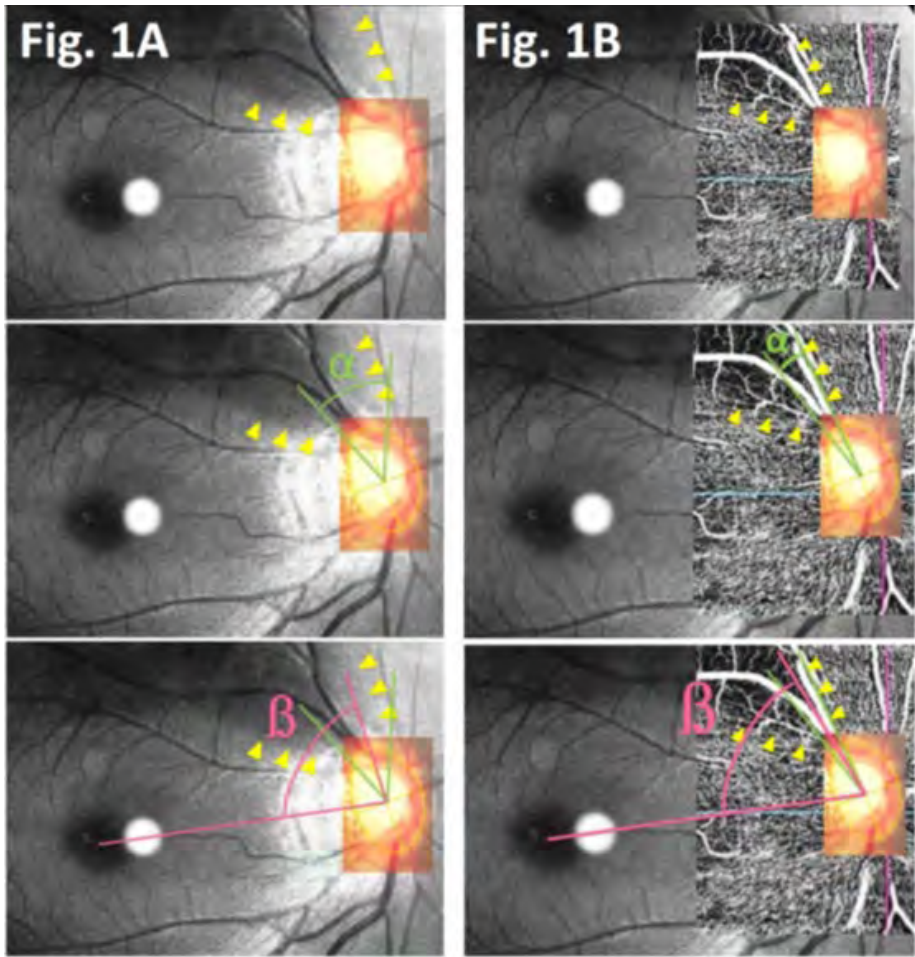


Figure 1: The circumferential location and the extent of the RNFL defect and VI were measured as the angular deviation of the midpoint of the RNFL defect or VI relative to the foveal-disc axis and as the angular extent of the RNFL defect or VI, respectively (1A and 1B).

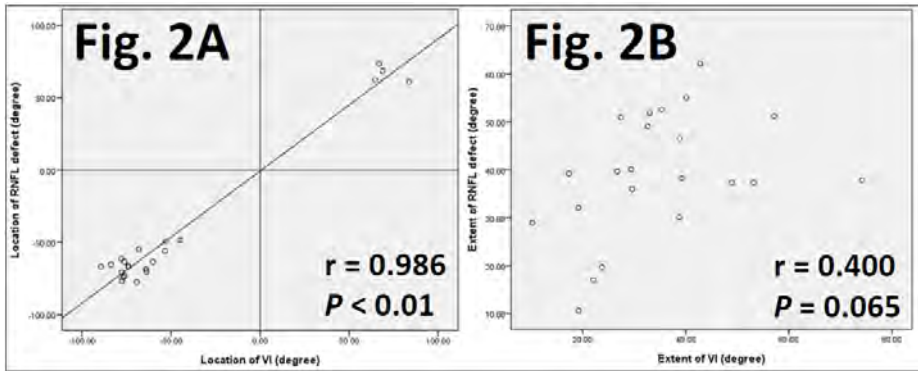


Figure 2: Scatter plots showing the topographic correlations between the VI and the RNFL defects. Positive and negative values of the locations of the RNFL defect and VI indicate the locations that are superior and inferior relative to the foveal–disc axis, respectively (2A and 2B).

Association between primary open-angle Glaucoma and an increased risk of ischemic heart disease: An 11-year population-based cohort study

Chen Y^{1,2}, Hung M³

¹Department of Ophthalmology, Taichung Veterans General Hospital, Taichung, Taiwan, ²Wilmer Eye Institute, Johns Hopkins University, , USA, ³Department of Medical Education, Taichung Veterans General Hospital, Taichung, Taiwan

Introduction

Although elevated intraocular pressure is the most common risk factor of primary open angle glaucoma (POAG), one hypothetical cause may be insufficient ocular blood flow leading to optic nerve ischemia and glaucomatous optic neuropathy. We conducted the study to investigate whether patients with POAG have a higher proportion of ischemic heart disease (IHD) development.

Methods

We used National Health Insurance Research Database (NHIRD) data in Taiwan for the entire population during 2001–2011 for this retrospective cohort study. 3,510 patients with POAG were enrolled into the POAG group and the comparison group consisted of randomly selected individuals, matched with the POAG group based on age, gender, and index date at a ratio of 1:4. Kaplan-Meier curves were used to compare the cumulative incidence of IHD between the two groups. Frailty model was used to estimate the crude and adjusted hazard ratio (HR) of IHD. Analyses were adjusted by age, gender, hypertension, diabetes mellitus, hyperlipidaemia, atrial fibrillation and congestive heart failure.

Results

The mean age of the cohort was 57.6±11.0 years and males were slightly more than females (51.6% vs. 48.4%). A log-rank test comparing Kaplan-Meier curves revealed a significantly higher cumulative incidence of IHD in the POAG group (p -value<0.001). In the univariate analysis by Frailty model, POAG patients had a significantly higher hazard of IHD (unadjusted HR = 2.32; 95% confidence interval

1.93 to 2.79). After adjustment, the increased risk remained significant (adjusted HR = 1.41; 95% confidence interval 1.16 to 1.72).

Conclusion

People with POAG may suffer from IHD more often than individuals without glaucoma.

Table 1. Characteristics of the study subjects

Variable	POAG ¹ group n=3510		Comparison group n=14040		p-value
	n (%)		n (%)		
Age , year, (mean SD ²)	56.7	11.0	56.7	11.0	1.000
Age , categorical					1.000
40-50	1096	(31.2)	4384	(31.2)	
50-60	1081	(30.8)	4324	(30.8)	
60-70	880	(25.1)	3520	(25.1)	
70	453	(12.9)	1812	(12.9)	
Gender					1.000
Male	1812	(51.6)	7248	(51.6)	
Female	1698	(48.4)	6792	(48.4)	
Diabetes mellitus					<0.0001

Yes	1208 (34.4)	2568 (18.3)	
No	2302 (65.6)	11472 (81.7)	
Hypertension			<0.0001
Yes	1894 (54.0)	5252 (37.4)	
No	1616 (46.0)	8788 (62.6)	
Hyperlipidaemia			<0.0001
Yes	1358 (38.7)	3590 (25.6)	
No	2152 (61.3)	10450 (74.4)	
Congestive heart failure			0.08
Yes	184 (5.2)	638 (4.5)	
No	3326 (94.8)	13402(98.7)	
Atrial fibrillation			0.09
Yes	60 (1.7)	186 (1.3)	
No	3450 (98.3)	13854 (98.7)	

¹ POAG, primary open-angle glaucoma

² SD, standard deviation

Table 2. Analyses of risk factors for IHD¹ in patients with and without POAG²

Predictive variables	Univariate analysis	Multivariate analysis ³
----------------------	---------------------	------------------------------------

	Unadjusted HR ⁴ (95% CI ⁵)	P value	Adjusted HR (95% CI)	p value
POAG (Yes vs. No)	2.32 (1.93–2.79)	<0.0001	1.14 (2.19–3.66)	0.0006
Age				
40-50	Reference		Reference	
50-60	2.84 (2.04–3.95)	<0.0001	2.14 (1.53-2.99)	<0.0001
60-70	4.45 (3.24-6.11)	<0.0001	2.63 (1.90-3.64)	<0.0001
70	5.86 (4.23-8.12)	<0.0001	2.97 (2.11-4.16)	<0.0001
Gender (Male vs. Female)	1.50 (1.26-1.79)	<0.0001	1.61 (1.35-1.93)	<0.0001
Hypertension	2.46 (2.03-2.99)	<0.0001	2.11 (1.68–2.64)	<0.0001
Diabetes	3.65 (3.05-4.36)	<0.0001	1.83 (1.50–2.23)	<0.0001
Hyperlipidemia	3.07 (2.57-3.68)	<0.0001	1.50 (1.22-1.83)	0.0001
Congestive heart failure	8.56 (6.89-10.63)	<0.0001	4.09 (3.24-5.17)	<0.0001
Atrial fibrillation	5.94(4.04-8.76)	<0.0001	1.94 (1.29-2.92)	0.0014

¹IHD, ischemic heart disease

² POAG, primary open-angle glaucoma

³ In the multivariable analysis, all the other variables in the Table are included for adjustment.

⁴ HR, hazard ratio

⁵ CI, confidence interval

Bilateral Iridoschisis with Primary Angle Closure Glaucoma and Corneal Decompensation: A case report

Chin C¹, Ettikan J¹, Govindasamy G¹, Hooi S¹, Vendargon F¹

¹Ophthalmology department, Hospital Sultanah Aminah, Johor Bahru, Malaysia

Introduction

Iridoschisis is characterized by splitting of the iris stroma into layers, with strands of anterior layer floating freely in the anterior chamber [1]. Iridoschisis typically affects patients of 6th to 7th decade, and often associated with angle closure glaucoma [1, 2].

Methods

Case report

Results

A 66-year-old gentleman presented with blurring of left nasal field which progressively generalized. His visual acuities were 6/12 and hand movement (HM) in right and left eye, respectively. Left relative afferent pupillary defect (RAPD) was elicited. Anterior segment examination showed bilateral clear cornea with iris atrophy inferiorly. Intraocular pressures (IOP) were raised and Shaffer's gonioscopy revealed closed angles. Bilateral peripheral iridotomy (PI) was performed. His IOP remained stable with three antiglaucoma drops. However, iridoschisis was not diagnosed at this point. Three years later, his visual acuity progressively worsened to 6/60 and HM. Left eye extracapsular cataract extraction was performed. Intraoperatively, lots of freely floating iris fibrils were observed. Postoperative vision remained the same. Anterior segment examination showed bilateral patchy anterior corneal scars with Descemet folds centrally, and iris atrophy inferiorly with iridocorneal touch (Figure 1&2). Anterior chambers (AC) were shallow but quiet bilaterally with normal IOP. Fundoscopy showed cup-to-disc ratio of 0.6 pink in right eye and 0.9 pale cupped disc in left eye. He was diagnosed with bilateral iridoschisis with primary angle closure glaucoma and

corneal decompensation, which is likely due to long-standing endothelial loss from iridocorneal touch from the iris strands in AC, and inflammation from PI and cataract surgery.

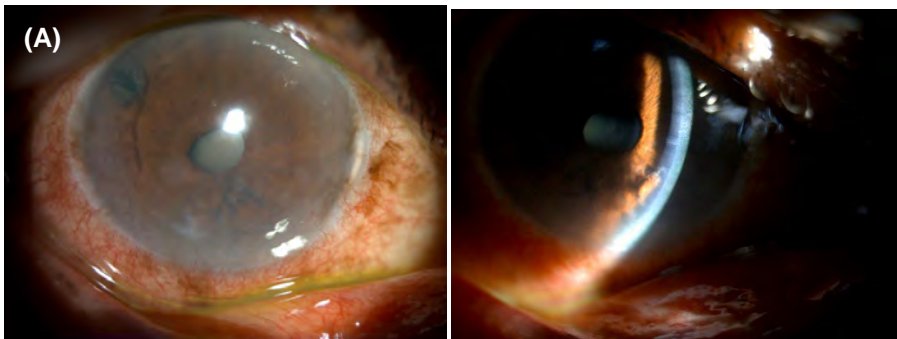
Conclusion

Although there are 100 reported cases of iridoschisis, only six cases of corneal decompensation secondary to iridoschisis were reported till date [2]. Ideally iridoschisis should be diagnosed preoperatively to ease the planning of surgery and post-operative care to achieve better outcomes.

References

1. Chen, Y., Y. Qian, and P. Lu, *Iridoschisis: a case report and literature review*. BMC Ophthalmology, 2017. **17**(1): p. 24.
2. Pegu, J., K. Jain, and S. Dubey, *Iridoschisis: Spectrum of Presentation*. Middle East African journal of ophthalmology, 2021. **27**(4): p. 224-227.

Figures



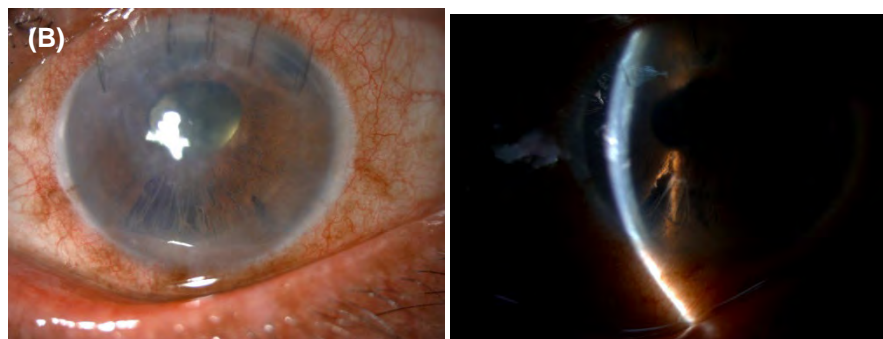


Figure 1: Anterior segment photos of right (A) and left (B) eyes

An Unusual Case of Pseudophakic Pupillary Block

[Chin Y¹](#), Tan L¹, Muji R¹, Mohamed Noor J¹

¹Hospital Kuala Lumpur, Kuala Lumpur, Malaysia

Introduction

To report an unusual case of a patient with primary angle-closure suspect (PACS) who developed pseudophakic pupillary block shortly after being treated for aqueous misdirection.

Methods

Case Report

Result

A 74-year-old man with right eye (RE) pseudophakia and PACS presented with anterior chamber (AC) shallowing and high intraocular pressure (IOP) during his routine follow-up. He had an uneventful cataract surgery many years earlier and a peripheral iridotomy (PI) done 2 years prior. A diagnosis of aqueous misdirection was made, Nd:YAG laser anterior hyaloidotomy was performed and topical atropine sulphate 1% was started. Despite the above treatment and maximum antiglaucoma therapy, the IOP continued to rise and subsequently the patient underwent a pars plana vitrectomy with surgical enlargement of his PI. Intraoperative findings revealed a non patent PI with lens capsule and remnant of cortical matter attached to it. Unfortunately, another episode of high IOP with shallow AC recurred. Suspecting a pupillary block, the iridotomy site was re-enlarged with Nd:YAG laser. Since then, the RE IOP has been maintained at 10mmHg with one antiglaucoma medication.

Conclusion

Secondary angle closure in eyes with posterior chamber IOLs is uncommon. This is an unusual case that involves both pupillary block and aqueous misdirection. Pupillary block must always be ruled out despite a visually patent PI.

Verified the Ganglion Cell Layer protection of Statins on the DBA2J mouse model for experimental glaucoma

Choi G¹, Kim M¹, Sung K²

¹Biomedical Research Center, College of Medicine, University of Ulsan, Asan Medical Center, Seoul, South Korea, ²Department of Ophthalmology, College of Medicine, University of Ulsan, Asan Medical Center, Seoul, South Korea

Introduction

The DBA2J (D2) mouse has been described as a anterior segment anomalies with synechiae and pigment dispersion for congenital experimental glaucoma. This research identified that intraocular pressure (IOP) elevation and glaucomatous damage at D2 glaucoma model. Statins such as Hyperlipidemia drug inhibit Muller gliosis and Ganglion cell death at D2 glaucoma model.

Methods

In order to confirm the increase in intraocular pressure according to the number of months of the D2 mouse model, the intraocular pressure was measured once a week using tonometer after respiratory anesthesia, and the retinal optic nerve layer was photographed after paramidine ocular examination. Statins drugs were administered at the same time every day for a total of 4 weeks. The control and Statins administered mice were CO₂ euthanized to remove the eyeball, and the changes in Muller gliosis and Ganglion Cell Layer (GCL) were compared through Immunohistochemistry (IHC) and Immunofluorescence (IF). In the case of Muller gliosis, it was dyed with GFAP, and in the case of GCL, it was confirmed by dyeing with CD90.1 and Brn3a, which are specific expression markers. And, Ganglion cell death was confirmed using an in situ cell death assay kit.

Results

In the case of the D2 mouse model, it was confirmed that pigment dispersion syndrome appeared and intraocular pressure increased from about 8 months or

more. Four weeks of administration of Simvastatin and Lovastatin have been shown to reduce Muller gliosis in retina.

In situ cell death assay results, it was confirmed that Ganglion cells was reduced by oral administration of Statins (Simvastatin, Lovastatin).

Conclusion

Oral administration of Simvastatin and Lovastatin is shown to reduce ganglion cell death in the GCL layer in DBA2J with glaucoma patterns by causing pigment dispersion syndrome for more than 9 months. It is possible to confirm the possibility of Simvastatin and Lovastatin as treatments for glaucoma.

Longer Tube-Iris Distance may cause Corneal Endothelial Cell Damage after Ahmed Glaucoma Valve Implantation

Choi W¹

¹Institute Of Vision Research, Department of Ophthalmology, Yonsei University College of Medicine, Seoul, Korea, Seoul, South Korea

Introduction

Purpose of the study was to investigate risk factors for corneal endothelial cell density (ECD) decline following Ahmed glaucoma valve (AGV) implantation from among a range of ocular and tube parameters and conduct analyses to determine the optimal cut-off values for the identified risk factors.

Methods

103 eyes (95 patients) that underwent AGV implantation were included in the study. We conducted consecutive t-tests between two groups separated by the ECD change rate to determine the survival state of the enrolled patients. Associations were evaluated using univariable and multivariable linear regressions.

Results

After implementing consecutive t-tests, only patients with an ECD change rate greater than -6.1%/year were considered to have survived. Tube-iris distance (TID) was the only statistically significant factor identified in both the univariable and multivariable linear regressions. The cut-off value determined from the consecutive Cox regression method was 0.33 mm (smallest p-value of 0.0087), and the cut-off value determined from the ROC method was 0.371 mm ([AUC], 0.662).

Conclusion

Patients with short TIDs showed a better ECD prognosis following AGV surgery; we suggest optimal TID cut-off values of 0.33 mm and 0.371 mm based on Cox regression and ROC methodology, respectively.

Axial length measurements for glaucoma screening reference in premature infants

Choo M^{1,2}, Grigg J², Surendran S¹, Peng L¹, Barnes E², Khaliddin N¹, Martin F², Zahari M¹

¹University Malaya Eye Research Centre, Kuala Lumpur, Malaysia, ²Save Sight Institute, University of Sydney, Sydney, Australia

Introduction

Incidence of glaucoma in retinopathy of prematurity (ROP) cohorts were 1.36-1.67% [1,2]. We report incidence in a well-characterised Malaysian ROP screening cohort. Glaucoma in premature infants included angle closure without pupillary block and neovascular glaucoma[3,4,5]. Altered anterior segment growth could be one mechanism. To investigate this we assessed axial length (AL), AC depth (ACD) and lens thickness (LT). Comparisons of mean ratios to adult values [6] may explain higher risk of angle closure glaucoma for this group.

Methods

This was a cross-sectional ocular biometric study of infants screened (2008-2017) divided into Group 1(Term,37-42weeks) measured using contact(ultrasound) method and Group 2(5 years old) measured with non-contact method (LENSTAR Erlangen, Germany). Results were compared between groups. Mean ratios were compared to adult(40-60years) calculated from Hashemi [6].

Results

Two cases of glaucoma/glaucoma suspect were identified giving incidence 0.8% (2/242). Mean AXL at term(n=113) was 16.63±0.54mm and 15.1±0.56mm at age 5years (n=129). AC depth were 1.91mm and 2.02mm respectively. Lens thickness 3.93mm and 3.92mm. One child with cdr 0.7, HCD 10mm, normal IOP at term had increased IOP (30mmHg) at 6 months. EUA confirmed Axenfeld anomaly with glaucoma. The axial lengths were 20.7 and 20.9mm at 10 months. Another infant

with craniofacial synostoses is monitored for glaucoma. Ratio of ACD:LT:AXL for term infants, 1:2.07:8.75(ACD:LT of Gp 1vs2, $p=0.028$) and 1:1.99:7.67(ACD:AXL between Gp 1vs2, $p<0.0001$) at 5 infer that in early infancy, lens is thicker compared to adult ratio of 1:1.63:8.83.

Conclusion

Incidence for glaucoma/glaucoma suspect was 0.8%. Mean AXL was 16.5mm(Term) and 15.10mm(age 5 years). There is increased ratio of lens thickness: AC depth in premature children.

Analysis of Ganglion Cell Complex to assess the progression of Glaucoma

[Choudhary S¹](#)

¹Shroff Eye Centre, New Delhi, India, ²Shroff Eye Centre, New Delhi, India

Introduction

Focal, especially inferior loss of GCC was demonstrated as the strongest single predictor of visual field progression. However, interindividual differences in parametric changes make a definitive diagnosis of change difficult. Therefore glaucoma patients with stable visual fields (assessed by event analysis on GPA) were analysed for changes in GCC parameters seen over a period of 5 years. This would provide a range for stability, against which parameters in progression could be identified.

Methods

Fifty consecutive glaucoma patients with stable reproducible visual fields and good quality OCT (SSI >40) were included in the study. Ganglion cell complex analysis reports done by RTvue (FD-OCT system) were assessed. GCC change was assessed both qualitatively and quantitatively.

Results

On quantitative evaluation, average GCC thickness was found to be 85.99 μ (range 74.39 μ - 104.19 μ). Average inferior GCC thickness was found to be 85.67 μ (range 75.2 μ - 109.63 μ). Mean change in average GCC thickness after 5 year follow up was -4.409 $\mu \pm 3.94$. Mean change in superior average was found to be -3.86 $\mu \pm 3.67$. Mean change in inferior average was found to be -4.66 $\mu \pm 4.99$. Mean FLV change was found to be 0.261 % (range -1.309 to 2.16)

Conclusion

Stable visual fields were associated with a change of average GCC thickness of -4.4 μ and FLV of 0.261% from the baseline after 5 year follow up. Changes on progression would likely be much greater.

References

1. Naghizadeh et al; Detection of Early Glaucomatous Progression With Different Parameters of the RTVue Optical Coherence Tomograph, Journal of Glaucoma: April/May 2014 - Volume 23 - Issue 4 - p 195-198 doi: 10.1097/IJG.0b013e31826a9707

Trabeculectomy with Antimetabolite Agents for Normal Tension Glaucoma: A Systematic Review and Meta-Analysis

Chin Lai¹, Shih-Chieh Shao³, [Lan-Hsin Chuang^{2,4}](#)

¹School of medicine, College of medicine, Kaohsiung Medical University, Kaohsiung, Taiwan

²Department of Ophthalmology, Chang Gung Memorial Hospital, Keelung, Taiwan

³Department of Pharmacy, Chang Gung Memorial Hospital, Keelung, Taiwan

⁴College of Medicine, Chang Gung University, Taoyuan, Taiwan

Introduction

Results regarding the treatment effects of trabeculectomy with antimetabolites for normal tension glaucoma (NTG) are conflicting. Our goal is to systematically assess the visual field (VF) progression rate and other treatment outcomes of trabeculectomy with antimetabolites for progressing NTG.

Methods

We searched published articles on PubMed, EMBASE, and the Cochrane Central Register of Controlled Trials from database inception to March 21, 2022.

We selected studies that reported VF progression data before and after trabeculectomy with antimetabolite agents for NTG. Data were extracted by 2 independent reviewers, and a random-effects model was employed for the meta-analysis. Study outcomes were VF progression rates, changes in antiglaucoma medications, and intraocular pressure (IOP). Subgroup analyses of the MD slope according to median age, baseline MD, and baseline IOP were performed to determine the robustness.

Results

We included 7 retrospective observational studies comprising a total of 166 eyes. Mean preoperative MD slopes ranged from -0.52 to -1.05 dB/year. The meta-analysis revealed significant MD slope improvement after trabeculectomy (pooled

mean difference: 0.54 dB/year, 95% CI: 0.40 to 0.67, I² = 9%). Median age, baseline MD, and baseline IOP subgroup analyses revealed MD slope results were consistent with those of the main analyses. The mean IOP and mean number of antiglaucoma medications significantly decreased after trabeculectomy.

Conclusion

The result of our study indicated that trabeculectomy with antimetabolites is beneficial for progressing NTG; it preserves visual function by alleviating the MD slope and reducing antiglaucoma medication use.

Utility of 3-0 Prolene Ripcord with Baerveldt-350 to Partially Occlude Tube Lumen and Minimize Hypotony-Associated Complications when Ligature Dissolves

Chun L¹, Qiu M¹

¹University Of Chicago Medical Center Department of Ophthalmology, Chicago, United States

Introduction

In this study, we retrospectively reviewed outcomes of a single surgeon's experience of using a 3-0 Prolene ripcord in the lumen of Baerveldt 350 Glaucoma Implants (BGI-350).

Methods

Retrospective chart review was performed on adult patients who had removable 3-0 prolene ripcords intraoperatively placed in the lumens of BGI-350s by a single surgeon. Demographics, clinical exam, and ripcord management outcomes were collected. Outcome variables included intraocular pressure (IOP), number of IOP-lowering medications, and anterior chamber (AC) inflammation at 2 time points: the soonest scheduled visit after the ligature suture dissolved and the postoperative day (POD) of ripcord removal.

Results

29 eyes from 26 patients underwent BGI-350. Mean age was 68.6 years. 26/29 (89.7%) eyes had primary open-angle glaucoma. 17 (58%) eyes had immediate ripcord removal, 11 (37.9%) eyes had delayed ripcord removal, and 1 (3%) eye had no ripcord removal. Among the eyes with delayed ripcord removal, 64% had IOP too low when the ligature dissolved, so some IOP-lowering medications were stopped prior to subsequent delayed ripcord removal to fully open the tube. 1 eye had mild AC shallowing when the ligature dissolved. No eyes had choroidal effusions or suprachoroidal hemorrhage when the ligature dissolved.

Conclusion

The intraoperative placement of 3-0 Prolene ripcords to partially occlude the lumen of BGI-350s may serve as a promising strategy to safely optimize and sustain postoperative IOP control, prevent hypotony, allow for improved patient outcomes.

References

1. Purtskhvanidze K, Saeger M, Treumer F, Roeder J, Noll B. Long-term results of glaucoma drainage device surgery. *BMC Ophthalmology*. 2019;19(1):14.
2. Christakis PG, Zhang D, Budenz DL, et al. Five-year pooled data analysis of the Ahmed Baerveldt comparison study and the Ahmed versus Baerveldt study. *Am J Ophthalmol*. 2017;176:118-126
3. An SJ, Wen JC, Quist MS, Mathenge EW, Vin A, Herndon LW. Scheduled postoperative ripcord removal in Baerveldt 350 implants: a prospective, randomized trial. *Journal of Glaucoma*. 2019;28(2):165-171.chroeder.com
4. Pollmann AS, Mishra AV, Campos-Baniak MG, Gupta RR, Eadie BD. Ab interno suture tube occlusion of the Baerveldt glaucoma implant for management of postoperative hypotony: A case series. *Am J Ophthalmol Case Rep*. 2020;19:100752.
5. Sharkawi E, Artes PH, Oleszczuk JD, et al. Systematic occlusion of shunts: control of early postoperative iop and hypotony-related complications following glaucoma shunt surgery. *J Glaucoma*. 2016;25(1):54-61.

Table 1.

	Ripcord Removal				
	Immediate	Delayed			Never
# Cases (%)	17 (58.6%)	11 (37.9%)			1 (3%)
		7 (63.6%)	2 (18.2%)	2 (18.2%)	
Reason for delayed or no ripcord removal	n/a	IOP low ^A	Excessive AC inflammation ^B	Logistical delay ^C	Persistent hypotony ^D
POD of ripcord removal	47 days	59.9 days	61.0 days	60.5 days	n/a
Mean IOP at ripcord removal	13.1 mmHg	7.1 mmHg	13.5 mmHg	11.5 mmHg	n/a
Mean # IOP-lowering meds at ripcord removal	3.6 meds	4.3 meds	4.0 meds	3.5 meds	n/a

POD = postoperative day; IOP = intraocular pressure; AC = anterior chamber

A: IOP was low at the soonest office visit after the ligature dissolved, so some IOP-lowering medications were stopped, and the patient followed-up at a future date for ripcord-removal when the IOP rose higher.

B: Patient inadvertently self discontinued or reduced topical steroid, so steroids were resumed / increased, and the patient followed-up at a future date for ripcord-removal when the AC was quiet.

C: Patient and glaucoma specialist were not available for close follow-up, so ripcord was left in place and follow-up was scheduled for a future date when close follow-up after ripcord removal was possible.

D: IOP was 9 on 0 meds, so ripcord was trimmed and left sub-conjunctivally; it can be removed in the future with a cut-down.

Figure 1: Intraoperative placement of 3-0 Prolene ripcord suture (blue) into lumen of BGI-350 to provide partial occlusion and 7-0 Polysorb ligature (purple).

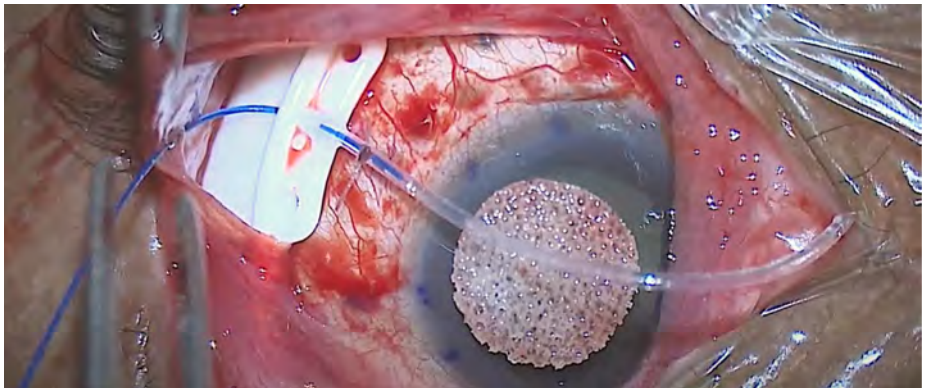
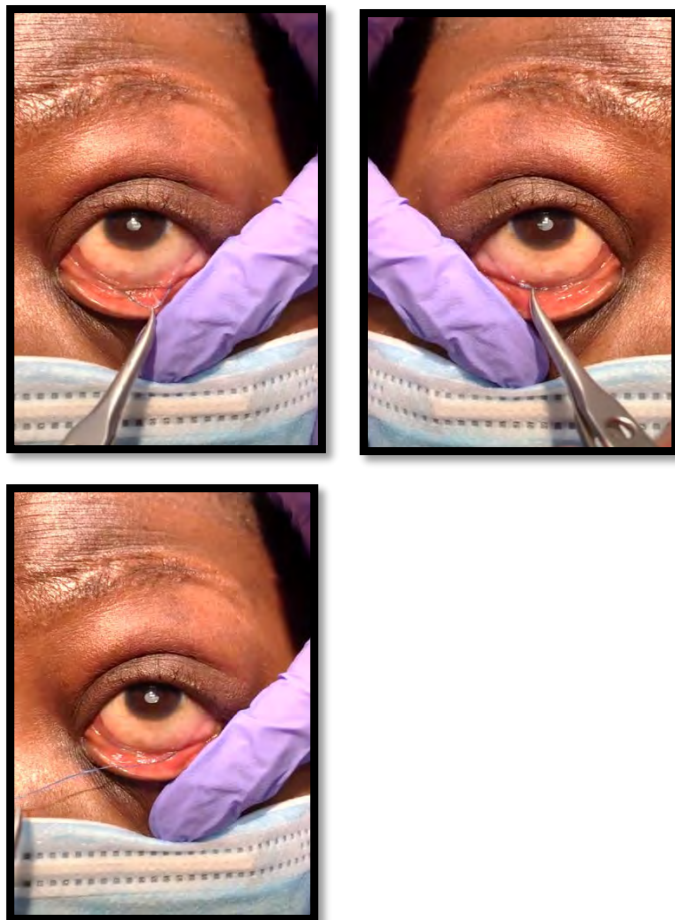


Figure 2: In-office removal of 3-0 Prolene ripcord (blue) from BGI- 350 lumen after ligature has dissolved.



Comparing the anterior chamber depth in East-Asian and non-East-Asian eyes

Dasgupta A1, Ong K2

¹University Of Sydney, Sydney, Australia, ²Royal North Shore Hospital, Sydney, Australia

Introduction

Eyes with shallow anterior chamber depth are predisposed to primary angle closure glaucoma. This study evaluated if a statistically significant difference exists in the mean ACD between East-Asian and non-East-Asian populations.

Methods

A retrospective cohort study was conducted on a sample of 4276 eyes. Data spanning 7 years was obtained from a private ophthalmology practice in Sydney using the Zeiss IOLMaster700. Patient files were stratified into three age groups (<40-years, 40-60 years, >60-years) and then further sub-divided by ethnicity (East-Asian and non-East-Asian). Analysis was conducted using IBM SPSS Statistics-26.

Results

The results demonstrate that age, gender, and ethnicity impact the ACD. ACD decreases with age uniformly across both genders and ethnic groups. East-Asians have a significantly shallower ACD compared to non-East-Asians in the >60-year age group. Females were demonstrated to have a shallower ACD compared to males at every age group.

Conclusion

The populations (female, East-Asian, >60-years) which this study shows to have shallower ACD. Eyes with shallow ACD are known to have a higher incidence of PACG. This study explains the higher incidence of PACG in East Asian eyes. The IOLMaster700 may be a useful screening tool for angle closure glaucoma by identifying patients with shallow ACD.

Outcomes of Virna Glaucoma Implant (VGI®) in patients with neovascular glaucoma in Cipto Mangunkusumo Hospital, Indonesia

Devona D¹, Oktariana V¹, Artini W¹, Suryono A¹, Yunard A¹, Laksmi Y¹

¹Department of Ophthalmology, Faculty of Medicine Universitas Indonesia, Cipto Mangunkusumo Hospital, Kota Administrasi Jakarta Pusat, Indonesia

Introduction

Glaucoma drainage device implantation is currently the main surgical treatment of choice in neovascular glaucoma (NVG) to control IOP. We aimed to evaluate outcomes of VGI®, a non-valved glaucoma implant, in NVG patients.

Methods

This retrospective study involved NVG patients who underwent implantation of VGI® (2019-2020), with at least 3- month follow-up. Cumulative success rate was defined as an IOP of 6-21 mmHg and $\geq 20\%$ IOP reduction at 6-12 months follow-up with or without glaucoma medication.

Results

Forty-five eyes were included (median age = 54.0 [min-max, 10.0-71.0] years; 57.8% males). Median preoperative IOP was 43 (13-77) mmHg. After a median follow-up of 6 months (3-24 months), IOP decreased by 65.1% (last visit IOP = 15 [3-60] mmHg, $p < 0.001$) compared to preoperative. Median IOP at 1, 3, 6, 9, and 12-month follow-up were 11 (2-64), 16 (4-47), 14 (3-55), 13 (3-60), 12 (3-35) mmHg, respectively. These were lower than preoperative IOP (all $p < 0.001$). Cumulative success rate was 76.7%. Changes of IOP over time in patients treated with intravitreal bevacizumab (IVB) were not different from those without IVB. The most common postoperative complications was hyphema (66.7%).

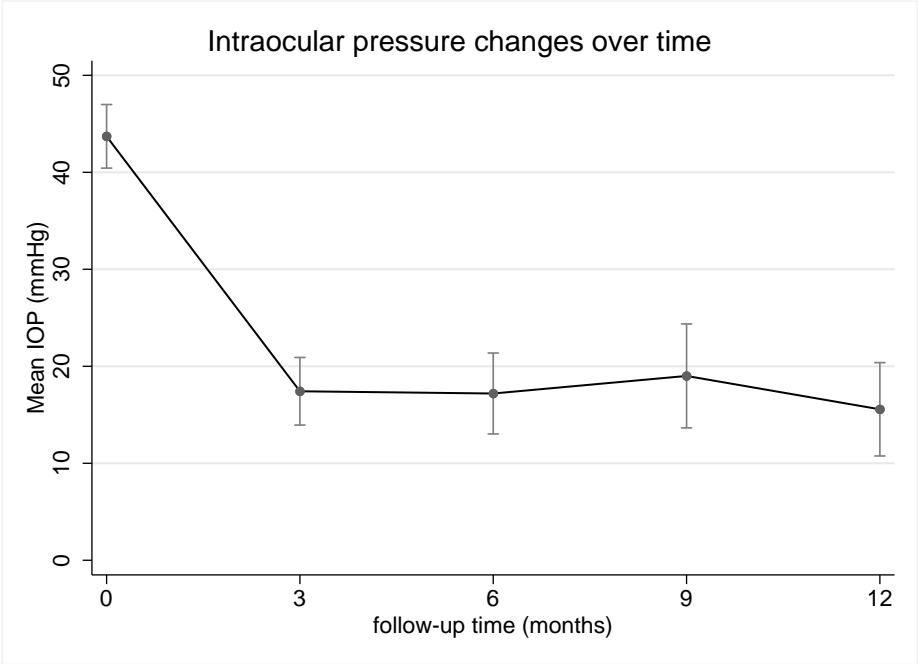
Conclusion

Virna Glaucoma Implant reduces IOP significantly in patients with NVG in a setting of tertiary hospital. The cumulative success rate seems comparable with previous studies using other implants.

References

1. Noor NA, et al. Glaucoma drainage device implantation with adjunctive intravitreal bevsacizumab in neovascular glaucoma: 3-year experience.(2017)*Clin Ophthalmol*.
2. Xie Z, et al. Efficacy of Ahmed Glaucoma Valve Implantation on Neovascular Glaucoma.(2019)*Int J Med Sci*.

Tables, figures, and illustrations



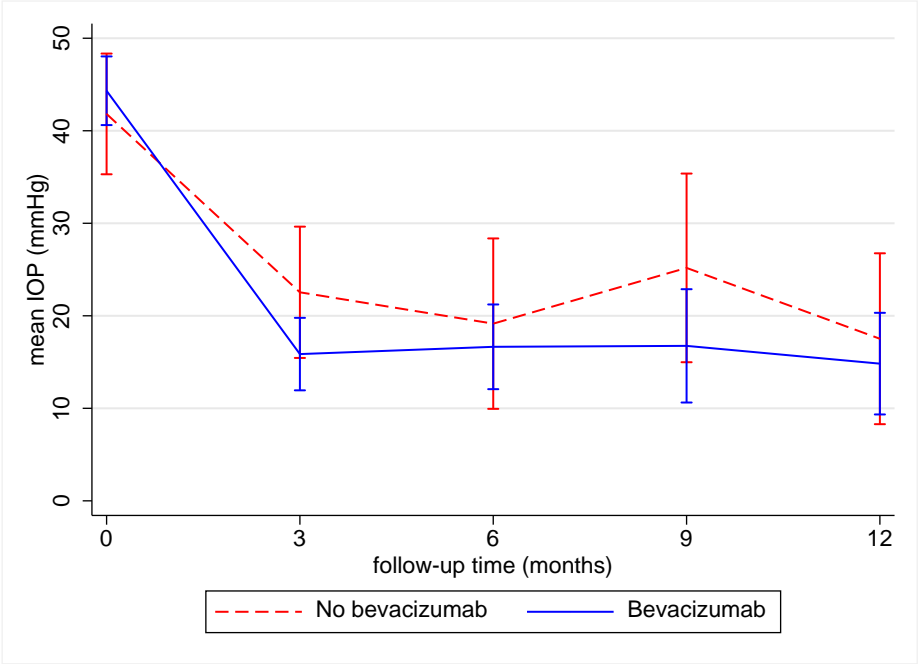


Figure 1. Changes of mean IOP over time (n=45)

Figure 2. Changes of mean IOP over time, by the use of bevacizumab (n=45)

Knowledge and Practice of Target Intraocular Pressure among Ophthalmologists and Trainees based on Malaysian Clinical Practice Guidelines

[Diana Toh S¹](#), Suhaily M², Azhany Y¹, Liza Sharmini A¹

¹Department of Ophthalmology and Visual Science, USM, Kota Bharu, Malaysia,

²Department of Community Medicine, USM, Kota Bharu, Malaysia

Introduction

To evaluate the knowledge and practice of target intraocular pressure (IOP) among ophthalmologists and trainees in Malaysia based on Malaysian Clinical Practice Guideline for glaucoma management.

Methods

A cross-sectional study was conducted between 1 January 2020 and 31 December 2021 involving 279 subjects (139 ophthalmologists and 140 trainees) working in various institutions in Malaysia. This study was divided into two phases. Phase I involved the development and validation of questionnaire on knowledge and practice in setting target IOP. Phase II involved an online survey using the validated questionnaire. Mean knowledge score and adherence to setting target IOP was compared between ophthalmologists and trainees.

Results

A total of 323 ophthalmologists and trainees were invited to participate, but only 279 (139 ophthalmologists and 140 trainees) responded (86.4%). Mean years of experience in ophthalmology practice was 7.4 (5.5) years. A total of 225 respondents (80.6%) adhered to setting target IOP. There was significant difference in the adherence between ophthalmologists (125, 89.9%) and trainees (100, 71.4%) ($p < 0.001$). Mean total score of knowledge among ophthalmologists (21.03 [95% CI:20.52,21.54]) was significantly higher than trainees (20.24 [95% CI:19.78,20.69]) ($p = 0.022$). There was significant association between mean total knowledge score and adherence in setting target IOP ($p = 0.002$). Poor

understanding (27.8%) and confusion in selecting the method of setting target IOP (35.2%) were the commonest reason among the non-adherences. The most popular method used was the percentage of IOP reduction from baseline.

Conclusion

There is the discrepancy in knowledge and practice of setting target IOP between ophthalmologists and trainees in Malaysia. An intervention program should be planned to address the discrepancy of standard clinical practice and prevention of glaucoma progression in Malaysia

Characteristic of Primary Congenital Glaucoma Patient in Kariadi Hospital during the COVID-19 Pandemic

Dimara S¹, Saubig A²

¹Resident of Ophthalmology Department of Diponegoro University, Kariadi Hospital, Semarang, Indonesia, ²Staff of Pediatric Ophthalmology Department of Diponegoro University, Kariadi Hospital, Semarang, Indonesia

Introduction

Primary congenital glaucoma (PCG) is a rare disease in children that occur early in life. The classic triad of signs of PCG include epiphora, photophobia, and blepharospasm. The purpose of this study was to describe the characteristics of PCG patients in Kariadi Hospital during the COVID-19 pandemic.

Methods

A retrospective, with descriptive approach on PCG patients who visited the eye clinic of Kariadi Hospital between January 2020 to March 2022.

Results

Fifteen eyes were examined, with the same number of lateralizations for unilateral and bilateral; most gender was male (60%), and onset occurred in neonates (60%). The triad of PCG symptoms were epiphora (80%), photophobia (10%), and blepharospasm (10%); and none of them have all three. Other signs were megalocornea (87%), corneal edema (73.3%), haab's striae (40%), and conjunctival injection (33.3%). The average of IOP was 36.77 ± 9.43 mmHg. Ultrasound examination results showed that all eyes had axial length lengthening. Seven eyes (47%) were performed trabeculotomy-trabeculectomy as the most therapy.

Conclusion

The results of this study showed that the majority of patients were male with the most onset in neonates. A longer study and involving larger subjects is needed to better describe the characteristics of PCG in the pandemic era.

References

1. American Academy of Ophthalmology. Pediatric Ophthalmology and Strabismus. San Fransisco; 2019.
2. Akbar, A., et al. Surgical Result of Goniotomy on Primary Congenital Glaucoma in Indonesia Patient. Ophthalmologica Indonesiana, 2021.
3. Sampaolesi R., et al. The Glaucomas: Pediatric Glaucomas. 2014.
4. Krieglstein G.K. And Weinreb R.N. Essential in Ophthalmology: Pediatric Ophthalmology, Neuro-Ophthalmology, Genetics. Germany: Springer; 2016.

Unilateral abducens nerve palsy, the lone sign and the lone side of cerebral venous thrombosis

EE SEE ONG D¹, Mohd Khialdin S¹, Wan Abdul Halim W¹, Yong M¹

¹Hospital Canselor Tuanku Muhriz, UKM, Cheras, Malaysia

Introduction

To describe a case of cerebral venous sinus thrombosis (CVST) with isolated unilateral abducens nerve palsy as the sole presentation.

Methods

Case report with literature review

Results

A 74-year-old male with underlying diabetes mellitus presented with horizontal diplopia for three days. He was otherwise well with no associated headache or other focal neurological deficits. Initial examination showed unilateral right isolated abducens nerve palsy. Optic nerve functions were preserved with no evidence of optic disc swelling. Initial computed tomography and subsequent magnetic resonance venography of the brain showed a filling defect of the right transverse sinus extending to the sigmoid sinus and right internal jugular vein, suggesting CVST. He was co-managed with the medical team for initiation of anticoagulation therapy. Literature review for unilateral abducens nerve palsy in CVST revealed six reported studies with various etiologies and associated deficits.

Conclusion

Neuroimaging for isolated unilateral abducens cranial nerve palsy plays a vital role in the early detection of a relative rare event- CVST. Early detection with prompt treatment will be able to avoid further complication.

Ocular Decompression Retinopathy after Trabeculectomy: A Case Report

[Elio P¹](#), [Cabrera C¹](#)

¹Amang Rodriguez Memorial Medical Center, Marikina City, Philippines

Introduction

This is a case of a 44 year-old female with elevated intraocular pressure who had ocular decompression retinopathy after trabeculectomy.

Methods

The patient consulted due to sudden left eye pain associated with blurring of vision, left-sided headache, nausea, and vomiting. Visual acuity was hand movement. Conjunctival hyperemia, corneal edema, shallow anterior chamber, mid-dilated pupil, and intraocular pressure of 58 mmHg on the affected eye were noted. Gonioscopy revealed 360 degrees synechially closed angles. Cup-to-disc ratio was 0.8 with concentric neuroretinal rim thinning. Retinal examination was unremarkable Patient was diagnosed with acute primary angle closure glaucoma on the left eye.

Results

Patient underwent trabeculectomy with early and slow paracentesis, viscoelastic injection, and pre-placed sutures to avoid sudden and prolonged hypotony. One day post-operatively, visual acuity was still hand movement, intraocular pressure dropped to 18mmHg, and fundoscopy revealed multiple superficial and deep blot intraretinal and flame-shaped hemorrhages with distinct white centers scattered all over the retina. Patient was assessed to have ocular decompression retinopathy for which no additional intervention was given. Six months post operatively, vision improved to 20/125 with complete resolution of the hemorrhages.

Conclusion

Ocular decompression retinopathy is a rare complication that occurs after any procedure that causes acute intraocular pressure lowering. It frequently presents as multiple intraretinal hemorrhages with white centers (Roth spots) at the posterior pole. Vascular and mechanical theories have been proposed to explain its pathophysiology. Management is mostly conservative because of its benign course with the visual acuity returning to preoperative levels even without treatment.




Figure 1. Fundus findings one day post-operatively showing multiple superficial and deep blot intraretinal and flame-shaped hemorrhages with distinct white centers scattered all over the retina

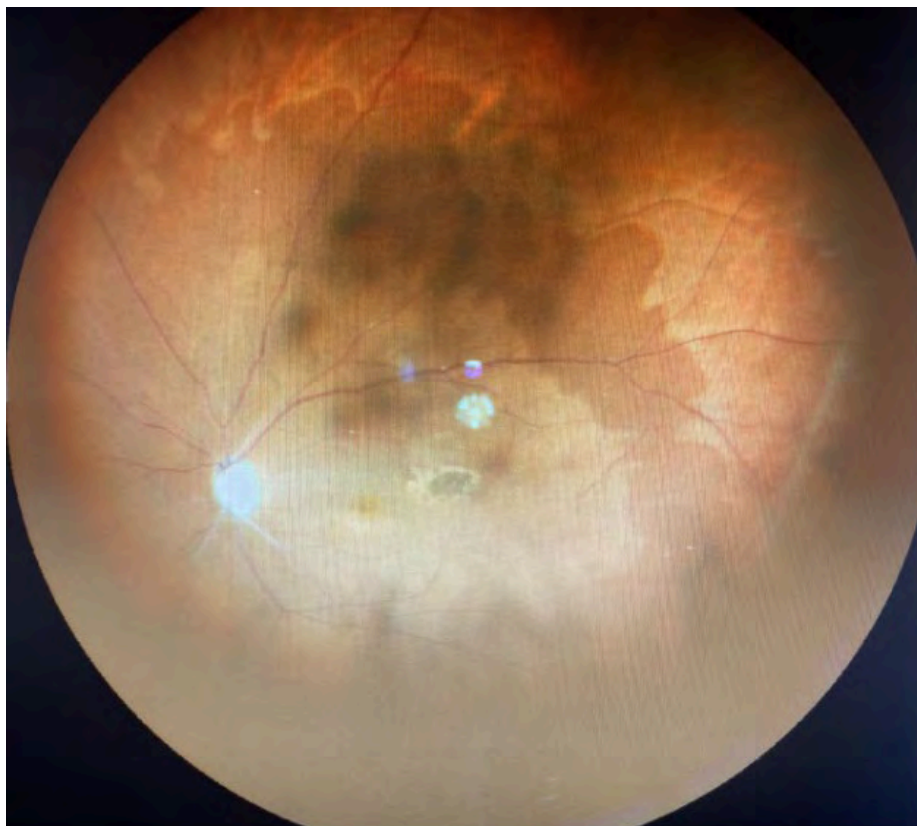


Figure 2. Fundus photo six months post-operatively showing complete resolution of the hemorrhages.

Isolated homonymous hemianopia; a rare presentation of posterior cerebral artery infarct

[Etthirajan T¹](#)

¹Hospital Selayang, Batu Caves, Malaysia

Introduction

Ischemic stroke presents with various physical malfunctions. Visual disturbances may be related to limb and facial weakness or could be the only presenting symptom.

Methods

Case report

Results

We report a 49-year-old man with uncontrolled co-morbidities, visited Ophthalmology clinic for sudden bilateral eye blurring of vision, specifically unable to see the periphery of words while reading. Examination showed bilateral eye normal anterior and posterior segments with 14mmHg intraocular pressure. Visual acuity was 6/24 improved to 6/12 with pinhole in right eye and 6/12 not improving with pinhole in left eye. Confrontation test showed right sided visual field defect which later confirmed to be right homonymous hemianopia using Humphrey visual field test. Other central nervous system examinations were absolutely normal. Computed Tomography (CT) of brain revealed left posterior cerebral artery infarct.

Conclusion

Visual symptoms may not always accompany other neurological manifestations of stroke but can also be the isolated sign in rare occasions. Detail history, examination and targeted investigation aid the diagnosis.

References

1. Text: Merwick Á, Werring D. Posterior circulation ischaemic stroke. *BMJ*. 2014;348 (may19 33): g3175.
2. Searls DE, Pazdera L, Korbel E et-al. Symptoms and signs of posterior circulation ischemia in the new England medical center posterior circulation registry. (2012) *Archives of neurology*. 69 (3): 346-51
3. Okkes Kuybu, Rimal H. Dossani. Posterior Cerebral Artery Stroke. (2018) Pubmed
4. Zhang, Xiaojun MD; Kedar, Sachin MD; Lynn, Michael J MS; Newman, Nancy J MD; Biousse, Valérie MD, Homonymous Hemianopia in Stroke, *Journal of Neuro-Ophthalmology*: September 2006 - Volume 26 - Issue 3 - p 180-183

The Surgical Outcome of Minimally Invasive Glaucoma Surgery (MIGS)- XEN implant in Hospital Kuala Lumpur (HKL)

Foo Yuen Cheng F^{1,2}, Abdul Rashid M¹, Jeffrey S¹, Muji R¹, Bahari N¹, Singh S²

¹Hospital Kuala Lumpur (HKL), KUALA LUMPUR, Malaysia, ²University of Malaya, KUALA LUMPUR, Malaysia

Introduction

Glaucoma is the third-commonest cause of blindness (6.6%) in Malaysia based on the National Eye Survey Malaysia(NESII)¹. MIGS implant has increased in its usage as an alternative for less invasive glaucoma surgery in mild-to-moderate glaucoma. They are categorised based on mechanism of action². Xen implant is channeling aqueous flow via subconjunctival drainage.

Methods

Retrospective review of medical note of all types of glaucoma patients whom underwent MIGS(Xen) implantation augmented with mitomycin C.

Results

A total of 24 eyes post Xen implant had follow-up for at least 1year(n=24). Among these, 33%(8eyes) was combined Xen+Phacoemulsification+Intraocular(IOL) implant. Majority was diagnosed with POAG(42%). A 33% reduction in mean IOP was observed when it dropped from 20.3 ± 9.0 mmHg at baseline to 13.7 ± 3.5 mmHg at 12 months follow-up. Mean follow-up duration was 18.5 months. The mean number of IOP-lowering medication dropped from 3.2 ± 1.0 to 1.7 ± 1.4 on last-review. For postoperative intervention, 18 eyes had bleb needling and 3 eyes needed open revision. Three patients underwent additional glaucoma filtration surgery with a median of 17 months post-operation. One patient had post operative conjunctival erosion while another patient needed explantation for implant dislocation into the anterior chamber.

Conclusion

Xen implant demonstrated a efficient and safe IOP-lowering effect as well as reduction in the number of antiglaucoma medication. A larger cohort and longer follow up can give a better insights.

References

1. Chew FLM, Salowi MA, Mustari Z, et al. Estimates of visual impairment and its causes from the National Eye Survey in Malaysia (NESII). *PLoS One*. 2018;13(6):e0198799. Published 2018 Jun 26. doi:10.1371/journal.pone.0198799
2. Saheb H, Ahmed II. Micro-invasive glaucoma surgery: current perspectives and future directions. *Curr Opin Ophthalmol*. 2012;23(2):96-104.doi:10.1097/ICU.0b013e32834ff1e7

Prevalence of ocular surface disease in Malaysian glaucoma patients

Gan E¹

¹International Specialist Eye Centre, KL, Kuala Lumpur, Malaysia

Introduction

Glaucoma is a progressive optic neuropathy due to degeneration of retinal ganglion cells, which results in cupping of the optic nerve head and visual-field damage.^{1,2} Elevated intraocular pressure (IOP) is the most significant modifiable risk factor for the development and progression of glaucoma.^{2,3} A common concern with the chronic use of IOP-lowering eye drops is ocular surface disease (OSD), whereby 45-60% of patients on these eye drops usually present with OSD.^{3,4} There has been no nationwide study in Malaysia to ascertain the prevalence of OSD among glaucoma patients, and as such this study would provide insights on managing glaucoma patients better.

Methods

This was multi-centre, cross sectional observational study. The primary objective of this study is to determine the prevalence of OSD in glaucoma patients, nationwide. Corneal and conjunctival fluorescein staining score, Hyperemia score, Tear break up time (TBUT) and Schirmer's test were measured. 406 adult patients diagnosed with primary open angle glaucoma (POAG), primary angle closure glaucoma (PACG), pseudoexfoliation glaucoma, pigment dispersion glaucoma or ocular hypertension (OHT), on anti-glaucoma medications for more than 6 months, with IOP readings ≤ 21 mmHg were enrolled in this study.

Results

The corneal and conjunctival fluorescent score were both low with relatively higher score at the inferior zone. Out of the 406 patients evaluated, more than half of the eyes had mild bulbar and palpebral conjunctival hyperaemia, less than 20% had moderate to severe hyperaemia. 90% of the eyes had abnormal TBUT while 70% exhibited abnormal Schirmer's test.

Conclusion

Majority of our glaucoma pts has positive signs of dry eye, mild in severity for corneal/ conjunctival fluorescent stain and hyperaemia but more severe in impaired TBUT and Schirmer's test.

References

1. Harasymowycz P, Birt C, Gooi P, et al. Medical management of glaucoma in the 21st century from a Canadian perspective. J Ophthalmol 2016;Volume 2016:Article ID 6509809.
2. Jonas JB, Aung T, Bourne RR, et al. Glaucoma. Lancet 2017;390:2083-2093.
3. Pérez-Bartolomé F, Martínez-de-la-Casa JM, Arriola-Villalobos P, et al. Ocular surface disease in patients under topical treatment for glaucoma. Eur J Ophthalmol 2017;27:694-704.
4. Mathews PM, Ramulu PY, Friedman DS, et al. Evaluation of ocular surface disease in patients with glaucoma. Ophthalmology 2013;120:2241-2248.

MY-OSD study group**

- 1) International Specialist Eye Centre, KL
Dr Fang Seng Kheong, Dr David Woo Wen Wei, Dr Gan Eng Hui
- 2) ParkCity Medical Centre:
Dr Lee Ming Yueh
- 3) Tun Hussein Onn National Eye Hospital
Dr Pall Singh
- 4) Synergy Specialist Eye Centre, KK
Dr Kong Vui Yin
- 5) Lee Eye Centre
Dr Lee Mun Wai
- 6) Mahkota Medical Centre
Dr Liao Kok Liang

A rare case of buphthalmos in a case of primary juvenile glaucomaGandhi A¹¹Samrpan Eye Hospital, Palanpur, India

A rare case of Buphthalmos in Primary Juvenile Glaucoma A 16-year-old female presented in Eye OPD with a chief complaint of enlargement of the right eye and diminution of vision in the right eye for five months. Vision in the right eye is CFCF and left eye 6/9. IOP of the right eye is 40mm of hg and the left eye is 36 mm of hg. In the right eye, a patient has buphthalmos and megalocornea. On gonioscopy, a patient has trabeculodysgenesis. And patient had 0.9 cupping with all rim thinning in the right eye. The patient was diagnosed with primary juvenile glaucoma with buphthalmos in right eye. And patient underwent glaucoma surgery for the right eye.

A comparative study on the efficacy of latanoprost (0.005%) vs netarsudil (0.02%) in reduction of intraocular pressure in ocular hypertension

Ghosh S¹, Ray Bhadra T¹

¹Regional Institute of Ophthalmology Kolkata, Jamshedpur, India

Objective

To compare the efficacy of latanoprost (0.005%) with netarsudil (0.02%) in intraocular pressure reduction in ocular hypertensive patients.

Methodology

This is an interventional double blinded study in which patients were randomly allocated between two groups, one group receiving eye drop latanoprost(0.005%) (n=25) and the other group receiving eye drop netarsudil(0.02%) (n=25) everyday in one eye and a placebo drug in the other eye. IOP was measured after 6 weeks of drug instillation. The patients were kept in follow up for a period of 18 months.

Results

From the study we found the mean IOP of the latanoprost group to be 25.4 ± 5.11 mm Hg before and 20.2 ± 3.58 mm Hg after drug instillation (20% reduction noted) after 6 weeks. On the other hand in the netarsudil group we found IOP to be 24.46 ± 2.96 mm Hg before and 12.92 ± 3.42 mm Hg after drug instillation (42% reduction noted) after 6 weeks. Over a period of 18 months, IOP was maintained and there was no change in the vertical cup disc ratio and the visual fields of the patients of the netarsudil group. Also there was no need of combined therapy as compared to latanoprost group in which newer drugs were further added.

Conclusion

Thus we can make out from the study that netarsudil(0.02%) is a better drug in terms of efficacy as compared to latanoprost(0.005%) in ocular hypertension

Efficacy of A2B retrobulbar tube shunt in primary congenital glaucoma

Griffin J¹, Fang J², Bharwani S², March de Ribot F³, Sponsel W¹

¹WESMDPA Glaucoma Service, San Antonio, United States, ²Medical University of Silesia, , Poland, ³Universitat Autònoma de Barcelona, , Spain

Introduction

The purpose of this study is to examine the efficacy of the blebless A2B (anterior to back) retrobulbar tube shunt in lowering intraocular pressure (IOP) among eyes with primary congenital glaucoma (PCG) following failure of other medical and surgical IOP-lowering therapies.

Methods

Prospective study, single-site, nonrandomized. Patients with PCG refractory to prior surgical treatment underwent A2B-shunt implantation, a procedure requiring minimal dissection as there is no plate involved for implantation. Each patient's IOP and medication requirements were compared to preoperative baseline values for 6mo postoperatively using paired t-tests.

Results

7 eyes of 7 patients (mean age 8.4 ± 1.2) were followed for 6mo. Mean IOP (mmHg \pm SEM) improved from baseline 36.6 ± 3.3 to 19.4 ± 3.6 (-47%; Δ -17.2; $p < 0.01$) at 6mo. Mean number of glaucoma medications (\pm SEM) at 1, 3, & 6mo decreased from baseline 2.7 ± 0.6 to 0.0, 0.3 & 0.4, ($p = 0.002$, 0.005, and 0.03) respectively. Complete (no meds < 21 mmHg) and qualified success (any meds < 21 mmHg) rates at 6 months were 60.0% and 80.0% respectively.

Conclusion

The retrobulbar tube shunt was an effective rescue surgery in a high proportion of these PCG patients for whom prior standard tube shunt surgeries had failed.

Anterior chamber morphology changes in eyes with narrow angles by Scheimpflug imaging: Pilocarpine versus laser peripheral iridotomy

Gupta R1

¹Sunetram Eye Care, New Delhi, India

Introduction

Argon and neodymium(Nd): yttrium-aluminum-garnet(YAG) lasers are widely used when performing laser peripheral iridotomies. However, its long term effectiveness depends on stage of disease and mechanism of angle closure(plateau iris or anteriorly directed ciliary processes) and is variable.¹

Rationale

To evaluate morphometric variables[anterior chamber angle(ACA), anterior chamber volume (ACV) and central anterior chamber depth(CACD)] after pilocarpine administration and laser peripheral iridotomy(LPI) in eyes with primary angle closure disease (PACD).

Methods

Ninety one eyes of 91 patients with narrow angles were consecutively enrolled in this prospective interventional cohort study and were classified into primary angle closure suspect (PACS), primary angle closure (PAC) and primary angle closure glaucoma(PACG). ACV, ACD and ACA were evaluated using Scheimpflug imaging technology at three time points: at baseline(T0), 45 minutes after application of pilocarpine before LPI(T1) and at one month post LPI(T2).

Results

PACS, PAC and PACG groups included 25(27.4%), 24(26.3%) and 42(46.1%) eyes respectively. At T1 and T2, mean pupil diameter, ACV & ACA changed significantly($P=0.00$). In all sub-groups, ACD decreased significantly at T1 & then increased significantly at T2. ACA was widened by 6 degrees in angles< 26 degrees

as compared to 3 degrees in >26 degrees eyes. In PACG group, mean ACV increased significantly between T0 & T2($P=0.0$). Other parameters like mean cornea volume ($P=0.27$), central corneal thickness($P=0.29$) showed no significant change between time points(T0, T1 & T2). Pilocarpine instillation caused significant increase in ACA, ACV and ACD.

Conclusion

Scheimpflug imaging detected significant changes in ACD post-LPI and post-pilocarpine in all groups. However, ACV changed significantly only in PACS & PACG. Our study also confirms that LPI is more effective than pilocarpine in widening the iridocorneal angles in angle closure disease.

Reference

1. Nolan WP, Foster PJ, Devereux JG et al. Yag laser iridotomy treatment for primary angle closure in East Asian eyes. Br J Ophthalmol 2000;84:1255-1259.

Effects of trans-resveratrol on connective tissue growth factor and fibronectin expression in dexamethasone-treated human trabecular meshwork cells

Hassan M², Abu Hanipah N¹, Agarwal R³, Razali N¹

¹Department of Pharmacology, Faculty of Medicine, UiTM Sungai Buloh, Sungai Buloh, Malaysia, ²Institute of Medical Molecular Biotechnology, UiTM Sungai Buloh, Sungai Buloh, Malaysia, ³School of Medicine, International Medical University (IMU), Bukit Jalil, Malaysia

Introduction

Increased deposition of extracellular matrix (ECM) proteins such as fibronectin (FN) in trabecular meshwork leads to elevated intraocular pressure (IOP), a well-known risk factor for glaucoma. Connective tissue growth factor (CTGF) is known to induce FN expression. *Trans*-resveratrol (TR) was shown previously to reduce the IOP in oculohypertensive rat model; however, whether this effect is mediated via downregulation of CTGF leading to reduced FN deposition is unknown. This study investigated the effects of TR on CTGF and FN expression in dexamethasone-treated human trabecular meshwork cells (HTMCs).

Methods

Primary HTMCs were incubated with dexamethasone (100 nM) alone or dexamethasone with TR (12.5 μ M). CTGF and FN gene and protein expressions were determined after 3- and 7-days incubation, respectively.

Results

Dexamethasone-treated HTMCs showed significantly higher FN gene (2.9-folds) and protein expression (1.2-fold) ($p < 0.05$) compared to vehicle-treated HTMCs. Co-treatment of HTMCs with dexamethasone and TR significantly reduced FN gene and protein expression by 3.2- and 1.4-folds, respectively ($p < 0.05$). Dexamethasone caused significantly greater CTGF gene and protein expression compared to

control group. HTMCs co-treated with dexamethasone and TR showed significantly lower CTGF gene and protein expressions, though the differences were not significant.

Conclusion

TR suppresses dexamethasone-induced FN gene and protein expressions in HTMCs. Although similar trend was observed for CTGF, the differences were not significant. Further studies are needed to elucidate the mechanisms of TR-induced suppression of FN deposition by HTMCs. This study is supported by grant no. 600-IRMI/FRGS 5/3 (413/2019).

Atypical bilateral direct carotid-cavernous fistula secondary to internal carotid aneurysm in an elderly lady

Hassan S¹, Cheng T¹, Che-Hamzah J¹

¹Ophthalmology Department, Hospital Canselor Tuanku Mukhriz, Bandar Tun Razak, Kuala Lumpur, Malaysia, Bandar Tun Razak, Malaysia

Introduction

Carotid-cavernous fistula (CCF) can be divided into direct and indirect type. Indirect CCF is more common in post-menopausal women. We aim to report a bilateral direct CCF secondary to internal carotid aneurysm at atypical location.

Methods

Case report

Results

We report a case of a 76 year old Chinese lady with underlying hyperlipidemia who had a left direct carotid cavernous fistula (CCF) treated with embolization 5 years ago came with contralateral involvement. She was stable until she developed new onset of right sided severe, throbbing headache associated with audible whooshing sound which was louder at right ear for 2 weeks before her presentation. She then developed sudden onset of right droopy eyelid, binocular diplopia and generalized blurring. On examination she was noted to have right multiple cranial nerve (III, IV and VI) palsies, conjunctival chemosis, corkscrew vessels, audible carotid bruit over right eye suggestive a right CCF with cavernous sinus syndrome. Cerebral angiography was done and revealed a large, wide neck aneurysm arising from the inferior aspect of the right cavernous internal carotid artery (ICA). A small direct anterior communication with the right cavernous sinus was suggestive of the point of fistulation. Intervention radiologist proceeded with coiling and embolization of the right CCF. The coils were deployed across the fistula, partly in the cavernous sinus and partly in the aneurysm while a flow diverter stent was deployed across the aneurysm neck. Her headache resolved

immediately after the procedure, while the diplopia and audible whooshing sound improved after few months.

Conclusion

Bilateral direct CCF secondary to aneurysm at the atypical location require an early intervention by intervention radiologist to prevent devastating complications of this disease.

References

1. (Masahiro Yoshida, July 2011)
2. (Sixto Obrador, April 1974)
3. (Andrew J. Ringer, 2005)

Sustained 5-year glaucoma control after second-generation trabecular micro-bypass with or without cataract surgery

Hengerer F¹

¹University Eye Hospital at University of Heidelberg, Heidelberg, Germany,

²Department of Ophthalmology, Buerger hospital, Frankfurt, Germany

Introduction

The current study evaluated 5-year (5yr) effectiveness and safety of iStent inject implantation with or without cataract surgery (Combined/Comb or Standalone/SA subgroups, respectively).

Methods

This prospective, non-randomized, unmasked, longitudinal case series included 125 consecutive iStent *inject* cases of a single surgeon at a large German academic hospital. Patients had variable preoperative (preop) disease severities and surgical histories; 97% reached the 5yr visit. Intraocular pressure (IOP), medications (meds), and safety were assessed through 5yr in All Eyes and in Comb (n=81) and SA (n=44) subgroups. The completion of both types of procedures by the same surgeon in the same setting enables validation of long-term stent performance independent from cataract extraction.

Results

Preop mean IOP in All Eyes was 23.5 ± 6.2 mmHg on 2.68 ± 1.02 mean meds, reducing to 14.1 ± 1.8 mmHg on 0.77 ± 0.82 meds at 5yr (40% and 71% reductions, respectively; both $p < 0.001$). All but 1 eye (>99%) took med(s) preop, but 46% were med-free at 5yr ($p < 0.001$). In Comb eyes, mean IOP decreased by 39% (22.6 ± 13.8 mmHg, $p < 0.001$) and meds by 69% (2.52 ± 0.78 , $p < 0.001$). In SA eyes, mean IOP reduced by 42% (25.3 ± 14.6 mmHg, $p < 0.001$) and meds by 75% (2.98 ± 0.74 , $p < 0.001$). At last follow-up, 83% of eyes achieved $\geq 20\%$ IOP reduction, >99% had the same or lower IOP, and 100% maintained or reduced meds vs preop. There were 0 intraoperative complications and 0 filtration surgeries.

Conclusion

iStent *inject* implantation with or without phacoemulsification produced significant and durable 5yr decrease in IOP (~10-mmHg reduction) and meds (~2-med reduction, nearly half of eyes med-free) in this prospective cohort of patients with high preop disease burden. Comb and SA cases had similarly favorable effectiveness and safety.

Clinical characteristics of patients with severe primary angle closure glaucoma

Hlaing T¹, Aung T^{1,2,3}, Nongpiur M^{1,2,3}

¹Singapore Eye Research Institute, Singapore, Singapore, ²Singapore National Eye Centre, Singapore, Singapore, ³DukeNUS Medical School, Singapore, Singapore

Introduction

To investigate and compare the clinical characteristics of patients across varying severity of primary angle closure glaucoma (PACG)

Methods

In this study, we retrospectively extracted the following clinical data from the case records of 563 PACG patients: the age at diagnosis of PACG, presenting intraocular pressure (IOP), gonioscopy data performed prior to laser or surgical intervention, visual field mean deviation (MD) at presentation, ocular biometry, and pre-surgery refractive data. One eye of each patient was analysed. For bilateral cases, the worse eye based on visual field MD was selected, whereas the affected eye was used in unilateral cases. Patients with previous acute primary angle closure (APAC) were excluded. Disease severity was based on the visual field MD and classified as having early-to-moderate (≥ -12 dB), advanced (-12.01 to -20.00 dB) and severe (< -20 dB).

Results

At presentation, the 563 patients were categorized as having early-to-moderate (n=268), advanced (n=115) and severe PACG (n=180) respectively. Of these, 51.3% were male, and the mean visual field MD at presentation was -14.5 ± 10.0 dB. Patients with severe disease at presentation were more likely to be male (63.9%), compared to 50.0% in early-to-moderate and 34.8% in advanced, $p < 0.001$; and they were also diagnosed at a significantly younger age compared to early-to-moderate and advanced PACG (65.4 ± 8.3 versus 67.9 ± 8.7 and 66.2 ± 8.9 years, ANOVA $p < 0.001$) respectively. The severe PACG group were also found to have the highest

IOP at presentation (ANOVA $p<0.001$) and narrowest anterior chamber angles on gonioscopy (ANOVA $p<0.001$); whereas axial length was longest in the early-to-moderate group (ANOVA $p=0.005$). There were no significant differences in the measurements of the anterior chamber depth, lens thickness, and spherical equivalent between the three severity groups.

Conclusion

Patients with severe PACG at presentation were characterised by a younger age at diagnosis, male gender and high presenting IOP. It is likely that these subjects either developed severe disease at an earlier age or underwent rapid disease progression.

The Association between Visual Field Defect and Functional Visual Impairments in Glaucoma Patients

Hsiao Y^{1,2}

¹Taipei City Hospital, Taipei, Taiwan, ²College of Medicine, National Yang Ming Chiao Tung University, Taipei, Taiwan

Introduction

In glaucoma patient, due to inability to detect peripheral obstacles, it has been reported visual field defects can influence patient's quality of life in different aspect. The purpose is to investigate the association between visual field (VF) defect and functional visual impairments and quality of life in glaucoma patients.

Methods

Patients with glaucoma who fulfilled the following criteria were enrolled: (1) intraocular pressure (IOP) controlled below 23 mmHg, and (2) a reliable VF test within 3months of enrollment. (fixation loss \leq 30%; false-positive \leq 15%, and false-negative \leq 15%.) Detailed ocular exams were performed, including visual acuity, IOP, and optic morphology by reliable OCT. A validated Taiwanese version of the 25-item National Eye Institute Visual Function Questionnaire (NEI VFQ-25(T)) was performed in each patient to assess quality of life (pVRQOL).

Results

Total 73 glaucoma patients (M:F =34:39) were enrolled and the mean age was 60.53 \pm 14.41 years old. The average IOP in the right eye were 13.77 \pm 3.89 mmHg. Mean Defect (MD) of VF exam were 8.22 \pm 6.71 dB (range: 0.9-25.3) in the right eye. 49.3% of patients presented with mild VF defect (MD \leq 6dB). Most common complaints of functional impairment encountered including reading difficulties, face recognition, limitations on using electronic device, fear of falling and fear of walking stairs. Our results revealed impaired function in near and distance activities in most patients with superior field defect.

Conclusion

Visual rehabilitation such as reading aid specific for glaucoma patients with superior VF defect will be investigated for special purpose. Ophthalmologists could provide customized assistance and education for patients to adjust their life to functional visual impairments.

References

1. Tham YC, Li X, Wong TY, et al. Global prevalence of glaucoma and projections of glaucoma burden through 2040: a systematic review and meta-analysis. *Ophthalmology*. 2014; 121:2081-2090.
2. Quigley HA, Broman AT Br J Ophthalmol. 2006 Mar; 90(3): 262–267
3. Wang JJ, Mitchell M, Smith W. Vision and low self-rated health: The Blue Mountains Eye Study. *Invest Ophthalmol Vis Sci*. 2000; 41:49–51.
4. Kotecha A O'Leary N Melmoth D Grant S Crabb DP. The functional consequences of glaucoma for eye-hand coordination. *Invest Ophthalmol Vis Sci*. 2009; 50:203–213
5. Haymes SA LeBlanc RP Nicoleta MT Chiasson LA Chauhan BC. Risk of falls and motor vehicle collisions in glaucoma. *Invest Ophthalmol Vis Sci*. 2007; 48:1149–1155
6. Haymes SA LeBlanc RP Nicoleta MT Chiasson LA Chauhan BC. Glaucoma and on-road driving performance. *Invest Ophthalmol Vis Sci*. 2008; 49:3035–3041.
7. Ramulu P. Glaucoma and disability: which tasks are affected, and at what stage of disease? *Curr Opin Ophthalmol*. 2009; 20:92–98.
8. McGwin G Jr Xie A Mays A. Visual field defects and the risk of motor vehicle collisions among patients with glaucoma. *Invest Ophthalmol Vis Sci*. 2005; 46:4437–4441
9. Mangione CM, Lee PP, Gutierrez PR, et al. Development of the 25-item National Eye Institute Visual Function Questionnaire. *Arch Ophthalmol*. 2001; 119:1050-1058.
10. Cheng HC, Guo CY, Chen YJ, Chen MJ, Ko YC, Huang N, Liu CJ. Patient-Reported Vision-Related Quality-of-Life Differences between Primary Angle-

Closure Glaucoma and Primary Open-Angle Glaucoma. PLoS One. 2016 30;11(9): e0163123.

Fig 1: most patients were in the early stage of visual field defect, and the distribution of mean defect was mild: moderate: severe <6dB: 6-12dB: >12dB= 49.3: 30.1: 20.5%.

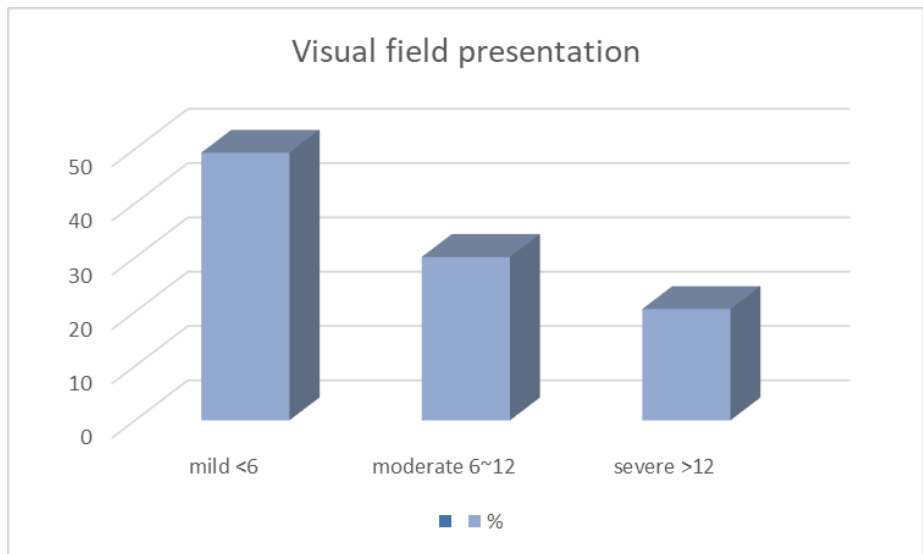


Fig 2: Scores for Each Subscale and the Total Score of NEI VFQ-25.

	Mean +/- SD	Range	n
General health	42.36+/-24.69	0-100	73
General vision	54.11+/-19.55	0-100	73
Near activity	81.34+/-23.27	0-100	73
Distance activity	89.73+/-18.45	0-100	73
Social function	91.95+/-13.24	50-100	73
Role limitations	71.06+/-26.99	0-100	73

Driving	87.5+/-17.06	0-100	30
Color vision	96.23+/-11.54	50-100	73
Peripheral vision	85.27+/-21.18	0-100	73

Patients with retinitis pigmentosa may have an increased risk of developing open angle glaucoma

[Hung M¹](#), [Chen Y²](#)

¹Department of Medical Education, Taichung Veterans General Hospital, Xitun Dist, Taiwan, ² Department of Ophthalmology, Taichung Veterans General Hospital, Xitun Dist, Taiwan

Introduction

Retinitis pigmentosa (RP) is the most common retinal hereditary dystrophy, which can lead to blindness. Similarly, open angle glaucoma (OAG) is a genetic disorder. The similarities in genetic variants and pathophysiology between RP and OAG have been reported. We conducted the study to explore whether patients with RP have a significantly higher risk of OAG development.

Methods

We enrolled patients with RP into the RP group through the Taiwan National Health Insurance Research Database from 2001 to 2013; we included a comparison group of 1:4 age- and gender-matched individuals without RP. We performed a Cox regression analysis to estimate the crude and adjusted hazard ratios (HRs) for OAG. Confounders adjusted in the Cox regression model were age, gender, hypertension, diabetes mellitus, hyperlipidaemia and chronic kidney disease.

Results

We enrolled 6,223 subjects with RP and 24,892 subjects for comparison. The mean age of the cohort was 49.0 ± 18.1 years. The RP group had significantly higher percentages of diabetes mellitus, hypertension and hyperlipidaemia. The cumulative incidence of OAG in patients with RP was 1.57%, which was significantly higher than that in the comparison group (0.58%, $p < 0.0001$). The univariate Cox regression revealed that the hazard of OAG development was significantly greater in the RP group than in the comparison group (unadjusted HR

= 2.86; 95% confidence interval [CI]:2.21–3.70). The increased risk persisted after adjusting for confounders (adjusted HR = 2.86; 95% CI: 2.21–3.70).

Conclusion

This nationwide population-based cohort study showed that people with RP are at a significantly higher risk of developing OAG than individuals without RP.

Table 1. Characteristics of the study subjects

Variable	RP ¹ group n=6223	Non-RP group n=24892	p-value
	n (%)	n (%)	
Age, year, (mean SD²)	49.0 18.1	49.0 18.1	0.97
Age, categorical			1.00
<40	1893(30.4)	7572(30.4)	
40–60	2494(40.1)	9976(40.1)	
60	1836(29.5)	7344(29.5)	
Gender			0.63
Male	3047 (49.0)	12101 (48.6)	
Female	3176 (51.0)	12791 (51.4)	
Diabetes mellitus			<0.0001
Yes	1269 (20.4)	4396 (17.7)	

No	4954 (79.6)	20496 (82.3)	
Hypertension			0.001
Yes	2398 (38.5)	9036 (36.3)	
No	3825 (61.5)	15856 (63.7)	
Hyperlipidaemia			<0.0001
Yes	1781 (28.6)	6404 (25.7)	
No	4442 (71.4)	18488 (74.3)	
Chronic kidney disease			0.26
Yes	323(5.2)	1385(5.6)	
No	5900(94.8)	23507(94.4)	
Outcome= OAG³			
FU⁴ time, year (mean SD)	6.1±3.7	6.4±3.7	<0.0001
OAG during the FU period	98 (1.57)	144 (0.58)	<0.0001

¹ RP, retinitis pigmentosa

² SD, standard deviation

³ OAG, open-angle glaucoma

⁴ FU, follow-up

Table 2. Analyses of risk factors for OAG¹ in patients with and without RP²

Predictive variables	Univariate analysis		Multivariate analysis ³	
	Unadjusted HR ⁴		Adjusted HR	
	(95% CI ⁵)	P value	(95% CI)	P value
RP (Yes vs. No)	2.86 (2.21–3.70)	<0.0001	2.83 (2.19–3.66)	<0.0001
Age				
<40	Reference		Reference	
40-60	1.79 (1.27–2.53)	<0.001	1.74 (1.21–2.49)	<0.01
60	2.56 (1.80–3.64)	<0.0001	2.45 (1.63–3.68)	<0.0001
Gender (Male vs. Female)	1.18 (0.92–1.52)	0.111	1.23 (0.95–1.58)	0.111
Hypertension	1.55 (1.20–1.99)	<0.001	1.02 (0.74–1.40)	0.914
Diabetes	1.48 (1.10–1.97)	<0.01	1.10 (0.79–1.53)	0.586
Hyperlipidemia	1.44 (1.11–1.87)	<0.01	1.11 (0.82–1.51)	0.511
Chronic kidney disease	1.07 (0.62–1.83)	0.808	1.01 (0.66–1.60)	0.904

¹ OAG, open-angle glaucoma² RP, retinitis pigmentosa³ In the multivariable analysis, all the other variables in the Table are included for adjustment.⁴ HR, hazard ratio⁵ CI, confidence interval

Predicting the development and factors affecting traumatic angle recession glaucoma in blunt ocular trauma using Kaplan Meier survival analysis

Hussin I¹, a/P Pulanisamy S², Mat Abu S², Buang N¹, Yaakub A³, Husain N¹, Ahmad Tajudin L³

¹Ophthalmology Clinic, Hospital Raja Perempuan Zainab II, Kota Bharu, Kelantan, Malaysia, Kota Bharu, Malaysia, ²Ophthalmology Clinic, Hospital Sultan Abdul Halim, Sungai Petani, Kedah, Malaysia, Sungai Petani, Malaysia, ³Department of Ophthalmology and Visual Science, School of Medical Sciences, Universiti Sains Malaysia, Health Campus, Kubang Kerian, Kelantan, Malaysia, Kubang Kerian, Malaysia

Introduction

Sequelae of blunt ocular trauma can be devastating and may cause monocular blindness. Traumatic angle recession glaucoma (TARG) is one of the common long-term sequelae, which develop from as early as 1 week to 30 years post-trauma. The main objective of this study is to identify the incidence and determine the 5-years development of TARG among those with blunt ocular trauma.

Methods

A retrospective cohort record review study was conducted among 128 (128 eyes) with history of blunt ocular trauma from three tertiary hospitals in Malaysia. Patients with blunt ocular trauma between 1 January 2010 and 31 December 2020 who completed at least one year follow up between 1 January 2021 and 31 December 2021 were selected. Clinical presentation and mechanism of trauma was documented. Kaplan-Meier survival and Cox proportional hazard regression analyses were performed.

Results

Blunt ocular trauma involved unilateral eye and affected men (117, 91.4%) mostly. Domestic (46.1%), work (23.4%) and sport injuries (16.4%) were the main

mechanism of ocular trauma. Twenty patients (15.6%) developed TARG after mean follow-up of 50.7 (48.5) months. Estimated median time for TARG was 36 (95% CI 18.5, 53.5) months based on Kaplan-Meier analysis. Mean survival time for not developing TARG was 58.6 (95% CI 47.1, 70.2) months. Presence of peripheral anterior synechiae (PAS) has significant longer median time to develop TARG ($p=0.001$).

Conclusion

TARG is seen at least 3 years post blunt ocular trauma. Those without PAS have higher risk to develop TARG. Longer duration follow-up especially those without PAS formation is recommended to detect the sequelae of blunt ocular trauma.

5-year progression of primary angle closure after treatment: The primary angle closure study (PACeS)

Farah Ibrahim¹, Kiew Sieh Yean¹, Monisha E Nongpuir^{1,2}, Tin Aung^{1,2}, [Jayant V Iyer^{1,2}](#)

¹Singapore National Eye Centre, Singapore

²Singapore Eye Research Institute, Singapore

Introduction

There is no recent evidence on progression rates of Primary Angle Closure (PAC) to Primary Angle Closure Glaucoma (PACG). We aimed to study the 5-year progression rates of treated PAC to PACG or acute primary angle closure (APAC).

Methods

A retrospective cohort study of 79 PAC subjects was performed. PAC was defined as iridotrabecular contact of 180 degrees or more, in the presence of raised intraocular pressure or peripheral anterior synechiae, without evidence of glaucomatous optic neuropathy. Data on intraocular pressure (IOP), gonioscopy, treatment instituted and time of progression to PACG or APAC were analyzed. In subjects with bilateral PAC, one eye per subject was randomly chosen.

Results

Of the 79 PAC subjects, 58 (73.4%) subjects were female and all subjects were Chinese. All eyes were treated - 76 underwent laser peripheral iridotomy (LPI) and 3 underwent lens extraction as a primary procedure. During follow-up, 30 were started on IOP-lowering medications, and 21 underwent cataract extraction. 14 of the eyes that underwent cataract extraction required medications. None of the eyes developed APAC. Only 4 eyes progressed to PACG over 5 years of follow-up, 3 of which remained phakic at time of progression.

Conclusion

These results suggest that the risk of progression of treated PAC to PACG is low. Our findings reveal lower rates of 5-year progression compared to previously published data. We found that cataract extraction reduces the likelihood of requiring glaucoma medications at 5 years.

Clinical Outcome of Ahmed Glaucoma Valve at 1 year: A Selayang Hospital Experience

Wardati Jami H^{1,2}, Ivan Lai Y¹, Swee Sew T¹, Shatriah I²

¹Department of Ophthalmology, Hospital Selayang, Batu Caves, Malaysia,

²Department of Ophthalmology and Visual Science, School of Medical Sciences, Universiti Sains Malaysia, Kubang Kerian, Malaysia

Introduction

Glaucoma drainage devices (GDD) are a treatment option for patients with refractory glaucoma. This study was conducted to evaluate the clinical outcome of the Ahmed glaucoma valve (AGV) implant in managing various types of glaucoma in Selayang Hospital.

Methods

Retrospective review of all patients who underwent AGV implant surgery at Selayang Hospital, Malaysia between January 2019 and September 2021. Success was defined as an intraocular pressure (IOP) ≤ 21 mmHg or reduction of 20% from baseline IOP on 2 consecutive visits after 3 months, with or without medications and without additional glaucoma surgery.

Results

A total of 14 eyes from 14 patients were treated with the AGV implant with at least 1 year follow up.

There were 6 Malay, 6 Chinese and 2 Indian patients. The mean age was 54.8 (SD 12.99) years. There were 9 females and 5 males. The commonest diagnosis was secondary glaucoma (57.1%). The mean preoperative IOP was 29.2 (SD 8.48) mmHg. Postoperatively, the mean IOP decreased to 12.4 (4.29) mmHg at 1 week, 13.5 (7.47) mmHg at 6 months and 14.9 (4.00) mmHg at 1 year. The success rate for IOP control was 92.9% at 1 year follow up.

The final best corrected visual acuity (BCVA) improved in 4 (28.6%) eyes, decreased in 2 (11.8%) eyes and 8 patients BCVA remains the same. Post-operative complications occurred in 4 (28.6%) eyes. The commonest complications were transient hypotony which resolved within a week (21.4%). One (7.1%) eye developed hypertony at day 4 post surgery and subsequently developed exogenous endophthalmitis secondary to ruptured bullous keratopathy.

Conclusions

AGV implant is a useful tool in the armamentarium of glaucoma management under various situations, with good safety profile.

References

1. Lai, J.S., Poon, A.S., Chua, J.K., Tham, C.C., Leung, A.T. and Lam, D.S., 2000. Efficacy and safety of the Ahmed glaucoma valve implant in Chinese eyes with complicated glaucoma. *British journal of ophthalmology*, 84(7), pp.718-721.
2. Bikbov, M.M. and Khusnitdinov, I.I., 2015. The results of the use of Ahmed valve in refractory glaucoma surgery. *Journal of Current Glaucoma Practice*, 9(3), p.86.
3. Patel, S. and Pasquale, L.R., 2010, November. Glaucoma drainage devices: a review of the past, present, and future. In *Seminars in ophthalmology* (Vol. 25, No. 5-6, pp. 265-270). Taylor & Francis.

A case report of an air bubble in the anterior chamber in a patient with primary angle-closure suspect.

Jamod H¹, Ahooja H², Yadav S³

¹Glaucoma Consultant, Ahooja Eye and Dental Institute., Gurgaon, India, ²Phaco refractive surgeon, Ahooja Eye and Dental Institute., Gurgaon, India, ³Cornea consultant, Ahooja Eye and Dental Institute, Gurgaon, India

Introduction

Patient complaining of headache and mild eye ache was examined revealing an air bubble in anterior chamber [FIGURE1] with no specific history. Gonioscopy was performed, diagnosed with Primary angle closure suspect and then Neodymium: YAG laser peripheral iridotomy was done in both eyes taking cautious steps. This reports a rarest of rare case and discusses possible reasons for its presence and approach for its management.

Methods

Case report.

Results

Unilateral mydriasis can be due to benign episodic unilateral mydriasis (BEUM)¹, but such case is not recorded yet. In our case no significant cause came out for the presence of air bubble.

Conclusion

Air bubble in the anterior chamber without any ocular procedure is rare. Either it can be an idiopathic condition or due to some non-documented cause. In our case, angle was occludable, time was given to assess the condition as intraocular pressure was not raised or any other complication was not visible. Laser peripheral iridotomy was done to rule out any retinopathy involved.

References

1. Skeik N, Jabr FI. Migraine with benign episodic unilateral mydriasis. Int J Gen Med. 2011;4:501-503. doi:10.2147/IJGM.S18613.

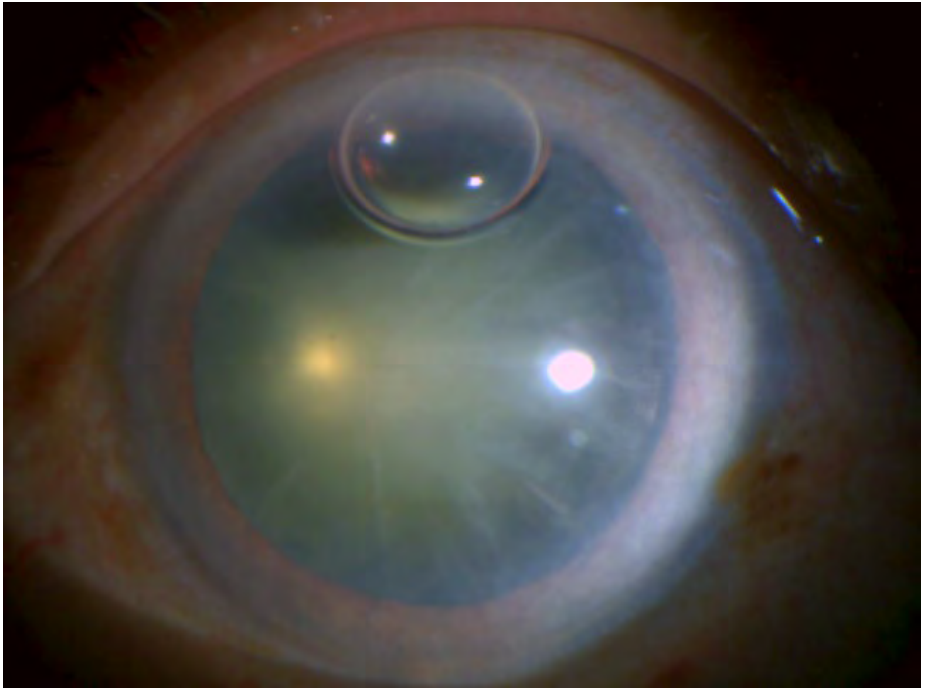


Figure 11: Left eye demonstrates quite conjunctiva with clear cornea. No sign of wound or trauma, fully dilated pupil with air bubble in upper quadrant of the anterior chamber occupying approximately 1/3 of it. No signs of inflammation or any procedure are visible. Lens opacification majorly present at periphery only.

Anterior Chamber Ahmed to Pars Plana Baerveldt Exchange in Eye with NVG with Prior Failed Ahmed

Jang L¹, Kanter J¹, Qiu M¹

¹University Of Chicago, Chicago, United States

Introduction

When additional IOP lowering is needed in eyes with prior failed Ahmed, a tube exchange to a Baerveldt can be considered¹. In NVG, tubes placed in the AC may be associated with corneal and iris complications. We present a NVG patient with a failed Ahmed, elevated IOP, and active NVI and NVA who underwent a same-quadrant exchange of an AC Ahmed to a pars plana Baerveldt with combined PPV and endolaser.

Methods

Case Report

Results

A 51-year-old monocular man (left is better-seeing eye) with PDR and NVG, status post bilateral Ahmed, anti-VEGF injections, and PRP presented to establish care. Visual acuity OS was 20/500, and IOP was 39mmHg on four IOP-lowering medications. Anterior segment exam showed a superotemporal AC Ahmed with no fluid over the plate, active NVI, 360 degrees of synechial closure with NVA, and a sulcus IOL. Fundus exam revealed a pallorous, cupped nerve, no NVD or NVE, and incomplete PRP with room for fill-in.

An AC Ahmed to pars plana Baerveldt exchange was planned, with use of the Ahmed capsule tissue as an autologous patch graft for the Baerveldt, and concurrent vitrectomy and PRP. Intravitreal bevacizumab was administered before the surgery. By postoperative month 4, visual acuity was 20/1000 limited by retinal ischemia, IOP was 10mmHg on no IOP-lowering medications, and the NVI and NVA were fully regressed.

Conclusion

For NVG patients undergoing tube surgery, pre-operative anti-VEGF is critical to regress active neovascularization. A tube exchange instead of an additional second tube should be considered. Concurrent vitrectomy allows for concurrent PRP and tube placement in pars plana, which may be preferable to AC placement.

References

1. Budenz, Donald L et al. "Five-year treatment outcomes in the Ahmed Baerveldt comparison study." *Ophthalmology* 122,2 (2015): 308-16.
doi:10.1016/j.ophttha.2014.08.043

Tables, figures, and illustrations

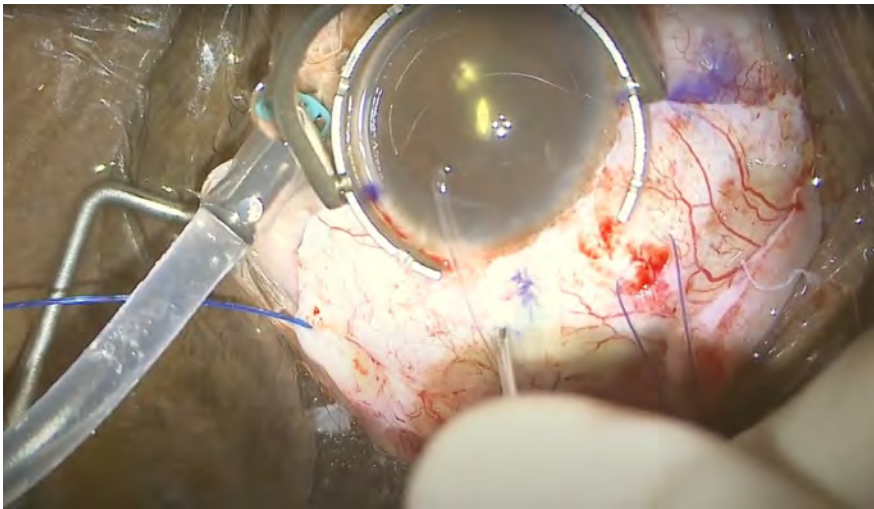


Image 1. Non-tunnelling sclerotomy into the pars plana with 23G needle.

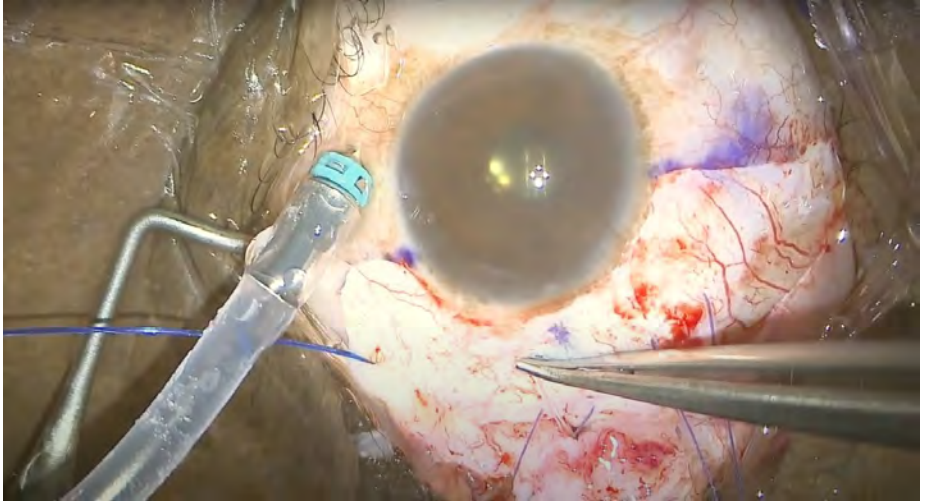


Image 2. Tube inserted into sclerotomy site and advanced into vitreous cavity, with tube tip visible in pupil behind the IOL.

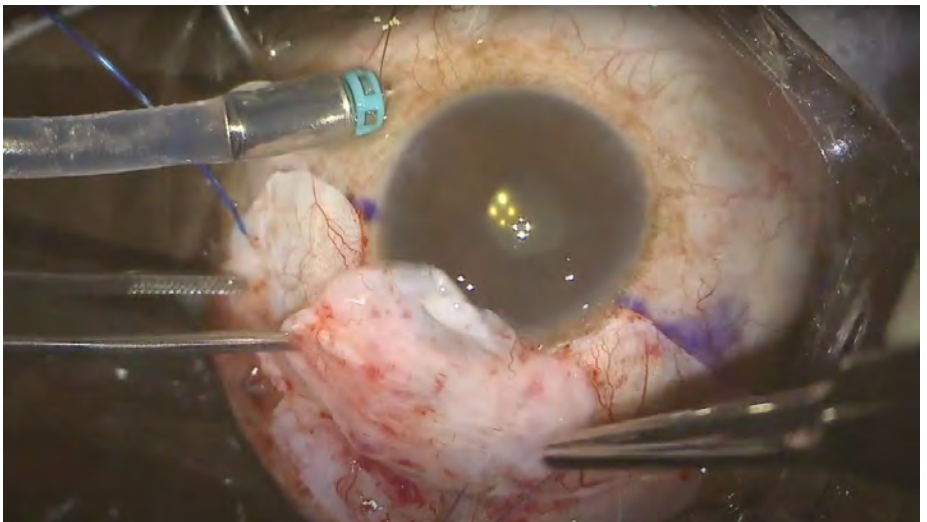


Image 3. Prior Ahmed capsule tissue positioned over new Baerveldt tube as autologous patch graft.

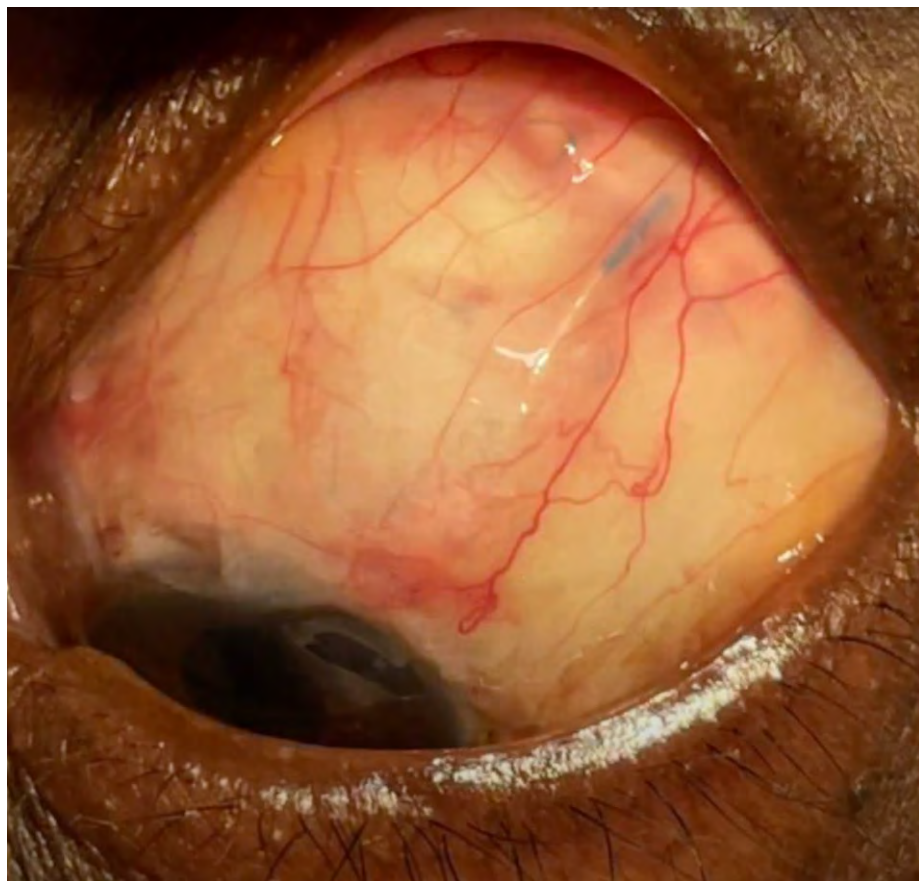


Image 4. Post-operative week 4 image of superotemporal Baerveldt with ripcord in place.

Myopic Open-Angle Glaucoma Prevalence in Northeast Asia: A Systematic Review and Meta-Analysis of Population-Based Studies

Jeong Y¹, Ha A^{2,3,4}, Shim S⁵, Kim Y^{1,2}

¹Seoul National University Hospital, Seoul, South Korea, ²Seoul National University College of Medicine, Seoul, South Korea, ³Jeju National University Hospital, Jeju-si, South Korea, ⁴Jeju National University School of Medicine, Jeju-si, South Korea, ⁵Korea University College of Medicine, Seoul, South Korea

Introduction

Investigation of myopic open-angle glaucoma (OAG) prevalence in Northeast Asia by systematic review and meta-analysis.

Methods

Systematic PubMed, EMBASE and Cochrane database searches for Northeast Asian population-based studies published up to 30 November 2020 and reporting on myopia and OAG diagnosis. By random-effect models, pooled OAG prevalence in a myopic population and pooled myopic OAG prevalence in a general population were generated, with 95% confidence intervals (CIs).

Results

The meta-analysis encompassed 5 population-based studies in 4 countries (12,830 individuals, including 7,723 patients with myopia and 1,112 patients with OAG). In a myopic population, OAG prevalence was 4.10% (95% CI, 3.00–5.70; I² = 93%); in a general population, myopic OAG prevalence was 1.10% (95% CI, 0.60–1.70; I² = 94%). A visual examination of funnel plot symmetry raised a suspicion of publication bias. Notwithstanding, Begg and Mazumbar's adjusted rank correlation test showed no such evidence (P = 0.6242).

Conclusion

Our systematic review and meta-analysis returned an estimate of OAG prevalence in a myopic Northeast Asian population. Our findings will inform future glaucoma studies as well as public health guidelines for Northeast Asian populations.

References

2. Dolgin E. The myopia boom. *Nature*. 2015;519:276–8.
3. Holden BA, Fricke TR, Wilson DA, et al. Global Prevalence of Myopia and High Myopia and Temporal Trends from 2000 through 2050. *Ophthalmology* 2016;123:1036–42.
4. Quigley HA, Broman AT. The number of people with glaucoma worldwide in 2010 and 2020. *The British journal of ophthalmology* 2006;90:262–7.
5. Mastropasqua L, Lobefalo L, Mancini A, et al. Prevalence of myopia in open angle glaucoma. *European journal of ophthalmology* 1992;2:33–5.
6. Boland M v, Quigley HA. Risk factors and open-angle glaucoma: classification and application. *Journal of glaucoma* 2007;16:406–18.
7. Marcus MW, de Vries MM, Junoy Montolio FG, et al. Myopia as a risk factor for open-angle glaucoma: a systematic review and meta-analysis. *Ophthalmology* 2011;118:1989–94.
8. Ha A, Kim CY, Shim SR, et al. Degree of Myopia and Glaucoma Risk: A Dose-Response Meta-Analysis. *Am J Ophthalmol*. 2021;21: Epub ahead of print.
9. Lacroix A. La tension oculaire dans la myopie élevée progressive chez l'adulte. *Annales d'oculistique* 1922;159:700–45.
10. DIAZ-DOMINGUEZ D. On the relations of severe myopia and ocular hypertension. *Annales d'oculistique* 1961;194:597–606.
11. Podos SM, Becker B, Ross Morton W. High Myopia And Primary Open-Angle Glaucoma. *American Journal of Ophthalmology* 1966;62:1039–43.
12. Stroup DF, Berlin JA, Morton SC, et al. Meta-analysis of observational studies in epidemiology: a proposal for reporting. Meta-analysis Of Observational Studies in Epidemiology (MOOSE) group. *JAMA* 2000;283:2008–12.

13. Moher D, Liberati A, Tetzlaff J, et al. Preferred reporting items for systematic reviews and meta-analyses: the PRISMA statement. *PLoS medicine* 2009;6:e1000097.
14. Sullivan GM. *Irb* 101. *Journal of graduate medical education* 2011;3:5–6.
15. Higgins JPT, Thompson SG. Quantifying heterogeneity in a meta-analysis. *Statistics in medicine* 2002;21:1539–58. doi:10.1002/sim.1186
16. Higgins JPT, Thompson SG, Deeks JJ, et al. Measuring inconsistency in meta-analyses. *BMJ (Clinical research ed)* 2003;327:557–60. doi:10.1136/bmj.327.7414.557
17. Egger M, Smith GD, Schneider M, et al. Bias in meta-analysis detected by a simple, graphical test. *BMJ* 1997;315:629–34.
18. Begg CB, Mazumdar M. Operating characteristics of a rank correlation test for publication bias. *Biometrics* 1994;50:1088–101.
19. (2018) RCT. R: A language and environment for statistical computing. R Foundation for Statistical Computing, Vienna, Austria 2018.
20. He J, Zou H, Lee RK, et al. Prevalence and risk factors of primary open-angle glaucoma in a city of Eastern China: a population-based study in Pudong New District, Shanghai. *BMC Ophthalmology* 2015;15:134.
21. Xu L, Wang Y, Wang S, et al. High myopia and glaucoma susceptibility the Beijing Eye Study. *Ophthalmology* 2007;114:216–20.
22. Suzuki Y, Iwase A, Araie M, et al. Risk factors for open-angle glaucoma in a Japanese population: the Tajimi Study. *Ophthalmology* 2006;113:1613–7.
23. Kim KE, Kim MJ, Park KH, et al. Prevalence, Awareness, and Risk Factors of Primary Open-Angle Glaucoma: Korea National Health and Nutrition Examination Survey 2008–2011. *Ophthalmology* 2016;123:532–41.
24. Perera SA, Wong TY, Tay W-T, et al. Refractive error, axial dimensions, and primary open-angle glaucoma: the Singapore Malay Eye Study. *Archives of ophthalmology (Chicago, Ill : 1960)* 2010;128:900–5.
25. Morgan IG, Ohno-Matsui K, Saw S-M. Myopia. *Lancet (London, England)* 2012;379:1739–48.

26. Shimizu N, Nomura H, Ando F, et al. Refractive errors and factors associated with myopia in an adult Japanese population. *Japanese journal of ophthalmology* 2003;47:6–12.
27. Li S-M, Liu L-R, Li S-Y, et al. Design, methodology and baseline data of a school-based cohort study in Central China: the Anyang Childhood Eye Study. *Ophthalmic epidemiology* 2013;20:348–59.
28. Resnikoff S, Pascolini D, Etya'ale D, et al. Global data on visual impairment in the year 2002. *Bulletin of the World Health Organization* 2004;82:844–51.
29. Boland M V, Quigley HA. Risk factors and open-angle glaucoma: classification and application. *Journal of glaucoma* 2007;16:406–18.
30. Marcus MW, de Vries MM, Junoy Montolio FG, et al. Myopia as a risk factor for open-angle glaucoma: a systematic review and meta-analysis. *Ophthalmology* 2011;118:1989–1994.e2.
31. Pan CW, Cheung CY, Aung T, et al. Differential associations of myopia with major age-related eye diseases: the Singapore Indian Eye Study. *Ophthalmology*. 2013;120:284–91.
32. Shen L, Melles RB, Metlapally R, et al. The Association of Refractive Error with Glaucoma in a Multiethnic Population. *Ophthalmology*. 2016;123:92–101
33. Wang YX, Xu L, Yang H, Jonas JB. Prevalence of glaucoma in North China: the Beijing Eye Study. *Am J Ophthalmol* 2010;150:917–24.
34. Iwase A, Suzuki Y, Araie M, et al. The prevalence of primary open-angle glaucoma in Japanese: the Tajimi Study. *Ophthalmology* 2004;111:1641–8.
35. Ramakrishnan R, Nirmalan PK, Krishnadas R, et al. Glaucoma in a rural population of southern India: the Aravind comprehensive eye survey. *Ophthalmology* 2003;110:1484–90.
36. Liang YB, Friedman DS, Zhou Q, et al. Prevalence of primary open angle glaucoma in a rural adult Chinese population: the Handan eye study. *Invest Ophthalmol Vis Sci* 2011;52: 8250–7.
37. Jiang X, Varma R, Wu S, et al. Baseline risk factors that predict the development of open-angle glaucoma in a population: the Los Angeles Latino Eye Study. *Ophthalmology* 2012;119:2245–53.

38. Leske MC, Wu SY, Hennis A, et al. Risk factors for incident open-angle glaucoma: the Barbados Eye Studies. *Ophthalmology* 2008;115:85-93
39. Wong TY, Klein BEK, Klein R, et al. Refractive errors, intraocular pressure, and glaucoma in a white population. *Ophthalmology* 2003;110:211-7.
40. Kuzin AA, Varma R, Reddy HS, et al. Ocular biometry and open-angle glaucoma: The Los Angeles Latino Eye Study. *Ophthalmology* 2010;117:1713-9.
41. Han SB, Jang J, Yang HK, et al. Prevalence and risk factors of myopia in adult Korean population: Korea national health and nutrition examination survey 2013-2014 (KNHANES VI). *PloS one* 2019;14:e0211204-e0211204.
42. Sawada A, Tomidokoro A, Araie M, et al. Refractive errors in an elderly Japanese population: the Tajimi study. *Ophthalmology* 2008;115:363-370.e3.
43. Kempen JH, Mitchell P, Lee KE, et al. The prevalence of refractive errors among adults in the United States, Western Europe, and Australia. *Archives of ophthalmology (Chicago, Ill: 1960)* 2004;122:495-505.
44. Rudnicka AR, Owen CG, Nightingale CM, et al. Ethnic differences in the prevalence of myopia and ocular biometry in 10- and 11-year-old children: the Child Heart and Health Study in England (CHASE). *Invest Ophthalmol Vis Sci* 2010;51:6270-6.
45. Rücker G, Schwarzer G, Carpenter JR, et al. Undue Reliance on I2I2 in Assessing Heterogeneity May Mislead. *BMC Medical Research Methodology* 2008;8:79.
46. Easterbrook PJ, Berlin JA, Gopalan R, et al. Publication bias in clinical research. *Lancet (London, England)* 1991;337:867-72.
47. Loyo-Berríos NI, Blustein JN. Primary-open glaucoma and myopia: a narrative review. *WMJ: official publication of the State Medical Society of Wisconsin* 2007;106:85-89,95.
48. Chang RT, Singh K. Myopia and glaucoma: diagnostic and therapeutic challenges. *Current opinion in ophthalmology* 2013;24:96-101.
49. Jonas JB, Wang YX, Dong L, et al. High Myopia and Glaucoma-Like Optic Neuropathy. *Asia-Pacific journal of ophthalmology (Philadelphia, Pa)* 2020;9:234-8.

Tables, figures, and illustrations

Figure 1. Flow diagram showing study selection process for meta-analysis.

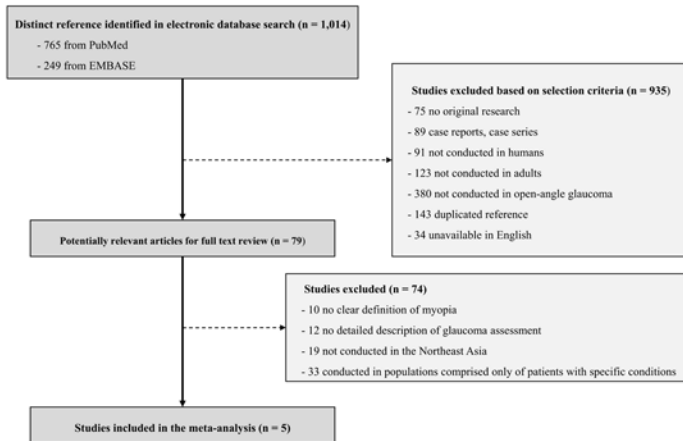


Figure 2. Bar graphs showing prevalences of myopia, OAG, myopic OAG, and OAG among myopic patients.

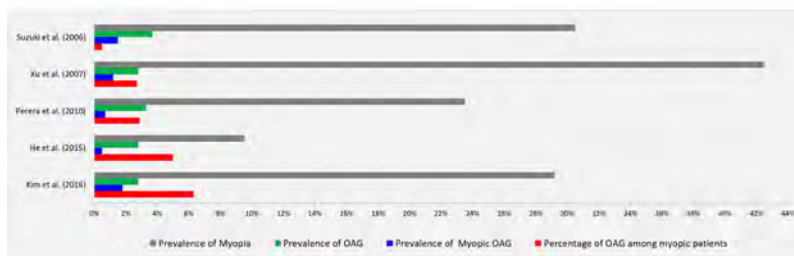


Figure 3A. Forest plot of overall pooled percentage of open angle glaucoma among patients with myopia. (CI = confidence interval)

Figure 3B. Forest plot of overall pooled prevalence of myopic open angle glaucoma. (CI = confidence interval)

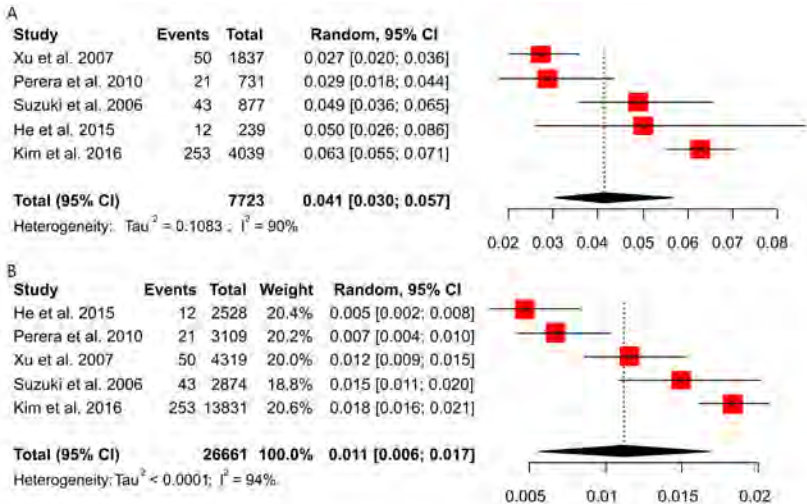
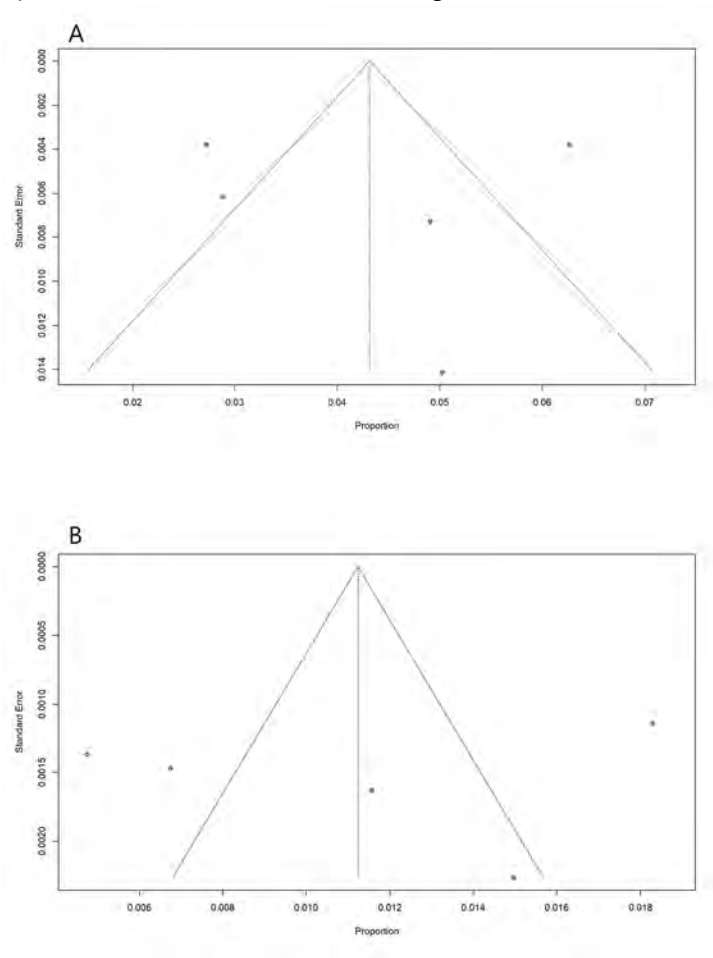


Figure 4A. A funnel plot for meta-analysis of overall pooled percentage of open angle glaucoma among patients with myopia.

Figure 4B. A funnel plot for meta-analysis of overall pooled prevalence of myopic open angle glaucoma.



Angle Closure Glaucoma in a Nanophthalmic Patient with MFRP and BEST1 Mutations

Jacson C¹, Reyes M¹, Fermin M¹, Ibanez M²

¹Far Eastern University - Nicanor Reyes Medical Foundation, Quezon City, Philippines, ²Makati Medical Center, Makati City, Philippines

Introduction

Nanophthalmos is a small-eye disorder with a global prevalence below 1/2,000. Bi-allelic mutations in the *MFRP* gene and homozygous mutations in *BEST1* are both implicated in nanophthalmos. Here we describe a case of nanophthalmos with a homozygous mutation in *MFRP* and a heterozygous mutation in *BEST1*. To our knowledge, this is the first genetically confirmed case of nanophthalmos in the Philippines.

Methods

This is a case report of a nanophthalmic patient, born out of a consanguineous marriage, who presented with acute angle closure glaucoma. The patient underwent ophthalmic assessment and ocular parameters were measured. A microphthalmia/anophthalmia panel consisting of 23 genes was done to confirm the diagnosis.

Results

Ocular examination revealed elevated intraocular pressure (40mmHg) on the left eye. Both eyes were found to have a high hyperopic refractive error (+13.50 D) and short corneal diameters (10.5mm, 9.5mm). Ancillaries showed steep corneal curvatures (50.12 D, 50.22 D) and short axial lengths (21mm, 20.5mm). Fundus of the right eye showed petaloid pattern of abnormal reflex in the central macula. Ocular coherence tomography of the right eye revealed macular edema consistent with the fundus findings. Genetic test results showed a pathogenic homozygous

mutation in *MFRP* c.1150dup (p.His384Profs*8) and a heterozygous variant in *BEST1* c.1054G>A(p.Ala352Thr).

Conclusion

Nanophthalmic eyes pose a great challenge to ophthalmologists, but prognosis may be favorable if correctly identified and promptly treated. This report highlights and hopes to expand the phenotype of a rare case of nanophthalmos presenting with angle closure glaucoma and genetically confirmed to have variants in both *MFRP* and *BEST1*.

References

1. Carricondo P, Andrade T, Prasov L, Ayres B. Nanophthalmos: A Review of the Clinical Spectrum and Genetics. *Journal of Ophthalmology*, 2018; 2018: 2735465. doi.org/10.1155/2018/2735465

Tables, figures, and illustrations

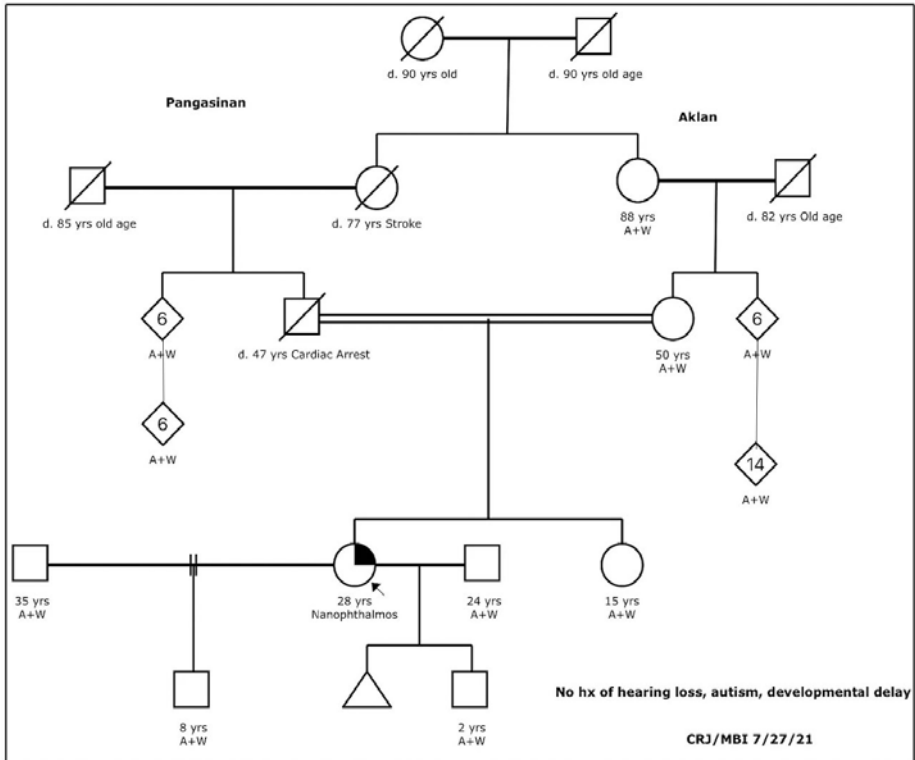


Fig.1 Family pedigree of the index patient depicting that parents of the patient are first-degree cousins

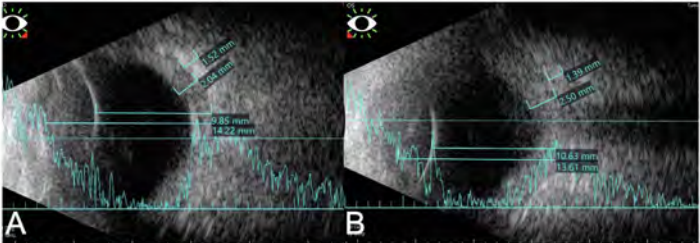


Fig.2 B-scan.
Scleral thickness were 2.04mm on the right (A) and 2.50mm on the left eye (B)

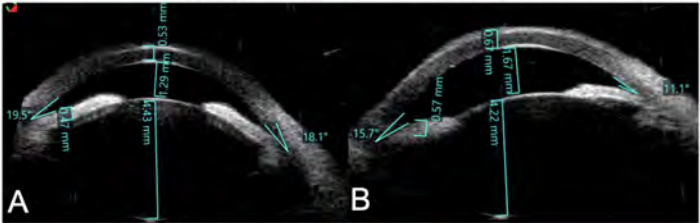


Fig.3 UBM.
Anterior chamber depths were 1.29mm on the right (A) and 1.67 on the left eye (B)

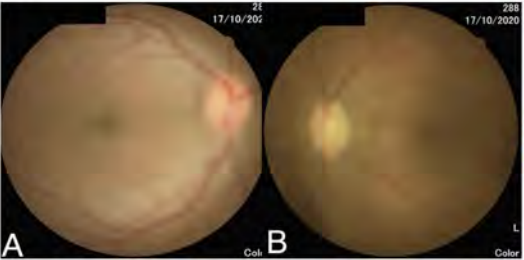

Fig.4 Fundus photographs of the right (A) and left eye (B)

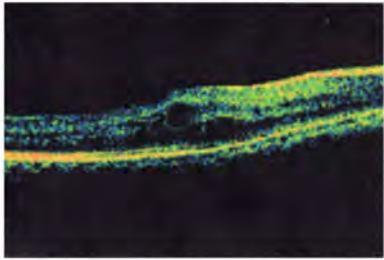


Fig.5 OCT of the macula of the right eye

A multidisciplinary treatment protocol for salvaging the conventional outflow pathway in neovascular glaucoma (SCOPING) – pilot Results

Kanter J¹, Amin P¹, Dao D¹, Shaw L¹, Mackin A¹, Komati R¹, Skondra D¹, Qiu M¹

¹University Of Chicago, Chicago, United States

Introduction

For NVI/NVG eyes with open angles, we propose a protocol to medically salvage the conventional outflow pathway and reduce the need for subsequent IOP-lowering surgeries. We also propose a novel strategy for utilizing GATT to surgically salvage the conventional outflow pathway in NVG eyes.

Methods

Patients with first-time NVI and/or NVA and at least partially open angles were treated with 6 intravitreal bevacizumab (IVB) injections interspersed with PRP at the discretion of the retina service. IVB injections were encouraged to be spaced by 28 days. Elevated IOP was treated at the discretion of the glaucoma service.

Results

Seven eyes from 6 patients were treated with SCOPING. The etiologies of NVG included PDR (5), CRVO (1), and OIS (1). The median presenting VA was 20/40 (range 20/25 to 20/1250). Median presenting IOP was 38 mmHg (range 15 to 47) on 0 meds at baseline. The median duration between IVBs was 35 days (range 23 to 77), and the median total duration from IVB#1 to IVB#6 was 203 days (range 152 to 224). The median number of PRP sessions during the protocol period was 3 (range 1 to 4). At 1 month after IVB #6, the median IOP was 15 mmHg (range 9 to 19) on median 0 meds (range 0 to 2). All 7 eyes had prompt regression of NVI/NVA and no recurrence throughout the protocol period. Five eyes had 100% open angles upon presentation; each maintained adequate IOP control without surgery. The 2 eyes with 50% PAS upon presentation developed progressive synechial closure; 1 patient elected GATT, and 1 elected Baerveldt 350 in the sulcus. After the protocol

was completed, two eyes developed NVA and one eye developed vitreous hemorrhage.

Conclusion

Our protocol demonstrates the value of aggressive anti-neovascular treatment for NVI/NVG with completely or partially open angles.

Table 1

Table 1. Demographic characteristics and clinical features of NVI/NVA eyes presenting with completely or partially open angles undergoing SCOPING Protocol															
	Age	Gender	Race	Etiology	VA at Presentation	RVP at Presentation	Iris / Angle Exam	Duration between 6 RVPs (days)	# RVP	VA 1 month after RVPs	RVP 1 month after RVPs	Recurrent NV during study period?	Recurrent NV after study period?	RPE-leaking surgery at any point	Subsequent anti-neovascular therapy after post-treatment period
Eye #1	61	Female	Black	PDR	20/25	14 on 0 meds	NVI no NVA no PAS	31, 37, 40, 43, 42	3	20/20	9 on 0 meds	No	No	None	None at 363 days
Eye #2	69	Male	Black	PDR	20/50	15 on 0 meds	NVI no NVA no PAS	28, 30, 77, 35, 28	1	20/30	19 on 0 meds	No	No	None	None at 147 days
Eye #3*	60	Male	Hispanic	PDR	20/30	30 on 0 meds	NVI Faint NVA no PAS	28, 69, 42, 42, 28	3	20/25	12 on 2 meds	No	No	None	None at 56 days
Eye #4*	60	Male	Hispanic	PDR	20/40	41 on 0 meds	NVI Faint NVA no PAS	28, 63, 42, 42, 28	3	20/30	10 on 2 meds	No	No	None	None at 49 days
Eye #5	66	Male	Caucasian	OIS	20/50	47 on 0 meds	NVI Faint NVA no PAS	28, 35, 28, 28, 53	4	20/20	19 on 0 meds	No	Yes**	None	Subsequent RVI & PRP
Eye #6	56	Female	Black	PDR	20/40	31 on 0 meds	NVI Faint NVA 50% PAS	34, 25, 40, 72, 35	2	20/30	18 on 0 meds	No	No	IGT between RVI #1 & #2	None at 28 days
Eye #7	57	Female	Black	CRVO	HMA	45 on 0 meds	NVI Faint NVA 50% PAS	35, 61, 51, 35, 44	2	20/200	15 on 2 meds	No	Yes***	GATT between RVI #2 & #5, subsequent CPC & IGA	Subsequent RVI & PRP

SCOPING Protocol: 6 monthly intravitreal bevacizumab with panretinal photocoagulation interspersed.

*Two eyes from same patient; **80 days after NVI #6; ***139 days after NVI #6

NVG: Neovascular Glaucoma, VA: Visual acuity, NV: Neovascularization, PDR: Proliferative diabetic retinopathy, OIS: Ocular ischemic syndrome, IOM: Hard motion, CRVO: central retinal vein occlusion, RVE: Neovascularization of the iris, RVP: Panretinal photocoagulation, CPC: Cyclophotocoagulation, PAS: Peripheral anterior synechiae, IGLESE: IGT between NVI #1 & #2, NV: Intravitreal bevacizumab

The relationship between recurrence frequency and corneal endothelial cells in Posner-Schlossman Syndrome

Ke X¹, Hong Y¹, Zhang C¹

¹Peking University Third Hospital, Beijing, China

Introduction

Posner Schlossman Syndrome (PSS) typically presents with acute, recurrent, unilateral attacks of significantly increased intraocular pressure (IOP) and few round endothelial keratic precipitates.

Recent evidence suggests that affected eyes of PSS patients would have fewer corneal endothelial cells (CEC). In this study, we investigated the risk factors that might relate to the loss of CEC in PSS patients.

Methods

Patients with PSS were enrolled from January, 2014 to March, 2022 in the Department of Ophthalmology, Peking University Third Hospital.

Clinical data including general information, medical history, recurrent attack frequency, duration of disease, maximum IOP and medication were collected. Noncontact-type specular microscopy was used to measure CEC in the central cornea.

All patients were divided into two groups by recurrence attack frequency: group 1 as those equal or less than once per year and group 2 as those more than once per year.

Independent t-test (SPSS software, version 26) was used to analyse the difference of CEC et al between two groups.

Results

Total 56 PSS patients were enrolled. The mean age was 45.0±16.9 years. 30 Patients were male (53.6%). CEC (2188.9±132.0 cells/mm²) in group 1 (N=30) is lower than CEC (2556.6±103.3 cells/mm²) in group 2 (N=26) with statistically

significant. ($p= 0.033$) There is no statistically significant difference in general information and maximum IOP between two groups.

Conclusion

Our results indicated that less CEC may related to annual recurrence frequency. This study might imply that doctor should pay more attention to PSS patients who have recurrence more than once per year.

Safe use of XEN 45 with Mitomycin C in angle recession glaucoma

[Kenworthy M](#)¹, [Mehta R](#)^{1,2}

¹Royal Perth Hospital, Perth, Australia, ²Lions Eye Institute, Perth, Australia

Introduction

XEN 45 insertion has recently become a useful surgical option with a comparable IOP reduction and lower complication rate compared to trabeculectomy/glaucoma drainage devices.^{1,2} Medium term XEN outcomes in angle recession glaucoma are limited to mixed glaucoma heterogeneity studies.³ This study reports safe, effective implantation of XEN 45 to treat angle recession glaucoma.

Methods

Two patients with angle recession glaucoma who underwent ab-interno XEN 45 with subconjunctival Mitomycin C are presented.

Case 1-A 65-year-old-man with angle recession glaucoma on two anti-glaucoma agents OS was referred. Ocular history was cataract surgery and a failed trabeculectomy OS. IOP measured 25 mmHg and gonioscopy demonstrated an area of angle recession from 5-10 o'clock position. XEN 45 was inserted with 6 micrograms of subconjunctival MMC.

Two weeks post XEN insertion, subconjunctival 5-FU was injected without bleb needling for early conjunctival scarring. At six months, IOP measured 14mmHg on zero anti-glaucoma agents.

Case 2-An 83-year-old man on two anti-glaucoma agents and ocular history of a traumatic eye injury (pellet from elastic band 14 years ago) and cataract surgery OS was referred. IOP measured 32 mmHg and angle recession was noted from the 10-2 o'clock position. XEN was insertion with 5 micrograms of MMC. Day one post-

operation, 3+ microhyphema was present. At 6 months, IOP measured 13mmHg on zero anti-glaucoma agents.

Results

Average baseline IOP was 28.5 mmHg on 2 anti-glaucoma agents. Day one follow XEN insertion average IOP was 5mmHg. At six months, average IOP was 13.5mmHg on 0 anti-glaucoma agents. BCVA pre-operatively was maintained post-operatively. No bleb needling was required.

Conclusion

These two cases support the use of XEN 45 in angle recession glaucoma.

References

1. Marcos Parra MT, Salinas López JA, et al. XEN implant device versus trabeculectomy, either alone or in combination with phacoemulsification, in open-angle glaucoma patients. *Graefes Arch Clin Exp Ophthalmol*. 2019; 257:1741-1750.
2. Dhingra D, Bhartiya S. Evaluating glaucoma surgeries in the MIGS context. *Rom J Ophthalmol*. 2020;64:85-95.
3. Karimi, A., Lindfield, D., Turnbull, A. et al. A multi-centre interventional case series of 259 ab-interno Xen gel implants for glaucoma, with and without combined cataract surgery. *Eye* 2019;33:469–477.

Table

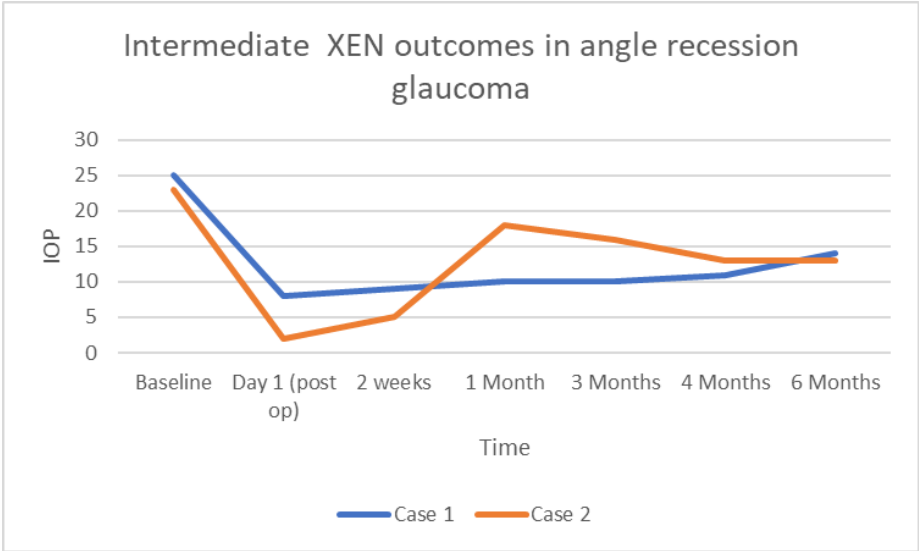


Table 1: XEN with MMC outcomes.

iTrack Global Data Registry to Support the Role of Canaloplasty for Treatment of Glaucoma

[Kerr N](#)¹, Lubeck D², Ahmed I³

¹Centre for Eye Research Australia, East Melbourne, Australia, ²Arbor Centres for Eye Care, , USA, ³University of Toronto, Canada

Introduction

The iTrack™ Global Data Registry (iTGDR) is a prospective, multicenter, real-world study of patients with primary and secondary open angle glaucoma undergoing canaloplasty using the iTrack™ or iTrack™ Advance devices (Nova Eye Inc., Fremont, USA). Canaloplasty lowers intraocular pressure by targeting the three main sites of outflow resistance: the trabecular meshwork, Schlemm's canal and the distal collector channels. During the surgical procedure, a flexible microcatheter is advanced 360-degrees around Schlemm's canal. As the microcatheter is withdrawn, viscoelastic fluid is injected to dilate Schlemm's canal, collector channel ostia and the distal outflow system.

Methods

The iTGDR is a surgeon-led initiative conducted in collaboration with the International Glaucoma Surgery Registry (IGSR). The IGSR is an independent cloud-based platform that collates high quality longitudinal data on the outcomes of glaucoma surgery and has been recognised by the European Glaucoma Society and the Australian New Zealand Glaucoma Society.

Results

The iTGDR commenced in January 2022 and will collate efficacy, safety and canaloplasty specific treatment parameters. Canaloplasty outcomes will be followed for a minimum of 12-months and up to 24 to 60 months. A minimum of 300 patients will be enrolled. The iTGDR commenced with approximately 20 sites in the USA, Canada, Europe, Asia and Australia. It will generate analytics and reports of outcomes for each participating site as well as the entire iTGDR.

Conclusion

The iTGDR will make a major contribution to understanding the clinical effectiveness of canaloplasty to guide evidence-based decision making for surgeons to achieve improved outcomes in the treatment of their glaucoma patients.

Heart rate variability as an indicator of autonomic dysfunction in normal-tension glaucoma

Khoo C^{1,2}, Choo M¹, Ramli N¹

¹UM Eye Research Centre, University of Malaya, Department of Ophthalmology, Kuala Lumpur, Malaysia, ²Hospital Sultanah Bahiyah, Alor Setar, Malaysia

Introduction

This study aims to investigate the utility of measuring short-term heart-rate variability (HRV) as a marker of autonomic dysfunction in patients with normal-tension glaucoma (NTG).

Methods

HRV measurements were conducted in NTG patients and controls during a cold provocation test. Recording was done over three phases (resting phase, cold provocation phase (CPT) and recovery phase), each lasting five minutes. All subjects were placed in supine position. In the (CPT) phase, the subjects immersed their hand into a container of cold water. In recovery phase, the hand was withdrawn from the cold water. The data collected from the subjects were transferred for data-processing. Time-domain and frequency-domain indices of HRV parameters were generated and analyzed.

Results

A total of 71 NTG patients and 56 healthy controls were recruited. At rest, there were no differences in HRV values between NTG and control group. With cold provocation, the NTG group showed an initial decline in root mean square of successive RR interval differences (RMSSD) (from 18.60 ± 20.30 to 16.80 ± 23.80 ms), followed by a significant rise beyond its initial values in the recovery phase (21.50 ± 21.00 ms, $p=0.001$ and $p=0.015$). There was also a significant rise in low-frequency-band (LF) power, which persisted beyond the CPT phase into the recovery phase (from 135.20 ± 339.20 ms² to 143.10 ± 257.20 ms², and $183.80 \pm$

265.80ms², p=0.002 and p=0.028). These dynamic changes in HRV were not seen in the control group.

Conclusion

NTG patients demonstrate abnormalities in short-term HRV parameters during cold provocation which implies impaired vagally-mediated functions and sympathetic overactivity. The findings support presence of autonomic dysfunction in these patients.

References

1. Electrophysiology. Task Force of the European Society of Cardiology and the North American Society of Pacing and Electrophysiology. Heart rate variability: standards of measurement, physiological interpretation, and clinical use. *Circulation*. 1996;93(5):1043-1065.

2. Na K-S, Lee NY, Park S-H, Park CK. Autonomic dysfunction in normal tension glaucoma: the short-term heart rate variability analysis. *Journal of glaucoma*. 2010;19(6):377-381. Kurysheva NI, Ryabova TY, Shlapak VN. Heart rate variability: the comparison between high tension and normal tension glaucoma. *EPMA Journal*. 2018;9(1):35-45.

Table 1. Within-group comparison of HRV parameters for each phase for NTG and non-NTG subjects

	NTG				Non-NTG Controls			
	Resting	CPT	Recovery	p-value [§]	Resting	CPT	Recovery	p-value [§]
	Median (IQR)	Median (IQR)	Median (IQR)		Median (IQR)	Median (IQR)	Median (IQR)	
SDNN	30.40	31.80	31.90	0.22	28.90	35.45	31.30	0.06

(ms)	(27.80)	(22.60)	(21.60)	9	(24.70)	(24.10)	(20.70)	6
RMSSD (ms)	18.60 (20.30)	16.80 (23.80)	21.50 (21.00)	0.001 [#] 1.000 ^a 0.001 ^b 0.015 ^c	15.35 (23.10)	16.35 (25.50)	17.25 (20.20)	0.121
TP (ms ²)	886.30 (1029.70)	815.90 (1354.20)	772.80 (1680.80)	0.053	649.60 (1039.30)	792.85 (1209.20)	834.20 (1100.10)	0.054
VLF (ms ²)	427.30 (646.30)	381.20 (543.90)	398.60 (737.60)	0.448	324.65 (437.90)	413.80 (540.80)	400.05 (525.20)	0.051
LF (ms ²)	135.30 (339.20)	143.10 (257.50)	183.80 (265.80)	0.002 [#] 1.000 ^a 0.002 ^b 0.028 ^c	149.85 (189.70)	143.75 (165.10)	176.15 (304.40)	0.460
HF (ms ²)	82.40 (194.30)	64.40 (201.40)	97.50 (208.90)	0.047 1.000 ^a 0.087 ^b 0.108 ^c	55.10 (240.90)	56.90 (283.00)	63.10 (244.10)	0.104

LF/HF	1.938 (2.124)	1.837 (2.11)	1.886 (2.00)	0.76 5	1.879 (1.82)	2.115 (2.19)	1.974 (2.57)	0.68 7
-------	------------------	-----------------	-----------------	-----------	-----------------	-----------------	-----------------	-----------

Notes

[§] analysis conducted using Friedman test. The p-values expressed represent that of the median.

[#] means p-value < 0.05.

^a indicates transition of phases from Resting to CPT.

^b indicates transition of phases from CPT to Recovery.

^c indicates transition of phases from Resting to Recovery.

p-value < 0.05 is considered significant.

One-Year Comparative Evaluation of Standalone iStent Implantation and Combined iStent Implantation with Phacoemulsification in a Single Center

Khoo P¹, Cheng T¹, Md Din N¹

¹Universiti Kebangsaan Malaysia, Kuala Lumpur, Malaysia

Introduction

This study assessed a 12-month effectiveness and safety of iStent trabecular micro-bypass implants in open-angle glaucoma (OAG) patients.

Methods

This is a real-world, retrospective longitudinal, comparative study in OAG patients who underwent iStent implantation as standalone procedure or as a combined procedure with phacoemulsification. Surgical success (qualified/complete) was calculated by Kaplan-Meier analysis based on guideline on reported surgical outcome as recommended by the World Glaucoma Association (WGA). Complete success was defined as intraocular pressure (IOP) reduction $\geq 20\%$ without medications and qualified success was the same percentage of reduction with medications.

Results

We included 53 eyes from 40 OAG patients: primary OAG (n= 44 eyes) and secondary OAG (n= 9 eyes). 24 eyes underwent standalone iStent implantation while 29 eyes underwent combined iStent implantation with phacoemulsification. Thirteen eyes were implanted with the iStent (G1) device and 40 eyes received the iStent inject (G2, G2-W) device. The majority of eyes (37.7%) had moderate glaucoma, based on mean deviation on Humphrey visual field analyser. Kaplan-Meier analysis revealed surgical success in 44.4% eyes after 1 year. Qualified success was higher in the combined group (58.8%) when compared to the standalone group (26.3%). Average medication usage was reduced from 3.54 ± 0.66 to 2 ± 1.41 ($p < 0.001$) in the standalone group and from 2.74 ± 0.75 to 1.3 ± 0.65 ($p < 0.001$) in the combined group. Stent occlusion occurred in 2 eyes, while steroid-

induced IOP elevation were noted in 4 eyes at one month postoperatively. 3 eyes required trabeculectomy during follow-up.

Conclusion

Significant and safe IOP and medication reductions were observed through 12 months after iStent implantation with or without concomitant cataract surgery. Greater success was observed in the combined group.

Refractory Steroid-Induced Glaucoma in Vogt-Koyanagi-Harada (VKH) Treated with Combined iStent Trabecular Micro-bypass Stent and Endoscopic Cyclophotocoagulation (ECP)

Khoo P¹, Cheng T¹, Md din N¹, Che-Hamzah J¹

¹Universiti Kebangsaan Malaysia, Kuala Lumpur, Malaysia

Introduction

Management of refractory steroid-induced glaucoma (SIG) can be extremely complicated, especially in cases of recurrent inflammatory diseases such as Vogt-Koyanagi-Harada (VKH) disease. We aim to report a case of advanced SIG and VKH with multiple failed glaucoma surgeries, treated with a combined iStent implantation and endoscopic cyclophotocoagulation (ECP) procedure.

Methods

Case report.

Results

A 34-year-old gentleman with VKH disease and bilateral advanced SIG presented with uncontrolled intraocular pressure (IOP) of both eyes. He had previously undergone multiple glaucoma surgeries which later failed to maintain the optimal IOP. Visual acuity was counting fingers (CF) OU. Examination revealed IOP of 26mmHg OD and 20mmHg OS with maximal topical anti-glaucoma, oral acetazolamide, and syrup glycerol. Gonioscopy revealed open-angle OD and closed-angle OS. Cup-to-disc ratio (CDR) was 0.95 OU. Humphrey visual field (HVF) test showed severe tunnel vision OU. He underwent combined iStent implantation and ECP on his right eye. Post-operatively, oral IOP-lowering agents were tapered off and IOP remained stable within the low-teens OD in the following 2 months.

Conclusion

Combined iStent and ECP procedure is a viable option in cases of refractory secondary glaucoma where conventional glaucoma surgeries fail to control the IOP.

References

1. Ngai P, Kim G, Chak G, Lin K, Maeda M, Mosaed S. Outcome of primary trabeculotomy ab interno (Trabectome) surgery in patients with steroid-induced glaucoma. *Medicine (Baltimore)*. 2016 Dec;95(50):e5383.
2. Rezkallah A, Mathis T, Denis P, Kodjikian L. XEN Gel Stent to Treat Intraocular Hypertension After Dexamethasone-Implant Intravitreal Injections: 5 Cases. *J Glaucoma*. 2019 Jan;28(1):e5–9.
3. Pantaloni AD, Barata ADDO, Georgopoulos M, Ratnarajan G. Outcomes of phacoemulsification combined with two iStent inject trabecular microbypass stents with or without endocyclophotocoagulation. *Br J Ophthalmol*. 2020 Oct;104(10):1378–83.

Figure



Figure 1: Two iStent injects (G2) implanted at the pigmented trabecular meshwork, via a clear corneal incision and ab interno approach under gonioscopy.

Managing recurrent tube exposure of glaucoma drainage device: a Malaysian tertiary eye centre experience

Koay J^{1,2}, Jeffrey S¹, Ja'afar F¹, Che Hamzah J²

¹Hospital Sultanah Bahiyah, Alor Setar, Malaysia, ²Universiti Kebangsaan Malaysia, Cheras, Malaysia

Introduction

Glaucoma drainage device (GDD) implantation is an effective tool in the management of glaucoma but can cause serious complications such as tube exposure and endophthalmitis. This study illustrates the management of recurrent tube exposure.

Methods

Observational case series of three eyes.

Results

In primary surgery, all GDD tubes were covered with a donor scleral or pericardial flap. Duration between primary surgery and tube exposure ranged from 6 weeks to 15 years. All cases manifested with a non-leaking conjunctival dehiscence. One eye developed recurrent exogenous endophthalmitis which resolved with antibiotic treatment. Another was initially repaired with a conjunctival patch, then a corneal graft with a tube extender in which both methods failed, ultimately requiring a scleral patch similar as other cases. A donor scleral patch was used to cover the exposed tube, further enclosed by a complex of bilayer amniotic membrane (AM) and host conjunctiva sandwiched in between using inlay and overlay grafting method. Postoperatively, autologous serum eye drops (ASEDs) were instilled to promote conjunctival epithelialization. Two eyes epithelialized successfully to cover the scleral patch over 4 to 6 months. One scleral graft dislodged after 4 months despite initial epithelialization and underwent another scleral patch surgery using the same method.

Conclusion

Complications of GDD tube exteriorization are potentially blinding if not treated promptly. A scleral patch graft with a double-layer amniotic membrane transplant is a promising method in managing tube exposure.

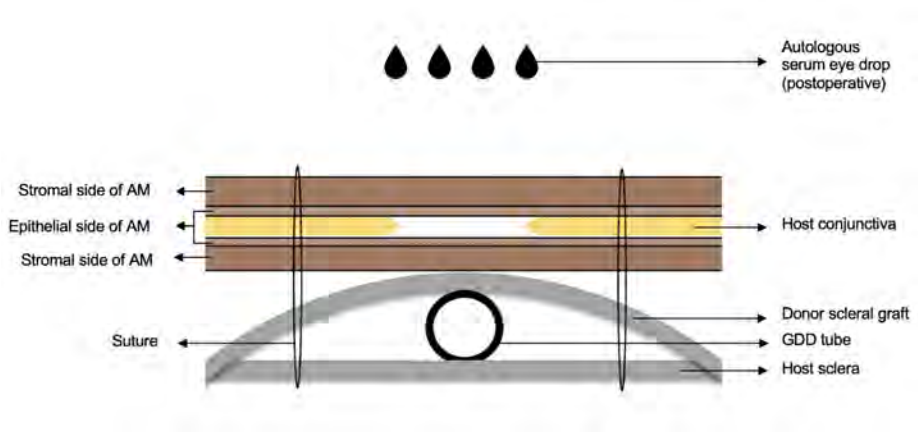


Figure 1. Schematic diagram of scleral patch and amniotic membrane transplantation.

Estimating theoretical pressure differential across tube shunt device containing monofilament intraluminal stent using Plane Poiseuille flow equation

Kong G^{1,2,3}

¹Royal Victorian Eye and Ear Hospital, Melbourne, Australia, ²Centre for Eye Research of Australia, Melbourne, Australia, ³The University of Melbourne, Parkville, Australia

Introduction

Intraluminal stent is sometimes used within tube shunt devices in an attempt to produce early flow restriction. Little is published on the theoretical pressure differential effect of intraluminal stent. Plane Poiseuille flow equation could be used to estimate the pressure differential due to laminar flow in the annular cross-section formed between the inner tube lumen and intraluminal stent.

Methods

Plane Poiseuille flow equation ($Q = \Delta p \cdot h^3 / (12m)$) (Ref 1) applies where flow is between two parallel plates, where Q is volumetric flow rate per unit width, Δp is pressure differential, h is gap between plates and m is dynamic viscosity. The annular cross-section can be assumed to be parallel plates with the width being the circumference of annulus. For our calculations, 12mm length tube is assumed and aqueous dynamic viscosity is assumed to be same as that of water at 37°C.

Results

For Baerveldt tube (284 micrometre), calculated pressure differential by 3-0, 4-0, 5-0 sutures are 0.56mmHg, 0.15mmHg and 0.07 mmHg respectively. For Molteno tube (313 micrometre), pressure differential produced by 2-0, 3-0, 4-0, 5-0 sutures are 119mmHg, 0.22mmHg, 0.08 mmHg and 0.04mmHg respectively. Therefore 2-0 suture is essentially occlusive and smaller sutures essentially provide negligible flow restriction. For PAUL implant (127 micrometre), the pressure differential

produced by 5-0, 6-0, 7-0, 8-0 sutures are 36mmHg, 4.38mmHg, 1.98mmHg and 1.45mmHg respectively.

Conclusion

Plane Poiseuille flow equation could be used to understand flow within tube shunt device with intraluminal stent. A 6-0 intraluminal suture within PAUL implant is expected to produce pressure differential within physiological level suitable to prevent early hypotony.

References

1. Fitzpatrick R, Fluid Mechanics, The University of Texas at Austin 2016.

Demographic Characteristics Of Glaucoma Patients That Underwent Surgery in Dr. Kariadi Hospital During The COVID-19 Pandemic

Krisantono Y¹, Maharani², Puspasari D², Rahmi F²

¹Ophthalmology Resident, Diponegoro University, Dr. Kariadi Hospital, Semarang, Indonesia, ²Ophthalmology Department Dr. Kariadi Hospital, Diponegoro University, Semarang, Indonesia

Introduction

The emergence of the coronavirus disease (COVID-19) at the end of 2019 caused strict social distancing protocols that have limited the number of patients in clinics. Lockdown and travel restrictions prevented patients in need of glaucoma care from leaving their local districts and using public transport services.

Methods

This descriptive observational study was using medical records of glaucoma patients that underwent glaucoma surgery in Dr. Kariadi Hospital during March 2020 – September 2021. The study aimed to describe the demographic profiles of the patients.

Results

There were 381 patients that underwent glaucoma surgery, 52.5% came from a shorter distance within 50 km radius of the hospital, while 47.5% came from over 50 km distance from the hospital. Primary Angle Closure Glaucoma is the most common diagnosis in both groups (46.5% and 53%) respectively. In the shorter distance group, Trabeculectomy (36%) was the most common procedure, while Phaco-Trab (44.2%) was the most common procedure in longer distance patients.

Conclusion

The study showed that even though there were lockdown and travel restrictions because of covid, almost half of the patients that come to our tertiary care hospital were coming from over 50 km distance. Patients with glaucoma urgency seek care despite travelling from long distances and risk of covid contraction.

References

1. World Health Organization. WHO Coronavirus Disease (COVID-19) Dashboard; 2021. Available from: <https://covid19.who.int/>. Accessed on February 8, 2022.
2. Ohannessian R, Duong TA, Odone A. Global Telemedicine Implementation and Integration Within Health Systems to Fight the COVID-19 Pandemic: A Call to Action. *JMIR Public Health Surveill* 2020;6(2):e18810

Visual field performance after implantation of multifocal intraocular lenses in glaucoma patients

Kuo C¹, Chang Y^{1,2}, Liu C^{1,2}

¹Department of Ophthalmology, Taipei Veterans General Hospital, Taipei City, Taiwan, ²School of Medicine, National Yang Ming Chiao Tung University, Taipei City, Taiwan

Introduction

To assess changes in visual performance and visual field outcome in glaucoma patients undergoing cataract surgery with multifocal intraocular lens (MFIOL) implantation.

Methods

We reviewed the charts of glaucoma patients undergoing cataract surgery with MFIOL implantation and having reliable visual field tests within 6 months preoperatively, at 6 months (PO6M) and 1 year postoperatively (PO1Y). We compared changes in uncorrected visual acuity (UCVA), intraocular pressure (IOP), number of glaucoma medications, visual field mean deviation (MD), pattern standard deviation (PSD), and visual field index (VFI).

Results

A total of 34 eyes (25 patients with mean age of 67.65 years at surgery) were enrolled, including 18 primary open-angle glaucoma (POAG), 14 primary angle-closure glaucoma (PACG) and 2 secondary glaucoma. Subgroup analysis revealed no difference between POAG and PACG group. The average preoperative UCVA, UCVA at PO6M and PO1Y were 0.43 ± 0.13 , 0.02 ± 0.04 and 0.01 ± 0.03 logMAR, respectively ($P < 0.001$). There was no significant change in IOP at PO6M and PO1Y. The number of glaucoma medications decreased from 1.79 preoperatively to 1.41 at PO6M ($P = 0.002$), but remained similar at PO1Y. The average MD at PO6M was comparable with that measured preoperatively (-9.76 ± 8.13 dB versus -10.7 ± 7.96 dB, $P = 0.075$), but improved at PO1Y (-8.8 ± 7.54 dB, $P = 0.004$). No significant differences

were observed in PSD or VFI at PO6M and PO1Y as compared to the preoperative measures.

Conclusion

There is no evidence suggesting all glaucoma patients should be excluded from the option of MFIOL, as this study revealed UCVA can improve greatly, while visual field performance may not be affected after MFIOL implantation.

References

1. Aychoua N, Junoy Montolio FGw, Jansonius NM. Influence of multifocal intraocular lenses on standard automated perimetry test results. JAMA Ophthalmol. 2013;131(4):481-485.

Surgery results for silicone oil-induced glaucoma: a 4-year retrospective study

[Yulinda Arty Laksmi](#)¹, [Virna Dwi Oktariana](#)¹, [Widya Artini](#)¹

¹Department of Ophthalmology, Faculty of Medicine Universitas Indonesia - Cipto Mangunkusumo Hospital, Indonesia

Introduction

The use of silicone oil in vitreoretinal surgery is inevitable due to its superiority as retinal tamponade. However, complications often arise, including secondary glaucoma. Definitive management regarding silicone oil-induced glaucoma hasn't been established. This study aims to evaluate the surgical outcomes, thus helping clinicians to decide the best surgical management in treating silicone oil-induced glaucoma.

Methods

Subject with silicone oil-induced glaucoma that had undergone glaucoma surgery and followed up for 3 months was included. Analyzed variables include clinical characteristics, retinal surgery properties, type of glaucoma surgical procedures, pre and post-operative IOP, and complications.

Results

Mean pre-operative IOP from 33 eyes included was 48.9 ± 9.8 mmHg. With or without scleral buckles, there's no significant difference in mean pre-operative IOP ($p=0.549$). Valved-GDD implantation showed a greater IOP reduction and better success rate (88.9%) than trabeculectomy (33.3%). It also showed good results, even as a second procedure when previous trabeculectomy has failed. Overall success rate of all surgeries was 63.6%. Complication rate was 12%, including exposed implant tube, bleb encapsulated, and bleb leakage.

Conclusion

In managing silicone oil-induced glaucoma, GDD implantation may be preferred as first-line surgery, with a success rate above eighty percent. It is also an option in refractory cases with a low complication rate.

References

1. Kanner EM. Glaucoma associated with disorders of the retina, vitreous, and choroid. In: Albert DM, editor. *Albert & Jakobiec's Principles & Practice of Ophthalmology* 3rd ed. Elsevier; 2008. p.2743-2762.
2. Nariani A, et al. Incidence of ocular hypertension following silicone oil use after vitrectomy surgery. *Int J Ophthalmol Clin Res* 2015;2:1-3.

Tables, figures, and illustrations

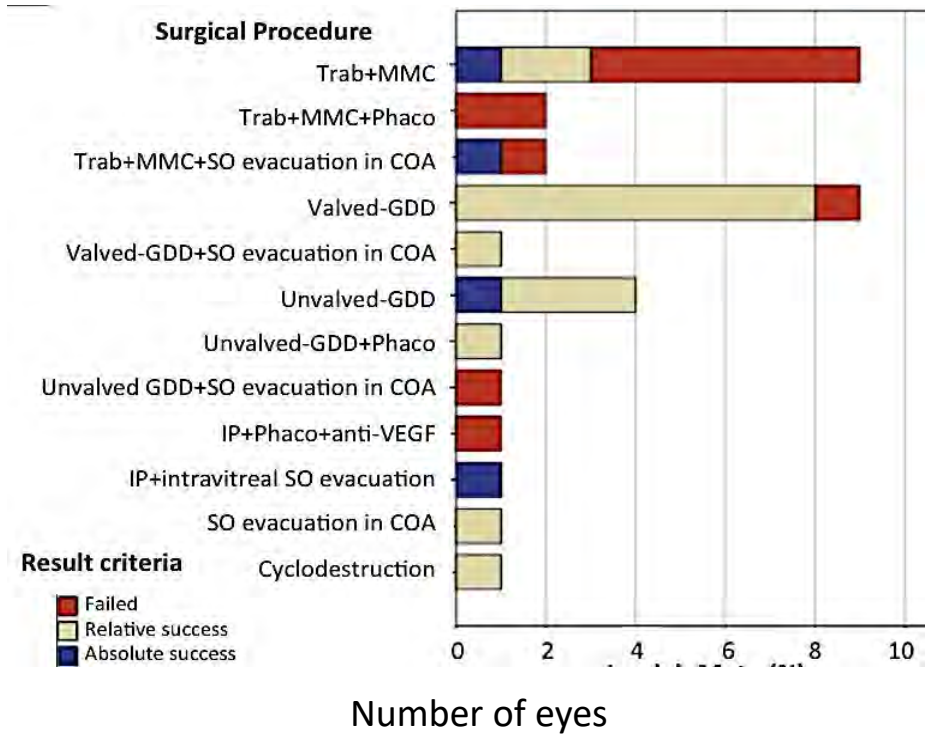


Fig 1. Outcomes of each procedure (N=33 eyes)

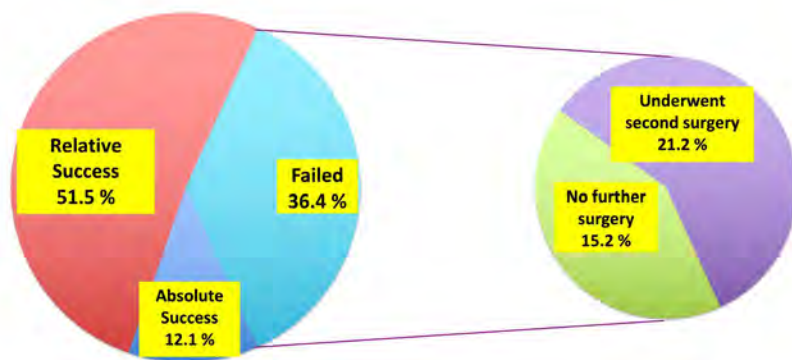


Fig 2. Overall success rate (N=33 eyes)

Ocular necrotizing granulomatous inflammation resulting in enucleation

Law N¹, Wong S¹, Lam C^{1,2}

¹Hospital SibU, SibU, Malaysia, ²Faculty of Medicine, SEGI University SibU Clinical Campus, SibU, Malaysia

Introduction

This is a case report reporting a case of ocular necrotizing granulomatous inflammation resulting in urgent enucleation

Methods

Case report

Results

A 17-year-old young gentleman, presented to us with acute onset of left eye loss of vision, pain, redness, and swelling for 3 days. Visual acuity of left eye was only perception of light with positive relative afferent pupillary pathway defect (RAPD). On examination, left eye was proptosed, with scleral bulging. Cornea was hazy with mutton-fat keratic precipitate. There was no fundal view, however, B-scan showed flat retina with no obvious mass posteriorly. Computed tomography (CT) orbit showed thickening of scleral and uvea anteriorly with displacement of lens anteriorly and superiorly. Mantoux test was 21mm, Sputum examination showed scanty acid-fast bacilli. Chest X-ray was normal. Left eye enucleation was performed due to impending perforation with aggressive presentation and possible malignancy. Histopathological examination (HPE) showed necrotizing granulomatous inflammation. Patient was subsequently treated as ocular tuberculosis with antituberculosis. The fellow eye was not affected with visual acuity 6/6 over a follow-up till date.

Conclusions

Ocular tuberculosis(TB) with aggressive presentation is rare. It is diagnostically challenging which mimic many ocular diseases. Prompt diagnosis and initiation of antituberculosis may prevent vision loss.

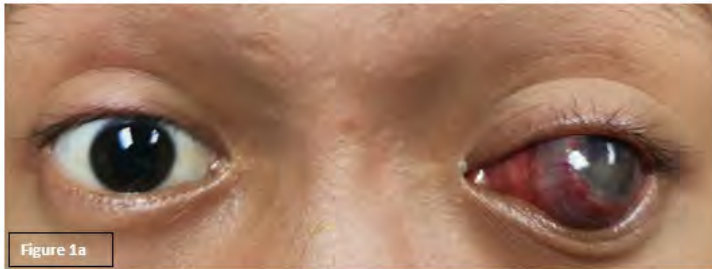

Figure 1a

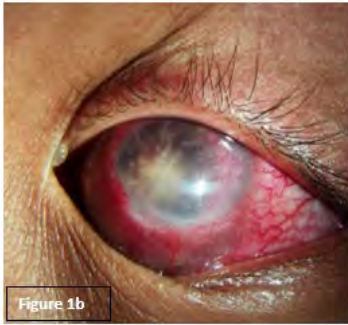

Figure 1b

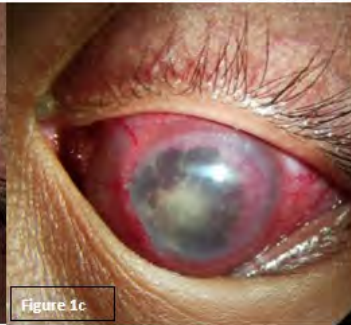

Figure 1c

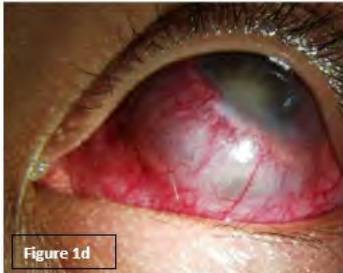

Figure 1d

Figure 1a-d: Left eye proptosis, with scleral bulging and thinning at the peri-limbal region from 5 to 11 o'clock. The overlying conjunctiva was injected with large, engorged vessels. The cornea was hazy with mutton-fat keratic precipitate. Anterior chamber was shallow with 1+ of cells. Pupil was displaced inferotemporally with 360° of posterior synechia. There were white masses noted over the peripheral iris from 10 to 5 o'clock with neovascularization.

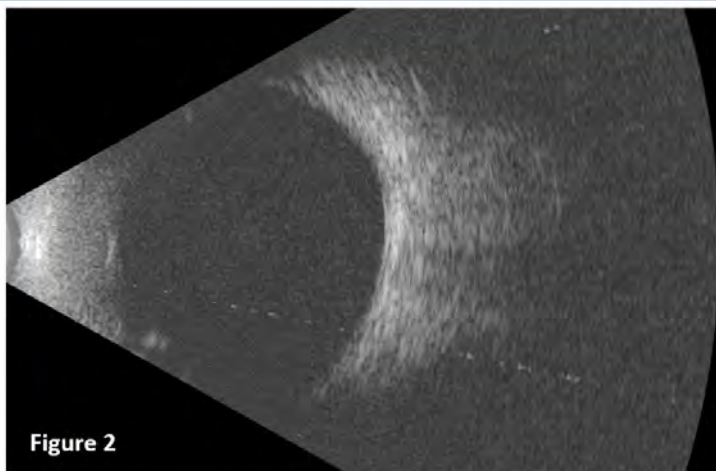


Figure 2: B-scan showed flat retina with no obvious mass posteriorly

One-year observation on the impact of phacomorphic glaucoma – A case series

Lee H¹, Subrayan V²

¹Hospital Pakar Sultanah Fatimah, Muar, Malaysia, ²University Malaya Medical Center, Kuala Lumpur, Malaysia

Introduction

Attack of phacomorphic glaucoma is often common in older patients with senile cataract. Symptoms of acute raised in intraocular pressure (IOP) and the long-term sequelae of the attack varies. The raised IOP and the inflammation incited can damage the cornea endothelial, trabecular meshwork, lens, retinal nerve fiber layers and retina. These often exert an impact on a person's vision, IOP, and optic disc changes.

Objective

To observe the impact of phacomorphic glaucoma on the visual acuity, IOP and optic disc changes

Methods

A one-year follow up of all phacomorphic glaucoma cases which were admitted to University Malaya Medical Center from January 2018 to December 2018. All cases have undergone cataract extraction surgery.

Results

Three patients were admitted due to phacomorphic glaucoma. They were aged 64 to 70. IOP was above 50mmHg on presentation. Two had vision of perception to light, and one was 6/36. Cataract extraction was done in a week for two patients, whereas another was delayed due to blepharitis. One patient developed expulsive hemorrhage intra-operatively and no fundus view permitted on subsequent follow-ups. The vision remained no perception to light and soft. In the other two

patients, fundus was examined as soon as view was permitted after the surgery. The cup-disc ratio was noted. In a one-year follow up, their vision is 6/7.5 - 6/6, IOP 10-13mmHg, and no progression of optic disc changes. None of the patients required antiglaucoma eyedrops.

Conclusions

Cataract extraction remains the main therapeutic approach to phacomorphic glaucoma. Outcomes appeared to be favorable. Complications of surgery, especially in an inflamed eye with high IOP, can be devastating.

Effect of intraoperative mitomycin C on the surgical outcomes of Ahmed glaucoma valve implantation with ciliary sulcus tube placement

Kim C¹, Lee J¹, Bae H¹, Park S¹, Lee S¹, Choi W¹

¹Severance Hospital, Seoul, Korea, Democratic Republic of

Introduction

To evaluate the effect of intraoperative mitomycin-C (MMC) on the surgical outcomes of ciliary sulcus (CS) Ahmed glaucoma valve (AGV) tube placement.

Methods

A retrospective review of medical records of 54 consecutive patients who underwent AGV implantation with tube placed in CS was performed. Consecutive cases operated without the use of intraoperative MMC from 2017 to 2019 were compared with consecutive cases operated with MMC from 2019 to 2021. Surgical failure was defined as IOP exceeding 21mmHg in 2 consecutive visits after postoperative 3 months or $\geq 30\%$ IOP reduction, IOP ≥ 5 mmHg in 2 consecutive visits, or loss of light perception. Kaplan-Meier survival analysis and log rank test were performed to compare the surgical failure rates.

Results

Patients were followed for 1.4 ± 0.8 years. The MMC group showed significantly lower IOP during the first postoperative month (20.5 ± 8.6 vs. 15.8 ± 6.4 mmHg; $P=0.027$), but the difference did not persist 1 year after the surgery ($P=0.523$). The mean number of postoperative antiglaucoma medications was significantly lower in the MMC group in the first postoperative month ($P=0.047$) but no difference was found at 1 year. No statistical difference was noted in the rates of postoperative complications. Kaplan-Meier survival analysis showed comparable probabilities of success of 96.9% and 85.9% for the MMC group and no MMC groups, respectively ($P=0.209$).

Conclusion

The intraoperative use of MMC significantly lowered IOP in the first postoperative month but did not increase 1 year success rates in patients receiving AGV tube placement in CS.

Intraocular pressure fluctuations in visual field progression of advanced open-angle glaucoma at low intraocular pressures

Lee J¹, Park S¹, Kim C¹, Lee S¹, Choi W¹, Bae H¹

¹Severance Hospital, Seoul, Korea, Democratic Republic of

Introduction

To identify risk factors associated with progression of visual field defect in patients with advanced primary open-angle glaucoma (POAG).

Methods

A retrospective review of 122 eyes of 122 patients, who met Hodapp-Parrish-Anderson criteria for advanced POAG was conducted. Intraocular pressure (IOP) measurement, standard automated perimetry (SAP), cirrus optical coherence tomography (OCT) and fundus photography were performed at 6-month intervals. Visual field progression was defined as deterioration of a minimum of 3 visual field locations more than baseline at 5% levels in 4 consecutive visual fields with 24-2 SITA testing.

Results

Thirty-six eyes of 122 eyes (29.5%, 51.9±13.9 years old) showed visual field progression during 100.7±44.2 months of follow-up. The progression group showed greater long-term IOP fluctuations (2.6±1.4 mmHg) than the no progression group (53.5±13.5 years; 2.0±1.0 mmHg, P=0.008). Disc hemorrhage was detected more frequently in the progression group (40.5% vs. 17.4%, P=0.005). Multivariate Cox regression analysis revealed long-term IOP fluctuations (HR 2.567 95% CI 1.327-5.370, P=0.012) and disc hemorrhage (HR 2.351 95% CI 1.120-4.931, P=0.024) to be independent risk factors of visual field progression. Patients who showed both disc hemorrhage and long-term IOP fluctuations were at greater risks of progression (HR 2.675 95% CI 1.072-6.457, P=0.035).

Conclusion

Long-term IOP fluctuations and disc hemorrhage are independent and additive risk factors of visual field progression in advanced glaucoma even at low intraocular pressures. Patients in whom these risk factors are identified require close monitoring and vigorous treatment.

Changes in corneal endothelial cell density after trabeculectomy

Lee N¹, Ong R², Ong K³

¹University Of New South Wales, Sydney, Australia, ²Sydney and Sydney Eye Hospital, Sydney, Australia, ³Royal North Shore Hospital, Sydney, Australia

Introduction

Glaucoma is a leading cause of blindness worldwide for which trabeculectomy is the most effective surgical intervention for advanced disease. However, trabeculectomy has been associated with a decrease in corneal endothelial cell density (CECD). The purpose of this study was to investigate changes in CECD after trabeculectomy and the factors affecting cell loss.

Methods

This retrospective study included 62 eyes of 53 patients who underwent trabeculectomy from 2018-2021. Corneal specular microscopy was performed pre-operatively and at 6 months post-operatively. CECD was evaluated and compared between groups to quantify changes to corneal endothelium and identify factors affecting CECD loss.

Results

Mean CECD was 2284.66 ± 375.59 pre-operatively and 2129.52 ± 401.96 after 6 months ($p < 0.001$). A greater decrease in CECD ($p = 0.005$) was observed in phakic eyes (235.45 ± 118.32) compared to pseudophakic eyes (137.82 ± 107.30). The amount of cell loss was negatively correlated with pre-operative central corneal thickness ($p = 0.009$) and anterior chamber depth ($p = 0.033$). There were no significant correlations between CECD loss and age, gender, number of glaucoma medications and number of post-operative antifibrotic agents.

Conclusion

Significant decreases in CECD occurred after trabeculectomy. Less CECD loss occurred in pseudophakic eyes. Hence, if patients need trabeculectomy and

cataract surgery, it may be better to perform cataract surgery first. Longer term studies should derive more information.

References

1. Higashide T, Nishino T, Sakaguchi K, Yamada Y, Sugiyama K. Determinants of Corneal Endothelial Cell Loss After Trabeculectomy With Mitomycin C. *Journal of Glaucoma* 2019; 28: 61-7.
2. Hirooka K, Nitta E, Ukegawa K, Sato S, Kiuchi Y. Effect of trabeculectomy on corneal endothelial cell loss. *British Journal of Ophthalmology* 2020; 104: 376.

Dysphotopsia after superior versus temporal laser peripheral iridotomy for narrow angle glaucoma

Lee N¹, Xuan R², Ong K³

¹University Of New South Wales, Sydney, Australia, ²Sydney and Sydney Eye Hospital, Sydney, Australia, ³Royal North Shore Hospital, Sydney, Australia

Introduction

Laser peripheral iridotomy (LPI) is commonly performed in patients with narrow angle glaucoma. While complications are rare, visual disturbances have been reported in up to 4% of patients after LPI. These dysphotopsia symptoms may be associated with LPI location and resultant eyelid coverage, however current evidence is inconclusive. The objective of this study was to investigate the incidence of dysphotopsia after LPI and evaluate for differences between eyes receiving superior or temporal LPI placement.

Methods

This retrospective study included 71 eyes of 38 patients who underwent LPI from July to December 2021 by the same ophthalmic surgeon. In patients who had bilateral iridotomies, one eye received temporal and one eye received superior LPI placement. The presence of dysphotopsia was assessed 1 month after the procedure. Differences in dysphotopsia between eyes receiving temporal versus superior iridotomies were evaluated.

Results

Of the 71 eyes included in this study, 38 eyes received superior and 33 eyes received temporal LPI placement. The incidence of dysphotopsia symptoms was 5.3% in the superior LPI cohort and 3.0% in the temporal LPI cohort. We identified no significant associations between the location of LPI and the development of dysphotopsia symptoms ($p=0.38$).

Conclusion

Visual disturbances can occur after LPI. There were no significant associations between the development of dysphotopsia symptoms and whether the LPI was superior or temporal in location.

References

1. Vera V, Naqi A, Belovay GW, Varma DK, Ahmed IIK. Dysphotopsia after Temporal versus Superior Laser Peripheral Iridotomy: A Prospective Randomized Paired Eye Trial. American Journal of Ophthalmology 2014; 157: 929-35.e2.

An Audit of the Quality of Glaucoma Referral Letters to a Tertiary Referral Center: A New Checklist to Improve Efficiency of Glaucoma Referrals in Malaysia

Lee W¹, Mt Saad A², Mohd Ramli N³

¹Hospital Pulau Pinang, Gelugor, Malaysia, ²Hospital Sultanah Bahiyah, Alor Setar, Malaysia, ³University of Malaya, Kuala Lumpur, Malaysia

Introduction

To create a standardised checklist for all glaucoma referrals by doing a survey with glaucoma specialists and to assess the quality of referral letters received by a tertiary glaucoma unit before and after the implementation of the quality improvement intervention.

Methods

A survey on five glaucoma specialists on the information they deemed important to be included in the referral letter was done via e-mail correspondence. A retrospective review of all new glaucoma referral letters sent to the glaucoma clinic was done. Universal sampling method was used. Then, a prospective study was done for re-audit purpose after quality improvement plan.

Results

The survey revealed that the top-10 most desired information including patient's name, identification-card number, date and reason(s) of referral, baseline intraocular pressure (IOP), trend of IOP on treatment, visual fields, current glaucoma therapy, any other ocular pathology, previous ocular surgery or laser treatment. During audit period, 32.7% of letters achieved the yardstick of at least 8 out of 10 criteria. Only one referral letter included all desired information. Medical officers were generally better than ophthalmologists in providing the crucial information. During re-audit period, similar results (32.7%) achieved the yardstick and 3 glaucoma referral letters had fulfilled all desired information. Overall, while

the intervention did not achieve desired target of 100%, there was an increase in the numbers of the desired criteria included in each referral letter.

Conclusion

Our audit highlights the need for improvement in glaucoma referral letters in view of most referral letters reviewed were of poor quality. A change of practice should be encouraged using glaucoma referral letter checklist, with emphasis on that important information which should not be missed when writing a comprehensive referral letter.

Effect of Transscleral Diode Laser Cyclophotocoagulation (TSCPC) in Neovascular Glaucoma and Its Long-Term Outcome

Lim K¹, Woon T¹

¹Hospital Pakar Sultanah Fatimah, Muar, Malaysia

Introduction

To study the effect of transscleral diode laser cyclophotocoagulation (TSCPC) in patients with neovascular glaucoma and its long-term outcome in visual acuity improvement, intraocular pressure (IOP) reduction and antiglaucoma eye drop requirement.

Methods

Retrospective observational case series of 14 patients who received TSCPC in Hospital Pakar Sultanah Fatimah, Muar, Johor, Malaysia from September 2019 to December 2021. Patients were followed up during first week, first month, second month, fourth month, sixth month, ninth month, one year post treatment.

Results

Total 14 eyes which had underwent TSCPC were followed up. Three patients had visual improvement, two patients had worsening vision and nine patients vision remain the same. Results showed 25.2% and 36.0% IOP reduction in the first week and after one year of treatment respectively. The mean IOP reduced from $45.5 \pm 9.00\text{mmHg}$ pre-treatment to $34.0 \pm 9.81\text{mmHg}$. Subsequently, mean IOP at first month, second month, fourth month, sixth month, ninth month, one year were $31.3 \pm 14.8\text{mmHg}$, $27.2 \pm 7.69\text{mmHg}$, $22.3 \pm 11.0\text{mmHg}$, $28.7 \pm 17.8\text{mmHg}$, $32.2 \pm 14.0\text{mmHg}$, $29.1 \pm 10.2\text{mmHg}$ respectively. Two patients managed to taper off topical antiglaucoma eye drops while the rest did not require additional eye drops.

Conclusion

TSCPC is a relatively safe procedure, able to achieve IOP lowering effect and visual acuity improvement in patients with advanced glaucoma. This procedure is

repeatable, less side effect and is suitable in patients who are contraindicated for surgical intervention.

References

1. Grueb M, Rohrbach JM, et al. Transscleral diode laser cyclophotocoagulation as primary and secondary surgical treatment in primary open-angle and pseudoexfoliative glaucoma. Graefe's Archive for Clinical and Experimental Ophthalmology 2006; 244(10): 1293-9

Timing in Intervening Acute Glaucoma and Its Long-term Outcome

[Lim K¹](#), Lee H¹

¹Hospital Pakar Sultanah Fatimah, Muar, Malaysia

Introduction

To study the timing in terminating acute glaucoma and the long-term outcomes in visual acuity, intraocular pressure (IOP) control and peripheral anterior synechiae (PAS) formation.

Methods

Retrospective observational case series. The data were collected in Hospital Pakar Sultanah Fatimah, Muar from January 2021 to January 2022. All patients presented with impaired vision and elevated IOP. Intervention was carried out medically or/and surgically. The timing of intervention, visual acuity, IOP and anterior chamber(AC) angle were analysed at immediate, one week, two weeks, one month and four months post treatment.

Results

Seven patients had acute angle closure attack on presentation. Two patients with pre-existing angle closure, five patients with lens related. Visual acuity on presentation were worse than 6/60. IOP ranged from 43 - 64mmHg (mean 54.42 ± 7.69 mmHg). Laser peripheral iridotomy (PI) was done in two patients with acute angle closure. Early cataract surgery within two weeks were performed on four patients with lens related acute glaucoma. One patient with subluxated lens underwent laser PI at one month followed by cataract surgery at three months of presentation. The visual acuity of those who were intervened within two weeks were 6/9 or better. The later one was 6/24. The mean IOP at first week, two weeks, one month, and four months were 13.71mmHg, 14.0mmHg, 15.4mmHg and 14.6mmHg respectively. All patients showed open angle up to the fourth month of observation. Four patients (two angle closure and two lens related) required two anti-glaucoma.

Conclusion

Early intervention of acute angle closure showed good outcome in visual acuity, IOP control, AC angle structure, and anti-glaucoma requirement. Delayed intervention showed a more challenging IOP control with moderately impaired visual acuity.

Clinical Outcomes after Second-Generation Trabecular Microbypass Stents (iStent inject) with Phacoemulsification in Korean Patients

LIM S¹

¹Daegu Veterans Health Service Medical Center, Dalseo-gu, South Korea

Introduction

To evaluate the intraocular pressure (IOP)-lowering effect of second-generation trabecular microbypass stents (iStent inject) with cataract extraction (combination group) and compare refractive changes in the combination group and the control (phacoemulsification only) group.

Methods

This retrospective case-control study included 36 eyes with cataract and medically controlled open-angle glaucoma with IOP < 21 mmHg and 100 nonglaucomatous eyes with cataract. Data were collected preoperatively and for 6 months postoperatively. Data included IOP, number of glaucoma medications, corrected distance visual acuity, and mean absolute error (MAE) from target refraction, and astigmatic vector analysis. Surgical success for the combination group was defined according to three criteria: (A) IOP <15 mmHg without medication, (B) IOP < 18 mmHg without medication, and (C) IOP < 18 mmHg with or without medication.

Results

In the combination group, mean IOP was reduced from 15.1 ± 2.9 mmHg to 12.5 ± 2.0 mmHg, and the mean number of medications decreased from 1.9 ± 1.0 to 0.4 ± 0.8 at postoperative 6 months (both $P < 0.001$). Surgical success rates were 77.8%, 83.3%, and 97.2% at 6 months by criteria A, B, and C, respectively. Mean IOP was reduced from 14.3 ± 2.7 mmHg to 13.1 ± 2.1 mmHg at 1 month in the control group ($P < 0.001$). The

MAE was 0.33 ± 0.26 D, and 83.3% of eyes had spherical equivalent difference within 0.50 D in the combination group (0.38 ± 0.33 D and 76.0% in the control group; $P = 0.309$ and $P = 0.363$, respectively). Preoperative and postoperative

centroid values were 0.51 D @ 1 and 0.66 D @ 178, respectively (0.23 D @ 176 and 0.66 D @ 1 in the control group). There were no statistical differences between the two groups with respect to preoperative and postoperative mean absolute values ($P = 0.154$ and $P = 0.322$, respectively).

Conclusion

On the basis of our results using Korean real-world interim experience, iStent inject with cataract extraction has favorable IOP-lowering effects and minimally impacts refractive outcomes.

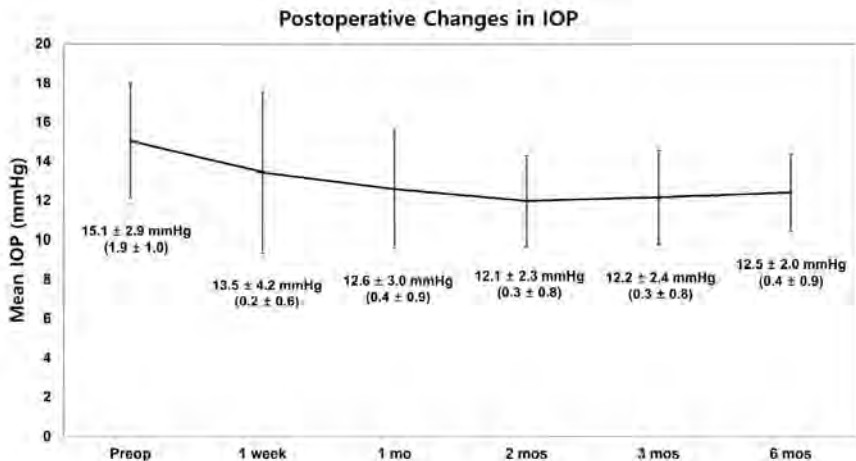


Figure 1. Postoperative changes in intraocular pressure in the combination group. Following the combination procedure, trabecular microbypass stents (iStent_inject) with phacoemulsification, mean intraocular pressure (IOP), and number of medications decreased significantly and were maintained during the study period. Participant IOP decreased from 15.1 ± 2.9 mmHg on 1.9 ± 1.0 medications to 12.4 ± 2.0 mmHg on 0.4 ± 0.8 medications at postoperative 6 months ($P < 0.001$, $P < 0.001$, respectively).

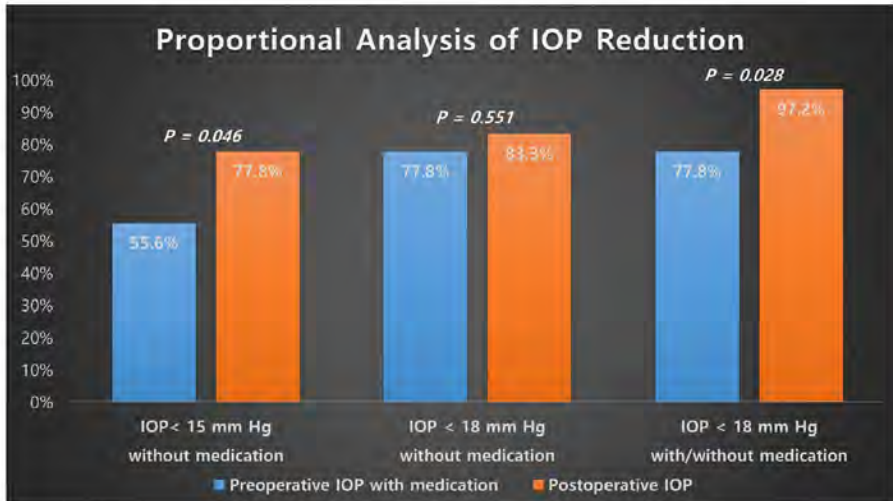


Fig. 2 Proportional analysis of IOP reduction in the combination group. Figure shows the percentage of eyes with IOP < 15 mmHg without medication, IOP < 18 mmHg without medication, and IOP < 18 mmHg with or without medication compared to the percentage of eyes with baseline preoperative IOP with medication < 15 mmHg or < 18 mmHg ($P = 0.046$, $P = 0.551$, $P = 0.028$, respectively; Fisher's exact test and chi-square test)

Retinal vasculitis and cystoid macular oedema in Chikungunya - a case report

[Liow Y¹](#), Chan H¹, Kamalden T²

¹Hospital Pulau Pinang, Georgetown, Malaysia, ²University of Malaya, Kuala Lumpur, Malaysia

Introduction

Chikungunya, a mosquito-borne disease is caused by Chikungunya virus, an arbovirus. It is characterized by abrupt onset of fever and debilitating arthralgia. We report a rare case of retinal vasculitis and cystoid macular oedema (CMO) after a quiescent interval following systemic infection.

Methods / Case

Case Report

A 61-year-old Malay lady with no known medical illness other than an admission for Chikungunya 6 weeks ago presented with bilateral painless blurring of vision. Anterior segment examination was unremarkable. Posterior segment examination revealed perivascular sheathing, intraretinal haemorrhages and macula oedema in both eyes confirmed by SD-OCT findings. Fundus fluorescein angiography (FFA) showed focal vascular leakage in the macula. Trial of topical NSAIDS for macula oedema was initiated.

Results / Discussion

Ocular manifestations of Chikungunya can be concurrent with systemic symptoms or can appear after a quiescent interval. The delayed onset of symptoms can be due to antigenic mimicry, delayed hypersensitivity reaction, or stimulation of a pathogenic lymphocyte reaction. Retinal vasculitis with CMO is a rare ocular manifestation of Chikungunya, but significantly affects vision resulting in morbidity.

Conclusion

Ocular manifestations of Chikungunya are vast, most common being anterior uveitis. As of date, there are no randomized controlled trials for treatment of ocular inflammatory diseases associated with Chikungunya.

References

1. Mahendradas, P., Avadhani, K. & Shetty, R. Chikungunya and the eye: a review. *J Ophthal Inflamm Infect* 3, 35 (2013). <https://doi.org/10.1186/1869-5760-3-35>:
2. D. F. Martínez-Pulgarín et al., Ophthalmologic aspects of chikungunya infection. *Travel Med Infect Dis* 14, 451-457 (2016).
3. H. Merle et al., Ocular manifestations of emerging arboviruses: Dengue fever, Chikungunya, Zika virus, West Nile virus, and yellow fever. *J Fr Ophtalmol* 41, e235-e243 (2018).

The effect of delayed laser peripheral iridotomy in acute angle closure glaucoma

Low A¹, Gan A¹, Zhen W¹, Foo S¹, Khaliddin N²

¹Penang General Hospital, Butterworth, Malaysia, ²University Malaya Medical Center, KUALA LUMPUR, Malaysia

Introduction

This study aims to evaluate the effects of delayed laser peripheral iridotomy due to late presentation of acute angle-closure on the intraocular pressure (IOP) control and the number of anti-glaucoma medications.

Methods

A 3-year retrospective study on patients presenting with acute angle-closure between 2019 and 2021 in Penang General Hospital. Patient demography, the interval between onset of symptoms and patent LPI, IOP, and the number of glaucoma medications needed after three months were assessed.

Results

Thirty-one patients were included in the study (mean age 62.1 years old (SD: 12.1), 67.7% Chinese, 51.6% males). The mean interval between onset of symptoms and patent LPI was nine days (SD: 5.8). The mean IOP was 49.2mmHg (SD: 10.4) at presentation and 13.1mmHg (SD: 2.5) three months after PI. Hence, there was a significant decrease in IOP after LPI ($p<0.001$). The mean number of anti-glaucoma medications needed was reduced from 4 to 2.3. The patients were then divided into two groups, depending on whether they had a patent LPI within nine days or more days than that. A comparison between the two groups found no significant difference in the IOP outcome ($p=0.778$) or the number of anti-glaucoma medications needed to control the IOP at three months ($p=0.737$).

Conclusion

The delayed presentation did not affect the IOP outcome or the number of medications needed to control IOP three months after a patent LPI.

Characteristic of Juvenile Open Angle Glaucoma in Kariadi Hospital during the COVID-19 Pandemic

[Maharani T¹](#)

¹Resident of Ophthalmology Department of Diponegoro University, Kariadi Hospital, Semarang, Indonesia

Introduction

Juvenile open-angle glaucoma (JOAG) is an uncommon form of primary open-angle glaucoma, with earlier onset (3 to 40 years of age), higher IOP, and severe visual field loss. The purpose of the study was to demonstrate the clinical characteristics of patients with JOAG at Kariadi General Hospital.

Methods

This was a descriptive study conducted at Kariadi Hospital, from January 2021 – March 2022. All participants were interviewed for their medical history and underwent full ocular examination

Results

Forty eight patients were recruited in this study. Patients with JOAG showed a female preponderance (32,5%). Most of the cases were affected in both eyes (81,25%). The mean age of the patients was $19,62 \pm 7,71$ years. The most frequent of onset symptoms were poor vision (37,3%), eye pain (20,5%), and seeing halos (12,0%). Myopia was present in 13 patients (27,0%). Total 35 patients (72,91%) had no visual impairment (VI), mild VI (10,41%), moderate VI (14,58%), and severe VI (2,08%). The mean of IOP was $25,51 \pm 14,71$ mmHg and CDR was $0,73 \pm 0,20$. All of the participants had OCT examination, the mean of RNFL thickness was $82,76 \pm 21,64$ μm .

Conclusion

The patients with JOAG presented late with poor vision. Periodic eye examinations are needed and could be of great benefit in creating awareness, demand early detection and prompt treatment

References

1. Allingham RR, editor. Childhood glaucomas; clinical presentation. In: Shields text book of glaucoma. 6th ed. India;2017.
2. Kwun Y, et al. Clinical Characteristics of Juvenile-onset Open Angle Glaucoma. Korean J Ophthalmol. 2016.

Effect of N-METHYL-D-ASPARTATE induction on ganglion cell-inner plexiform layer thickness

Ezra Margareth¹, Raissa Vaniana¹, Hermawan Istiadi², Fifin L Rahmi³, Arief Wildan³, Maharani³

¹Resident of Ophthalmology Department of Diponegoro University, Semarang, Indonesia, ²Staff of Pathology Anatomy Department of Diponegoro University, Semarang, Indonesia, ³Staff of Ophthalmology Department of Diponegoro University, Semarang, Indonesia

Introduction

Glaucoma is a neurodegenerative disease characterized by progressive retinal ganglion cell (RGC) death and axonal degeneration. N-methyl-D-aspartate (NMDA)-mediated excitotoxicity represents a common pathway for glaucomatous neuropathy. In particular, NMDA has been considered as a potential agent to serve as an instrument for studying excitotoxicity-related RGC death. The aim of this study was to investigate the effects of NMDA on Ganglion Cell-Inner Plexiform layer (GC-IPL) thickness in rats.

Method

A post test-only control group design of 4 groups male Wistar rats. Groups 1, 2, 3 and 4 were intravitreally administered with vehicle and NMDA at the doses 80, 160 and 320 nmol respectively. 8-hours, 24-hours and 3 days after NMDA injection, rats were euthanized and their eyes were taken. GC-IPL Thickness in retinal was examined by Hematoxylin Eosin staining. Data were analyzed by a Games Howell post hoc test with p value <0.05

Results

GC-IPL thickness after NMDA injection at the doses 160 and 320 nmol in 8-hours, 24-hours and 3 days was lower than the control and 80 nmol group with p value <0.05

Conclusion

The results demonstrates intravitreal NMDA injection caused dose-dependent damage to RGC death that may attributed to glaucoma.

References:

1. Lambuk L, Jafri AJA, et al. Dose-dependent effects of NMDA on retinal and optic nerve morphology in rats. *Int J Ophthalmol* 2019;12(5):746-753.
2. Cheng WS, Lin IH, et al. Neuroprotective Effects of Exogenous Erythropoietin in Wistar Rats by Downregulating Apoptotic Factors to Attenuate N-Methyl-D-Aspartate-Mediated Retinal Ganglion Cells Death. *PLoS One*. 2020;15(4):1–2

Next generation sequencing-based gene panel tests for the diagnosis of open angle glaucoma

Milla E¹, Pascual B², Gamundi M², Marone E³, Carballo M²

¹Hospital Clinic De Barcelona, Barcelona, Spain, ²Hospital de Terrassa, Barcelona, Spain, ³University of Barcelona, Barcelona, Spain

Background and rationale

Next generation sequencing (NGS) has been an invaluable tool to put genomic sequencing into clinical practice. The incorporation of clinically relevant target sequences into NGS-based gene panel tests has generated practical diagnostic tools that enable individualized patient care. Primary open angle glaucoma (POAG) is a multifactorial, complex disease for which only four genes had been described as disease causing genes in the past but in the last years more genetic variants have been identified partially due to the improvement in diagnostic tools such as NGS.

The aim of our study was to perform the genetic analysis of a cohort of Spanish patients affected of POAG by NGS-based gene panel.

Methods

Ophthalmology tests: 48 POAG patients underwent complete eye examinations and ancillary tests to diagnose the severity of the disease. Blood samples were drawn for the genetic testing. Laboratory tests: a panel of 78 genes was designed after literature search. It included “classical” glaucoma genes, new recently described genetic variants, pharmacogenetic variants, genes associated to syndromic glaucoma and quantitative endophenotypes. Panels were processed by NGS using SureSelect Custom DNA Target Enrichment Probes and sequenced in Illumina HiSeq™ platform.

Results

We found some known disease causing mutations namely CYP1B1 (p.Tyr81Asn), SIX6 (p.Thr212Met), OPTN (p.Glu322Lys), WDR36 (p.Ala449Thr and p.Asp658Gly)

and NTF4 (p.Ala88Val) , as well as other described disease-associated polymorphisms. In addition we found 14 variants in 10 different not previously described genes, and they displayed a frequency <1% than the general population. We found some variants in the CYP family, responsible for antiglaucoma drugs metabolism, which explain the genetic basis for an individual's response to therapy

Conclusion

Personalized medicine using genetic information to predict disease development and to tailor preventive interventions for each patient is an evolving field. NGS panel tests offer the possibility to test a large amount of glaucoma related genes to identify disease severity, endophenotypic traits and targeted therapies to provide a customized treatment strategy. However, the proportion of patients with a clearly defined genetic cause for glaucoma is relatively small at present.

Clinical Outcome of Acute Primary Angle Closure Post Laser Peripheral Iridotomy: A 3 Years Review

Natashini R¹

¹Hospital Sultanah Nur Zahirah, Kuala Terengganu, Malaysia, ²Department of Ophthalmology and Visual Science, School of Medical Sciences, Universiti Sains Malaysia, Kubang Kerian, Malaysia

Introduction

Primary angle closure is a major form of glaucoma in East Asian people. Acute primary angle closure (APAC) in Asian eyes is believed to be more severe as compared to Caucasian eyes.

Methods

Retrospective study of 25 patients (29 eyes) with APAC treated with laser peripheral iridotomy (LPI) were conducted at Hospital Sultanah Nur Zahirah, Terengganu, Malaysia from January 2011 until January 2017. All patients had minimum of 3 years follow-up. The demographics and clinical data on presentation were documented. Progression of the disease including visual acuity, intraocular pressure and visual field changes were analyzed.

Results

Twenty-five patients (29 eyes) with a mean age of 64.7 years old ± 7.8 were enrolled. All patients involved were Malays. Females were more commonly affected (20 patients, 80.0%) than males (5 patients, 20.0%). Twenty-one patients had unilateral APAC (84.0%) while 4 patients had bilateral APAC (16.0%). Nineteen eyes presented with vision poorer than 6/60 (76.0%) and 10 eyes had vision better than 6/60 (24.0%). The mean presenting IOP was 48.8 mmHg ± 9.5 . Only 5 eyes (17.2%) were successfully treated with LPI alone within 1 month following the resolution of acute attack. At 3 years follow-up, 24 eyes (82.8%) had vision better than 6/60 and 5 eyes (17.2%) had vision worse than 6/60. Mean IOP was 13.8 mmHg ± 2.5 . Twenty-four eyes remained as primary angle closure without

evidence of glaucomatous changes(82.7%).Of these,16 eyes required antiglaucoma(55.1%) and 8 eyes were not on antiglaucoma(27.6%).Five eyes(17.2%) developed glaucomatous changes at 3 years follow-up. One patient underwent trabeculectomy (3.4%) and 1 patient had Baerveldt implantation done.

Conclusion

Despite LPI, high proportion of eyes with APAC still require antiglaucoma and glaucoma surgery in long term. Close monitoring is crucial to prevent the progression of the disease.

Reference

3. Aung T, Ang LP, Chan SP, Chew PT. Acute primary angle-closure: long-term intraocular pressure outcome in Asian eyes. *Am J Ophthalmol.* 2001 Jan;131(1):7-12. doi: 10.1016/s0002-9394(00)00621-8. PMID: 11162972.
4. Liza-Sharmini AT, Ng GF, Nor-Sharina Y, Khairil Anuar MI, Nik Azlan Z, Azhany Y. Clinical presentation, severity and progression of primary angle closure in malay and chinese patients. *Med J Malaysia.* 2014 Dec;69(6):245-51. PMID: 25934953.
5. Ng WS, Ang GS, Azuara-Blanco A. Laser peripheral iridoplasty for angle-closure. *Cochrane Database Syst Rev.* 2012;2012(2):CD006746. Published 2012 Feb 15. doi:10.1002/14651858.CD006746.pub3

Diagnostic Challenges in Paediatric Optic Neuritis: A Case Series

[Natashini R^{1,2}](#)

¹Department of Ophthalmology, Hospital Sultanah Nur Zahirah, Terengganu, Malaysia, , , ²Department of Ophthalmology and Visual Science, School of Medical Sciences, Universiti Sains Malaysia, Kubang Kerian, Kelantan,

Introduction

Pediatric optic neuritis (PON) is a clinically isolated and self-limiting disease that presents secondary to underlying neurologic, infective, or systemic disease.

Methods

We describe three PON cases with different etiologies that presented to Hospital Sultanah Nur Zahirah, Terengganu, Malaysia.

Results

Case 1: A 3-year-old girl presented with sudden inability to walk upon waking up from sleep. There was associated fever for 5 days. Visual acuity of both eyes was 6/120. No relative afferent pupillary defect (RAPD). Fundus examination showed both eyes optic disc blurred margin. MRI brain revealed bilateral optic neuritis with white matter lesions in brain suggestive of neuromyelitis optica.

Case 2: A 15-year old girl complained of painless recurrent blurring of vision since 11 years old. Her right eye vision was 2/60 and HM over left eye. RAPD was positive over the right eye. Fundus examination showed left optic disc swelling with right eye pale optic disc. MRI was consistent with features of multiple sclerosis. MOG-IgG taken showed seropositive.

Case 3: A 9-year-old boy presented with loss of vision in his right eye for one week. Preceding that, he had episodes of urinary retention with bilateral lower limb weakness. His right eye visual acuity was PL and left eye was 6/6. RAPD was positive over the right eye. Fundus examination showed blurred right optic margin. MRI brain was suggestive of multiple sclerosis.

All three cases were treated with high dose steroid and showed significant clinical improvement in terms of visual acuity.

Conclusion

Presenting features of PON can be unilateral or bilateral and mostly due to autoimmune condition. Prompt treatment shows favorable outcome.

Reference

6. Presicci A, Serra M, Achille M, Caputo E, Margari L. Pediatric Optic Neuritis: Description of Four Cases and Review of the Literature. *Children (Basel)*. 2021 Sep 27;8(10):855. doi: 10.3390/children8100855. PMID: 34682120; PMCID: PMC8534428.
7. Khadse R, Ravindran M, Pawar N, Maharajan P, Rengappa R. Clinical profile and neuroimaging in pediatric optic neuritis in Indian population: A case series. *Indian J Ophthalmol*. 2017;65(3):242-245. doi:10.4103/ijo.IJO_939_16
8. Borchert M, Liu GT, Pineles S, Waldman AT. Pediatric Optic Neuritis: What Is New. *Journal of Neuro-ophthalmology : the Official Journal of the North American Neuro-ophthalmology Society*. 2017 Sep;37 Suppl 1:S14-S22. DOI: 10.1097/wno.0000000000000551. PMID: 28806345; PMCID: PMC6149212.

Glaucoma in Posner-Schlossman Syndrome: A Retrospective Review

[Natashini R¹](#)

¹Department of Ophthalmology, Hospital Sultanah Nur Zahirah, Terengganu, Malaysia, , , ²Department of Ophthalmology and Visual Science, School of Medical Sciences, Universiti Sains Malaysia, Kubang Kerian, Kelantan

Introduction

Posner–Schlossman Syndrome (PSS) is a benign, unilateral, secondary open angle glaucoma. It typically affects young to middle-aged individuals. The hallmark of PSS is the recurrent episodes of self-limiting, non-granulomatous anterior uveitis with markedly elevated intraocular pressure (IOP).

Methods

A retrospective study was conducted involving 14 patients diagnosed with PSS in Hospital Sultanah Nur Zahirah, Malaysia from January 2010 until January 2016. The demographics and clinical data on presentation were documented. Progression of the disease including the number of attacks, IOP, visual field and optic disc changes were analyzed.

Results

Fourteen eyes of 14 patients with the mean age 39 ± 10 (range 21–57 years old) were enrolled. Twelve patients had no comorbidity, whereas one patient with gout and another one had breast cancer. The mean follow up was 7.5 years (range, 1.5 - 11 years). PSS was more prevalent in females (57.2%). Malays were more commonly affected (85.7%) compared to Chinese (14.3%). The number of attacks ranged from 1-18 attacks. All patients presented with visual acuity better than 6/18 with the mean IOP was $39\text{mmHg} \pm 11$. Three patients with glaucomatous changes responded to medical treatment. Trabeculectomy was performed in 2 patients with uncontrolled IOP. Four patients without glaucomatous changes were on anti-glaucoma. Meanwhile, the remaining 5 patients with no evidence of glaucoma were not on anti-glaucoma

Conclusion

In this study, PSS is a rare disease with variable course. Intraocular pressure, optic disc and visual field should be monitored for glaucomatous changes. Medical treatment is efficacious to control the IOP. Nevertheless, glaucoma surgery is required in recalcitrant case.

References

1. Liu PK, Tseng HY, Huang MY, Wu KY. Glaucomatocyclitic Crises May Occur in Patients with Narrow or Closed Angles. *J Ophthalmol*. 2017;2017:4074912. doi:10.1155/2017/4074912.
2. Okonkwo ON, Tripathy K. Posner Schlossman Syndrome. 2021 Nov 14. In: StatPearls [Internet]. Treasure Island (FL): StatPearls Publishing; 2022 Jan-. PMID: 35015437
3. Jap, Aliza & Sivakumar, Meenakshi & Chee, Soon-Phaik. (2001). Is Posner Schlossman syndrome benign. *Ophthalmology*. 108. 913-8. 10.1016/S0161-6420(01)00551-6.

Acute primary angle closure: Comparison of clinical characteristics of patients with and without glaucomatous optic neuropathy at presentation

Nongpiur M¹, Hliang T¹, Aung T²

¹Singapore Eye Research Institute, Singapore, Singapore, ²Singapore National Eye Centre, Singapore, Singapore

Introduction

To compare the baseline clinical characteristics of patients with acute primary angle closure (APAC) between those with and without glaucomatous optic neuropathy (GON) at presentation.

Methods

In this study, we retrospectively extracted the following clinical data from the case records of 135 APAC patients: age at presentation of APAC, presenting intraocular pressure (IOP), gonioscopy performed prior to laser or surgical intervention, vertical cup-to-disc ratio (VCDR), first reliable visual field mean deviation (VFMD), visual acuity after resolution of the acute episode, ocular biometry, and pre-surgery refractive data. Patients who were diagnosed with GON prior to presentation of the APAC episode were excluded. APAC was defined by the presence of specific symptoms and signs.

Results

Of the 135 patients, 71 were diagnosed to have GON with compatible VF loss at presentation, and 64 did not. Comparison between the APAC with glaucoma and non-glaucoma group revealed no significant differences in the age at presentation (62.2 ± 9.7 vs 59.5 ± 7.6 years, $p=0.07$), gender (69.0% vs 67.2%, $p=0.82$), presenting IOP (55.7 ± 10.8 vs 56.2 ± 9.2 mmHg, $p=0.78$), axial length (22.54 ± 0.83 vs 22.80 ± 1.10 mm, $p=0.16$), anterior chamber depth (2.47 ± 0.44 vs 2.47 ± 0.92 mm, $p=0.98$), lens thickness (4.53 ± 0.94 vs 4.44 ± 0.92 mm, $p=0.73$), and spherical equivalent (-0.42 ± 1.78 vs -0.31 ± 2.23 D, $p=0.80$). Significant differences were observed in the VCDR (0.69 ± 0.22 vs 0.44 ± 0.14 , $p<0.001$) and VFMD (-21.73 ± 8.8

vs -4.12 ± 3.2 dB, $p < 0.001$). The APAC glaucoma eyes also had significantly worse visual acuity (logMAR 0.37 ± 0.25 vs 0.22 ± 0.16 , $p < 0.001$) and wider anterior chamber angles (mean Shaffer gonioscopy 0.53 ± 0.68 vs 0.29 ± 0.47 , $p = 0.03$).

Conclusion

Clinical and biometric parameters were largely similar in APAC eyes irrespective of the likely presence of underlying optic neuropathy. Despite having greater visual impairment and severe VF loss, patients with APAC and GON only presented to hospital due to the symptomatic episode of elevated IOP. The late presentation puts these individuals at a greater risk of blindness and necessitates the need for their early detection and treatment.

Diurnal variation of corneal hysteresis in untreated primary open angle glaucoma and normal subjects

Okayama M¹, Tsuchiya S¹, Higashide T¹, Udagawa S¹, Yamashita Y¹, Shioya S¹, Takemori H¹, Nakazawa K¹, Manbo Y¹, Sugiyama K¹

¹Kanazawa University, kanazawa

Introduction

To investigate the diurnal variation of corneal hysteresis (CH) in patients with untreated primary open angle glaucoma (POAG) and normal subjects using the Ocular response analyzer (ORA).

Methods

This prospective study included 72 eyes of 52 patients with untreated POAG and 53 eyes of 47 normal subjects. The intraocular pressure (IOP) was measured by Goldmann applanation tonometry and CH was measured using ORA every 3 hours from 9:00 to 24:00. Diurnal variation of IOP and CH in POAG patients and normal subjects were analyzed using mixed-effects models. Factors associated with the CH amplitude and mean CH values were also explored with the mixed models.

Results

The CH in both groups had a significant diurnal variation with increasing in nocturnal period and decreasing in diurnal period ($P < 0.05$) while IOP had the antiphase pattern with a significant change ($P < 0.05$). The multivariate mixed model analysis revealed that the diurnal amplitude of CH had a significantly positive correlation with the IOP amplitude (coefficient \pm standard errors: 0.110 ± 0.035 ; $P = 0.002$). Moreover, the thinner central corneal thickness, higher mean IOP, and the existence of glaucoma were significantly associated with the lower diurnal mean average CH values (0.017 ± 0.003 , -0.108 ± 0.038 , -0.423 ± 0.212 ; $P < 0.001$, $=0.004$, $=0.046$, respectively).

Conclusion

CH in patients with both untreated POAG and normal subjects demonstrated significant diurnal variation. The larger diurnal IOP variations were significantly associated with the higher CH amplitude in both groups.

A simple tool of aqueous humor polymerase chain reaction to diagnose a case of chronic anterior uveitis with secondary glaucoma of 25 years

Ong J¹, Oo K¹, See Y¹

¹Sarawak General Hospital, Kuching, Malaysia

Introduction

Cytomegalovirus (CMV) anterior uveitis is a relatively recently emerged disease entity increasingly detected over the past decade among immunocompetent patients. Following recent advances in polymerase chain reaction (PCR) technology, CMV is the causative virus for estimated two-thirds of viral uveitis cases in Asian countries. Its variable ocular manifestation and absence of distinctive clinical features can contribute to diagnostic challenge.

Case presentation

We report the case of a 67-years-old immunocompetent gentleman presenting with left eye chronic hypertensive anterior uveitis and secondary glaucoma refractory to treatment for 25 years. His glaucoma control progressively worsened over the years, eventually resulting with a failed left eye trabeculectomy. He was recently diagnosed with CMV anterior uveitis following a positive aqueous humor PCR analysis. Disease remission was achieved following initiation of topical ganciclovir with no signs of recurrence to date. Despite symptomatic resolution, IOP elevation persisted. He is scheduled for glaucoma drainage device surgery.

Conclusion

We highlight the clinical features, investigation findings and diagnostic dilemma of CMV anterior uveitis to raise clinical suspicion for similar diagnoses in the future. It is crucial for clinicians to be able to recognize and have a low threshold of acquiring aqueous fluid analysis to aid diagnosis and avoid many unnecessary laboratory investigations. Diagnostic uncertainty can lead to increased ocular morbidity and reduced quality of life.

References

1. Chee SP, Bacsal K, Jap A, Se-Thoe SY, Cheng CL, Tan BH. Clinical features of cytomegalovirus anterior uveitis in immunocompetent patients. *Am J Ophthalmol.* 2008; 145:834-840.
2. Hsiao YT, Kuo MT, Chiang WY. Epidemiology and clinical features of viral anterior uveitis in southern Taiwan - diagnosis with polymerase chain reaction. *BMC Ophthalmol.* 2019; 19:87.
3. Chee SP, Jap A. Presumed fuchs heterochromic iridocyclitis and Posner-Schlossman syndrome: comparison of cytomegalovirus-positive and negative eyes. *Am J Ophthalmol.* 2008; 146:883-889.
4. Pleyer U, Chee S. Current aspects on the management of viral uveitis in immunocompetent individuals. *Clin Ophthalmol.* 2015; 9:1017-1028.
5. Chronopoulos A, Roquelaure D, Souteyrand G, Seebach JD, Schutz JS, Thumann G. Aqueous humor polymerase chain reaction in uveitis - utility and safety. *BMC Ophthalmol.* 2016; 16:189.
6. Miyazaki D, Shimizu D, Shimizu Y, Inoue Y, Inoue T, Higaki S et al. Real-time PCR for ocular cytomegalovirus infection study group. Diagnostic efficacy of real-time PCR for ocular cytomegalovirus infections. *Graefes Arch Clin Exp Ophthalmol.* 2018; 256:2413-2420.
7. Trivedi D, Denniston AK, Murray PI. Safety profile of anterior chamber paracentesis performed at the slit lamp. *Clinical & Experimental Ophthalmology.* 2011; 39:725-728.
8. Accorinti M, Gilardi M, Pirraglia MP, Amorelli GM, Nardella C, Abicca I et al. Cytomegalovirus anterior uveitis: long-term follow-up of immunocompetent patients. *Graefes Arch Clin Exp Ophthalmol.* 2014; 252:1817-1824.

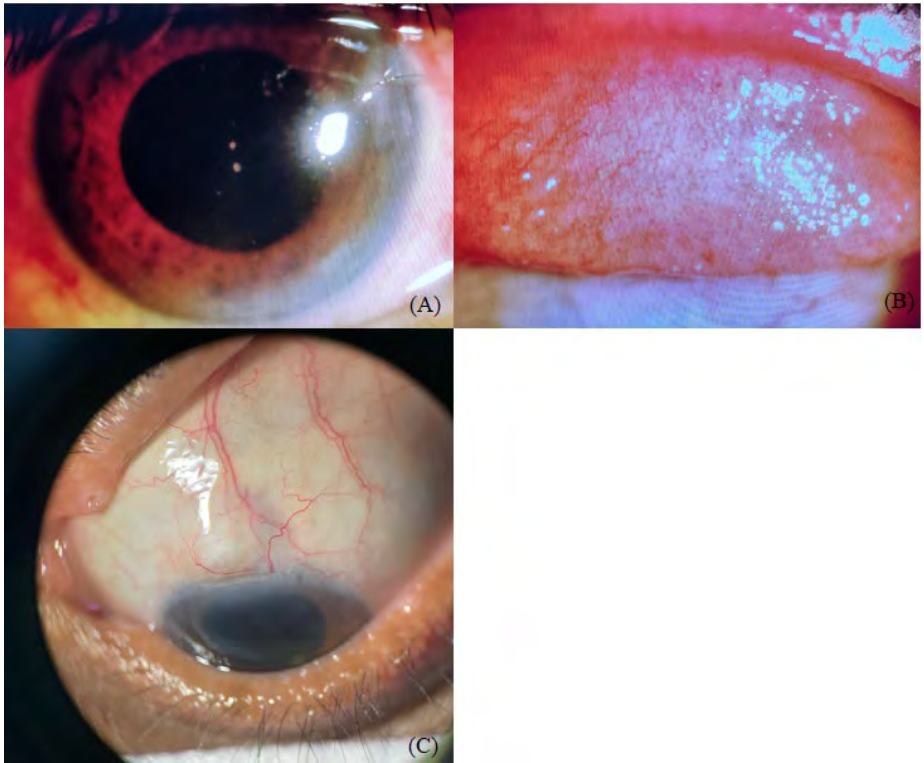


Fig.1. Anterior segment of left eye. (A) Fresh mutton-fat keratic precipitates (B) Palpebrae conjunctiva papillae (C) Trabeculectomy bleb

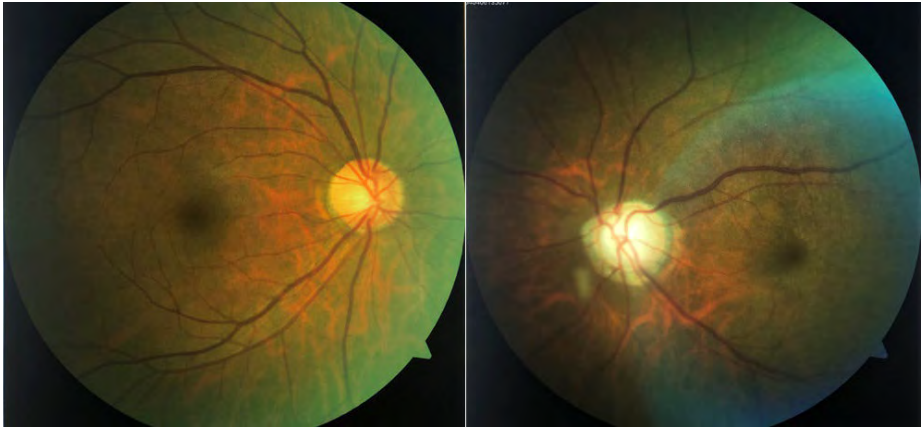


Fig.2. Fundus pictures of bilateral eyes, showing left eye glaucomatous optic disc changes (right image).

Ong Square Scleral Punch

[Ong K¹](#)

¹University Of Sydney, Sydney, Australia

Introduction

In trabeculectomy, it is ideal to make a sufficiently large internal opening to facilitate exit of aqueous, complemented by a scleral flap that is sutured so as to cover this opening to prevent excessive egress of fluid.

Methods

The maximum dimension of the internal scleral opening of the fistula is dictated by the cornea anteriorly and iris root-ciliary body posteriorly. Shapes and sizes of tissues cut by various scleral punch designs were analysed - standard round, square and triangle.

Results

The optimal design found was a square cross-section scleral punch to cut a square block of tissue 0.8 mm x 0.8mm. This size was chosen so as the instrument will fit into a 3 mm wide limbal incision under the 3 mm scleral flap. A round scleral punch would have to be of similar dimensions to fit into this 3 mm incision.

A 0.8mm square cross-section opening has a cross-section area of 0.8mm x 0.8mm = 0.64 mm². A 0.8 mm diameter cross-section round opening would have a cross-section area of $3.14 \times 0.4\text{mm} \times 0.4 \text{ mm} = 0.50 \text{ mm}^2$.

Success of trabeculectomy can be enhanced by combining with groove sclerectomy (YouTube "Groove Sclerectomy in Trabeculectomy").

Conclusion

Hence, a square cross-section scleral punch will give a larger effective opening than a round profile scleral punch when the same number of scleral cut-bite is used - one or two is usually sufficient with this design. There is less risk of cutting

into uveal tissue, as there is less need to make multiple bites to make a larger opening posteriorly.

References

1. Groove Sclerectomy in Trabeculectomy: YouTube video 2018.
2. Ong Square Scleral Punch for Trabeculectomy. Farocare Australia and Epsilon USA.

SMILE Lenticule Assisted Modified Technique of Ahmed Glaucoma Valve Implantation.

PANDEY A¹, SHAH R¹

¹Centre For Sight, Surat, India

Introduction

The aim is to describe the application of a Modified surgical technique of implanting Ahmed Glaucoma Valve (AGV), to decrease surgical time, minimize the risk of complications and provide better outcomes.

Methods

Data of a patient implanted with AGV using the surgical technique described was retrospectively analysed. Patient underwent AGV implantation for uncontrolled glaucoma, despite a previous trabeculectomy. Postoperatively, Intraocular pressure (IOP) measurement and ophthalmic examination were done at weekly intervals for a month, to detect complications like wound leak, conjunctival retraction, hypotony, choroidal detachment or haemorrhage.

The modified surgical technique consisted of using 2 corneal lenticules acquired from one patient who underwent small incision lenticule extraction (SMILE) for myopia correction. These lenticules were placed over the subconjunctival part of the AGV tube in a manner to provide a triple layered covering over it.

Results

IOP reduced from preoperative value of 38 mm Hg to 12 mm Hg at 1 month follow up. No wound leakage, conjunctival retraction, hypotony or hypotony related posterior segment complications were noted in all the follow-ups. Patient remained comfortable and had no complains of foreign body sensation during this period.

Conclusion

SMILE lenticule can be a better alternative to preserved partial thickness corneal/scleral graft, conventionally used in AGV implantation to prevent tube exposure. Ease of manipulation, lack of epithelial/uveal tissue remnants, potentially lower chances of retraction, better patient comfort and cosmesis are some of the various advantages noted of using this technique.

Short Term Success of Trabeculectomy with Mitomycin C over trabeculectomy without Mitomycin C in Patients with Advanced Juvenile Open Angle Glaucoma

[Paul A¹](#)

¹Regional Institute of Ophthalmology, Kolkata., Dumdum, India

Purpose

To evaluate the effects of intraoperative application of mitomycin-c during trabeculectomy in a Juvenile Open Angle Glaucoma.

Methods

A hospital based prospective interventional study was done after obtaining clearance from ethical committee. Patients were divided into two main groups: Group 1 included 20 eyes of 28 patients with juvenile glaucoma. We performed trabeculectomy without use of MMC. Group 2 included 20 eyes of 30 patients with juvenile glaucoma on which we performed trabeculectomy with MMC. Assessment of clinical outcome included intraocular pressure, visual acuity, visual field and complications. Follow up was done for 2years. Success of filtering surgery was defined as final IOP of 21 mmHg or lower with or without antiglaucoma medications.

Results

At the end of 2 years post-operatively , a significant drop in IOP with complete success rate of 80% and qualified success rate of 10% and failure rate of 10% was noted, with significant p value(0.05%) in the group1 whereas complete success rate of 60% and qualified success rate of 6% and failure rate of 42% in group 2 p value(0.05%).

Conclusions

Mitomycin-C as adjunctive treatment during trabeculectomy in JOAG offers a great benefit in reducing IOP with lesser number of complications.

Efficacy and safety of medical treatment in acute angle closure glaucoma at Thammasat hospital

Penpian C¹, Ananprasert S²

¹Thammasat University Hospital, Bangkok, Thailand, ²Thammasat University Hospital, Bangkok, Thailand

Introduction

Acute angle closure glaucoma (AACG) (is a suddenly high intraocular pressure (IOP) from pupillary block which cause optic neuropathy. The key concept of AACG management is to promptly lower the IOP in order to prevent blindness. The IOP-lowering medical treatments are prescribed to reduce the IOP in the initial stage, which are used to help clear up the cornea and reduce ocular inflammation before performing laser-peripheral iridotomy (L-PI). The purpose of this study is to determine the effectiveness and safety of medical treatments in the initial management of AACG at Thammasat University Hospital.

Methods

Prospective pre-experimental study. Twelve cases of AACG were diagnosed at Thammasat Hospital. All participants were enrolled in this study. Patients without a history of drug allergy underwent a protocol of management at Thammasat Hospital. Patients were recorded at regular intervals for IOP control, and patients were given medication until resolution of AACG which is defined as IOP \leq 30 mmHg and resolution of acute symptoms. Qualitative data were calculated into percentage. Quantitative data were calculated as mean and standard deviation.

Results

Fifteen eyes of 12 patients, 7 (58.33%) women with the mean age of 70.58 \pm 6.1 years were studied. With medical therapy, AACG resolved within 1, 12, and 24 hours are 6 (50%), 4 (33.33%), and 1 (8.33%), respectively. No serious adverse effects of IOP-lowering medical treatment were observed in this study. Successful L-PI was performed in all subjects.

Conclusion

According to the result in this study found that IOP-lowering medical treatments prescribed to reduce initial stage of IOP is effective and safe. Medical management of AACG should still remain as the first-line treatment.

Ineffective Trabeculectomy in Glaucoma Secondary to Sturge Weber Syndrome: A Case Report

Permatasari D¹, Rahmi F², Puspasari D², Maharani²

¹Resident of Ophthalmology Department of Diponegoro University, Kariadi Hospital, Semarang, Indonesia

²Staff of Glaucoma Subdivision, Ophthalmology Department of Diponegoro University, Kariadi Hospital, Semarang, Indonesia

Introduction

Glaucoma secondary to Sturge Weber Syndrome (SWS) is a challenging disease due to its condition's variable presentation, complex etiology, and poor response to standard medical treatment. Aim of this case report was to present ineffective trabeculectomy in glaucoma secondary to SWS.

Methods

A 21-year-old male patient presented with slow blurring of vision in the right eye (RE) and left eye (LE) for 3 years ago. There was port-wine stain on both side of face that involved the upper and lower lids. His visual acuity was 6/38 in RE and no light perception in LE. The intraocular pressure (IOP) was 51mmHg (RE) and 59mmHg (LE). There was dilatation of episcleral vessels and funduscopy revealed glaucomatous optic nerve. Medications failed to control IOP, thus he underwent RE trabeculectomy.

Results

First day after surgery, the IOP was 7.1mmHg and visual acuity was 6/15. A week post-operative, the IOP was 10.1mmHg and visual acuity was 6/20. The bleb appeared elevated. One-month post-operative, the IOP tended to increase again. Topical therapy was given to maintain IOP.

Conclusion

Trabeculectomy in glaucoma secondary to SWS requires close monitoring of IOP as there's a potential for IOP to rise again. Trabeculectomy with antimetabolites or glaucoma drainage device implantation can be considered to obtain long-term control of IOP.

References

1. Glaser TS, et al. Outcomes and lessons learned from two decades' experience with glaucoma drainage device implantation for refractory Sturge Weber-associated childhood glaucoma. JAAPOS 2021;25:332.e1-6.
2. Javaid, et al. Pathophysiology, diagnosis, and management of glaucoma associated with Sturge-Weber syndrome. Int-Ophthalmol. 2017.
3. Mantelli, et al. Ocular manifestations of Sturge-Weber syndrome: pathogenesis, diagnosis, and management. Clinical Ophthalmology 2016;10:871-878.

Bilateral Serous Retinal Detachment in Pregnancy

Daniel P^{1,2}, Nurulhuda A², Hayati A², Francesca Martina V², Khairy Shamel S¹

¹Department of Ophthalmology and Visual Sciences, School of Medical Sciences, Universiti Sains Malaysia, 16150 Kubang Kerian, Malaysia, ²Department of Ophthalmology, Hospital Sultanah Aminah, 80000 Johor Bharu, Malaysia

Introduction

Serous retinal detachment in pregnancy is a rare complication of preeclampsia. Its presentation is usually acute and the main symptoms include blurring of vision and visual field defects.

Methods

Case report

Results

We herein report a case serous retina detachment in a 30-year-old primigravida who developed bilateral serous retinal detachment in her third trimester. Fundus examination revealed bilateral serous retina detachment involving macula. She was treated conservatively and her blood pressure normalized after delivery. There was partial resolution of subretinal fluid 1 month post delivery and complete resolution of subretinal fluid 9 months later. Her final best corrected visual acuity was 6/6 and N5 in both eyes.

Conclusion

Bilateral serous retinal detachment in pregnancy is a rare sight threatening complication of pre-eclampsia. Management of pre-eclampsia-induced serous retinal detachment is conservative and carries good visual prognosis.

References

1. Roos NM, Wiegman MJ, Jansonius NM, Zeeman GG. Visual disturbances in (pre)eclampsia. *Obstet Gynecol Surv.* 2012 Apr;67(4):242-50. doi: 10.1097/OGX.0b013e318250a457. PMID: 22495060.
2. Srećković SB, Jančićjević-Petrović MA, Stefanović IB, Petrović NT, Sarenac TS, Paunović SS. Bilateral retinal detachment in a case of preeclampsia. *Bosn J Basic Med Sci.* 2011;11(2):129-131. doi:10.17305/bjbms.2011.2598
3. Spaide RF, Goldbaum M, Wong DW, Tang KC, Iida T. Serous detachment of the retina. *Retina.* 2003 Dec;23(6):820-46; quiz 895-6. doi: 10.1097/00006982-200312000-00013. PMID: 14707834.

Surgical intervention for dynamic movement of a glaucoma drainage device with shifting tube position associated with corneal edema and cataract

Ogino M¹, Plotnik J²

¹Phoenix Children's Hospital, Scottsdale, United States, ²Creighton University School of Medicine, Phoenix, United States

Background

Dynamic tube movement is a rarely reported complication occurring after placement of a glaucoma drainage device. When encountered, there is variability in the position of the glaucoma shunt tube associated with movements of the eye. The result is an increase or decrease in the amount of tube in the anterior segment.

Observations

This case describes a six-year-old male with no previous eye surgeries who demonstrated excessive tube movement after placement of a glaucoma shunt. The tube movement was associated with corneal edema and a cataract. A video documenting the dynamic tube movement accompanies this case report.

Conclusion

Dynamic tube movement has previously been reported only in cases in which other ocular surgeries had been performed. While localized corneal edema was identified in one of the earlier cases, intermittent migration of the tube under the iris and tube-lenticular touch with cataract formation has not been previously reported. Intraoperative exploration showed the failure of adequate fixation of the shunt plate to the globe as the cause of the dynamic tube movement.

References

1. Park HL, Jung KI, Park CK. Serial intracameral visualization of the Ahmed glaucoma valve tube by anterior segment optical coherence tomography. *Eye* 2012; 26:1256–1262.

2. Tan AN, De Witte PM, Webers CA, et al. Baerveldt drainage tube motility in the anterior chamber. *Eur J Ophthalmol* 2014; 24(3):364-70.
3. Law SK, Coleman AL, Caprioli J. Dynamic tube movement of Ahmed glaucoma valve. *J Glaucoma* 2009; 18:628-31.
4. Senthil S, Badakare A, Dynamic tube movement after reimplantation of Ahmed glaucoma valve in a child with glaucoma in aphakia. Epub ahead of print April 2, 2014 *BMJ*.

A rare case of fibrin membrane pupillary block glaucoma post uneventful cataract surgery

Ponnaiah P¹, Ui Lyn L¹, Buandasan K¹

¹Hospital Sultanah Nora Ismail, Batu Pahat, Malaysia

Introduction

Fibrin membrane pupillary block glaucoma is a rare postoperative complication after an uneventful cataract surgery. Its presentation may be similar to postoperative endophthalmitis. This case reports the clinical features of this complication to ensure early detection and prompt treatment.

Method

Case report

Results

56 years old, lady with uncontrolled diabetes mellitus, presented with painful, red left eye (OS) one week after an uncomplicated cataract surgery. Visual acuity OS was 6/36. She had mildly injected conjunctiva, oedematous cornea and shallow anterior chamber with intraocular pressure (IOP) of 48mmHg. Oral and topical IOP lowering agents were commenced. Once corneal oedema cleared, intermittent posterior synechiae with dense fibrin covering the pupil and behind the intraocular lens (IOL) were evident. B scan showed localised vitreous opacities behind the IOL but no loculation. There was no keratic precipitates, iris nodules and hypopyon. Topical intensive steroid challenge was promptly commenced and did not worsen her eye condition. Thus, we continued with hourly topical dexamethasone 0.1%, moxifloxacin hydrochloride ophthalmic solution 0.5%, oral acetazolamide and topical IOP lowering agents.

After three days, OS vision improved to 6/24 and IOP was 6mmHg. Anterior chamber deepened with 1+ cells. Posterior synechiae were released and contracted fibrin was seen only at center of pupil and retrolentally. Fundoscopy showed diabetic papillitis, severe non proliferative diabetic retinopathy and

diabetic macula oedema with no evidence of infection. A retrospective diagnosis of fibrin pupillary block glaucoma was made.

Conclusion

Postoperative fibrin pupillary block glaucoma may mimic acute endophthalmitis. Thorough assessment is required to differentiate them to ensure proper early treatment to prevent further complication.

References

1. Khan S, Elashry M. The Nd: YAG laser as first-line treatment for fibrin pupillary-block glaucoma following uncomplicated cataract surgery. Oxford Medical Case Reports. 2019 Jan;2019(1):omy113.
2. Yoshino H, Seki M, Ueda J, Yoshino T, Fukuchi T, Abe H. Fibrin membrane pupillary-block glaucoma after uneventful cataract surgery treated with intracameral tissue plasminogen activator: a case report. BMC ophthalmology. 2012 Dec;12(1):1-4.
3. Gatton DD, Mimouni K, Lusky M, Ehrlich R, Weinberger D. Pupillary block following posterior chamber intraocular lens implantation in adults. British journal of ophthalmology. 2003 Sep 1;87(9):1109-11.
4. Ragab IT, Abdelkader AM, Kishk HM, Elshal AA. Assessment of post-operative pseudophakic glaucoma by ultrasound biomicroscopy. Clinical Ophthalmology (Auckland, NZ). 2020;14:1495.

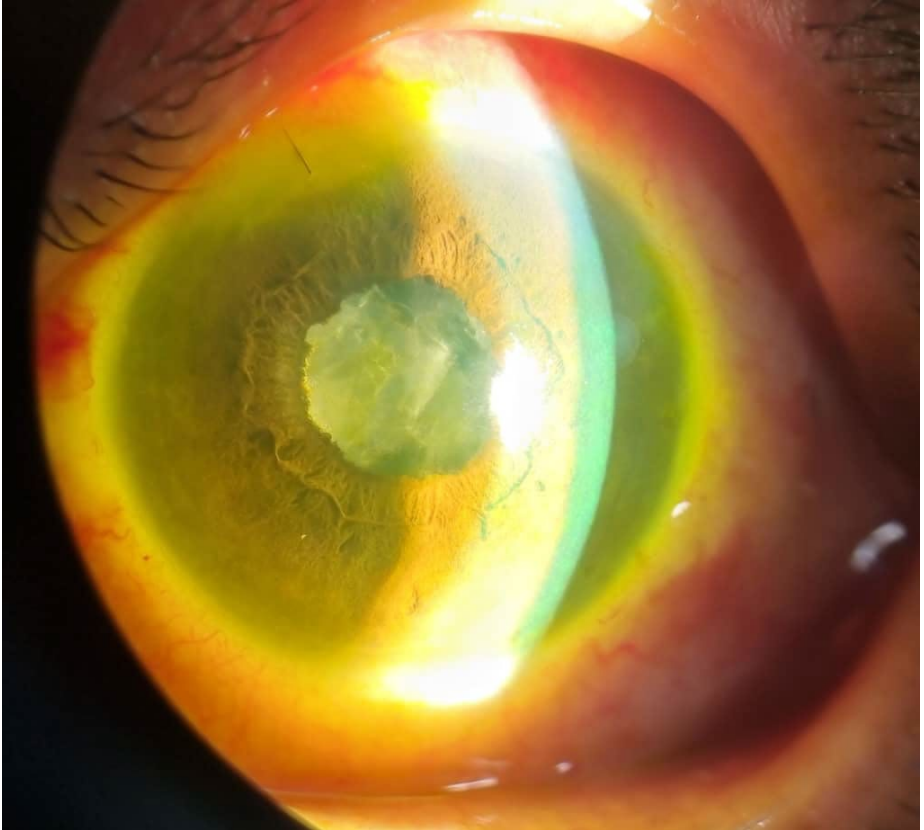


Figure12 Fibrin covering pupil

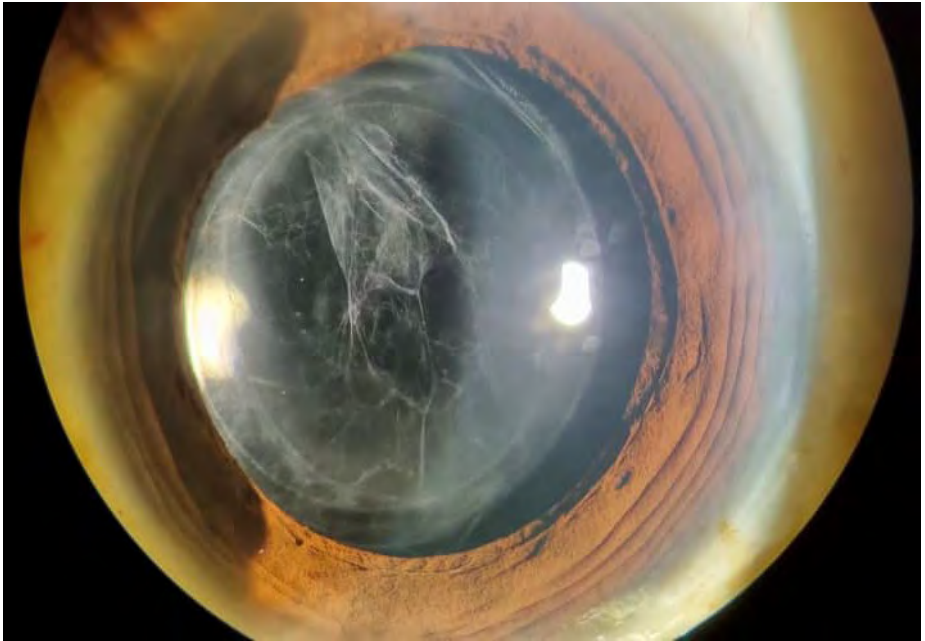


Figure13 Contracted fibrin

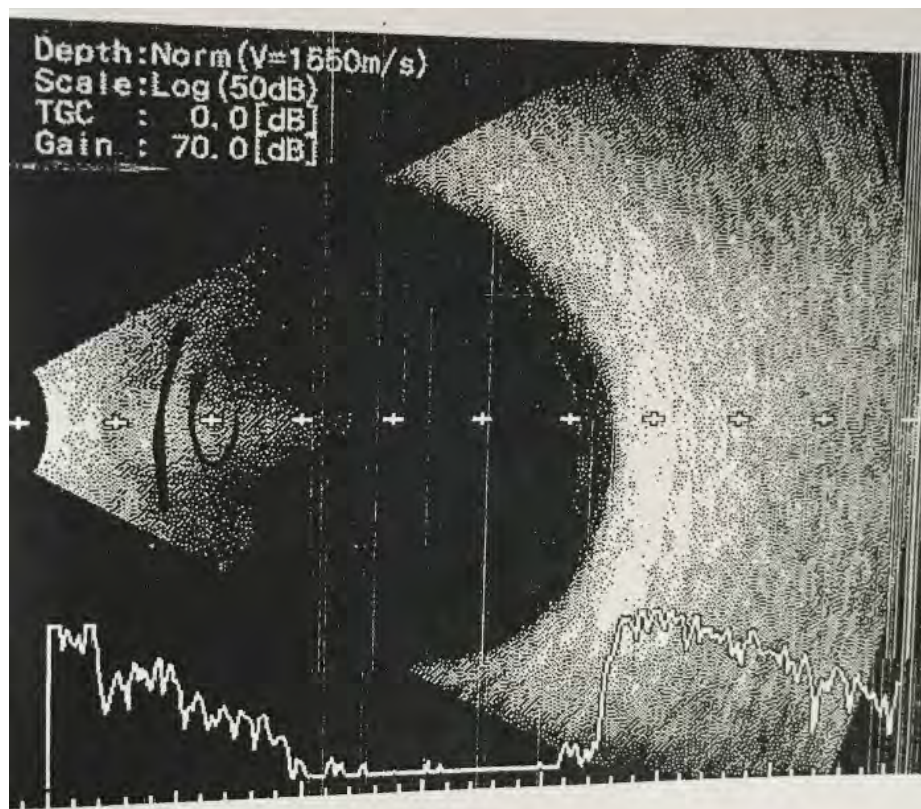


Figure14 B scan: Retrolental vitreous opacity

Assessment of IOP measurement between Goldman Applanation Tonometer, Rebound Tonometer, Non-Contact Tonometer and its correlation with Central Corneal Thickness

[Porwal A¹](#)

¹Choithram Netralaya, Indore, India

Introduction

To compare the IOP readings taken with Goldman Applanation Tonometer (GAT) with Non-Contact Tonometer (NCT) and Rebound Tonometer (RBT- iCare) and their correlation with Central Corneal Thickness (CCT).

Methods

Cross sectional observational study where patients above 18 years of age coming to the eye OPD were enrolled. 400 eyes of 200 non glaucomatous patients underwent IOP recordings by GAT, NCT, RBT and CCT was also noted. Patients with ocular surface disorder, posterior segment pathology and patients who were not willing were excluded from the study. The IOP values of the three methods were compared and were correlated with CCT.

Results

Mean IOP measured by NCT was 15.65 ± 2.80 , by RBT was 14.23 ± 3.05 and by GAT was 14.69 ± 2.97 . Mean central corneal thickness was 510.61 ± 33.83 . Difference between mean IOP recorded by NCT and RBT is 1.41 ± 2.39 and between NCT and GAT is 0.95 ± 2.03 and between GAT and RBT is 0.45 ± 2.22 . Difference between the IOP values is statistically significant [p value >0.005]. In our study it is seen that NCT values > GAT values > RBT values. It was observed that the RBT values of IOP were closer to those measured by GAT the difference being 0.45 ± 2.22 . All Tonometers show a statistically significant correlation with CCT but it is observed that NCT has a stronger correlation [Pearson correlation 0.4037]

Conclusion

The IOP reading by all the three methods is comparable however RBT values are closer to GAT values. CCT does influence the IOP values and is to be kept in mind while evaluating.

Success Rate of Trabeculectomy in Dr.Kariadi Hospital During Covid-19 Pandemic

Prabhaswari Y¹, Maharani², Puspasari D², Rahmi F²

¹Medical Faculty of Diponegoro University, Semarang, Indonesia, ²Ophthalmology Department of Diponegoro University, Semarang, Indonesia

Introduction

Trabeculectomy is the effective procedure used to decrease intraocular pressure (IOP) and can reduced frequency visit to the hospital during coronavirus disease 2019 (COVID-19) pandemic in glaucoma patients.

Methods

This study was a retrospective cohort using medical records of glaucoma patient underwent trabeculectomy in Dr. Kariadi Hospital during March 2020 – September 2021. Patients were categorized into 3 groups: Complete success rate if within 3 months the IOP 21 mmHg or 20% reduction in mild glaucoma, 18 mmHg or 30% reduction for moderate glaucoma, 15 mmHg or 40 % reduction for severe glaucoma without anti-glaucoma medication. Partial success rate is the group of patients who can achieve the target IOP with the use of one or two antiglaucoma drugs. Patients who did not achieve the target IOP or use of more than two types of antiglaucoma drugs were considered to have failed.

Results

158 eyes were matched with inclusion and exclusion criteria. The complete success rate for trabeculectomy was 45%, partial success rate was 18%, failed was 16%. The complete success rate for trabeculectomy with antimetabolite was 14%, partial success rate was 9%, failed was 8%. The complete success rate for phacotrabeculectomy was 82%, partial success rate was 7%, failed was 22%.

Conclusion

Phacotrabeculectomy has the highest success rate compared to others in the Dr. Kariadi Hospital during Covid-19 Pandemic

References

1. Holland LJ, Mercieca KJ, Kirwan JF. Effect of COVID-19 pandemic on glaucoma surgical practices in the UK. Br J Ophthalmol. 2021;1–5.
2. Shaarawy TM, Sherwood MB, Grehzn F (ed). Guidelines on design and reporting of glaucoma surgical trials. World Glaucoma Association

Midterm Glaucoma Surgery Outcomes in Dr.Kariadi General Hospital during the COVID-19 Pandemic

Purnaningrum N¹, Cahyono M², Puspasari D², Rahmi F²

¹Faculty Of Medicine, Diponegoro University, Semarang, Indonesia,

²Ophthalmology Department, Faculty of Medicine, Diponegoro University, Semarang, Indonesia

Introduction

This study aimed to investigate the midterm glaucoma surgery outcomes in Dr. Kariadi Hospital during the COVID-19 pandemic

Methods

This was an observational study of glaucoma surgery outcomes on 1 month and 3 months after surgery during March 2020 until September 2021

Results

A total of 381 patients underwent glaucoma surgery, but only 181 patients completed 1 month and 3 months postoperative follow-up. 68 patients (37.6%) had phacotrabeculectomy, 26 (14.4%) had phacoemulsification, 69 (38.1%) had trabeculectomy, 16 (8.8%) had glaucoma drainage device (GDD) implantation, and 2 (1.1%) had GDD implantation and phacoemulsification. Preoperative IOP in phacotrabeculectomy group, phacoemulsification group, trabeculectomy group, GDD implantation group, and GDD implantation plus phacoemulsification group were 31.44 ± 12.17 mmHg, 20.15 ± 7.83 mmHg, 32.74 ± 11.19 mmHg, 30.59 ± 7.28 mmHg, 20.15 ± 0.77 mmHg, respectively. Decrease IOP was seen at 1 month and 3 months follow-up in all groups except GDD implantation plus phacoemulsification. Visual acuity was improved in trabeculectomy and GDD implantation plus phacoemulsification group. Complications that happened during the follow-up were flat anterior chamber and misplaced GDD tube.

Conclusion

Glaucoma surgery during the COVID-19 pandemic had good midterm outcomes even though urgent cases were prioritized. Long-term follow-up is still needed to know the final outcome.

References

1. Holland L, Kirwan J, Mercieca K. Effect of COVID-19 pandemic on glaucoma surgical practices in the UK. *British Journal of Ophthalmology*. 2021;1-5.
2. Dub N, et al. Changes to glaucoma surgery patterns during the COVID-19 pandemic : A shift toward less invasive procedures. *Journal of Clinical Medicine*. 2021;10.

OCT-based Bruch Membrane Opening as Optic Nerve Head Profile in Glaucoma Patient and Normal Population

[Putri Khrisnawati A¹](#), Ekantini R¹, Talka Gani T¹, Jati K¹

¹Sardjito General Hospital, Yogyakarta, Indonesia

Introduction

Optic nerve head examination using OCT has been widely used for detection and evaluating progression of glaucoma structurally. Recently, Bruch Membrane Opening (BMO) has become new standard measurement of optic nerve head profile in patient with glaucoma.

Methods

A cross-sectional study was done in 72 glaucoma patients (25 NTG and 47 POAG) and 56 normal patients. Bruch Membrane Opening (BMO), Retinal Nerve Fiber Layer (RNFL), Ganglion Cell Inner Plexiform Layer (GCIPL), Perfusion, Flux Index and CDR of optic nerve head in normal and glaucoma groups was measured using Cirrus HD-OCT and analysed using SPSS. P-value of <0,05 was considered significant.

Results

Median BMO, RNFL, and GCIPL of glaucoma patients was 1.642mm (1.028-2.182), 97µm (36-141), 80 µm (26-99) respectively. In normal patients, median of BMO, RNFL and GCIPL were 1.522mm (1.263-1.962;), 103.5 µm (81-133) and 85 µm (75-95) respectively. Mean of CDR in glaucoma and normal groups was 0,60±0.15 and 0.43±0.13 with 95% CI -0.22 – (-0.12). Perfusion and Flux index in glaucoma group was 0.449 (0.326-0.517) and 46% (39%-50%). Otherwise, in normal patient, Perfusion and Flux index was 0.454 (0.433-0.483) and 46% (39%-50%) respectively. All of the variable tested between glaucoma and normal group showed significant difference with $P < 0,05$ except Perfusion which has $P = 0,056$. There was also significant difference of BMO ($P = 0.001$; 95% CI -0.31 – (-0.07)) between NTG and normal groups.

Conclusion

There is significant difference of BMO between glaucoma and normal patient. BMO can be used as a parameter for diagnosing of glaucoma alongside RNFL, GCIPL, CD ratio especially in normo-tension patients.

Table 1. Characteristic of patients

	Normal	NTG	POAG
No. of eyes	56	25	47
Age \pm SD	29,0 \pm 7,6	42,4 \pm 13,8	48,6 \pm 14,3
Sex (%)	M 18 (32,1)	8 (32)	24 (51)
	F 38 (67,9)	17 (68)	23 (49)
Spherical Equivalence \pm SD	-0,67 \pm 1,33	-2,13 \pm 1,65	-1,32 \pm 1,88

Table 2. Comparison of BMO, RNFL, GCIPL, Perfusion and Flux Index between glaucoma groups and normal group using Mann-Whitney U test

	Normal		Glaucoma		P-value
	Median	Min-max	Median	Min-max	
BMO	1522	1.263-1.962	1642	1.028-2.182	0.001
RNFL	103.5	81-133	97	36-141	0.000
GCIPL	85	75-95	80	26-99	0.000
Perfusion	0.454	0.433-0.483	0.449	0.326-0.517	0.056
Flux	0.46	0.39-0.50	0.41	0.26-0.48	0.000

Table 3. Comparison of CDR between glaucoma groups and normal group using T-test

	Normal		Glaucoma		P-value	95% CI
	Mean	(SD)	Mean	(SD)		

CDR	0.43	0.133	0.60	0.151	0.000	-0.22 – (-0.12)
-----	------	-------	------	-------	-------	-----------------

Table 4. Comparison of BMO, RNFL, GCIPL, and CDR between normal group, NTG and POAG groups using Multivariate analysis

			P-value
BMO	Normal	NTG	0.001
		POAG	0.101
	NTG	POAG	0.086
RNFL	Normal	NTG	0.062
		POAG	0.000
	NTG	POAG	0.072
GCIPL	Normal	NTG	0.017
		POAG	0.000
	NTG	POAG	0.069
CDR	Normal	NTG	0.000
		POAG	0.000
	NTG	POAG	0.515

References

1. Muth, D.R. and Hirneiß, C.W., 2015. Structure–function relationship between Bruch's membrane opening–based optic nerve head parameters and visual field defects in glaucoma. *Investigative ophthalmology & visual science*, 56(5), pp.3320-3328.
2. Zheng, F., Wu, Z. and Leung, C.K., 2018. Detection of Bruch's membrane opening in healthy individuals and glaucoma patients with and without high myopia. *Ophthalmology*, 125(10), pp.1537-1546.

Evaluation of giant blebs after implantation of XEN45 gel Stent and Preserflo microshunt using anterior segment optical coherence tomography

Quijada Angeli S¹, Pana I², Ausin Gonzalez E¹, Perucho L³, Jimeno Anaya L¹, Crespo Carballes M¹, Donate Lopez J³

¹Hospital Infanta Leonor de Vallecas, Madrid, Spain, ²Hospital Universitario Puerta de Hierro, Majadahonda, Spain, ³Hospital La Luz, Madrid, Spain

Introduction

The wide spread use of minimally-invasive glaucoma surgery (MIGS) devices has led to new findings and characteristics in the post-operative period of our patients, so we can develop new guidelines for improve the treatment as well as the use of devices like anterior segment Optical Coherence Tomography (AS-OCT).

Methods

Cross-sectional study of two cases of giant blebs after Preserflo® microshunt and XEN45® gel Stent implantation.

Results

Case 1: Male, 74 Y.O, OS, Mean height 1661µm, Highest point 2030µm, 1253µm. Bleb Extension 5´ clock-hours, the AS-OCT showed a mainly multi-cystic giant bleb, the patient was asymptomatic. Case 2: Female, 55 Y.O Female, OD, Mean height 1680 µm, Highest point 1900µm, at the tip of the implant 1225µm. Bleb Extension 7´ clock-hours. AS-OCT showed an uniform more shallowed but more extense giant bleb. Both patients showed a small limbic corneal ulcer due to friction against the blebs.

Conclusion

Despite being classified as MIGS is possible for they to develop giant blebs being more diffuse an cystic in the case of XEN45 implantation and more extensive and regular in Preserflo case.

Evaluation of peripapillary choroidal vascularity index in primary open-angle glaucoma patients

Quijada Angeli S¹, Pana I², Ausin Gonzalez E¹, Pastora Salvador N¹, Donate Lopez J³, Crespo Carballes M¹

¹Hospital Infanta Leonor de Vallecas, Madrid, Spain, ²Hospital Universitario Puerta de Hierro, Majadahonda, Spain, ³Hospital Clinico San Carlos, Madrid, Spain

Introduction

Peripapillary choroidal vascularity index (pCVI) is a novel optical coherence tomography (OCT) parameter that can be altered in patients with primary open-angle glaucoma (POAG).

Methods

Case-control study of ten POAG patients and ten healthy control age and gender matched. We evaluated images of OCT of the retinal nerve fiber layer through 3 circular concentric scans optic nerve head centered, using a spectral domain tomography scanner HRA2 (Spectralis, Heidelberg Engineering, Heidelberg, Germany).

We converted the choroidal images into a binary mask and measure the choroidal vascular area (CVA) and the total peripapillary choroidal area (TPCA). The pCVI was defined as the ratio between CVA/TPCA.

Results

pCVI was lower (0.38 ± 0.07) in patients with POAG compared to the control group (0.52 ± 0.14). *t*-Test Paired was performed, obtaining a statistical significance in 3.5mm ($p=0.007$), and 4.1mm ($p=0.0436$).

Conclusions

Patients with POAG showed a lower pCVI, in two of the concentric scans. Is reasonable to assume that choroidal alterations could be mediated by glaucoma, possibly through an ischemic effect. Despite these results, the evaluation of the peripapillary choroid may be influenced by POAG but also a sum of comorbidities

References

1. Iovino C, Pellegrini M, Bernabei F, Borrelli E, Sacconi R, Govetto A, et al. Choroidal Vascularity Index: An In-Depth Analysis of This Novel Optical Coherence Tomography Parameter. JCM. February 21, 2020;9(2):595.
2. Li F, Shang Q, Tang G, Zhang H, Yan X, Ma L, et al. Analysis of Peripapillary and Macular Choroidal Thickness in Eyes with Pseudoexfoliative Glaucoma and Fellow Eyes. Journal of Ophthalmology. June 8, 2020;2020:1-7.
3. Pablo LE, Bambo MP, Cameo B, Ferrández B, Güerri N, Polo V, et al. The use of zonal analysis of peripapillary choroidal thickness in primary open-angle glaucoma. Jpn J Ophthalmol. January, 2018;62(1):41-7.

Evaluation of long term outcome of glaucoma surgeries in Sturge Weber syndrome

Ramanatha Pillai M¹, Maheshwari D, Pawar N, Dodum Tara T, Rengappa R
1Aravind Eye Hospital, Tirunelveli, Tirunelveli, India

Aim

To study the outcome of surgical management in glaucoma associated with Sturge -Weber Syndrome

Method

Retrospective study. 7 patients with glaucoma associated with Sturge Weber syndrome were included in the study. All these patients had a minimum follow up of 5 years.

Results

All the 7 patients were females with a mean age at presentation of 14.61 years. Mean IOP during presentation was 24.57mmHg .3(42.9%) patients had undergone trabeculectomy with trabeculotomy augmented with MMC. Ahmed glaucoma valve was implanted in 2(28.6%) of these patients.2 patients underwent Trabeculectomy with MMC, among which 1 patient had AGV implantation and 1 patient underwent cataract surgery.Mean IOP in the trabeculectomy with trabeculotomy group was 25.5 mmHg and 20 mmHg in the AGV group. There was significant difference ($P<0.05$) between postsurgery IOP and baseline. The mean number of medications were 1.5 and 2.5 in the trabeculectomy with trabeculotomy and AGV group respectively at the end of 5 years.

Conclusion

Surgical treatment in patients with glaucoma associated with Sturge Webers Syndrome seems to maintain the intraocular pressure over a long term.

‘Eye MG 3D’ App/A 3D Glaucoma App with True Colour Confocal Images to Enhance Pedagogy & Counselling

Ramesh P¹

¹Mahathma Eye Hospital Private Limited, Trichy, India

Abstract

To make glaucoma concept learning & patient counselling better, we have innovated a totally 3D app (Eye MG 3D), depicting the ocular anatomy and pathophysiology, pertaining to glaucoma.^[1] Currently, most of the apps use (two-dimensional) 2D animated or (three-dimensional) 3D animated ophthalmic images. In this app, we have used real-time, high resolution, TrueColor, confocal images for constructing the eye models and have built it on an interactive 3D touch interface. Concepts of glaucoma have lots of theoretical framework; thus, students and patients may have to mentally visualise them. Only a powerful cognitive tool like a 3D atlas with real unanimated images, where users can choose their optimal frame, cross-section, and amount of zoom to visualise various parts of the eye, can fill in these mental theoretical gaps. Currently, this app is available free of cost for Android users from Google Play Store. For a bigger display, the windows version of the app is also available and it is provided free of cost. These applications simplifies glaucoma learning and aids in e-counselling, allowing users to not have any dark side of oculus uterque pertaining to glaucoma.

References

1. Eye MG 3D - Apps on Google Play. [cited 2021 Aug 31]. Available from: https://play.google.com/store/apps/details?id=com.EyeMG_3D&hl=en&gl=IN

Figures:

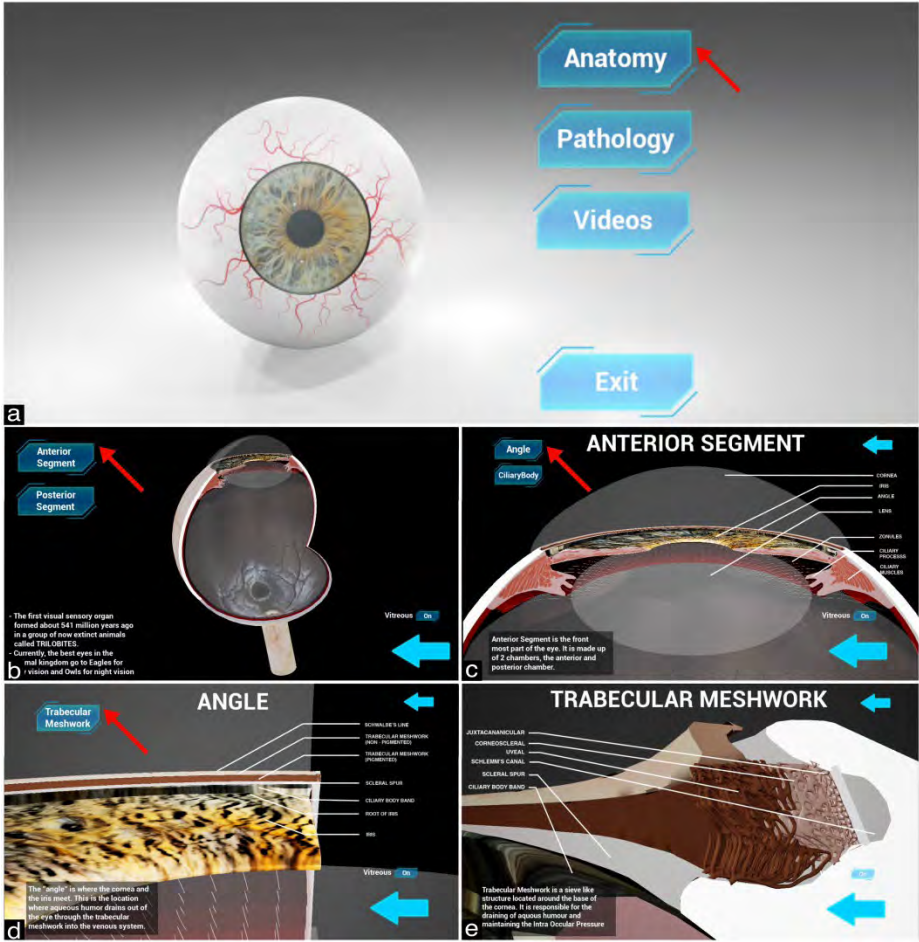
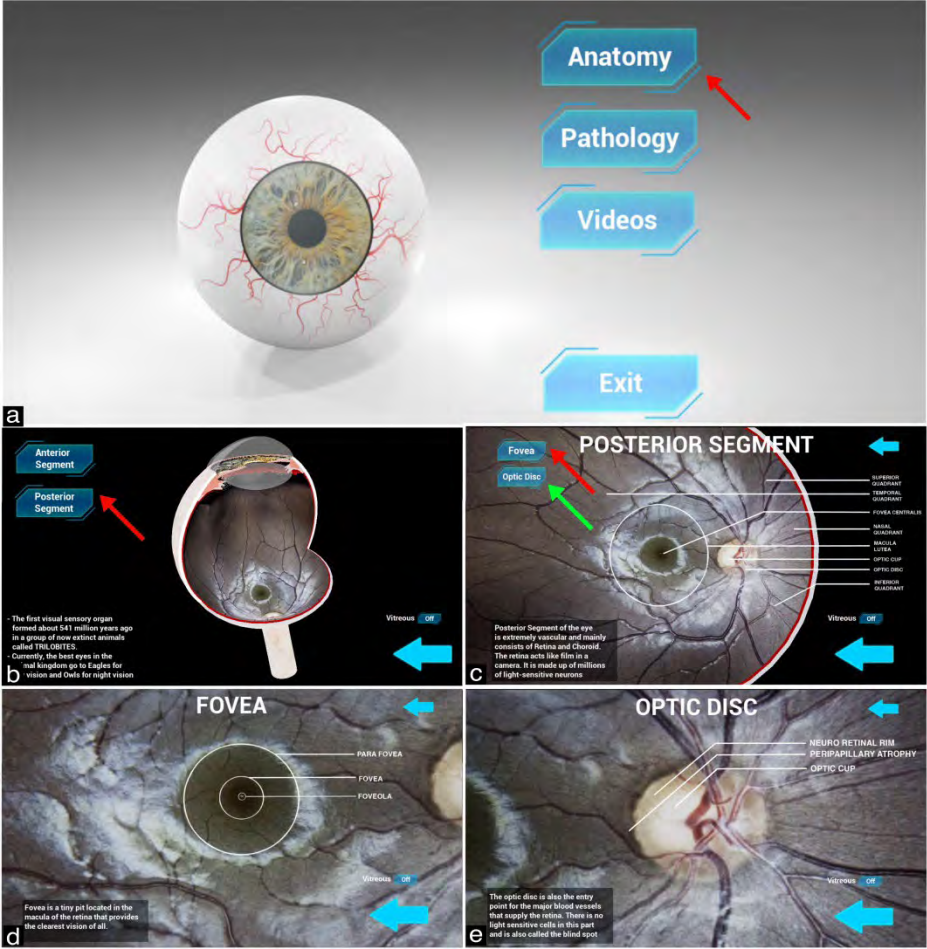


Figure 1: Image showing the 'Eye MG 3D' app being used for learning with our innovative 3D models.



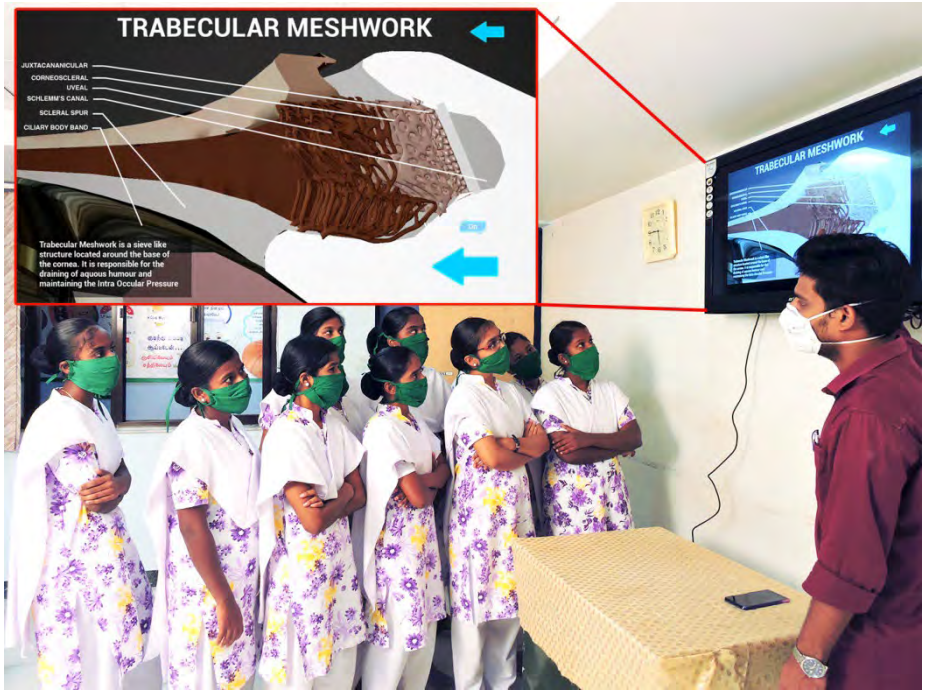


Figure 2&3: Image showing the utilisation of the ‘Eye MG 3D’ app for visualising anterior segment and posterior segment structures respectively.

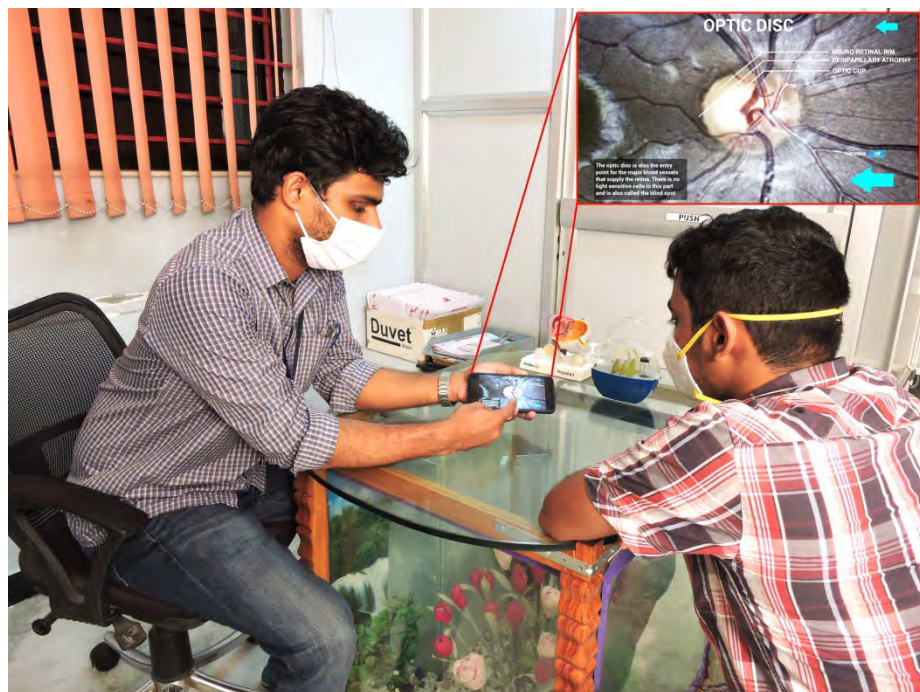

Figure 4: Image showing the 'Eye MG 3D' app being used for e-counseling.

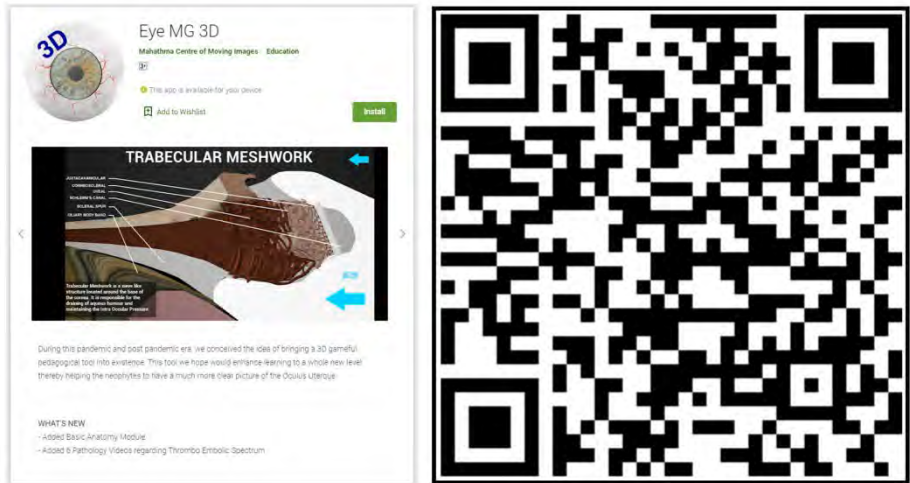


Figure 5: Image showing the ‘Eye MG 3D’ app available in Google Play Store and the QR code for downloading the app.

3D Printing Ophthalmology Related Models for Enhancing Glaucoma Anatomy Learning Through the Concept of Puzzle Assembly - A Comprehensive Self Learning Tactile Tool Kit

Ramesh P¹

¹Mahathma Eye Hospital Private Limited, Trichy, India

Purpose

Practical sessions facilitate teaching and critical thinking, especially among medical students, glaucoma residents and allied ophthalmic personnels. Currently, virtual and augmented reality are employed for surgical training, using three-dimensional (3D) eye models.[1]

Methods

These 3D models when printed, can be used not only for surgical training, but also for concept learning among neophytes, through tactile 3D puzzle assembly.

Results

3D printing is perfectly suited for creation of complex, bespoke items in a cost-effective manner, making it ideal for rapid prototyping. Puzzle making, when combined with 3D printing can evolve into a different level of learning. Though various 3D eye models are currently available, complex structures such as trabecular meshwork has never been printed, and presented as 3D puzzles. Also, the 3D models created by us have real-time high resolution TrueColor confocal images with all the glaucomatous fundus signs, aiding as atlas.

Conclusion

This concept of pedagogy has never been reported in the literature. In this paper, we have discussed on how to create these unique 3D models, and the economics involved in 3D printing them into multiple puzzle pieces for effective tactile learning.

References

1. Ramesh PV, Aji K, Joshua T, Ramesh SV, Ray P, Raj PM, et al. Immersive photoreal new-age innovative gameful pedagogy for e-ophthalmology with 3D augmented reality. Indian Journal of Ophthalmology. 2022;70(1):275–80.

Figures:

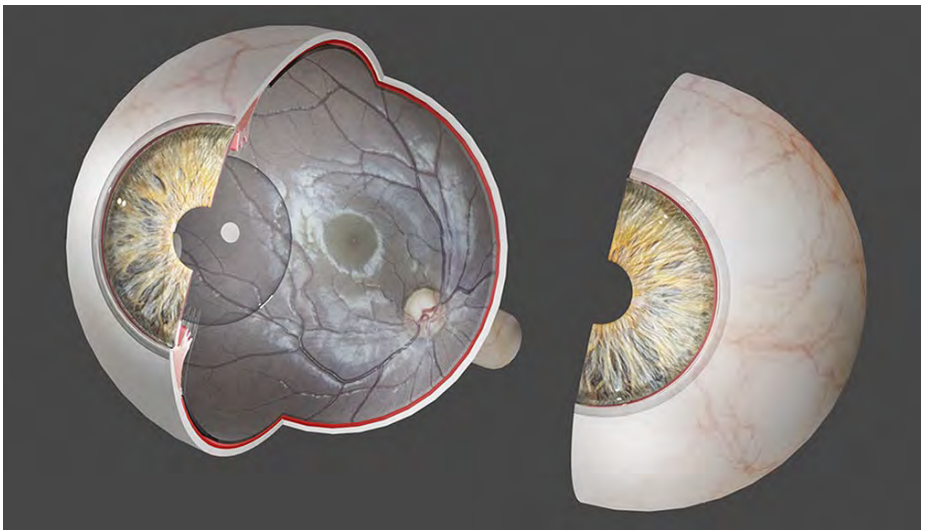


Figure 1: Image showing the 3D eyeball model with TrueColor high resolution confocal fundus image, which was created in the 3D computer graphics software.

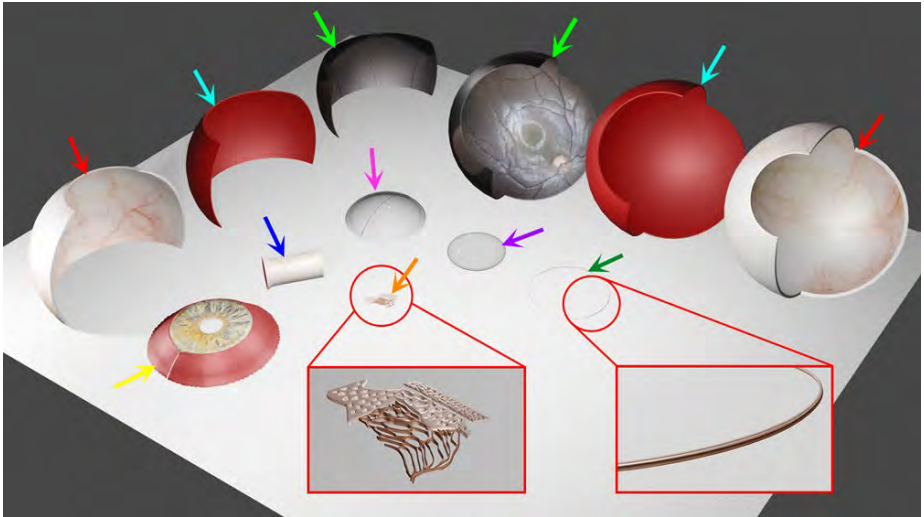


Figure 2: Image showing the eyeball model split into different parts: sclera (red arrows), choroid (light blue arrows), retina (light green arrows), iris & ciliary body (yellow arrow), optic nerve (dark blue arrow), cornea (rose arrow), lens (purple arrow), trabecular meshwork (orange arrow), anterior chamber angle (green arrow) for 3D puzzle printing.



Figure 3: Trabecular meshwork 3D models.

An Innovative Glaucoma Titled-Based Cricket Match for Screening and Promoting Awareness on Glaucoma

Ramesh P¹

¹Mahathma Eye Hospital Private Limited, Trichy, India

Purpose

A novel green cricket match was conducted to create glaucoma awareness among public at Trichy, India during World Glaucoma Week 2021, with players involving ophthalmologists. Goal of the match was to simultaneously educate and screen the public attending, with non-contact tonometry, confocal fundus scanner and portable virtual reality perimetry, and refer suspicious patients to base hospital.^[1]

Methods

Protocol of the match was designed with glaucomatous nomenclatures, such as 'Ocular Hypertensive Man of the Match, Compliant Economic Bowler, Visual Fielder, Trabeculectomy Wicket Taker, Pseudo-exfoliative Catch of the Match & Applanation Tonometry Batsman' to educate the public. A 12-point questionnaire-based survey was also conducted, to assess impact of the campaign in creating awareness.

Results

1,021 people visited the match and 253 people above the age of 40 were screened, out of which 24 (9.4%) were found to be suspicious and were referred to hospital. 17 out of 24 (70.8%) glaucoma suspects presented to the hospital, out of which 10 (41.6%) were confirmed to have glaucoma. A total of 327 people took up the 12-point questionnaire, out of which 201 (61.4%) people answered ten or more questions correctly.

Conclusion

Innovative approaches through cricket in India, where people have high affinity for IPL, will increase the awareness about glaucoma.

References

1. Ramesh PV, Ramesh SV, Ray P, Balamurugan A, Ramesh MK, Rajasekaran R. The green glaucoma cricket championship: An innovative glaucoma titled based cricket match initiative for screening and promoting awareness on glaucoma disease process and compliance. KJO.2021;33(1):104-6.

Figures



Figure 1: The two-contrasting green colour team jerseys.

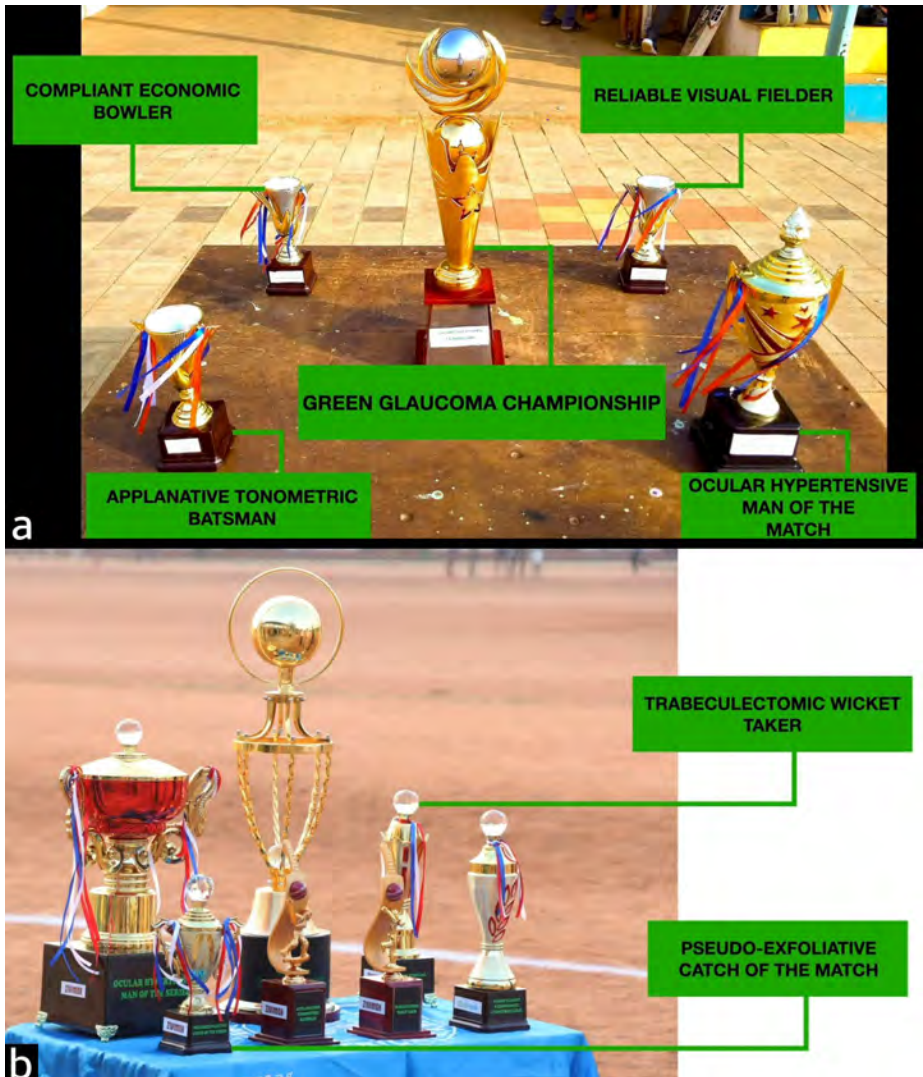

Figure 2: The various glaucoma named awards for extraordinary players.



Figure 3: Image showing (a) team open angle gladiators, and (b) team angle closure sixers.



Figure 4: Image showing the comprehensive glaucoma screening done for the public who gathered to witness the glaucoma awareness cricket mach.

Glaucoma Drainage Implantation in a Pregnant Woman with Axenfeld-Rieger Syndrome

Ramesh P¹

¹Mahathma Eye Hospital Private Limited, Trichy, India

Axenfeld-Rieger syndrome (ARS) is a rare disease characterised by anterior segment anomalies with or without glaucoma.^[1] A 28-year-old antenatal woman diagnosed with ARS presented with uncontrolled intraocular pressures (IOPs) and advanced glaucoma despite maximal medical therapy and progressive vision loss during her third trimester. The refractory and progressive nature of glaucoma with useful vision in one eye necessitated immediate surgical intervention. After obstetric consultation, Ahmed glaucoma drainage device (GDD) was implanted in OD under sub tenon's anesthesia with foetal monitoring in a facility, where obstetric emergency services were within reach, after weighing risks to both mother and child. Following the GDD implantation, there was successful control of the IOP, lasting till the final follow-up period of 18 months. In this paper, we discuss the role of glaucoma surgery, for ARS patients with refractory glaucoma, during the third trimester with a comprehensive review of the literature.^[2,3]

References

1. Shields MB. Axenfeld-Rieger syndrome. A theory of mechanism and distinctions from the iridocorneal endothelial syndrome. Trans Am Ophthalmol Soc. 1983;81:736–84
2. Dubey, S.; Sharma, V.; Agrawal, A.; Chauhan, A.; Douglas, G. Safety and efficacy of Ahmed Glaucoma Valve implantation in refractory glaucomas in Northern Indian eyes. Saudi J. Ophthalmol. 2015, 29, 103–108.
3. Radhakrishnan OK, Pahuja K, Patel K, et al. OLOGEN((R)) implant in the management of glaucoma in an unusual case of Axenfeld-Rieger syndrome. Oman J Ophthalmol 2014;7:90–2.

Figures

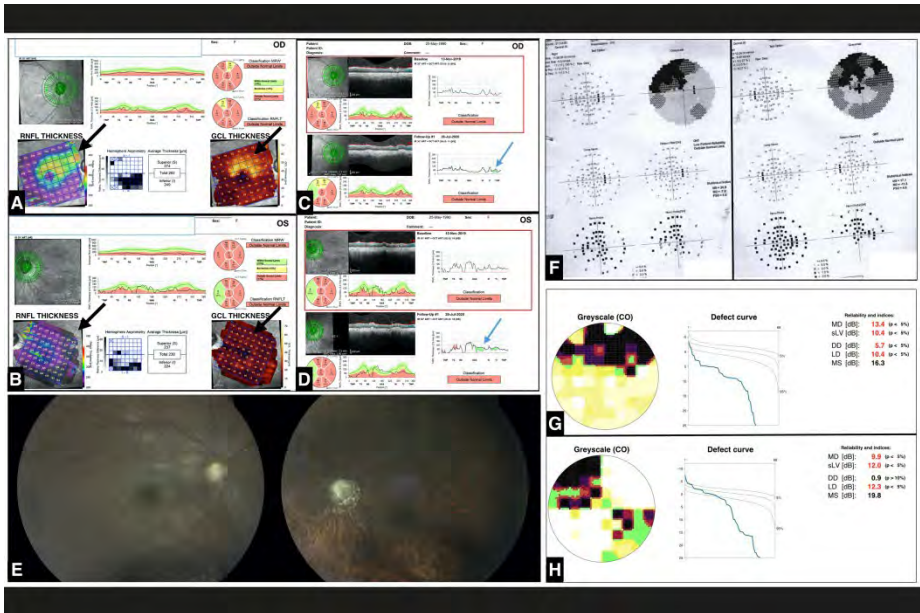


Figure 1: Image showing (A) Optical Coherence Tomography (OCT) optic nerve head (ONH) OD revealing preservation of the superior retinal nerve fibre layer and superior ganglion cell layer (black arrows). (B) OCT ONH OS revealing complete loss of the RNFL and GCL (black arrows). (C&D) Follow up OCT ONH of OD & OS, respectively. (E) Fundus Photograph was taken during the third trimester of pregnancy. (F) Visual fields done in 2018, revealing superior arcuate scotoma in OU when Axenfeld-Rieger syndrome was diagnosed. (G&H) Visual fields 10-2 in OD and OS, respectively.

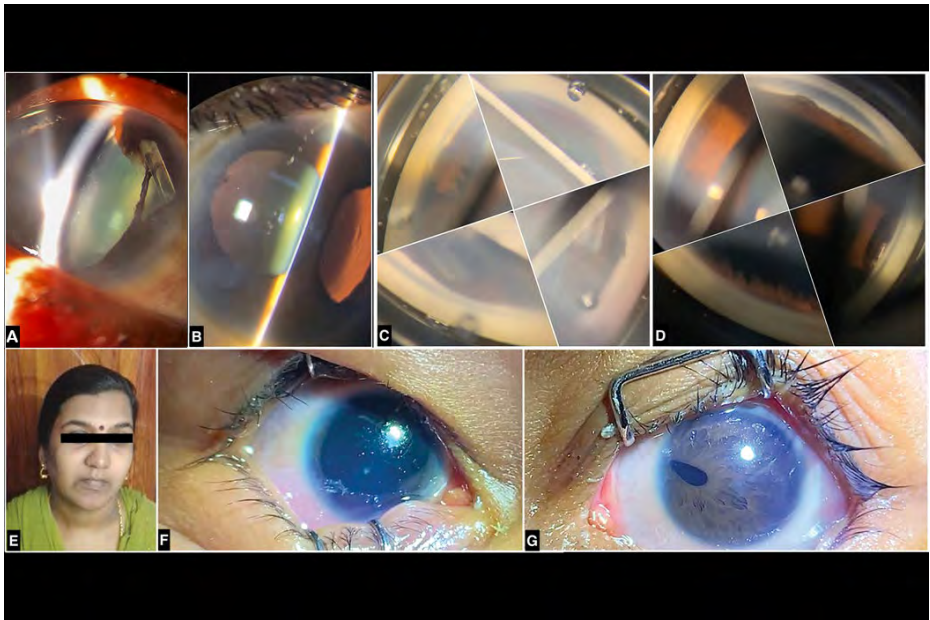


Figure 2: Image showing (A&B) Slit-lamp examination of OD and OS revealing features suggestive of Axenfeld-Rieger syndrome (ARS) taken post AGV implantation in OD. (C&D) Gonioscopy examination of OD & OS revealing angle dysgenesis (taken post AGV implantation in OD),respectively. (E) Facial dysmorphism features suggestive of ARS. (F) Family screening revealed ARS features for the newly born male in OD & OS respectively. The horizontal and vertical diameter of the cornea was 10 mm OU with an axial length of 16.96 mm in OD and 16.58 mm in OS. IOP by Perkins tonometer was 10 mmHg in OD & 12 mmHg in OS.

Follow-up	OD (Post Ahmed glaucoma	OS (Post Trabeculectomy
-----------	-------------------------	-------------------------

	valve implantation)	with Ologen)
1 week	17 mm Hg	12 mm Hg
2 weeks	15 mm Hg	22 mm Hg
1 month	17 mm Hg	18 mm Hg
3 months	16 mm Hg	15 mm Hg
6 months	15 mm Hg	13 mm Hg
12 months	13 mm Hg	14 mm Hg
18 months	14 mm Hg	13 mm Hg

Table 1. Follow up timeline for both eyes. Patient was put on brinzolamide and timolol in OD for tackling the hypertensive phase post AGV implantation. Patient was started on brinzolamide with timolol combination and bimatoprost in the OS at two weeks and one month respectively in the postpartum period to tackle bleb scarring related IOP rise.

Gonioscopy - Still A Silent Guardian, A Watchful Protector and A Dark Knight in Modern Day Practice

[Ramesh P¹](#)

¹Mahathma Eye Hospital Private Limited, Trichy, India

A 24-year-old male presented with defective vision in his left eye (OS) following phakic intraocular collamer lens (ICL) surgery in both eyes (OU) done elsewhere. On examination, OS had corneal edema with intraocular pressure (IOP) of 24 mm of Hg, despite maximum IOP lowering medications. He was diagnosed with secondary angle-closure glaucoma with pupillary block following ICL and was advised ICL explanation by them after the surgical peripheral iridectomy didn't work. However, on our examination with gonioscopy, he was re-diagnosed as secondary open-angle glaucoma with 360-degree dense pigment dispersion into the angles. Anterior segment optical coherence tomography (AS-OCT) supported the open-angle theory, revealing a deep anterior chamber and a patent peripheral iridectomy. Now, trabeculectomy seemed a better option than unilateral ICL explanation, as the patient had bilateral high myopia and ICL explanation may not recover the obstructed trabecular meshwork. The surgery was uneventful and the IOP decreased. The patient has been under good follow-up for 4 years now. The final follow-up revealed a best-corrected visual acuity (BCVA) of 20/20 with IOP in low teens in OU and a cosmetically happy patient. The pearl here is gonioscopy remains unparalleled in dictating the direction of glaucoma treatment.^[1-3]

References

1. Ye C, Patel CK, Momont AC, Liu Y. Advanced pigment dispersion glaucoma secondary to phakic intraocular collamer lens implant. American Journal of Ophthalmology Case Reports. 2018; 10:65–7.
2. Senthil S, Choudhari NS, Vaddavalli PK, Murthy S, Reddy J, Garudadri CS. Etiology and Management of Raised Intraocular Pressure following Posterior Chamber Phakic Intraocular Lens Implantation in Myopic Eyes. PLoS One. 2016;11(11): e0165469.

3. Badakere SV, Mandal AK. Glaucoma following phakic posterior chamber intraocular lens implantation. *Clinical and Experimental Optometry*. 2017;100(2):195–7.

Figures:




Figure 1: Slit-lamp photograph showing a well-placed intraocular collamer lens (ICL) with a patent opening in the centre of it, with a deep anterior chamber.

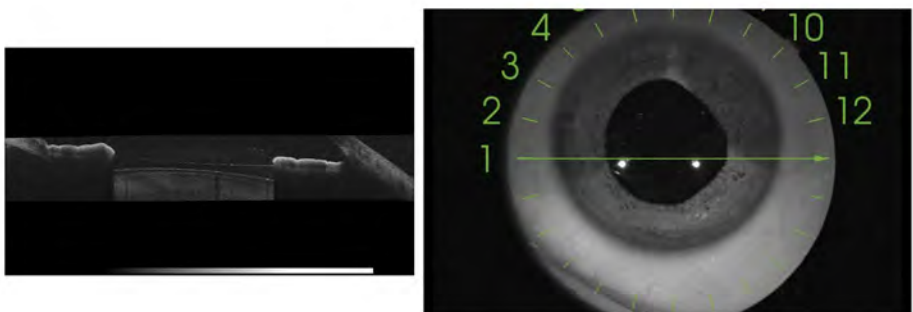


Figure 2: Anterior Segment Optical Coherence Tomography (AS-OCT) showing good vaulting of the ICL with the open angles.

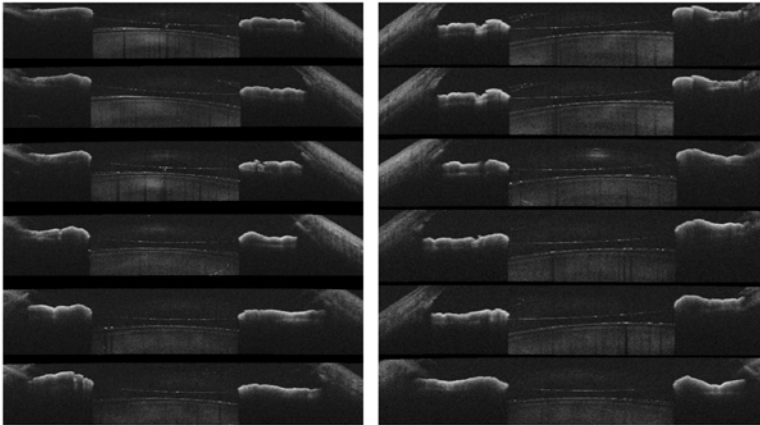


Figure 3: AS-OCT revealing the open angles of the anterior chamber in all the 12 o'clock hours.




Figure 4: Gonioscopic image revealing the heavily pigmented trabecular meshwork post ICL implantation surgery.

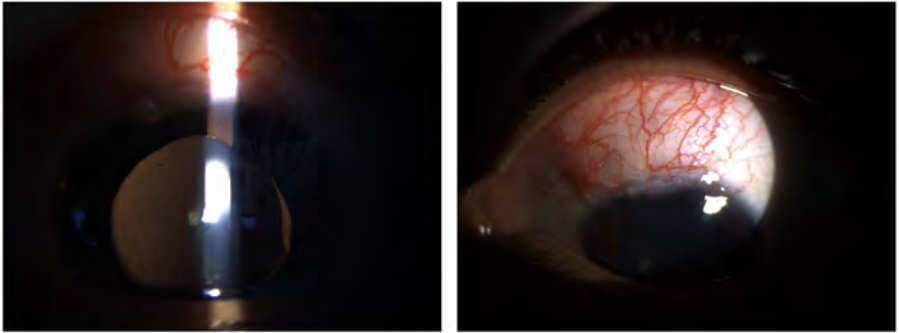


Figure 5: Slit-lamp image taken during the 1st week of follow-up post trabeculectomy with Ologen implantation surgery in the left eye (OS).




Figure 6: Gonioscopic image taken during the final follow up period of four years post-surgery, revealing a patent ostium.

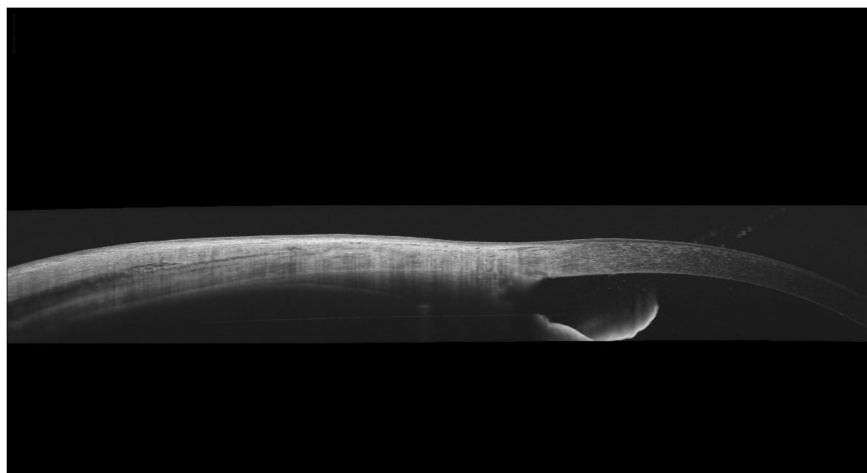


Figure 7: AS-OCT image taken during the final follow up period of four years post-surgery revealing a healthy bleb.

Holographic Elysium of A 3D Glaucoma Anatomical & Pathological Metaverse with Extended Reality/Mixed Reality

Ramesh P¹

¹Mahathma Eye Hospital Private Limited, Trichy, India

Purpose

Extended reality (XR) is one of the leading cutting-edge technologies, which has not yet fully set foot into the field of glaucoma.^[1,2] The use of extended reality technology especially in glaucoma education and counselling will revolutionize the face of teaching and counselling on a whole new level.

Methods

With reference from standard anatomic and ophthalmic textbook images, we have constructed the three-dimensional (3D) eye models in Computer-Aided Design softwares such as Autodesk Maya, Blender and Cinema 4D. These 3D models were then imported into HoloLens 2 (Microsoft, USA) for creating a successful XR experience.

Results

We have used this novel technology and have created a holographic museum of 3D eye ball models with trabecular meshwork and optic disc in fine detail.

Conclusion

These 3D ophthalmic holograms created by us, are constructed with TrueColor confocal images in a cost-effective manner to serve as a new-age immersive 3D pedagogical and counselling tool for gameful learning and counselling, respectively. According to our knowledge, this concept has not been reported in the literature before.

References

1. HoloLens 2. [cited 2022 Jan 14]. Available from: <https://medtrixhealthcare.com/holoLens-2blog-post>
2. Ramesh PV, Aji K, Joshua T, Ramesh SV, Ray P, Raj PM, et al. Immersive photoreal new-age innovative gameful pedagogy for e-ophthalmology with 3D augmented reality. Indian J Ophthalmol 2022;70(1):275-80.

Figures




Figure 1: The user is wearing the head-mounted HoloLens 2 device to experience the extended reality (XR) 3D holograms.

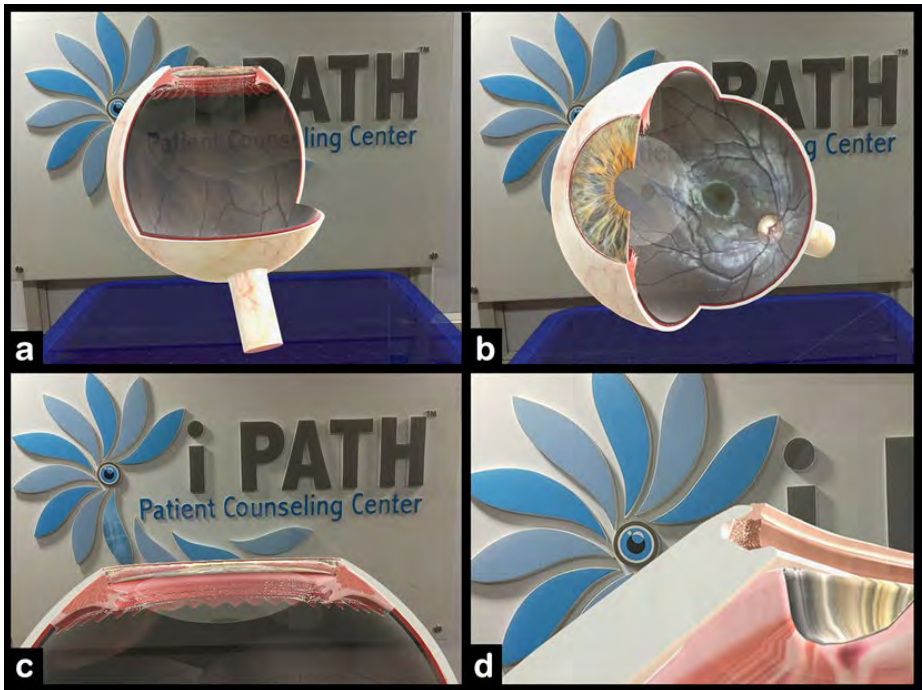


Figure 2: The image shows the 3D holograms of the normal anatomy of the eye in (a) cross sectional view, (b) anterior-posterior view, (c) gonioscopic view, and (d) electron microscopic view (for visualising the trabecular meshwork).

Amnionic membrane-umbilical cord (AM-UC) grafts reflecting new rays towards Glaucoma shunt surgery

Ray Bhadra T¹, Mitra A

¹Rio Medical College Kolkata, Kolkata, India

Objective

To determine the safety and efficacy of amnionic membrane-umbilical cord (AM-UC) graft in Glaucoma shunt surgery for reducing glaucoma shunt tube exposure.

Method

Hospital based prospective interventional study. 50 eyes of 50 patients with refractory glaucoma underwent glaucoma shunt surgery using Ahmed valve. Tubes are inserted in anterior chamber (n = 45), pars plana (n= 5). Tubes were covered with AM-UC patch grafts. AS- OCT were used to assess the patch graft stability and host tissue integration with a focus on tube exposure, graft thinning and graft-related complication.

Result

The average age was 50 +/- 5 years. The mean follow-up 24 +/- 3 month. Tube exposure occurred in 1 eye (2%) at 3 months. Sequential AS-OCT showed excellent host tissue integration. Early graft thinning <3 month occurred in 6 eyes (12%) and late thinning occurred in 2 eyes (4%). No evidence of graft rejection or infection was associated with AM -UC graft.

Conclusion

AM-UC grafts are well tolerated and its high-tensile strength, low immunogenicity and excellent host- tissue integration offer good tectonic support in glaucoma shunt surgery.

Prospective evaluation of wipe out after glaucoma filtration surgery in eyes with split fixation

Ray Bhadra T¹, Mitra A¹

¹Rio Medical College Kolkata, Kolkata, India

Introduction

“Wipe-out” phenomenon is defined as idiopathic and irreversible loss of central vision in eyes with advanced glaucoma after filtration surgery.^[1,2] The aim of our study was to assess the incidence and cause of wipe-out” in the early postoperative period after glaucoma-filtration surgery in advanced glaucoma.

Methods

Prospective, interventional cohort study. 30 patients (30 eyes) with advanced glaucoma and macular split fixation underwent either only trabeculectomy (group A) or combined phacoemulsification with trabeculectomy (group B). Incidence and cause of visual loss, changes in intraocular pressure (IOP), visual acuity and visual field indices during 2 months post-surgery were assessed.

Results

No significant difference was seen between the preoperative and postoperative mean deviation (MD) in both groups A and B ($p=0.41$, $p=0.65$) (Figure 1). 2 eyes in group A and one eye in group B had visual loss of 2 lines or more at the end of 2 months due to cataract and choroidal detachment. None of the eyes showed “wipe-out”.

Conclusion

“Wipe-out” is a rare phenomenon after surgery in advanced glaucoma. Filtration surgery in advanced glaucoma should not be withheld for fear of wipe out in cases where medical management cannot sufficiently control the IOP.

References

1. Costa VP, Smith M, Spaeth GL et al. Loss of visual acuity after trabeculectomy. *Ophthalmology* 1993;100:599–612.
2. Moster MR, Moster ML. Wipe-out: a complication of glaucoma surgery or just a blast from the past? *Am J Ophthalmol.* 2005 Oct;140(4):705-6.

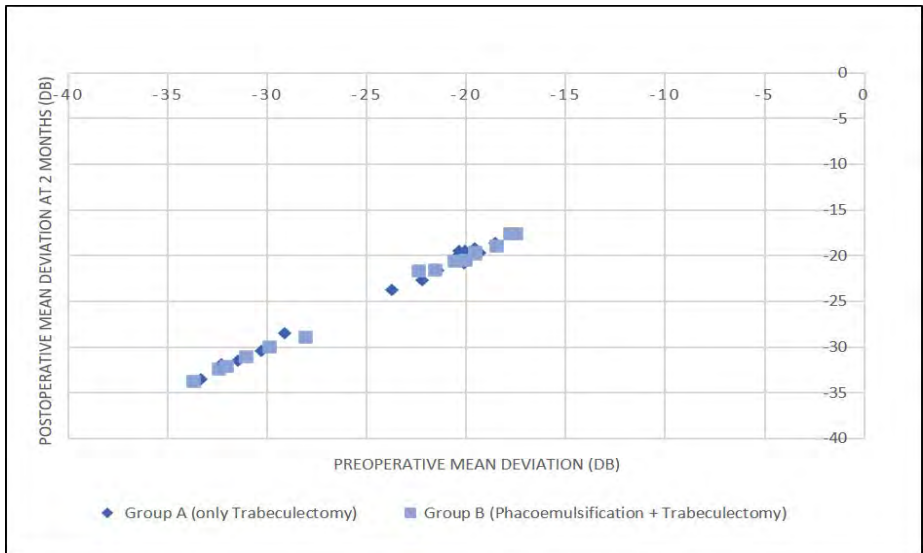


Figure 1: Scatter Plot comparing preoperative mean deviation with postoperative mean deviation measured after 2 months in Group A and Group B

The effect of intravitreal mesenchymal stem cells combined with BDNF and NGF on retinal ganglion cells density and Caspase-3 expression in rat model of glaucoma

Razief Fitri M¹, Artini W¹, Liem I², Siregar N³

¹Department of Ophthalmology, Faculty of Medicine, Universitas Indonesia, Jakarta, Indonesia, ²Department of Anatomy, Faculty of Medicine, Universitas Indonesia, Jakarta, Indonesia, ³Department of Anatomical Pathology, Faculty of Medicine, Universitas Indonesia, Jakarta, Indonesia

Introduction

Progressive damage of retinal ganglion cells (RGCs) occurs despite the controlled intraocular pressure (IOP) in glaucoma. Neurotrophic action and growth factor deprivation have been reported to cause RGCs apoptosis in glaucoma through Caspase-3 activation. Mesenchymal stem cells (MSCs) has paracrine effect because it contains brain-derived neurotrophic factor (BDNF) and nerve growth factor (NGF) to stimulate neuroprotection and neuroregeneration. We aim to evaluate the RGCs in glaucoma model following intravitreal injection of MSCs combined with BDNF and NGF.

Methods

Sixteen Wistar rats were divided into four groups. Elevation of IOP was done to three intervention groups. Intravitreal injection of placebo (second group), MSCs (third group), and MSCs combined with BDNF-NGF (fourth group) were performed on day-5. The IOP were monitored closely. Caspase-3 expression and RGCs density were evaluated following enucleation.

Results

Retinal ganglion cells density in the glaucoma group was lower than control group ($p < 0.001$). Higher RGCs density was found within the MSCs with and without BDNF-NGF groups compared to glaucoma group ($p < 0.001$). There was no difference in

Caspase-3 expression between groups ($p=0.395$).

Conclusion

Mesenchymal stem cells, with and without BDNF-NGF combination increase retinal ganglion cell density but do not appear to reduce Caspase-3 expression in rat model of glaucoma.

References

1. Davis BM, Crawley L, Pahlitzsch M, Javaid F, Cordeiro MF. Glaucoma: the retina and beyond. *Acta Neuropathol.* 2016;132:807–26.
2. Mead B, Scheven BA. Mesenchymal stem cell therapy for retinal ganglion cell neuroprotection and axon regeneration. *Neural Regen Res.* 2015;10:371–3.

Lens subluxation in painful blind eye: to extract or not to extract?

[Rifqi K¹](#), Komaratih E¹

¹Department of Ophthalmology, Faculty of Medicine Universitas Airlangga, Surabaya, Indonesia

Introduction

Neovascular glaucoma has a very high rate of severe visual loss with final visual acuity of no light perception. In this case report, we discussed the dilemma whether to perform intraocular surgery in a painful No Light Perception (NLP) eye caused by lens subluxation.

Methods

A 56 years old male patient came with a complaint of ocular pain for the past 4 weeks. The pain was followed by redness and watery eyes. He had a history of diabetic retinopathy and chronic kidney disease. He had a visual acuity of NLP since 2 years ago in his RE and two meters counting finger in his LE. RE initial IOP was 43.4 mmHg with shallow anterior chamber depth, hyphema, rubeosis iridis and inferonasal lens subluxation. Gonioscopy also showed a closed angle with Grade 1 Shaffer in all RE quadrants. From USG examination of the RE showed an impression of tractional retinal detachment and LE vitreous haemorrhage. He was diagnosed with RE absolute glaucoma, RE neovascular glaucoma, RE hyphema, RE lens subluxation, RLE PDR, and LE vitreous haemorrhage.

Results

Intraocular surgery like lens extraction is inappropriate to be done in NLP eyes. The contralateral eye is also vulnerable to have a potential sympathetic ophthalmia (SO). Should a complication occur, a blind eye may become painful which can cause a more thorough follow-up care. In the absence of possible visual benefit, these risks may outweigh benefit of intraocular surgery.

Conclusion

The decision whether or not to perform intraocular surgery on an NLP eye ultimately hinges in each ophthalmologist's subjective clinical judgement. As we no longer hope for visual improvement, the decision made was to do cyclocryotherapy to relieve the pain so that the patient might have a better quality of life.

References

1. Havens S, Gulati JV. Neovascular glaucoma Introduction. *Dev Ophthalmol*. 2016;55:196–204.
2. Susanna R, De Moraes CG, Cioffi GA, Ritch R. Why Do People (Still) Go Blind from Glaucoma? *Transl Vis Sci Technol*. 2015;4(2):1.
3. Rodrigues GB, Abe RY, Zangalli C, Sodre SL, Donini FA, Costa DC, et al. Neovascular glaucoma: A review. *Int J Retina Vitre*. 2016;2(1):1–10.
4. Liu L, Xu Y, Huang Z, Wang X. Intravitreal ranibizumab injection combined trabeculectomy versus Ahmed valve surgery in the treatment of neovascular glaucoma: assessment of efficacy and complications. *BMC Ophthalmol*. 2016 Dec;16(1):65.
5. Anderson RL, Caplan A, Schuman JS. Ethical Considerations for Performing Intraocular Surgery on Eyes with No Light Perception. *Ophthalmology*. 2019 Jan;126(1):10–2.
6. Aung T, Crowston J. Asia Pacific Glaucoma Guidelines. 3rd edition. NSW, Australia: Kugler Publications BV / Amsterdam; 2016.
7. Tanna, A.P., Boland, M. V., Giaconi, J.A., Krishnan, C., Lin, S.C., Medeiros, F.A., Moroi, S.E. and Sit A. Glaucoma Basic and Clinical Science Course. 2020th–2021st edn. San Francisco: American Academy of Ophthalmology. In 2021. p. 2013–5.

Tables, figures, and illustrations

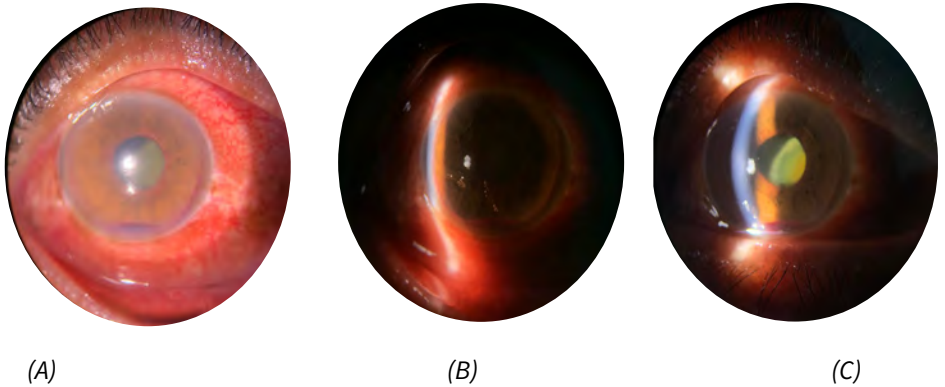


Figure 1: Right Eye's anterior segment (A) diffuse beam showed CVI, hyphema, rubeosis iridis and inferonasal lens subluxation. **(B)** Shallow anterior chamber depth Von Herrick grade I. **(C)** Definite RE inferonasal lens subluxation.

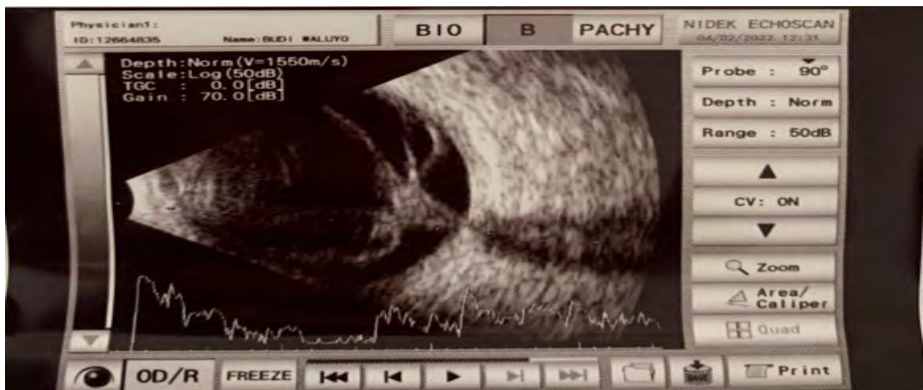

Figure 2: Right eye's USG examination

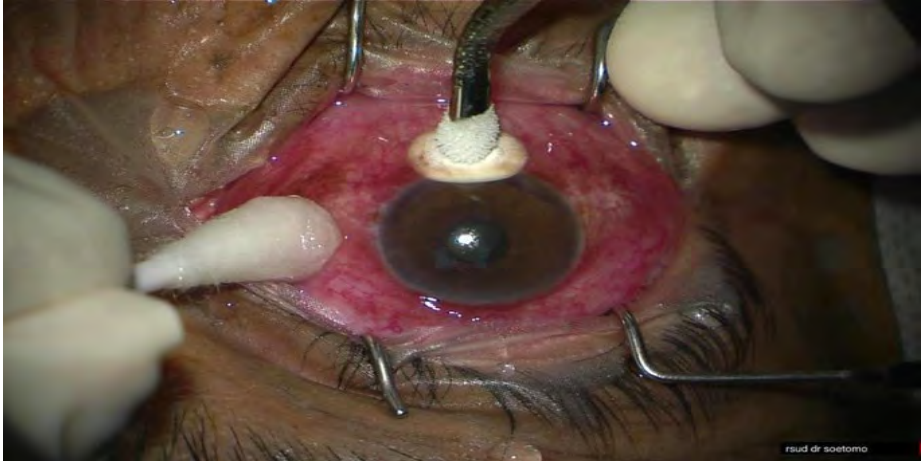


Figure 3: Right eye's cyclocryotherapy

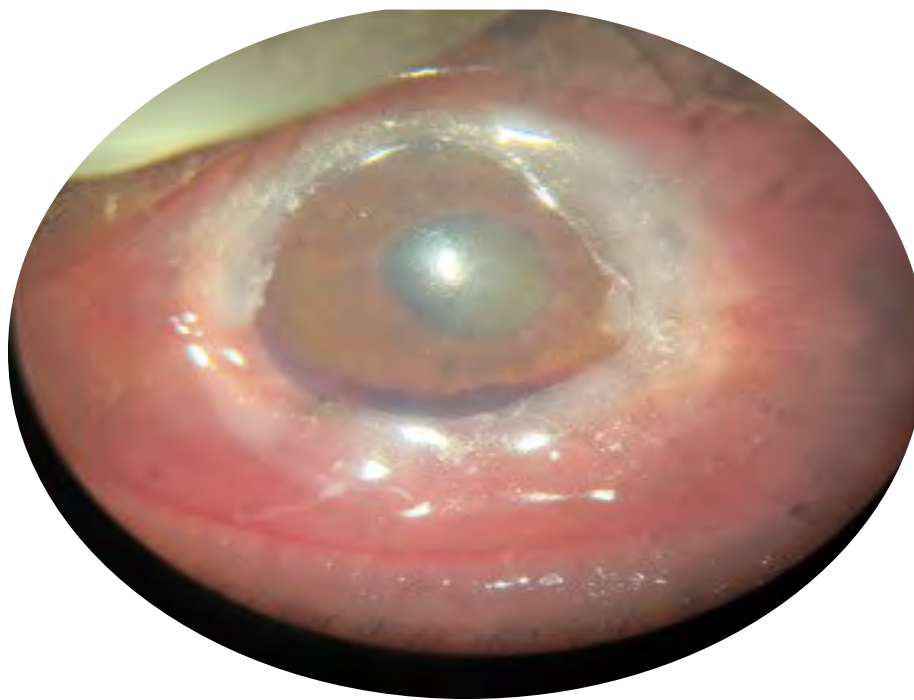

Figure 4: Right eye's condition one day post cyclocryotherapy

Demographic and clinical characteristics of glaucoma patients in a referral hospital in Yogyakarta

Rizkah L¹, Ekantini R¹, Gani T¹, Jati K¹

¹Department of Ophthalmology, Faculty Of Medicine, Public Health And Nursing, Universitas Gadjah Mada – Dr. Sardjito General Hospital, Indonesia, Sleman, Indonesia

Introduction

Glaucoma poses a significant public health concern as a lifelong chronic disease, which has a major impact on a patient's quality of life. This study aimed to describe the characteristics of patients presenting with glaucoma in Dr. Sardjito General Hospital Yogyakarta.

Methods

The medical records of patients presenting to Dr. Sardjito General Hospital Yogyakarta from January to December 2021 with diagnosis of glaucoma were retrospectively reviewed. Data regarding age, gender, residence, subtypes of glaucoma, laterality, intraocular pressure (IOP), cup-to-disc ratio (CDR), medical and surgical treatment, and visual acuity were recorded.

Results

This study comprised 573 glaucoma patients, the mean age was 47 ± 19.14 years old, with primary open-angle glaucoma (POAG) being the most common subtypes presented (44%). Female sex was more common at 60%. Sixty two percent patients were originated from Yogyakarta, 28% were from Central Java, and 10% from outside Yogyakarta and Central Java. The mean IOP of all glaucoma patients was 16.0 ± 8.31 mmHg, and the mean CDR was 0.65 ± 0.17 . Of all patients, 17% received both medication and surgical intervention while 83% received medication only. Trabeculectomy was the most common surgeries performed (83%). Furthermore, the mean refractive errors of all eyes was -0.76 ± 2.16 dioptries (D),

with 66% of eyes had good visual acuity (6/12 or better), 16% had moderate visual acuity (6/15 to 6/50), and 18% had poor visual acuity (count fingers to no light perception).

Conclusion

The most common subtypes of glaucoma presented was POAG. A high proportion of glaucoma patients were originated from Yogyakarta. Trabeculectomy was the most common surgeries performed.

References

1. Allison K, Patel D, Alabi O. Epidemiology of Glaucoma: The Past, Present, and Predictions for the Future. Cureus. 2020 Nov 24;12(11):e11686. doi: 10.7759/cureus.11686. PMID: 33391921; PMCID: PMC7769798.

Tables, figures, and illustrations

Table 1
Demographic data of study patients

Variable	Study Patients
Age (years)	
Mean±SD	47±19.14
Subtype of Glaucoma, number of patients (% of total)	
POAG	253 (44)
PACG	72 (13)
JOAG	42 (7)
SOAG	36 (6)
SACG	12 (2)

NTG	151 (26)
Ocular Hypertension	7 (1)
Gender, number of patients (% of total)	
Male	228 (40)
Female	345 (60)
Residence, number of patients (% of total)	
Yogyakarta	355 (62)
Central Java	158 (28)
Others	60 (10)
Total Patients	573 (100)

Note: POAG, primary open-angle glaucoma; PACG, primary angle-closure glaucoma; JOAG, juvenile open-angle glaucoma; SOAG, secondary open-angle glaucoma; SACG, secondary angle-closure glaucoma; NTG, normal tension glaucoma.

Table 2
Clinical Characteristics of glaucoma in study patients

	Average IOP (mmHg), mean±SD		Average mean±SD		CDR, number of patients (%)	Treatment Modality, number of patients
	OD	OS	OD	OS	Medicati on Only	Medicati on + Surgery
Diagnosis						
POAG	16.5±7.7 4	16.5±8.3 0	0.7±0.1 9	0.7±0.1 7	206 (81)	47 (19)
PACG	19.0±14. 18	17.9±11. 05	0.7±0.2 3	0.7±0.1 9	51 (71)	21 (29)
JOAG	15.6±4.7	16.9±7.4	0.6±0.1	0.6±0.1	37 (88)	5 (12)

	3	7	6	6		
	18.6±9.1	18.8±9.2	0.6±0.2	0.5±0.2		
SOAG	5	7	1	2	25 (96)	11 (4)
	19.9±19.	17.9±13.	0.6±0.2	0.5±0.2		
SACG	18	98	7	3	2 (17)	10 (83)
	13.0±3.3	13.0±3.6	0.6±0.1	0.6±0.1		
NTG	7	0	2	1	146 (97)	5 (3)
Ocular Hypertension	17.3±3.8	17.9±3.1	0.5±0.1	0.5±0.0	7 (100)	0 (0)
	6	3	1	8		
Gender						
	15.9±7.9	15.4±7.5	0.7±0.1	0.7±0.1		
Male	7	7	7	7	182 (80)	46 (20)
	16.1±8.8	16.1±8.8	0.6±0.1	0.6±0.1		
Female	9	9	8	8	292 (85)	53 (15)
Residence						
Yogyakarta	16.4±9.1	15.9±9.1	0.6±0.1	0.6±0.1		
	1	1	8	6	294 (83)	61 (17)
Central Java	15.7±8.2	16.0±8.2	0.7±0.1	0.7±0.1		
	3	6	8	8	131 (83)	27 (17)
	14.9±4.9	16.0±7.6	0.7±0.1	0.7±0.1		
Others	7	5	9	7	49 (82)	11 (18)
	16.0±8.5	16.0±8.0	0.7±0.1	0.7±0.1		
Total Patients	2	9	8	7	474 (83)	99 (17)

Note: IOP, intraocular pressure; CDR, cup-to-disc ratio.

Table 3

Laterality of affected eyes

Subtype of glaucoma	Unilateral, number of patients (%)	Bilateral, number of patients (%)
POAG	21 (8)	90 (19)

PACG	26 (8)	26 (22)
JOAG	0 (0)	9 (11)
SOAG	18 (50)	5 (9)
SACG	1 (8)	5 (22)
NTG	0 (0)	36 (12)
Ocular Hypertension	0 (0)	1 (7)
Total Patients	66 (12)	507 (88)

Table 4

Ocular surgeries performed and subtype of glaucoma in the study patients

Subtype of Glaucoma	Trabeculectomy, number of eyes (%)	Cyclocryotherapy, number of eyes (%)	GDD Implant, number of eyes (%)	Iridectomy, number of eyes (%)	LPI, number of eyes (%)	Phacoemulsification, number of eyes (%)
POAG	44 (94)	2 (4)	1 (2)	0 (0)	0 (0)	0 (0)
PACG	26 (85)	2 (6)	0 (0)	0 (0)	2 (6)	1 (3)
JOAG	5 (100)	0 (0)	0 (0)	0 (0)	0 (0)	0 (0)
SOAG	11 (100)	0 (0)	0 (0)	0 (0)	0 (0)	0 (0)
SACG	6 (38)	0 (0)	0 (0)	1 (6)	0 (0)	9 (56)
NTG	2 (67)	1 (33)	0 (0)	0 (0)	0 (0)	0 (0)
Ocular Hypertension	0 (0)	0 (0)	0 (0)	0 (0)	0 (0)	0 (0)
Total Eyes	94 (83)	5 (4)	1 (1)	1 (1)	2 (2)	10 (9)

Note: GDD, glaucoma drainage device; LPI, laser peripheral iridotomy.

Table 5

Best-corrected visual acuity, refractive error, and subtype of glaucoma in the study patients

Subtype of glaucoma	6/12 or better, number of eyes (%)	6/15-6/60, number of eyes (%)	CF-NLP, number of eyes (%)	SEQ (D), mean \pm SD
POAG	303 (63)	90 (19)	89 (18)	-0.65 \pm 2.27
PACG	42 (36)	26 (22)	48 (41)	0.03 \pm 0.95
JOAG	71 (84)	9 (11)	4 (5)	-1.46 \pm 1.91
SOAG	29 (55)	5 (9)	19 (36)	-0.75 \pm 2.11
SACG	5 (22)	5 (22)	13 (57)	-0.36 \pm 1.14
NTG	243 (80)	36 (12)	23 (8)	-1.08 \pm 2.38
Ocular Hypertension	13 (93)	1 (7)	0 (0)	-0.73 \pm 1.10
Total Eyes	706 (66)	172 (16)	196 (18)	-0.76 \pm 2.16

Note: CF, count fingers; NLP, no light perception; SEQ, spherical equivalent refraction; D, dioptres.

Ischemia Modified Albumin (IMA) as a New Biomarker in Glaucoma

Rusmayani E¹, Wiyogo W¹, Suhardjo S², Sasongko M²

¹JEC, Jakarta, Indonesia, ²Gadjah Mada University Indonesia, Yogyakarta, Indonesia

Introduction

Glaucoma is an optic neuropathy disease, which is multifactorial with chronic progressivity if left untreated leads to permanent visual loss. Early diagnosis is imperative to monitor progression so adequate treatment could be given⁽¹⁾. A novel biomarker diagnostic for progression detection and preventing blindness as the nature course of the disease is needed⁽²⁾. Ischemia modified albumin (IMA) was recently suggested to be a pathologic marker for ischemic diseases. Data regarding IMA as a sensitive biomarker in ophthalmology is still limited⁽³⁾⁽⁴⁾⁽⁵⁾. In this research, we aim to compare IMA levels in serum and aqueous humour, as well as correlation to retinal nerve fiber layer (RNFL) thinning.

Methods

Patients with primary glaucoma undergoing cataract surgery or glaucoma surgery were recruited. Total of 74 subjects with 33 patients as control and 41 patients with glaucoma (n=20 PACG, n=21 POAG). Intraocular pressure was measured before surgery using Goldmann applanation tonometry. IMA was quantified in serum preoperatively and aqueous humour taken intraoperatively.

Results

Correlations of IMA in aqueous humor to RNFL thinning was found significant in all glaucoma patients ($p=0.05$; $r=0.299$), PACG ($p=0.04$; $r=0.402$), and POAG ($p=0.03$; $r=0.485$). However, we found no significant correlation of IMA levels in serum to RNFL in all glaucoma patients ($p=0.273$ $r=0.173$), PACG ($p=0.247$; $r=-0.271$), and POAG ($p=0.204$; $r=-0.289$).

Conclusion

Oxidative stress induced by ischemia process was found to initiate trabecular mitochondrial damage in glaucoma⁽⁷⁾⁽⁸⁾. Our study shows that IMA levels in aqueous humour were found significantly correlated with RNFL thinning in glaucoma. IMA has a potential role as a novel local ischemic biomarker in glaucoma patients. Therefore, our findings might support antioxidant therapy as a potential new target treatment⁽⁵⁾⁽⁹⁾.

References

1. Kokotas H, Kroupis C, Chiras D, Grigoriadou M, Lamnissou K, Petersen MB, et al. Biomarkers in primary open angle glaucoma. *Clin Chem Lab Med CCLM*. 2012 Dec 1;50(12):2107–19.
2. Bhattacharya SK, Lee RK, Grus FH, the Seventh ARVO/Pfizer Ophthalmics Research Institute Conference Working Group. Molecular Biomarkers in Glaucoma. *Invest Ophthalmol Vis Sci*. 2013 Jan 7;54(1):121–31.
3. Hazini A, Cemek M, Işıldak İ, Alpdağtaş S, Önül A, Şenel Ü, et al. Investigation of ischemia modified albumin, oxidant and antioxidant markers in acute myocardial infarction. *Postepy W Kardiologii Interwencyjnej Adv Interv Cardiol*. 2015;11(4):298–303.
4. Gulpamuk B, Tekin K, Sonmez K, Inanc M, Neselioglu S, Erel O, et al. The significance of thiol/disulfide homeostasis and ischemia-modified albumin levels to assess the oxidative stress in patients with different stages of diabetes mellitus. *Scand J Clin Lab Invest*. 2018 Feb 17;78(1–2):136–42.
5. Karakurt Y, Mertoglu C, Gok G, Ucak T, Tasli N, Icel E, et al. Thiol-Disulfide Homeostasis and Serum Ischemia Modified Albumin Levels in Patients with Primary Open-Angle Glaucoma. *Curr Eye Res*. 2019 Aug;44(8):896–900.
6. Yu M, Lin C, Weinreb RN, Lai G, Chiu V, Leung CK-S. Risk of Visual Field Progression in Glaucoma Patients with Progressive Retinal Nerve Fiber Layer Thinning: A 5-Year Prospective Study. *Ophthalmology*. 2016 Jun 1;123(6):1201–10.

7. Izzotti A, Longobardi M, Cartiglia C, Saccà SC. Mitochondrial Damage in the Trabecular Meshwork Occurs Only in Primary Open-Angle Glaucoma and in Pseudoexfoliative Glaucoma. PLoS ONE. 2011 Jan 20;6(1):e14567.
8. Li G, Luna C, Liton PB, Navarro I, Epstein DL, Gonzalez P. Sustained stress response after oxidative stress in trabecular meshwork cells. Mol Vis. 2007 Dec 17;13:2282–8.
9. Kimura A, Namekata K, Guo X, Noro T, Harada C, Harada T. Targeting Oxidative Stress for Treatment of Glaucoma and Optic Neuritis. Oxid Med Cell Longev. 2017;2017:2817252.

Phacotrabeculectomy in management of glaucoma

Rusmayani E¹, Wiyogo W¹

¹Jakarta Eye Center, Jakarta , Indonesia

Introduction

Cataract and glaucoma are globally the most common causes of blindness, and they frequently coexist⁽¹⁾⁽²⁾⁽³⁾. Elevated intraocular pressure (IOP) is the only modifiable risk factor for the progression of visual field loss in patients with glaucoma⁽⁴⁾⁽⁵⁾⁽⁶⁾. Many patients with existing cataract and glaucoma, who cannot achieve target IOP require combine phacotrabeculectomy. This study was conducted to evaluate the outcome of phacotrabeculectomy⁽⁷⁾⁽⁸⁾⁽⁹⁾⁽¹⁰⁾.

Methods

This retrospective descriptive study was done in Jakarta Eye Center. Patients diagnosed with primary glaucoma undergoing combined phacotrabeculectomy during January 2016 to December 2021 were included with follow up time was minimum 1 year. Evaluation of visual acuity, intraocular pressure, number of glaucoma medication, additional surgery, and complications related to surgery were analyzed.

Results

Mean IOP was significantly lower in POAG (15.65 ± 5.31 ; $P=0.05$) and PACG (13.44 ± 2.70 ; $P=0.109$) at one year follow up. The number of glaucoma medications were significantly reduced in both groups. The PACG group revealed a complete and qualified success of 46% and 54% respectively. Similarly, POAG group showed a complete and qualified success of 21% and 66% respectively with 13% of failure in 1 year follow up. Visual acuity outcomes postoperative are increased ($r=0.178$ $p=0.385$) in PACG and significantly increase in POAG ($r=0.625$ $p=0.00$) at one year follow up. Additional surgery in the PACG group were found in 1 patient (3.8%) and in POAG group was 9 patients (17%).

Conclusion

Combined phacotrabeculectomy offers many advantages in managing glaucoma with coexistence cataract. Quick visual recovery and long-term control of IOP, and reduction of post-operative IOP spike especially for cases with advanced optic neuropathy. Also patients convenience with less visit to operating theatre, reduction of cost, and risks of anesthesia.

References

1. Kingman S. Glaucoma is second leading cause of blindness globally. *Bull World Health Organ.* 2004 Nov;82(11):887–8.
2. Foran S, Wang JJ, Mitchell P. Causes of visual impairment in two older population cross-sections: the Blue Mountains Eye Study. *Ophthalmic Epidemiol.* 2003 Oct;10(4):215–25.
3. Wu S-Y, Hennis A, Nemesure B, Leske MC, Barbados Eye Studies Group. Impact of glaucoma, lens opacities, and cataract surgery on visual functioning and related quality of life: the Barbados Eye Studies. *Invest Ophthalmol Vis Sci.* 2008 Apr;49(4):1333–8.
4. Coleman AL, Miglior S. Risk Factors for Glaucoma Onset and Progression. *Surv Ophthalmol.* 2008 Nov 1;53(6, Supplement):S3–10.
5. Stein JD, Khawaja AP, Weizer JS. Glaucoma in Adults—Screening, Diagnosis, and Management: A Review. *JAMA.* 2021 Jan 12;325(2):164–74.
6. Shalaby WS, Ahmed OM, Waisbourd M, Katz LJ. A review of potential novel glaucoma therapeutic options independent of intraocular pressure. *Surv Ophthalmol [Internet].* 2021 Dec 8 [cited 2022 Feb 26]; Available from: <https://www.sciencedirect.com/science/article/pii/S003962572100223X>
7. Melancia D, Pinto LA, Marques-Neves C. Cataract Surgery and Intraocular Pressure. *Ophthalmic Res.* 2015;53(3):141–8.
8. Poon LY-C, Lai I-C, Lee J-J, Tsai J-C, Lin P-W, Teng M-C. Comparison of surgical outcomes after phacotrabeculectomy in primary angle-closure glaucoma versus primary open-angle glaucoma. *Taiwan J Ophthalmol.* 2015 Mar 1;5(1):28–32.

9. L Jung J, Isida-Llerandi CG, Lazcano-Gomez G, SooHoo JR, Kahook MY. Intraocular Pressure Control after Trabeculectomy, Phacotrabeculectomy and Phacoemulsification in a Hispanic Population. *J Curr Glaucoma Pract.* 2014 Aug;8(2):67–74.
10. Sacchi M, Monsellato G, Villani E, Lizzio RAU, Cremonesi E, Luccarelli S, et al. Intraocular pressure control after combined phacotrabeculectomy versus trabeculectomy alone. *Eur J Ophthalmol.* 2022 Jan 1;32(1):327–35.

“Untangling the fibers”: A rare case of bilateral iridoschisis in a Filipino adult male

San Juan M¹, Covar R¹

¹Department of Ophthalmology and Visual Sciences, Sentro Oftalmologico Jose Rizal, Philippine General Hospital, Ermita, Philippines

Introduction

Iridoschisis is a rare condition that consists of the separation of the anterior mesodermic layer of the iris. Only about 150 cases of iridoschisis have been reported to this date ¹. The anterior stromal fibers of the iris split from the posterior stromal fibers, and then float in the anterior chamber ². Several theories have been presented with regards to the pathogenesis of iridoschisis- vascular, degenerative, genetic, pharmacologic and traumatic ^{3,4,5}. Due to its low incidence and minimal case populations, the exact underlying mechanism is yet to be explained.

Case Discussion

A case of a 54-year-old Filipino male presenting with a 2-year history of progressive blurring of vision. There is no predisposing trauma, pharmacologic exposure and inheritance patterns noted.

On ocular examination, Patients visual acuity was 20/200 OU not improved on pinhole. Slit lamp microscopy reveals Shallowed anterior chambers with apparent separation of between the anterior and posterior layers of the iris presenting as loose fibers obscuring the central visual axis bilaterally. (Figure 1) Ultrasound biomicroscopy confirms the diagnosis of Iridoschisis with secondary angle closure OU. (Figure 2 & 3) The patient underwent phacoemulsification with mechanical pupillary dilation intraoperatively as per recommended treatment standards ⁶. Postoperatively our patient shows no structural signs of glaucoma deficits on diagnostic testing, commonly associated with iridoschisis

Conclusion

Iridoschisis as a rare disease may be prone to misdiagnosis especially with dark colored iris such in Asian populations. The case presented shows none of the known predisposing factors for iridoschisis are present with the case and rather he presents with a sporadic presentation of the disease (Table 1). The etiology of iridoschisis remains obscure nonetheless our case shows that a constellation of findings even in the absence of identifiable etiologies can and does allow for appropriate diagnosis of iridoschisis and subsequent adequate management.

References

1. Gogaki, E., Tsolaki, F., Tiganita, GOGAKI, E., & Balatoukas. (2011). Iridoschisis: Case Report and Review of the Literature. *Clinical Ophthalmology*, 381. Doi:10.2147/Oph.S17269 (<https://doi.org/10.2147/Oph.S17269>)
2. Loewenstein, A., & Foster, J. (1945). Iridoschisis With Multiple Rupture Of Stromal Threads. *British Journal of Ophthalmology*, 29(6), 277–282. Doi:10.1136/Bjo.29.6.277
3. Mansour, A. M. (1986). A Family With Iridoschisis, Narrow Anterior Chamber Angle, And Presenile Cataract. *Ophthalmic Paediatrics And Genetics*, 7(3), 145–149. Doi:10.3109/13816818609004131 (<https://doi.org/10.3109/13816818609004131>)
4. Piekarczyk, B., Grochowski, E. T., Saeed, E., Sidorczuk, P., Mariak, Z., & Dmuchowska, D. A. (2020). Iridoschisis—a Systematic Review. *Journal Of Clinical Medicine*, 9(10), 3324. Doi:10.3390/Jcm9103324 (<https://doi.org/10.3390/Jcm9103324>)
5. Danias, J., Aslanides, I. M., Eichenbaum, J. W., Silverman, R. H., Reinstein, D. Z., & Coleman, D. J. (1996). Iridoschisis: High Frequency Ultrasound Imaging. Evidence For A Genetic Defect? *British Journal Of Ophthalmology*, 80(12), 1063–1067. Doi:10.1136/Bjo.80.12.1063 (<https://doi.org/10.1136/Bjo.80.12.1063>)

6. Payne, T. D., & Thomas, R. P. (1966). Iridoschisis. *American Journal Of Ophthalmology*, 62(5), 966–967. Doi:10.1016/0002-9394(66)91927-1 ([https://doi.org/10.1016/0002-9394\(66\)91927-1](https://doi.org/10.1016/0002-9394(66)91927-1))
7. Romano, A., Treister, G., Barishak, R., & Stein, R. (1972). Iridoschisis And Angle-closure Glaucoma. *Ophthalmologica*, 164(3), 199–207. Doi:10.1159/000306752 (<https://doi.org/10.1159/000306752>)
8. Snyder, M. E., Malyugin, B., & Marek, S. L. (2019). Novel approaches to phacoemulsification in iridoschisis. *Canadian Journal of Ophthalmology*, 54(5), e221–e225. doi:10.1016/j.jcjo.2019.01.009
9. Lee, E. J., Lee, J. H., Hyon, J. Y., Kim, M. K., & Wee, W. R. (2008). A Case of Cataract Surgery without Pupillary Device in the Eye with Iridoschisis. *Korean Journal of Ophthalmology*, 22(1), 58. doi:10.3341/kjo.2008.22.1.58
10. Eiferman, R. A., Law, M., & Lane, L. (1994). Iridoschisis and Keratoconus. *Cornea*, 13(1), 78–79. doi:10.1097/00003226-199401000-00013

Figures and Tables

Figure 1. Preoperative Slit lamp microscopy of Left and Right iridoschisis

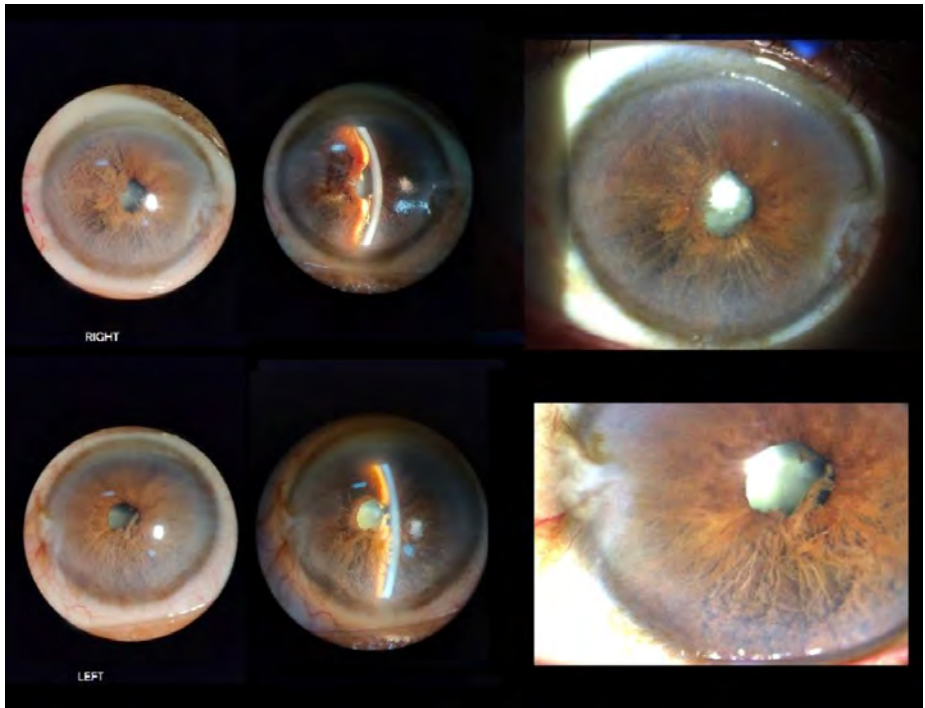
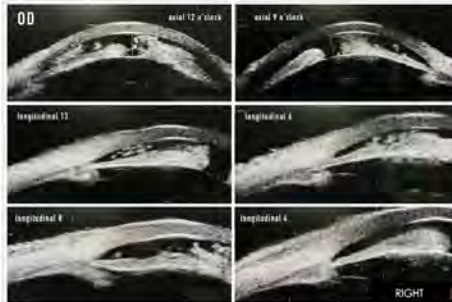

Figure 2. Ultrasound Biomicroscopy Right

Ultrasound Biomicroscopy - Right



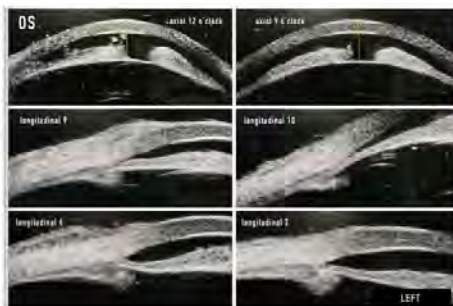On axial scans there is note of slightly hyperechoic cornea centrally with central corneal thickness of 0.61 - 0.62 mm. The central anterior chamber depth measures 1.32 - 1.33 mm. The iris plane is convex. There is cleavage of the iris stroma centrally and peripherally, with some iris fibrils touching the corneal endothelium. The lens appears cataractous.

On longitudinal scans there is note of thin peripheral iris thickness, moderate iris convexity superiorly and inferiorly, mild iris convexity nasally and temporally, basal iris insertion, absent peripheral iris insertion angulation, medium ciliary body size, and anterior ciliary body position.

There is note of synechial angle closure at the 12th, 10th, 9th, 8th, and 6th clock hours, as evidenced by iridotrabecular contact with blunting of the angles. There is note of open angles at the 3rd and 4th clock hours. The zonules are visible and intact in all clock hours

Figure 3. Ultrasound Biomicroscopy Left

Ultrasound Biomicroscopy - Left



On axial scans there is note of slight hyperechoic cornea centrally with central corneal thickness of 0.59 - 0.64 mm. The central anterior chamber depth measures 1.37 - 1.40 mm. The iris plane is convex. There is some cleavage of the iris stroma centrally and peripherally, with some iris fibrils touching the corneal endothelium. The lens appears cataractous.

On longitudinal scans there is note of thin peripheral iris thickness, mild iris convexity, basal iris insertion, absent peripheral iris angulation, medium ciliary body size, anterior ciliary body angulation nasally, and neutral ciliary body angulation elsewhere.

There is note of iridotrabecular contact at the 12th, 10th, 9th, 8th, and 6th clock hours, with no blunting of the angles. There is blunting of the angles at the 4th clock hours. The 2nd clock hour is open. The zonules are visible and intact in all clock hours.

Table 1. Prevailing theories of mechanism of management of iridoschisis

Vascular

Iridoschisis: A clinical and histopathologic study
EC, Albers, BA Klien BA

Fluoroidiographic aspects of Iridoschisis
A Carnevalini

Degenerative

Iridoschisis With Multiple Rupture Of Stromal Threads
A Loewenstein, J Foster

Iridoschisis: Essential Iris atrophy
Bajeri J

Genetic

Iridoschisis: HFU Imaging. Evidence for a genetic defect?
J. Daniels,

Iridoschisis—A Systematic Review
B. Plekharz, E.Grochowski,

Pharmacologic

Iridoschisis : A Case Report
T. Payne, R. Thomas

Traumatic

A Further Case Of Iridoschisis.
J. Foster, S. Sledge

The Use of Oxygen Therapy for the Treatment of Corneal Degenerations in Glaucoma Patients

Sas O, Shargorodska I

¹Shupyk National Healthcare University of Ukraine, Kyiv, Ukraine

Introduction

Degenerative-dystrophic changes of the cornea accompanies patients with glaucoma. Today a hot issue of ophthalmology is the search for new treatment options, one of which is oxygen therapy.

Methods

We observed 20 patients (40 eyes) with neurotrophic keratitis (glaucoma). For research, we used a device allowing to obtain a new level of quality of liquid gas saturation. Different aspects of the therapy were studied: duration, density, concentration, etc. Clinical-laboratory and instrumental methods of examination of glaucoma patients with degenerative diseases of the eye cornea were used in this study.

Results

For the first time, the role of components of the system of oxidative and mixidative stress in the development of degenerative-dystrophic diseases of the cornea has been established. New scientific knowledge on the importance of components of oxidative and mixidative stress in the mechanisms of vascular damage in corneal degeneration and the dependence of the detected disorders on the content of superoxide radical, hydroxyl radical, diene conjugates and malonic dialdehyde, which can open new possibilities in prevention and treatment of this pathology, was obtained.

Conclusion

The search for and research of new treatment options for patients with degenerative-dystrophic corneal diseases is relevant, as untimely and ineffective treatment can have significant implications for individual and public health.

References

1. Bostanci Ceran B, Ozates S. Ocular manifestations of coronavirus disease 2019. *Graefes Arch Clin Exp Ophthalmol*. 2020;258(9):1959-63. <https://doi.org/10.1007/s00417-020-04777-7/>
2. Shimazaki J, Goto E, Ono M, Shimmura S, Tsubota K. Meibomian gland dysfunction in patients with Sjogren syndrome. *Ophthalmology*. 1998;105(8):1485-8. [https://doi.org/10.1016/S0161-6420\(98\)98033-2/](https://doi.org/10.1016/S0161-6420(98)98033-2/)
3. E. I. Sidorenko and E. E. Kenarskaya, *Vestn. Oftalmol.*, **120**, No. 3, 16-19 (2004).

Intravitreal Ganciclovir in a toddler with CMV Retinitis

[S.Gaytry](#)¹, Goh Siew Yuen¹, Norhafizah Hamzah¹

¹Department of Ophthalmology Hospital Tunku Azizah

Purpose

To report a rare case of CMV retinitis in a toddler

Method

Case Report

Results

A Malay boy presented at day 14 of life with prolonged jaundice and was noted to have isolated thrombocytopenia. Further history revealed strong family history of Wiskott Aldrich Syndrome (WAS). Patient undergone TCR Alpha Beta Depleted Haploidentical Transplantation on 29 June 2021. Blood screening cytomegalovirus DNA revealed titre of 2362 IU/ml post transplantation. The patient was started on intravenous ganciclovir 40mg (5mg/kg) EOD. Patient was referred to Paediatric ophthalmology on day 125 post- transplant for chalazion. Patient vision with Cardiff 1m 6/60 OD and 6/76 OS. Fundi examination revealed bilateral retinitis with retinal haemorrhages and exudates involving Zone 1 which was suggestive of cytomegalovirus retinitis. Patient was planned for biweekly intravitreal ganciclovir injection to both eyes. Bilateral eye aqueous and vitreous tap was done and sample was sent for CMV DNA PCR, intravitreal Ganciclovir 2mg/0.04ml was given under aseptic technique to both eyes. At this time patient was on intravenous ganciclovir 45mg BD. The right eye intravitreal fluid CMV titre was 11.69 million IU/ml and the left eye 13.01 million IU/ml. After the seventh intravitreal Ganciclovir injection, patient developed respiratory distress following platelet transfusion. He was intubated and was treated for pneumonia. The decision was made by the ophthalmology team to reduce the intravitreal injection to once a week. Patient had received a total of 10 intravitreal ganciclovir injections to both eyes. On his last

review in the clinic there was resolving retinal lesions and improvement of his visual acuity of 6/24 OD and 6/76 OS.

Conclusion

To report a rare case of CMV retinitis in an immunocompromised toddler that was successfully treated with intravitreal and systemic Ganciclovir.

Corneal blood staining: Does intraocular pressure matter?

Sethi S¹

¹Arunodaya Deseret Eye Hospital, Gurugram, India

Introduction

Corneal blood staining occurs in the presence of hyphema and high intraocular pressure. These cases usually get referred to Glaucoma specialists for control of IOP. It can mimic appearance of crystalline lens in the anterior chamber making it a diagnostic challenge clinically. The relevance of ocular imaging has to be emphasized at this point. We report a rare case of corneal blood staining in the presence of low intraocular pressure where ultrasound imaging helped clinch the diagnosis and guide the management.

Method

A 10year old boy presented to the emergency department of Arunodaya Deseret Eye Hospital following blunt trauma to the left eye with a cricket ball injury. He was referred to the glaucoma department for further management. Detailed history and ocular examination was done including visual acuity, intraocular pressure, slit lamp examination. Ultrasound B scan was done as the view to the posterior segment was not possible. Written consent was sought from the patient and anterior segment and patient photographs were obtained.

Results

The initial suspected diagnosis of dislocated crystalline lens in the anterior chamber was made. The differential diagnosis of corneal blood staining was initially precluded due to absence of high intraocular pressure. This diagnosis was quickly revised after performing ultrasound B scan which suggested posterior and downward dislocation of the lens. There was no retinal detachment or choroidal effusion. Thus, we discovered a rare case of corneal blood staining in the presence of hypotony. Since this patient had poor visual prognosis due to probable traumatic optic neuropathy, conservative management was sought.

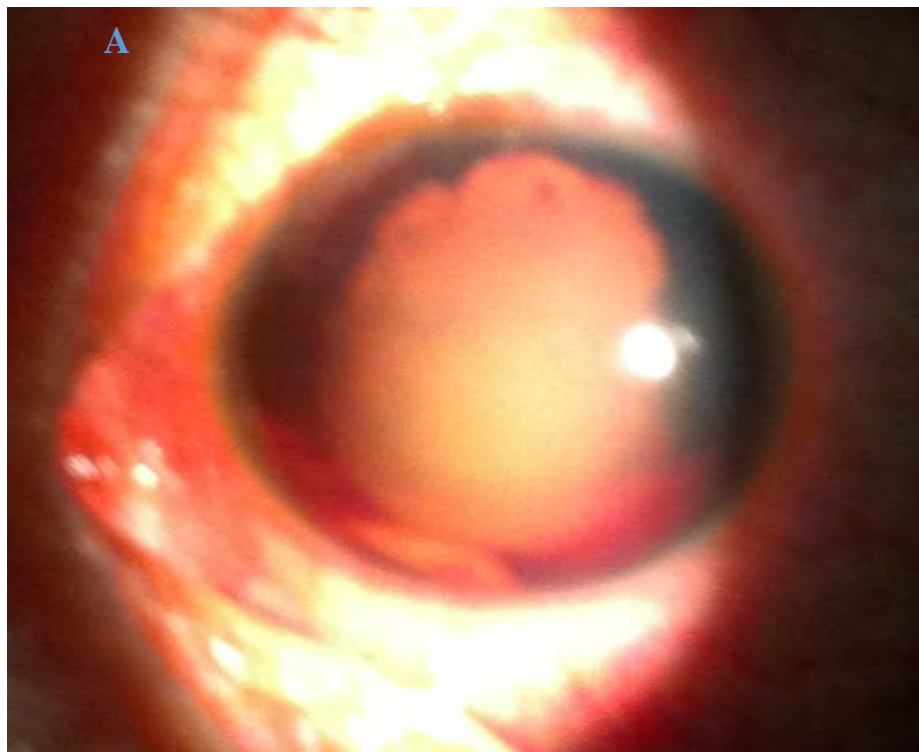
Conclusion

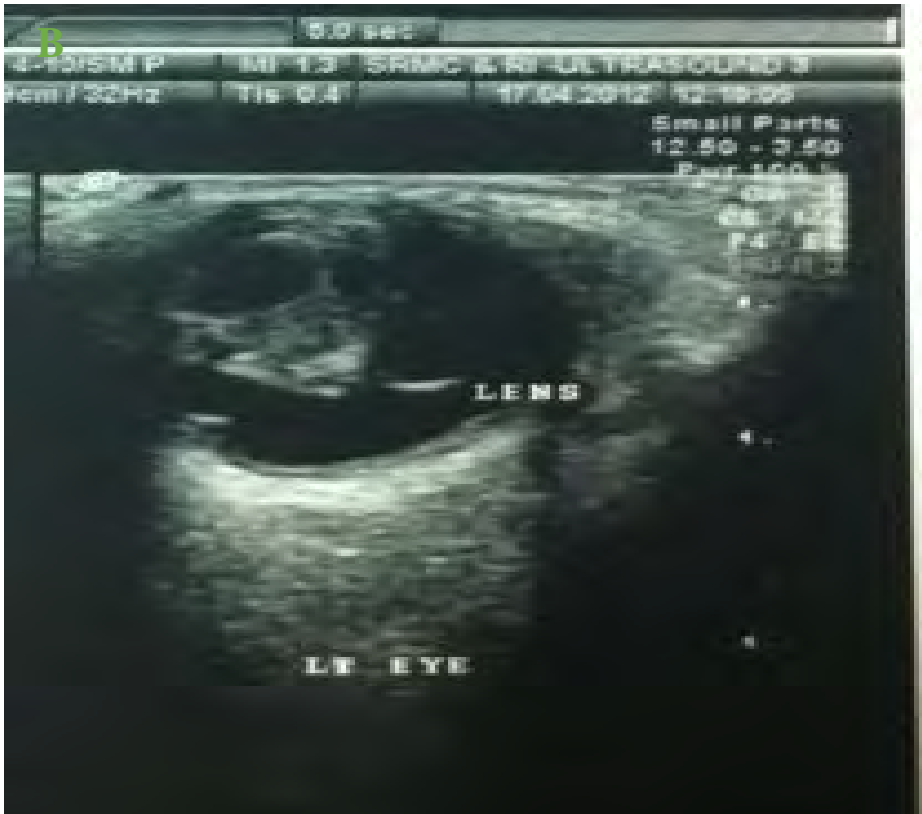Corneal blood staining is a diagnosis glaucoma specialists have to bear in mind even in the absence of high IOP, an entity reported scarcely in the past literature¹. Ocular imaging like ultrasound B scan, AS-OCT and/or UBM become mandatory to clinch the diagnosis and guide management. Newer management modalities will be discussed.

References

1. Beyer TL, Hirst LW. Corneal blood staining at low pressures. Arch Ophthalmol. 1985 May;103(5):654-5. doi: 10.1001/archopht.1985.01050050046014. PMID: 3994574.

Figures





A: slit lamp image of blood stained cornea; B: ultrasound B scan showing infero-posterior dislocation of lens

Understanding barriers to glaucoma treatment initiation and adherence in the capital region of India.

Sethi S¹, Sethi A¹

¹Arunodaya Deseret Eye Hospital, Gurugram, India

Introduction

In India, more than 75% of glaucoma is undiagnosed, which perhaps represent the submerged portion of the iceberg phenomenon of the traditional disease explanations. Data on glaucoma treatment barriers in North India is limited. Improved knowledge of barriers could improve disease awareness and self-management. We aimed to understand glaucoma treatment barriers in the capital of India.

Methods

Glaucoma patients ≥ 40 years taking ≥ 1 medication at two tertiary eye care centres in Delhi, NCR namely, Arunodaya Deseret Eye Hospital and Dr Sethi Eye centre were screened with a validated medication adherence tool. Consent was sought from all patients. The responses were statistically analysed.

Results

61/102 (62%) had poor self-reported adherence to drops. 55 (90%) were non-adherent to medication and 32 (53%) were late for follow-up. Top barriers to medication adherence were difficulty obtaining drops, idea that drops are not helping, intolerance/allergies to medication, being busy, affordability, and difficulty in understanding multiple medication schedules. Top barriers to appointment follow-up were distance to the hospital, expense, being busy, hot weather and no escort. Other important barriers included mistrust in the health system, poor knowledge of glaucoma and family needs.

Conclusions

Previously, 50% of glaucoma patients in North India self-reported poor medication adherence; the 62% identified in this study is in line with glaucoma medication adherence rates globally and more than what has been realised in India before. Multitudes of factors caused high rates of non-adherence. It prompts more intensive societal-level interventions that address these barriers including thorough counselling, increasing awareness in society and among relatives of patients, motive patients and family members. It is clear that interventions to improve medication adherence must address each patient's unique set of barriers.

Utility and sensitivity of water drinking test in screening for glaucoma in high risk patients.

Sethi S¹, Sethi A¹

¹Arunodaya Deseret Eye Hospital, Gurugram, India

Introduction

The importance of lowering IOP at the pre-perimetric stage in patients with multiple risk factors is well established. Progression rate can be as high as 57% noted over 5 years in untreated patients¹. An exaggerated water drinking test (WDT) response indicates compromised outflow facility and the peak IOPs are aggregable with diurnal variation test². Hence, we study the need, utility and sensitivity of WDT subject to patients with normal IOP but at high risk of developing glaucoma treatment can be instituted in time. According to the study, WDT is a more feasible test to pick up ocular hypertension in high risk patients in a busy OPD practice and respects patient's time and effort.

Methods

A total of 100 eyes with more than 2 risk factors for developing glaucoma (eg disc hemorrhage, family history, thin pachy, high c:d ratio, diabetes, hypertension) but with normal visual fields, open angles and normal IOPs were included and subject to water drinking test. Peak IOPs and IOP fluctuations were noted.

Results

33 out of 100 eyes showed IOP peaks of more than 25mmHg and 28 eyes had IOP higher than 30mmhg. A total of 61% had ocular hypertension defined as IOP more than 25mmHg. In patients with IOP peaks of more than 30mmHg, 19 of them had disc hemorrhage or/and high C:D ratio.

Conclusion

Water drinking test is a useful, practical and feasible test in identifying ocular hypertension in glaucoma suspects with normal IOP at one clinic visit. It respects

patient's time and effort and can be easily performed during office hours in a busy OPD practice. We conclude, it be added to our investigational armamentarium before devising treatment plan in such patients.

References

1. Kim E et al. Long-term follow-up in preperimetric open-angle glaucoma: progression rates and associated factors. *Am J Ophthalmol.* 2015 Jan;159(1):160-8.e1-2.
2. Kadambi SV et al. Comparison of intraocular pressure variability detected by day diurnal variation to that evoked by water drinking. *Indian J Ophthalmol.* 2021 Jun;69(6):1414-1417.

Lipid keratopathy induced by topical ocular hypotensive agent

Shao Y¹

¹China Medical University Hospital Ophthalmology Medical Center, Taichung, Taiwan

Introduction

To report a case with corneal stromal opacity and vascularization presumably induced by topical ocular hypotensive agent.

Methods

Case report.

Results

A 76-year-old female was diagnosed as having primary open angle glaucoma 8 years previously and was being treated with tafluprost and brimonidine for both eyes at her initial presentation at our hospital. Ocular examination revealed hyperemia, follicular conjunctivitis, and blepharitis in both eyes and semicircular falciform-shaped corneal infiltration with stromal neovascularization in her left eye. She had no remarkable medical, allergic histories and rosacea. Under the impression of lipid keratopathy, subconjunctival injection of bevacizumab was performed but not effective. The two topical drugs were discontinued and replaced with topical 0.1% fluorometholone and oral acetazolamide due to progressive hyperemia and corneal infiltration 4 months later after the injection. After replacement, follicular conjunctivitis and corneal neovascularization ultimately were resolved. Tafluprost was again prescribed and there was no recurrence of corneal infiltration or neovascularization in the left eye. Only corneal opacity remained in the deep layer of the corneal stroma.

Conclusion

We encountered a case of corneal complication that was suspected as side effects after topical hypotensive eye drop use. Special care should be taken to observe the condition of ocular surface when a topical ocular agent is administered.

References

1. Yuka K. et al. Corneal Opacity Induced by Antiglaucoma Agents Other Than Brimonidine Tartrate. Case Reports in Ophthalmological Medicine Volume 2020, Article ID 4803651.
2. Yuko M, et al. Severe Corneal Disorders Developed After Brimonidine Tartrate Ophthalmic Solution Use. Cornea 2017;0:1–3.
3. Yusuke M. et al. Corneal sterile infiltration induced by topical use of ocular hypotensive agent. Eur J Ophthalmol . 2020 Sep;30(5):NP23-NP25.

A retrospective study of Paediatric Thyroid Eye Disease: The Asian Experience

Bryan Sim¹, Chiaw Ling Chng², Chia Audrey¹, Lay Leng Seah¹

¹Singapore National Eye Centre (SNEC), Singapore

²Singapore General Hospital, Department of Endocrinology, Singapore

Introduction

To study the clinical presentation, disease characteristics and management approach for children with thyroid eye disease (TED) over a 10 year period in a multidisciplinary Paediatric Thyroid Eye Disease Clinic at a tertiary care referral centre.

Methods

Retrospective case series of patients with TED at Kandang Kerbau Women's and Children's Hospital (KKWCH) Singapore between August 2006 to June 2015. The diagnosis of TED was clinical based on the Bartley criteria. Ophthalmic examination findings, systemic thyroid function and ophthalmological intervention were recorded.

Results

Nineteen subjects with paediatric TED were studied. The median age at diagnosis was 12.5 years (range 6-17). The onset of TED was at the same time as their thyroid disease in half of these patients (52.6%) of which all were hyperthyroid except one. The most common signs at TED diagnosis were proptosis (84.2%), lid retraction (63.2%), acquired epiblepharon (63.2%). All patients were inactive and none had evidence of compressive optic neuropathy. TED remained stable in all patients except for one who developed worsening proptosis with exposure keratopathy. No patients were prescribed steroids (oral or intravenous) or had orbital decompression surgery. The most debilitating morbidity was acquired epiblepharon of which out of 12 patients - one had everting sutures and three were offered surgical correction.

Conclusion

Paediatric TED subjects exhibit milder clinical manifestations compared to adults. Acquired epiblepharon causes most significant visual morbidity by compromising the corneal surface. Being cognisant of the subtleties of paediatric TED will permit the discerning clinician to effectively manage such cases accordingly.

References

1. Goldstein, S.M., Katowitz W.R., Moshang T, Katowitz J.A., et al., Pediatric thyroid-associated orbitopathy: the Children's Hospital of Philadelphia experience and literature review. *Thyroid*, 2008. 18(9): p. 997-9.
2. Lim, N.C., Amrith S., and Sundar G., Pediatric thyroid eye disease--the Singapore experience. *Orbit*, 2014. 33(2): p. 96-103.
3. Chng C.L., Seah L.L., and Khoo D.H., Ethnic differences in the clinical presentation of Graves' ophthalmopathy. *Best Pract Res Clin Endocrinol Metab*, 2012. 26(3): p. 249-58.
4. Lim, N.C., Sundar G, Amrith S, Lee K.O., Thyroid eye disease: a Southeast Asian experience. *Br J Ophthalmol*, 2015. 99(4): p. 512-8.
5. Bartley, G.B. and Gorman C.A., Diagnostic criteria for Graves' ophthalmopathy. *Am J Ophthalmol*, 1995. 119(6): p. 792-5.
6. Bartley, G.B., Evolution of classification systems for Graves' ophthalmopathy. *Ophthalmic Plast Reconstr Surg*, 1995. 11(4): p. 229-37.
7. Bartalena, L., Baldeschi L, Dickinson A, et al., Consensus statement of the European Group on Graves' orbitopathy (EUGOGO) on management of GO. *Eur J Endocrinol*, 2008. 158(3): p. 273-85.
8. Wakelkamp, I.M., Baldeschi L, Saeed P, et al., Surgical or medical decompression as a first-line treatment of optic neuropathy in Graves' ophthalmopathy? A randomized controlled trial. *Clin Endocrinol (Oxf)*, 2005. 63(3): p. 323-8.
9. Orgiazzi, J., Anti-TSH receptor antibodies in clinical practice. *Endocrinol Metab Clin North Am*, 2000. 29(2): p. 339-55, vii.

10. Wong, G.W. and Cheng P.S., Increasing incidence of childhood Graves' disease in Hong Kong: a follow-up study. *Clin Endocrinol (Oxf)*, 2001. 54(4): p. 547-50.
11. Acuna, O.M., Athanassaki I, and Paysse E.A., Association between thyroid-stimulating immunoglobulin levels and ocular findings in pediatric patients with Graves disease. *Trans Am Ophthalmol Soc*, 2007. 105: p. 146-50; discussion 150-1.
12. Lavard, L., Ranlov I, Perrild H, et al., Incidence of juvenile thyrotoxicosis in Denmark, 1982-1988. A nationwide study. *Eur J Endocrinol*, 1994. 130(6): p. 565-8.
13. Krassas, G.E. and Gogakos A., Thyroid-associated ophthalmopathy in juvenile Graves' disease--clinical, endocrine and therapeutic aspects. *J Pediatr Endocrinol Metab*, 2006. 19(10): p. 1193-206.
14. Forssberg, M., Arvidsson C.G., Engvall J, et al., Increasing incidence of childhood thyrotoxicosis in a population-based area of central Sweden. *Acta Paediatr*, 2004. 93(1): p. 25-9.
15. Uretsky, S.H., Kennerdell J.S., and Gutai J.P., Graves' ophthalmopathy in childhood and adolescence. *Arch Ophthalmol*, 1980. 98(11): p. 1963-4.
16. Bartley, G.B., Fatourechi V, Kadrmas E.F., et al., Clinical features of Graves' ophthalmopathy in an incidence cohort. *Am J Ophthalmol*, 1996. 121(3): p. 284-90.
17. Chua, M.R., Tomlinson L.A., Binenbaum G, et al., Pediatric Thyroid Eye Disease: Clinical Characteristics and Orbital Decompression Outcomes. *Ophthalmic Plast Reconstr Surg*, 2018. 34(4S Suppl 1): p. S52-S55.
18. Park, S.W., Khwarg S.I., Kim N, et al., Acquired lower eyelid epiblepharon in thyroid-associated ophthalmopathy of Koreans. *Ophthalmology*, 2012. 119(2): p. 390-5.
19. Tan, M.C., Young S, Amrith S, et al., Epidemiology of oculoplastic conditions: the Singapore experience. *Orbit*, 2012. 31(2): p. 107-13.
20. Chan, W., Wong G.W.K, Cheng A.C.K., et al., Ophthalmopathy in childhood Graves' disease. *Br J Ophthalmol*, 2002. 86(7): p. 740-2.
21. Belanger, C., Zhang K.S., Reddy A.K., et al., Inflammatory disorders of the orbit in childhood: a case series. *Am J Ophthalmol*, 2010. 150(4): p. 460-3.

22. International Thyroid Eye Disease Society. Clinical VISA Recording Forms. <http://thyroideyedisease.org/clinical-visa-recording-forms/> (accessed 1 Jun 2013).

Comparison of a novel conjunctival swab technique and Schirmer's tear strips for detection of tear cytokines

Sim R¹, Wu M², Chan A¹, Tong L¹

¹Singapore National Eye Centre, , Singapore, ²Singapore Eye Research Institute, , Singapore

Introduction

Nasopharyngeal swabs have been shown to be efficacious for COVID19 testing. This study aims to evaluate its use as a safe and painless method to analyse ocular surface tear cytokines.

Methods

In 5 patients, Dacron soft tip nasopharyngeal swabs (Copan Italia S.p.A, Italy, SPD Scientific) were used to swab the lower lacrimal punctum and conjunctival surface without local anaesthesia under direct visualization. In 14 patients, Schirmer's tear samples were collected. Protein concentration was measured using Micro BCA Assay Protein Conc (ug/ml). All samples were analysed in duplicates using the Simoa Human Cytokine 6-plex Panel 1 Advantage Kit on the Simoa Quanterix SR-X platform. Cytokines measured included: tumour necrosis factor alpha (TNFa), interferon-gamma (IFNg), IL-6, interleukin-10 (IL10), interleukin-17 alpha (IL 17a), interleukin 12p-170 (IL12p-170).

Results

33 eyes from 17 individuals with no diagnosed ocular disease were involved. The mean protein concentration (ug/ml) was 157.8 ± 112.0 (133.1, 11.5- 573.4) and protein could be detected in all samples. None experienced pain or redness post procedure.

TNFa, IFNg, IL6 and IL17a were readily detected in both conjunctival swabs and Schirmer's tears samples. These cytokines were elevated above negative controls. There was no difference in the non-detectable rates for these cytokines between

the swab (50% non-detectable) and Schirmer's (54% non-detectable) groups ($p=0.85$).

Conclusion

This pilot study suggests that these swabs can be used to painlessly detect ocular surface inflammatory cytokines, particularly TNF α , IFN γ , IL6 and IL17 α , with equal efficacy as Schirmer's tear strips. This novel technique may be an alternative method for collection of ocular surface cells and cytokines.

Three-Dimensional Structural Analysis of the Optic Nerve Head in Myopic subjects with and without Glaucoma

Sim R¹, Thierry A³, Ang M¹, Chong R¹, Foo L¹, Girard M¹

¹Singapore National Eye Centre, Singapore, ²Singapore Eye Research Institute, Singapore, ³National University of Singapore, Singapore, ⁴Duke-NUS Medical School, Singapore

Introduction

Myopic structural and functional changes complicate the diagnosis of glaucoma. We hypothesise that novel artificial intelligence algorithms can identify structural differences at the optic nerve head (ONH) in myopic eyes with glaucoma (MG) and myopic non-glaucomatous eyes (MN).

Methods

All subjects were Chinese, aged ≥ 50 years and myopic, defined as spherical equivalent (SE) of $\leq -0.25D$. Single eyes of 8 MN subjects were compared with 48 MG subjects). Optical coherence tomography (OCT) was performed at the ONH, and raster scans were obtained. Two separate AI algorithms (Reflectivity, Abyss Processing, Singapore) were used to compute the following structural parameters: RNFL, GCC, choroidal, and prelaminar thickness; minimum rim width (MRW); LC and prelaminar depth (referenced to Bruch's membrane opening [BMO]); area of BMO opening; LC global shape index (a measure of LC curvature); and the amount of scleral bending. Independent T tests were performed for each ONH quadrant where $p < 0.05$ indicate statistical significance.

Results

There was no significant difference in age, gender, SE, or axial length between MG and MN subjects. MG eyes had smaller MRW ($p < 0.01$), thinner RNFL ($p < 0.01$), thinner GCC ($p < 0.05$), greater prelaminar depth ($p = 0.021$), greater LC depth ($p = 0.014$) and smaller minimum prelaminar thickness ($p < 0.01$) compared to MN

eyes. There was no significant difference in choroidal thickness, scleral bending, BMO area or LC global shape index ($p>0.05$).

Conclusion

Our deep learning model has identified thinner RGC layers, smaller MRW and greater prelaminar and LC depth in low myopia eyes with glaucoma compared to low myopia eyes without glaucoma.

Vitreous hemorrhage after trabeculectomy; a case report

[Sinurat V¹](#), Christine R¹

¹Christian University of Indonesia General Hospital, East Jakarta, Indonesia

Introduction

It's a rare case when spontaneous vitreous hemorrhage occurred after trabeculectomy. The hemorrhage may be either due to bleeding from deep scleral suture, retinal break, suprachoroidal hemorrhage, or neovascularization of iris. It may also occur from a coexisting pathology such as diabetic retinopathy.

Case Illustration

A 61-year-old man came with blurred vision and pain on right eye. Right eye's visual acuity was 0.4 with IOP of 37 mmHg. Anterior chamber was deep and no iris neovascularization with implanted IOL. Fundus examination showed CD ratio was 0.9-1.0, with myopia degeneration. Gonioscopy revealed no NVA with occludable angle, PAS (+). Patient was diagnosed with chronic angle-closure glaucoma with moderate NPDR. With maximum medications, IOP target wasn't achieved. Then we performed trabeculectomy with 5-FU on right eye. One day after surgery, IOP was 15 mmHg and visual acuity was 0.3 with diffuse bleb. But four days after surgery, the patient came with sudden blurred vision. Visual acuity HM, IOP was 27 mmHg, flat bleb, and hyperemia. Posterior segment showed vitreous hemorrhage. Triamcinolone was injected 0.1 ml intravitreal. Two weeks after injection, right eye's visual acuity was 0.5, IOP was 14 mmHg, diffuse bleb, and vitreous was clear.

Discussion

Around 5% of patients after glaucoma surgery especially aqueous shunt implantation experienced vitreous hemorrhage. Anti-VEGF could be an option to treat vitreous hemorrhage. Due to the inability to afford anti-VEGF, we used triamcinolone acetonide injection to achieve better visual acuity and clear vitreous.

Conclusion

Intravitreal injection of triamcinolone in vitreous hemorrhage after trabeculectomy may give good results.

References

1. Zhao, Xinyue; Wang, Zhi; Yang, Xiaobo. Management of neovascular glaucoma with intravitreal ranibizumab, panretinal photocoagulation, and subsequent 5-fluorouracil augmented trabeculectomy. *Medicine*. 2017;96(25).
2. Daneshvar R. Anti-VEGF Agents and Glaucoma Filtering Surgery. *J Ophthalmic Vis Res*. 2013;8(2):182-186.
3. Cheng JW, Cheng SW, Wei RL, Lu GC. Anti-vascular endothelial growth factor for control of wound healing in glaucoma surgery. *Cochrane Database of Systematic Reviews*. John Wiley & Sons; 2017.
4. Ghoraba HH, Leila M, Elgouhary SM, Elgemai EE, Abdelfattah HM, Heikal MA. Safety of high-dose intravitreal triamcinolone acetate as low-cost alternative to anti-vascular endothelial growth factor agents in lower-middle-income countries. *Clinical Ophthalmology*. 2018;12:2383–91.
5. Liu L, Xu Y, Huang Z, Wang X. Intravitreal ranibizumab injection combined trabeculectomy versus Ahmed valve surgery in the treatment of neovascular glaucoma: assessment of efficacy and complications. *BMC Ophthalmology*. 2016;16(1):1-7.
6. Artini Widya, Gracia Ajeng, Kekalih A, Oktariana VD, Victor AA, Bani AP. Intravitreal anti-vascular endothelial growth factor injection combined with panretinal photocoagulation for neovascular glaucoma in Indonesian patients with diabetes mellitus: a prospective study. *Med J Indones*. 2019;28(3):258–67.
7. Horsley MB, Kahook MY. Anti-VEGF therapy for glaucoma. *Current Opinion in Ophthalmology*. 2010;21(2):112–117.
8. Slabaugh M, Salim S. Use of Anti-VEGF Agents in Glaucoma Surgery. *Journal of Ophthalmology*. 2017:1–6.

A Comparison of peripapillary and juxtapapillary choroidal thickness in healthy subjects

Son D¹, Kim T¹, Kim J¹

¹Chuncheon Sacred Heart Hospital, Chuncheon, South Korea

Introduction

To evaluate the correlation between the two methods of measuring the choroidal thickness around optic nerve head (ONH).

Methods

We conducted a cross-sectional study. Sixty-two eyes of 62 healthy subjects were included. Using spectral-domain optical coherence tomography (SD-OCT), peripapillary circle scan (3.5-mm diameter) and 24 radial B-scan image centered on the Bruch's membrane (BM) opening (BMO) were obtained. Peripapillary and juxtapapillary choroidal thickness (PPCT and JPCT, respectively) were measured using circle and radial B-scan images, respectively. Correlation and agreements between values measured by two methods was analyzed. Factors associated with PPCT and JPCT, and the difference between the values measured by two methods were evaluated.

Results

A total of 62 eyes of 62 healthy subjects were enrolled. Average PPCT and JPCT were 165.2 ± 50.1 and 139.7 ± 39.2 μm , respectively. The linear regression analysis showed a strong correlation between both measurements (PPCT vs. JPCT) ($r^2 = 0.900$, $P < 0.001$). PPCT and JPCT measurements showed good agreement in global and all 6 sectors (ICCs > 0.900). Bland-Altman plot showed good agreement between the two methods with a systematic deviation of 17.9 μm and a 95% confidence interval of -9.6 to 60.5 . In multivariate regression analysis, BMOA ($\beta = -11.87$, $P = 0.002$) was the only factor significantly correlated with the difference between PPCT and JPCT, which showed a negative correlation. The difference

between PPCT and JPCT measurements (PPCT – JPCT) showed a divergent tendency with decreasing BMOA size.

Conclusion

The two measures of choroidal thickness around the ONH were well correlated. However, the peripapillary choroid was generally thicker than the juxtapapillary choroid especially in eyes with small BMO area.

References

1. Nicolela MT, Ferrier SN, Morrison CA, Archibald ML, LeVatte TL, Wallace K, et al. Effects of cold-induced vasospasm in glaucoma: the role of endothelin-1. *Invest Ophthalmol Vis Sci*. 2003;44(6):2565-72.
2. Mojon DS, Hess CW, Goldblum D, Fleischhauer J, Koerner F, Bassetti C, et al. High prevalence of glaucoma in patients with sleep apnea syndrome. *Ophthalmology*. 1999;106(5):1009-12.
3. Lee EJ, Lee KM, Lee SH, Kim TW. OCT Angiography of the Peripapillary Retina in Primary Open-Angle Glaucoma. *Invest Ophthalmol Vis Sci*. 2016;57(14):6265-70.
4. Lee EJ, Lee KM, Lee SH, Kim TW. Parapapillary Choroidal Microvasculature Dropout in Glaucoma: A Comparison between Optical Coherence Tomography Angiography and Indocyanine Green Angiography. *Ophthalmology*. 2017;124(8):1209-17.
5. Lee EJ, Lee SH, Kim JA, Kim TW. Parapapillary Deep-Layer Microvasculature Dropout in Glaucoma: Topographic Association With Glaucomatous Damage. *Invest Ophthalmol Vis Sci*. 2017;58(7):3004-10.
6. Nagia L, Huisingh C, Johnstone J, Kline LB, Clark M, Girard MJ, et al. Peripapillary Pachychoroid in Nonarteritic Anterior Ischemic Optic Neuropathy. *Invest Ophthalmol Vis Sci*. 2016;57(11):4679-85.
7. Sharma S, Ang M, Najjar RP, Sng C, Cheung CY, Rukmini AV, et al. Optical coherence tomography angiography in acute non-arteritic anterior ischaemic optic neuropathy. *Br J Ophthalmol*. 2017;101(8):1045-51.

8. Garcia-Basterra I, Lahrach I, Morillo Sanchez MJ, Kamal-Salah R, Rius-Diaz F, Dawid Milner MS, et al. Analysis of peripapillary choroidal thickness in non-arteritic anterior ischaemic optic neuropathy. *Br J Ophthalmol*. 2016;100(7):891-6.
9. Lee KM, Lee EJ, Kim TW. Juxtapapillary choroid is thinner in normal-tension glaucoma than in healthy eyes. *Acta Ophthalmol*. 2016;94(8):e697-e708.
10. Suh W, Cho HK, Kee C. Evaluation of peripapillary choroidal thickness in unilateral normal-tension glaucoma. *Jpn J Ophthalmol*. 2014;58(1):62-7.
11. Kim JA, Son DH, Lee EJ, Kim H, Kim TW. Intereye Comparison of the Characteristics of the Peripapillary Choroid in Patients with Unilateral Normal-Tension Glaucoma. *Ophthalmol Glaucoma*. 2021;4(5):512-21.
12. Chauhan BC, O'Leary N, AlMobarak FA, Reis ASC, Yang H, Sharpe GP, et al. Enhanced detection of open-angle glaucoma with an anatomically accurate optical coherence tomography-derived neuroretinal rim parameter. *Ophthalmology*. 2013;120(3):535-43.
13. Danthurebandara VM, Sharpe GP, Hutchison DM, Denniss J, Nicolela MT, McKendrick AM, et al. Enhanced structure-function relationship in glaucoma with an anatomically and geometrically accurate neuroretinal rim measurement. *Invest Ophthalmol Vis Sci*. 2014;56(1):98-105.
14. Lee EJ, Lee KM, Kim H, Kim TW. Glaucoma Diagnostic Ability of the New Circumpapillary Retinal Nerve Fiber Layer Thickness Analysis Based on Bruch's Membrane Opening. *Invest Ophthalmol Vis Sci*. 2016;57(10):4194-204.
15. Mansouri K, Medeiros FA, Tatham AJ, Marchase N, Weinreb RN. Evaluation of retinal and choroidal thickness by swept-source optical coherence tomography: repeatability and assessment of artifacts. *Am J Ophthalmol*. 2014;157(5):1022-32.
16. Lee SH, Lee EJ, Kim TW. Topographic Correlation Between Juxtapapillary Choroidal Thickness and Microstructure of Parapapillary Atrophy. *Ophthalmology*. 2016;123(9):1965-73.
17. Hirooka K, Tenkumo K, Fujiwara A, Baba T, Sato S, Shiraga F. Evaluation of peripapillary choroidal thickness in patients with normal-tension glaucoma. *BMC Ophthalmol*. 2012;12:29.

18. Johnstone J, Fazio M, Rojananuangnit K, Smith B, Clark M, Downs C, et al. Variation of the axial location of Bruch's membrane opening with age, choroidal thickness, and race. *Invest Ophthalmol Vis Sci.* 2014;55(3):2004-9.
19. Rhodes LA, Huisinigh C, Johnstone J, Fazio MA, Smith B, Wang L, et al. Peripapillary choroidal thickness variation with age and race in normal eyes. *Invest Ophthalmol Vis Sci.* 2015;56(3):1872-9.
20. Huang W, Wang W, Zhou M, Chen S, Gao X, Fan Q, et al. Peripapillary choroidal thickness in healthy Chinese subjects. *BMC Ophthalmol.* 2013;13:23.
21. Roberts KF, Artes PH, O'Leary N, Reis AS, Sharpe GP, Hutchison DM, et al. Peripapillary choroidal thickness in healthy controls and patients with focal, diffuse, and sclerotic glaucomatous optic disc damage. *Arch Ophthalmol.* 2012;130(8):980-6.
22. Yang H, Luo H, Gardiner SK, Hardin C, Sharpe GP, Caprioli J, et al. Factors Influencing Optical Coherence Tomography Peripapillary Choroidal Thickness: A Multicenter Study. *Invest Ophthalmol Vis Sci.* 2019;60(2):795-806.
23. Torres LA, Sharpe GP, Hutchison DM, Zangalli CS, Burk RO, Reis ASC, et al. Influence of Bruch's Membrane Opening Area in Diagnosing Glaucoma With Neuroretinal Parameters From Optical Coherence Tomography. *Am J Ophthalmol.* 2019;208:94-102.
24. Amini N, Miraftabi A, Henry S, Chung N, Nowroozizadeh S, Caprioli J, et al. The Relationship of the Clinical Disc Margin and Bruch's Membrane Opening in Normal and Glaucoma Subjects. *Invest Ophthalmol Vis Sci.* 2016;57(3):1468-75.
25. Kadziauskiene A, Kuoliene K, Asoklis R, Lesinskas E, Schmetterer L. Changes in choroidal thickness after intraocular pressure reduction following trabeculectomy. *Acta Ophthalmol.* 2016;94(6):586-91.
26. Suh MH, Zangwill LM, Manalastas PI, Belghith A, Yarmohammadi A, Medeiros FA, et al. Deep Retinal Layer Microvasculature Dropout Detected by the Optical Coherence Tomography Angiography in Glaucoma. *Ophthalmology.* 2016;123(12):2509-18.
27. Spalton DJ. Microvasculature of the human optic nerve. *Am J Ophthalmol.* 1996;121(4):452-3.

28. Jiang R, Wang YX, Wei WB, Xu L, Jonas JB. Peripapillary Choroidal Thickness in Adult Chinese: The Beijing Eye Study. *Invest Ophthalmol Vis Sci*. 2015;56(6):4045-52.
29. Song A, Hou X, Zhuo J, Yu T. Peripapillary choroidal thickness in eyes with high myopia. *J Int Med Res*. 2020;48(4):300060520917273.

An excruciating outcome – lens related glaucoma secondary to pandemic related fear.

Sothirachagan S¹, Cheng T¹, Che-Hamzah J¹

¹Hospital Universiti Kebangsaan Malaysia, Kuala Lumpur, Malaysia

Introduction

Lens induced glaucoma is a secondary glaucoma in which the crystalline lens is involved in the mechanism of increased intraocular pressure (IOP)^{1,2}. With the declaration of the COVID-19 pandemic as a global health emergency in 2020, movement control orders were instated. This led to delayed appointments, resulting in sequelae of untreated mature cataracts namely lens induced glaucoma³.

Methods

Case series

Results

Three male patients diagnosed as having phacomorphic and phacolytic glaucoma, one and two respectively, from March 2020 to January 2021 were discussed in this case series. The presentation of all patients was similar with ocular pain, redness, progressive blurring of vision and haloes in the affected eye for several weeks. All of them faced difficulty to comply with ophthalmology clinic follow ups for their cataracts during Covid-19 pandemic. All cases were unilateral and patients were between the ages of 50 – 75 years. Pre-treatment IOP was 45-60mmHg, and were treated with systemic and maximum topical antiglaucoma upon initial acute presentation. Each underwent prompt cataract extraction with subsequent lifelong topical antiglaucoma medication for IOP control. For case 1 with phacomorphic glaucoma, zonulolysis was noted intraoperatively, hence he was left aphakic after intracapsular cataract extraction. He was then subjected for a secondary scleral fixated intraocular lens implantation. Case 2 with phacolytic glaucoma presented with a pseudohypopyon and high IOP, mimicking

endophthalmitis highlighting the severity and complexity of delayed presentation. While case 3 with phacolytic glaucoma developed venous stasis retinopathy due to ocular hypertension causing a poor vision over the affected eye despite prompt treatment.

Conclusion

Cataract typically causes reversible blindness and is simply managed. If left untreated however, it could not only lead to devastating vision loss but it could cause an adverse impact on quality of life. This highlights the late presentation of patients with mature cataract during the COVID-19 pandemic.

References

1. Shahid, E., Sheikh, A., Fasih, U. (2011). Complications of Hypermature Cataract and Its Visual Outcome. Pak J Ophthalmol 2011, Vol.27No.2.
<http://www.pjo.com.pk/27/2/Erum%20Shahid.pdf>.
2. Laurenti, K. and Salim, S. (2016). Lens-induced Glaucoma: Diagnosis and Management. American Academy of Ophthalmology, EyeNet.
<https://www.aao.org/eyenet/article/lens-induced-glaucoma-diagnosis-management>.
3. Aref, A.A., Luna, G., Tripathy, K. et al (2020). Lens Induced Glaucomas, American Academy of Ophthalmology. EyeWiki.
https://eyewiki.aao.org/Lens_Induced_Glaucomas.

The trend in Acute Primary Angle Closure cases under the COVID-19 Omicron outbreak in a regional eye hospital in Hong Kong

Su C¹, Au S², Tsang A², Ko C²

¹Li Ka Shing Faculty Of Medicine, The University Of Hong Kong, , Hong Kong,

²Department of Ophthalmology, Pamela Youde Nethersole Eastern Hospital, , Hong Kong

Introduction

Previous studies have characterized a shallower anterior chamber in Asian eyes, and primary angle closure spectrum diseases are more prevalent in Asian countries.^[1] Cough and cold medications are known to precipitate acute primary angle closure (APAC).^[2] Here, we investigate the trend of APAC, an ocular emergency, in relation to the local COVID-19 Omicron outbreak in 2022 in Hong Kong.

Methods

A regional eye hospital's attendance record from 18th October 2021 to 16th April 2022 was retrospectively reviewed. Patients diagnosed with APAC were included. Exclusion criteria included secondary angle closure such as lens subluxation, uveitis, uveal tumours, and neovascular glaucoma. Trends in COVID-19 cases and APAC cases were compared by graphical methods.

Results

28,992 patients were reviewed, and 9 cases of APAC were identified. At baseline, an APAC case appeared every one to two months, but a cluster of cases appeared the week after the COVID-19 Omicron surge (Figure1). All individual cases reported prior cough and cold medication use.

Conclusion

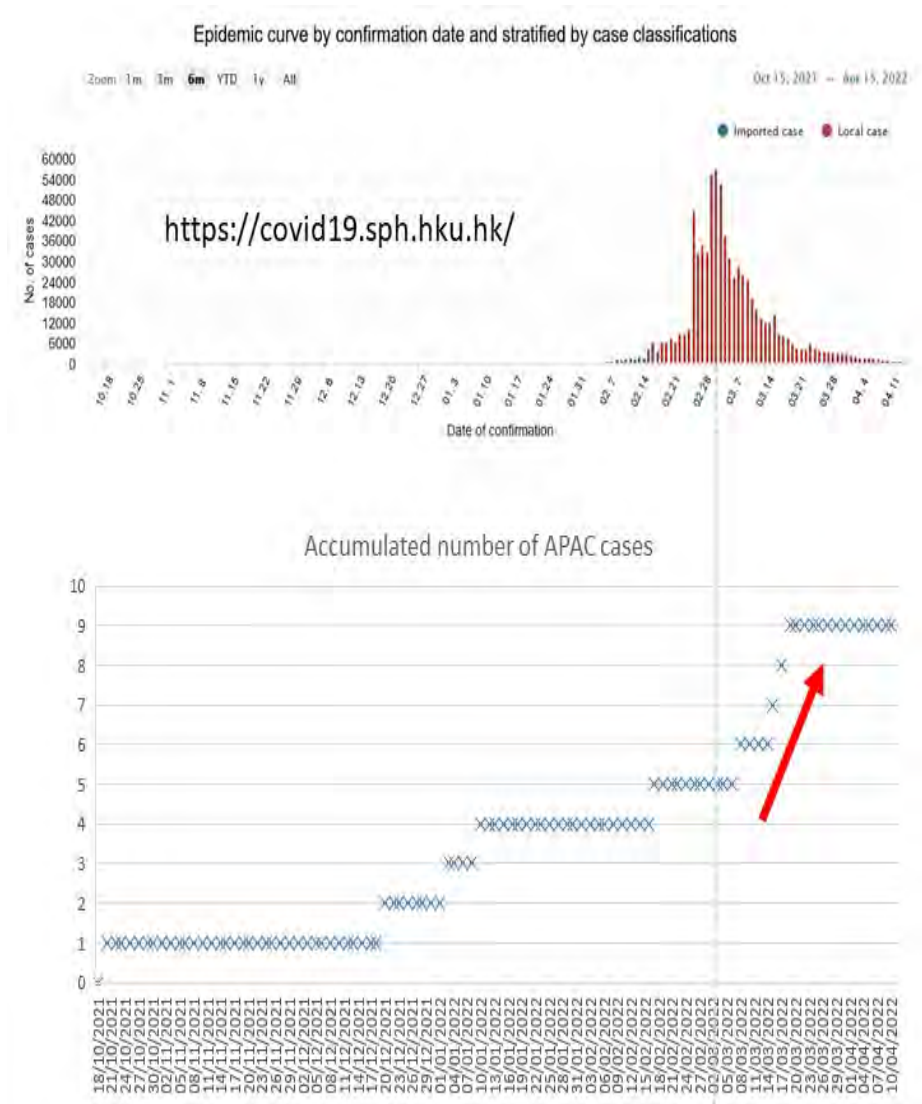
The surge in cough and cold medications used during the Omicron outbreak likely caused a surge in APAC cases ~1 week after the local COVID-19 Omicron peak.

References

1. He M, Foster PJ, Johnson GJ, Khaw PT. Angle-closure glaucoma in East Asian and European people. Different diseases? Eye (Lond). 2006;20(1):3-12.
2. Lai JS, Gangwani RA. Medication-induced acute angle closure attack. Hong Kong Med J. 2012;18(2):139-45.

Figure

Figure 1: Side-by-side graphical comparison of new COVID-19 cases and APAC cases in a regional hospital in Hong Kong.



Evaluation of bleb morphology using three-dimensional anterior segment optical coherence tomography before surgical bleb revision following failed trabeculectomy

Sugihara K¹, Narita A¹, Takizawa S¹, Masuda Y¹, Seguchi J¹

¹Okayama Saiseikai General Hospital, Okayama, Japan

Introduction

Surgical bleb revision is one of the methods to revive failed trabeculectomy blebs, however the morphological features of blebs before surgical bleb revision remain to be identified. To identify the association between pre-revised bleb morphology and intraocular pressure (IOP) control at 1 year after surgical bleb revision, we examined intrableb features using swept-source three-dimensional anterior segment optical coherence tomography (3D AS-OCT) prior to surgical bleb revision following failed trabeculectomy.

Method

This retrospective cohort study included 49 eyes of 47 patients that had undergone surgical bleb revision. Subjects were classified into two groups, successful or unsuccessful, according to the following success criteria: IOP ≤ 15 mm Hg and $>20\%$ IOP reduction without glaucoma medication and additional glaucoma surgeries. The blebs were examined using swept-source 3D AS-OCT before surgical bleb revision regarding the 3D AS-OCT parameters, including the width of the filtration opening of the scleral flap and the preoperative filtering bleb grades in accordance with the fluid space patterns above and/or below the scleral flap as follows: no fluid below the scleral flap (grade 1), fluid below the scleral flap but not above the scleral flap (grade 2), and fluid below and above the scleral flap (grade 3).

Results

The mean IOP of 20.1 ± 5.4 mmHg decreased significantly to 10.4 ± 3.8 mmHg at 1 year, with a success rate of 75.5%. There were 37 (75.5%) and 12 (24.5%) eyes in

the successful and unsuccessful groups, respectively. There were no significant between-group differences in preoperative 3D AS-OCT parameters.

Conclusion

Surgical bleb revision is effective for reviving failed blebs, regardless of the preoperative bleb morphology.

Visual Loss As Primary Manifestation Of Olfactory Groove Meningioma

[Sulaiman F¹](#), [Sawri Rajan R¹](#), [Wan Abdul Halim W²](#)

¹Hospital Selayang, Gombak, Malaysia, ²Universiti Kebangsaan Malaysia, Bandar Tun Razak, Malaysia

Introduction

Olfactory groove meningiomas are a slow-growing tumour, asymmetrical in growth, more commonly bilateral than unilateral. Olfactory groove meningioma is commonly found at the ethmoidal bone cribriform plate, frontosphenoidal suture and the planum sphenoidale, originating from the anterior cranial base. It's occurrence comprises 5-18% of all intracranial meningiomas. It can cause a progressive compression on the frontal lobes and may extend towards the sella. It may compromise vision by causing compression the optic nerve and the optic chiasm. We present a case of olfactory nerve meningioma compressing the frontal lobe and optic nerve causing bilateral visual loss.

Methods

Case Report

Results

A 58 years old Chinese man presented to ophthalmology clinic with bilateral gradual onset, generalised blurring of vision over 6 months duration. He had lost 10 kilograms within 3 months. Ocular examination revealed diminished visual acuity, decreased colour discrimination with positive relative afferent pupillary defect the left eye. Right optic disc was swollen with blurring of the disc margin superonasally. Humphrey Visual Field 24-2 done revealed bilateral total loss of visual field. Cranial nerve examination revealed impaired cranial nerve I and II. Magnetic Resonance Imaging showed features of anterior skull base meningioma

causing mass effect, midline shift & contralateral early hydrocephalus. He was referred to Neurosurgical and subsequently underwent bifrontal craniotomy & tumor debulking surgery.

Conclusion

This case report describes the clinical presentations of olfactory groove meningioma. Ophthalmologists should have a high index of suspicion that optic disc swelling and low vision can be caused by an intracranial tumor which compresses optic apparatus.

References

1. Pepper J, Hecht SL, Gebarski SS, Lin EM, Sullivan SE, Marentette LJ. Olfactory groove meningioma: discussion of clinical presentation and surgical outcomes following excision via the subcranial approach. *Laryngoscope*. 2011;121:2282–2289.
2. Fountas KN, Hadjigeorgiou GF, Kapsalaki EZ, *et al.* Surgical and functional outcome of olfactory groove meningiomas: lessons from the past experience and strategy development. *Clin Neurol Neurosurg* 2018;171:46–52.
3. Ciurea AV, Iencean SM, Risea RE, Brehar FM. Olfactory groove meningiomas. A retrospective study of 59 surgical cases. *Neurosurg Rev*. 2011 Sep 30; [Epub ahead of print.]
4. Mukherjee S, Thakur B, Corns R, *et al.* Resection of olfactory groove meningioma - a review of complications and prognostic factors. *Br J Neurosurg* 2015;29:685–92.

Trabeculectomy in Glaucoma Secondary to Nanophthalmos: A Case Report

[Cahya Suspimantari](#)¹, [Denti Puspasari](#)², [Maharani](#)², [Fifin L Rahmi](#)²

¹Resident of Ophthalmology Department of Diponegoro University, Kariadi Hospital, Semarang, Indonesia

²Staff of Glaucoma Subdivision, Ophthalmology Department of Diponegoro University, Kariadi Hospital, Semarang, Indonesia

Introduction

Glaucoma secondary to nanophthalmos is a relatively rare abnormality characterized by a small eye without other malformations and the management is a challenging. Aim of this case report to present trabeculectomy was effective in glaucoma secondary to nanophthalmos.

Methods

A case report of a 22-year-old female presented with slow blurring vision in both eyes for 1 year. Her visual acuity was 6/60 in RE and hand movement in LE and intraocular pressure (IOP) was 18 mmHg (RE) and 28 mmHg (LE) with topical and oral therapy for 1 year. Patient has short axial length, shallow anterior chamber depth (ACD), thick choroid, and steep cornea. The funduscopy revealed glaucomatous optic neuropathy and gonioscopy was close angle. Medication failed to control IOP, thus she underwent RE and LE trabeculectomy.

Results

First day after surgery, the IOP was 10,5 mmHg (RE) and 7,5 mmHg (LE). The bleb appeared elevated. The IOP was maintain after one-month after trabeculectomy without drugs.

Conclusion

Result indicates that trabeculectomy was effective and save for IOP control in patient with nanophthalmos.

References

1. Carricondo PC, et al. Nanophthalmos : A Review of the Clinical Spectrum and Genetic. J Ophthalmol. 2018.
2. Yang N, et al. Nanophthalmos : An Update on the Biological Parameters and Fundus Abnormalities. 2021
3. Nouri-Mahdavi K, Nilforushan N, Razeghinejad MR, Amini H, Perera SA. Glaucoma in a patient with nanophthalmos. J Ophthalmic Vis Res. 2011;6(3):208-214.

Laser power stability of SubCyclo probes after repeated use

[Suvannachart P¹](#), Rujkorakarn P¹, Watha T¹, Srihatrai P¹

¹Department of Ophthalmology, Suddhavej Hospital, Mahasarakham University, Mahasarakham, Thailand, Mahasarakham, Thailand

Introduction

Micropulse transscleral cyclophotocoagulation is an effective procedure for glaucoma patients. The SubCyclo probe (Quantel Medical, France) is made from optical fiber and recommended for single use. Reuse of probes is cost-effective despite its lack of supporting evidence. This study aims to evaluate laser power stability of SubCyclo probes after repeated use.

Methods

This study included a new probe (A) and 2 used probes with ethylene oxide resterilization at least once (B and C). Each probe was connected to SubCyclo mode (2,000 mW power, 31.3% duty cycle, and 100 seconds duration) of Vitra 810 laser delivery system (Quantel Medical, France). Laser power measurements were taken using a calibrated laser power at early period (0-20 seconds), middle period (40-60 seconds), and late period (80-100 seconds) for each cycle, with a total of 40 cycles. Repeated measures ANOVA and pairwise comparisons with Bonferroni adjustment were used for analyses.

Results

Mean (SD) power outputs were 441.88 (6.37), 455.61 (6.15), and 453.04 (3.94) mW for probe A, probe B, and probe C, respectively. There were no statistical differences of all periods for each probe. Pairwise comparisons demonstrated that probe B and C provided significantly higher power than probe A ($P < 0.001$) at all periods. Mean differences (95% CI) for Probe A and B were -14.03 (-17.43, -10.63) for early period, -12.08 (-14.95, -9.20) for middle period, and -15.10 (-17.87, -12.33) for late period. For probe A and C, mean differences (95% CI) were -9.95 (-13.35, -6.55)

for early period, -10.45 (-13.33, -7.57) for middle period, and -13.10 (-15.87, -10.33) for late period. All probes had no defects before and after all measurements.

Conclusion

SubCyclo probe has stable laser power outputs within each cycle and throughout repeated use up to 40 cycles. Used probes with ethylene oxide resterilization released significantly higher power.

Risk factors for endothelial cell loss and graft failure after Descemet's stripping automated endothelial keratoplasty

[Takemori H](#)¹, Higashide T¹, Yokogawa H¹, Kobayashi A¹, sugiyama K¹

Department of Ophthalmology, Kanazawa University Graduate School of Medical Sciences, Kanazawa, Japan.

Introduction

To evaluate the long-term risk factors associated with postoperative endothelial cell loss and graft failure after Descemet's stripping automated endothelial keratoplasty (DSAEK) in Japanese eyes, with special attention to glaucoma.

Methods

This retrospective study involved 117 eyes of 110 consecutive patients with bullous keratopathy who were treated with DSAEK. These patients were classified into four groups: the no glaucoma group (n=23 eyes), primary angle-closure disease (PACD) group (n=32 eyes), glaucoma group that had previously undergone trabeculectomy (n=44 eyes, glaucoma with bleb), and the glaucoma group that had not previously undergone trabeculectomy (n=18 eyes, glaucoma without bleb). The changes in endothelial cell density (ECD) after DSAEK and probability of graft failure were compared between 4 groups.

Results

In all groups, ECD significantly decreased after DSAEK at all time points. The cumulative 5-year graft survival rate was 82.1% for all patients, 73% in the no glaucoma group, 100% in the PACD group, 39% in the glaucoma with bleb group, and 80% in the glaucoma without bleb group. Multivariate analysis showed that "additional glaucoma medication or surgery" after DSAEK were independent risk factors for ECD loss after DSAEK. Conversely, "glaucoma with bleb" and "pupillary block" were independent risk factors for graft failure after DSAEK.

Conclusion

Previous trabeculectomy and medical or surgical glaucoma treatment after DSAEK seemed to be related to ECD loss and subsequent graft failure. For long-term follow-up after DSAEK, corneal surgeons should pay attention to patients with preexisting filtering blebs and those who require postoperative glaucoma treatment. Patients with a history of pupillary block after DSAEK should also be carefully monitored.

Comparison of inner retinal layer thicknesses by macular segmental area in early glaucoma eyes affected in the upper versus lower hemiretina

Takemoto D¹, Higashide T¹, Ohkubo S^{1,2}, Udagawa S¹, Sugiyama K¹

¹Kanazawa University Graduate School of Medicine, Kanazawa, Japan, ²Ohkubo Eye Clinic, Kanazawa, Japan

Introduction

Text: We investigated the difference in thickness of the inner retinal layers by macular segmental area and the diagnostic ability of this for glaucoma eyes affected in the upper versus lower hemiretina.

Methods

Text: We retrospectively studied 45 normal eyes and 86 eyes with early glaucoma (EG) (mean deviation > -6 dB, including preperimetric glaucoma) with a photographically determined glaucomatous retinal nerve fiber layer defect and disc change confined to one hemiretina. The 86 EG eyes were divided into two groups: 31 upper and 55 lower hemiretina-affected eyes. OCT macular area scans were used to obtain the thickness of the RNFL, GCL/IPL, and GCC. The thicknesses of these layers were compared to control eyes across 8 sectors dividing the macular area. Furthermore, we assessed the AUC for the glaucoma diagnostic performance based on mean thickness and asymmetry index across the 8 macular sectors.

Results

Text: RNFL thickness was significantly smaller than controls in only the glaucomatous affected side in both the upper and lower hemiretina-affected groups. On the other hand, GCL/IPL thickness was significantly smaller than controls in all macular areas in both groups, except for the upper nasal central area in the lower hemiretina-affected group. The best AUC was obtained as blow in each group; the mean GCC thickness in the temporal upper peripheral area in the upper hemiretina-affected group had an AUC of 0.951 and the AUC of the

asymmetry index of the temporal GCL/IPL thickness in the lower hemiretina-affected group was 0.973.

Conclusion

Text: We suggest that appropriate sector and layer on macular OCT measurements should be analysed depending on which side (upper or lower) is affected in the hemiretina to achieve the best EG diagnostic performance.

Six-year incidence and risk factors for primary angle closure disease: The Singapore Epidemiology of Eye Diseases Study

Zhen Ling Teo¹, Zhi Da Soh^{1,3*}, Yih-Chung Tham^{1,2}, Marco Yu^{1,2}, Miao Li Chee¹, Sahil Thakur¹, Monisha E. Nongpiur^{1,2}, Victor Koh^{3,4}, Tien Yin Wong^{1,2,3}, Tin Aung^{1,2,3}, Ching-Yu Cheng^{1,2,3}

¹Singapore National Eye Centre, Singapore, Singapore Eye Research Institute, Singapore

²Ophthalmology & Visual Sciences Academic Clinical Program (Eye ACP), Duke-NUS Medical School, Singapore

³Yong Loo Lin School of Medicine, National University of Singapore, Singapore

⁴Department of Ophthalmology, National University Hospital, National University Health System, Singapore

Introduction

To determine the incidence and risk factors of primary angle closure disease (PACD) over six years in a multi-ethnic Asian population.

Methods

The Singapore Epidemiology of Eye Diseases study is a population-based cohort study conducted amongst adults aged 40 years or more. The baseline examination was conducted between 2004 to 2010; and the six-year follow up visit between 2011 to 2017. Out of 6,762 participants who attended the follow up examination, 5,298 participants at risk for primary angle closure glaucoma (PACG) and 5,060 participants at risk for PACD were included for analyses. Six-year PACD incidence was evaluated amongst an at-risk population excluding adults with baseline glaucoma, PACS, PAC, pseudophakia at baseline or follow-up, or laser peripheral iridotomy or iridectomy at baseline visit. Logistic regression analysis was performed to evaluate associations between PACD development and demographic or ocular characteristics. Forward selection based on the Quasi-likelihood Information Criterion (QIC) was used in multi-variable analysis.

Results

The six-year age-adjusted PACD incidence was 3.50% (95% confidence interval [CI] 2.94%–4.16%). In multivariable analysis, increasing age per decade (Odds ratio [OR] 1.35; 95% CI, 1.15–1.59), higher intraocular pressure (IOP) (OR1.04; 95%CI 1.00–1.08) and shallower anterior chamber depth (OR1.11; 95% CI 1.08–1.14) at baseline were associated with higher odds of PACD, while late posterior subcapsular cataract (OR0.60, 95% CI 0.48–0.76) was associated with lower odds of PACD. The six-year age-adjusted incidence of PACG, PAC & PACS were 0.29% (95% CI 0.14–0.55%), 0.46% (0.29–0.75%) and 2.54% (2.07–3.12%) respectively.

Conclusion

Our study showed that the six-year incidence of PACD was 3.50%. Increasing age, higher IOP and shallower anterior chamber were associated with higher risk of incident PACD while late posterior subcapsular cataract was associated with lower odds of PACD. These findings can aid in future projections and healthcare policy formulation for screening of at-risk individuals for timely intervention.

Bleb morphology after Ahmed valve glaucoma surgery by using Anterior segment Optical Coherence Tomography

Nguyen Dinh Cang², [Thuy Tien P](#)¹, Trang Thanh Nghiep¹, Doan Kim Thanh²

¹Ho Chi Minh City Eye Hospital, Ho Chi Minh City, Viet Nam, ²Pham Ngoc Thach University Ho Chi Minh City, Vietnam

Introduction

The function of bleb has important influence on Ahmed valve glaucoma surgery outcome. This study was to determine the characteristics in bleb morphology and its relationship with success of the surgery after Ahmed valve glaucoma implantation by using anterior segment optical coherence tomography (AS-OCT) and propose a classification system for bleb according to clinical and AS-OCT parameters.

Methods

A total of 48 patients who had received Ahmed valve implantation participated in this prospective study. Clinical morphology (extent, color, vascularity) and AS-OCT parameters (bleb wall thickness, bleb wall reflectivity, bleb height, microcyst) were measured post-operatively at 1 week, 1 month, 3 months and 6 months. The relationship between the bleb morphology and success of the surgery was evaluated. Success was defined as IOP < 21 mmHg with a maximum of 2 glaucoma medications.

Results

Photographic standards illustrating clinical bleb morphology characteristics was selected from the slit-lamp images of blebs in the study. Bleb vascularity and color was significantly correlated with the hypertensive phase and surgery success ($p < 0.05$). Bleb analysis using AS-OCT revealed a significant reduction in bleb wall

thickness and increase in bleb wall reflectivity at 1 month, which was mostly associated with hypertensive phase. There was a significant correlation between AS-OCT parameters and surgery success ($p < 0.05$).

Conclusion

AS-OCT is an objective method for assessment of bleb morphology. Clinical characteristics and AS-OCT parameters shows potential tools to better understand, predict and modify outcomes of Ahmed valve glaucoma surgery.

References

1. Jung K I, Park H, Jung Y, et al. (2015), "Serial changes in the bleb wall after glaucoma drainage implant surgery: characteristics during the hypertensive phase", *Acta Ophthalmol*, 93 (4), pp. e248-53.
2. Fargione RA, Tansuebchueasai N, Lee R, et al. (2019), "Etiology and management of the hypertensive phase in glaucoma drainage-device surgery", *Surv Ophthalmol*, 64 (2), pp. 217-224.
3. Wagdy Faried (2020), "Bleb Morphology Using Anterior-Segment Optical Coherence Tomography after Ahmed Glaucoma Valve Surgery with Tenon Capsule Resection", *J Ophthalmol*, 2020, pp. 8386135.

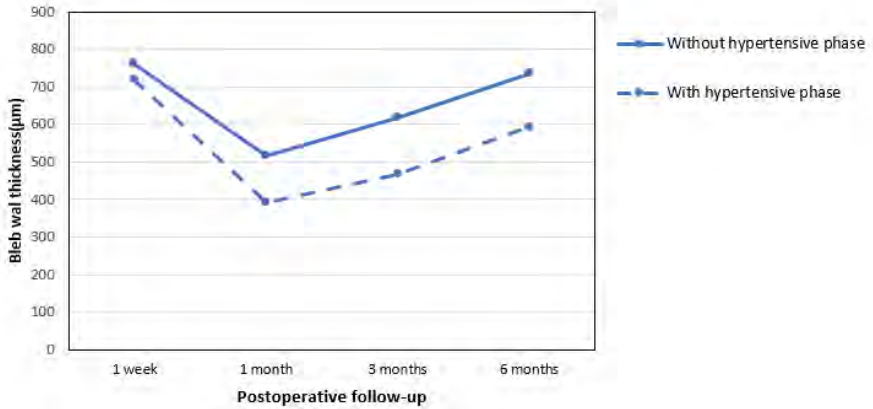


Figure 15: Bleb wall thickness in groups with and without hypertensive phase.

Table 1: Classification scale of clinical bleb morphology after Ahmed valve glaucoma surgery.






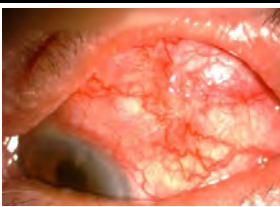

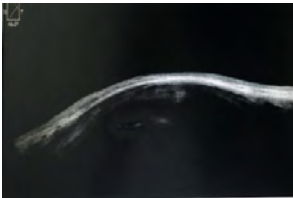
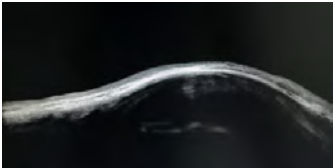
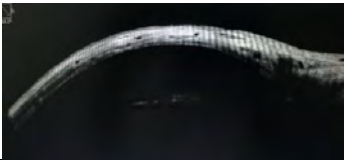
Characteristics			
Extent E			
	E1 Focal, limited under 2 clock hours	E2 Extend over 2 clock hours	
Color C			
	C1 Transparent	C2 Blurry	C3 Cloudy white
Vascularity V			
	V1 Extensive vascularity	V2 Mild vascularity or avascular	

Table 2: Classification scale of bleb morphology on AS-OCT after Ahmed valve glaucoma surgery.

Type	Parameters			
	Bleb wall thickness	Bleb height	Bleb wall reflectivity	Microcyst
A 	300-499 μm	400-600 μm	High	No
B 	500-699 μm	600-800 μm	High	Yes
C 	>700 μm	>800 μm	Low	Yes

Clinical outcomes of Ahmed glaucoma valve implantation for refractory glaucoma following pars plana vitrectomy

Nguyen Thi Thu Tam², [Thuy Tien P](#)¹, Ngo Thanh Tung¹, Le Minh Tuan²

¹Ho Chi Minh City Eye Hospital, Ho Chi Minh City, Viet Nam, ²University of Medicine and Pharmacy at Ho Chi Minh City, Ho Chi Minh City, Vietnam

Introduction

Secondary ocular hypertension is one of the commonest complications after pars plana vitrectomy, with 20-60% patients suffer from high IOP or glaucoma after this surgery. Causes may due to vitreoretinal diseases or the vitrectomy procedure. Glaucoma valve implantation is reasonable candidate for eyes which do not archive target IOP by drug treatment. The aim of this study is to evaluate the early effectiveness of Ahmed valve glaucoma for refractory glaucoma following pars plana vitrectomy.

Methods

Noncomparative interventional case series was done at Ho Chi Minh Eye Hospital, from July 2019 to February 2020. All patients suffering from secondary glaucoma following pas plana vitrectomy and IOP could not be controlled with maximum anti-glaucoma drugs (3 agents) for at least 2 weeks were operated with Ahmed glaucoma valve implantation. Patients were evaluated at 1 day, 1 month, 3 months, 6 months and each 3 months after surgery until the end of study.

Results

Thirty-four eyes of 33 patients with a mean age of 46.71 ± 14.40 years underwent a AGV implantation. The average follow-up after surgery was 11.49 ± 4.99 months (range 6-24 months). On average, treatment reduced the IOP by 15.4 ± 7.4 mmHg at the last visit. Kaplan–Meier survival analysis revealed cumulative success of 97.1% at 3 months, 94.1% at months, 91.2% at 6 months, 87.5% at 9 months and still stable until 24 months. Vision-threatening complications did not occur. The *success rate* was 88,23%. Cause of failure was high IOP due to bleb encapsulation.

In total, 11.76% had decreased in vision acuity. Factors including hypertensive phase, bleb encapsulation and high preoperative IOP were found to be associated with higher failure rates.

Conclusion

Ahmed valve implantation is a safe and effective procedure for refractory glaucoma following vitrectomy.

References

1. Ishida K., Ahmed I.I., Netland P.A. (2009), Ahmed Glaucoma Valve Surgical Outcomes in Eyes With and Without Silicone Oil Endotamponade, *Journal of glaucoma*, 18(4), pp. 325-330.
2. Erçalık N.Y., İmamoğlu S. (2017), Ahmed Glaucoma Valve Implantation in Vitrectomized Eyes, *Journal of Ophthalmology*, 2018, pp. 1-5.
3. Hong J.W., Choi G.J. (2005), Ahmed Valve Implantation for Refractory Glaucoma following Pars Plana Vitrectomy, *Korean journal of ophthalmology: KJO*, 19, pp. 293-296.
4. Jo J., Sung K.R., Kim Y.J. (2018), Influence of Vitrectomy-related Factors on the Outcome of Ahmed Glaucoma Valve Implantation, *Korean Journal of Ophthalmology*, 32(5), pp. 400-408.

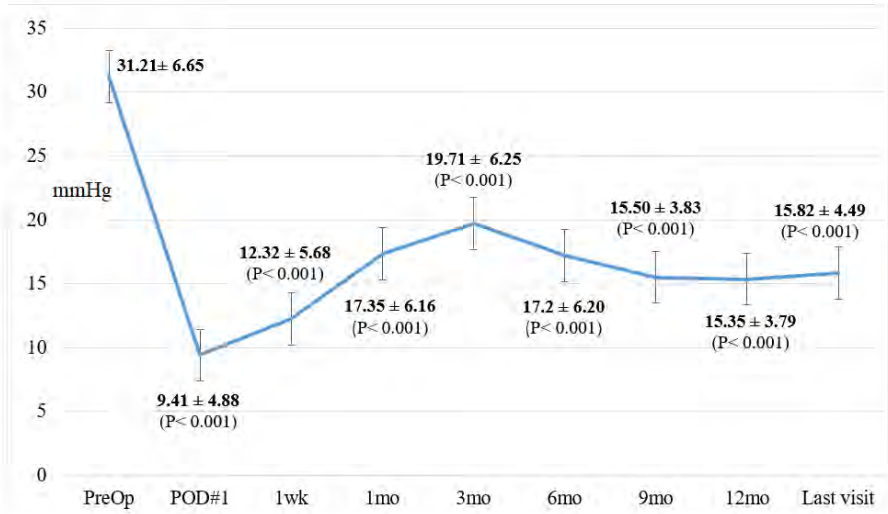


Fig. 1. Mean Intraocular pressure before and after ahmed valve implantation following pars plana vitrectomy.

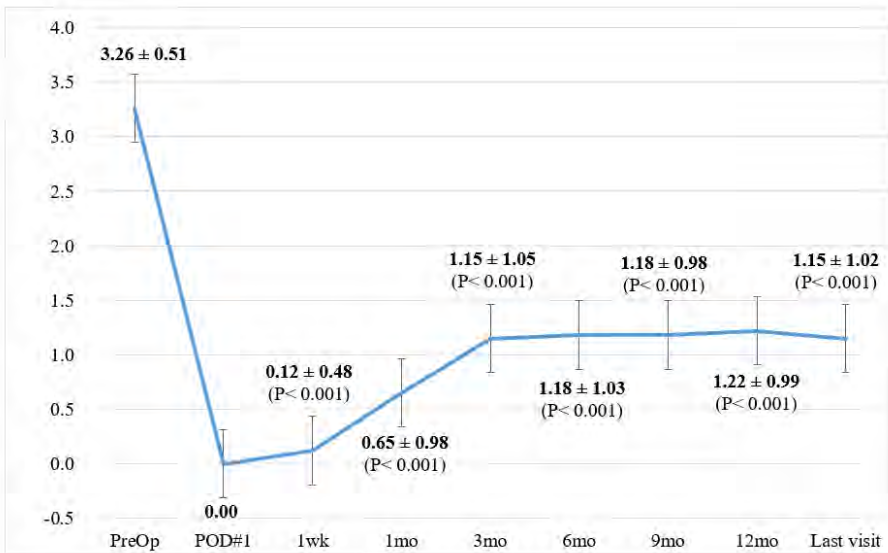


Fig. 2. Mean number of anti-glaucoma medications before and after ahmed valve implantation following pars plana vitrectomy.

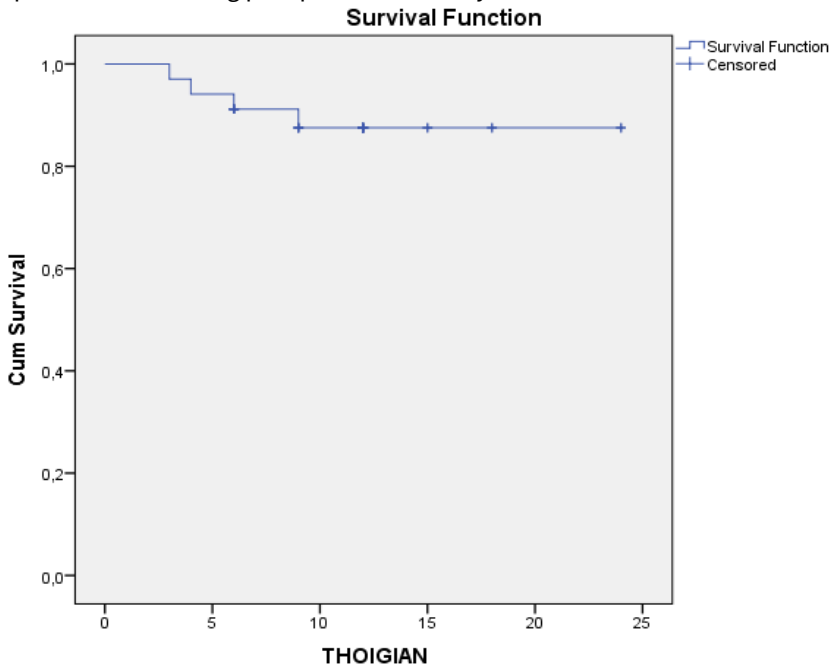


Fig. 3. Kaplan–Meier curve of success rate of ahmed valve implantation following pars plana vitrectomy.

Efficacy and safety of Micropulse transscleral diode laser cyclophotocoagulation in absolute glaucoma

Hau H², Thuy Tien P¹, Nghiep T¹, Hieu N³

¹Ho Chi Minh City Eye Hospital, Ho Chi Minh City, Viet Nam, ²General Hospital of Binh Duong Province, Binh Duong, Vietnam, ³Medical and Pharmaceutical University of Ho Chi Minh City, Ho Chi Minh City, Vietnam

Introduction

Absolute glaucoma caused blind and pain. Micropulse Transscleral diode laser cyclophotocoagulation (MP-TSCPC) has just used to treat glaucoma as MIGS. The purpose of this study to evaluate the effectiveness of lowering intraocular pressure and the safety of Micropulse Transscleral diode laser cyclophotocoagulation (MP-TSCPC) in absolute glaucoma patients.

Methods

A prospective interventional study was performed on 64 refractory glaucoma eyes from October 2020 to April 2021 at the Ho Chi Minh City Eye Hospital.

Results

Sixty four patients including 26 females and 38 males were recruited with the mean age 56.1 ± 2.1 . The mean IOP at pre- and post-operation was 45.9 ± 11.0 and 25.8 ± 13.8 mmHg, respectively. The average IOP reduced 42.4%, 33.5%, 39.1% and 45.5% from baseline after surgery at 1 week, 1 month, 3 months and 6 months (p value < 0.001). 93,7% of patients improved pain symptoms after MP-TSCPC. The mean number of anti-glaucoma medication was down from 3.5 ± 0.69 at the beginning to 1.6 ± 0.78 at the end of the study. No serious complications were recorded.

Conclusion

Micropulse Transscleral diode laser cyclophotocoagulation is an effective and safe method to lower intraocular pressure and relieve pain in absolute glaucoma.

References

1. Benhatchi N., Bensmail D., Lachkar Y. (2019) "Benefits of SubCyclo Laser Therapy Guided by High-frequency Ultrasound Biomicroscopy in Patients With Refractory Glaucoma". *J Glaucoma*, 28 (6), 535-539.
2. Garcia G. A., Nguyen C. V., Yelenskiy A., Akiyama G., McKnight B., Chopra V., et al. (2019) "Micropulse Transscleral Diode Laser Cyclophotocoagulation in Refractory Glaucoma: Short-Term Efficacy, Safety, and Impact of Surgical History on Outcomes". *Ophthalmol Glaucoma*, 2 (6), 402-412
3. Zaarour K., Abdelmassih Y., Arej N., Cherfan G., Tomey K. F., Khoueir Z. (2019) "Outcomes of Micropulse Transscleral Cyclophotocoagulation in Uncontrolled Glaucoma Patients". *J Glaucoma*, 28 (3), 270-275.

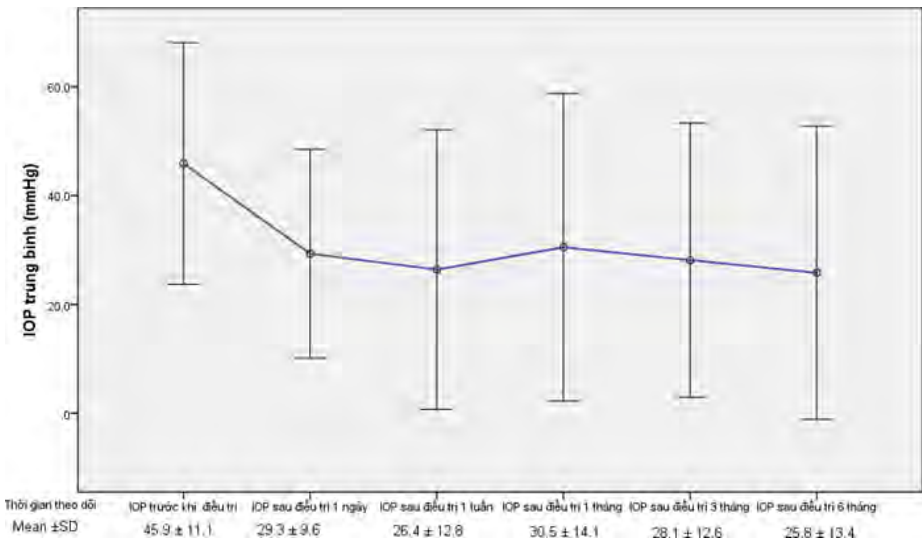


Figure 1. The curve shows mean IOP progression in mmHg over time. The mean IOP

at admission was 45.9 ± 11.1 mmHg, decreased to 26.4 ± 12.8 mmHg (42.4% reduction) after 1 week, 30.5 ± 14.1 mmHg (33.5% reduction) after 1 month, 28.1 ± 12.6 mmHg (39.1% reduction) after 3 months, 25.8 ± 13.4 mmHg (45.5% reduction) after 6 months with $p < 0.001$ in follow-up visits.

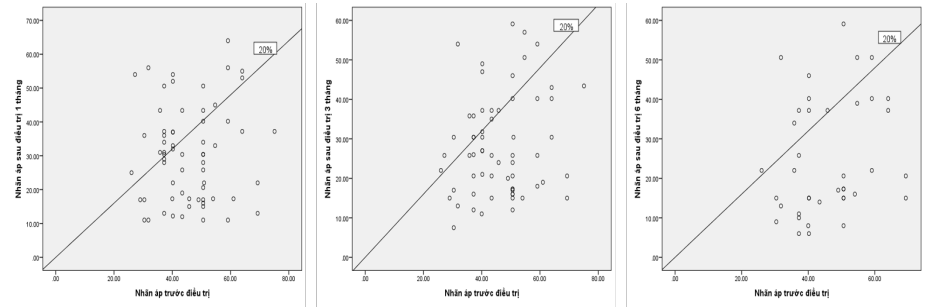


Figure 2. Scatter chart comparing IOP at baseline with them at 1 month, 3 months and 6 months after treatment.

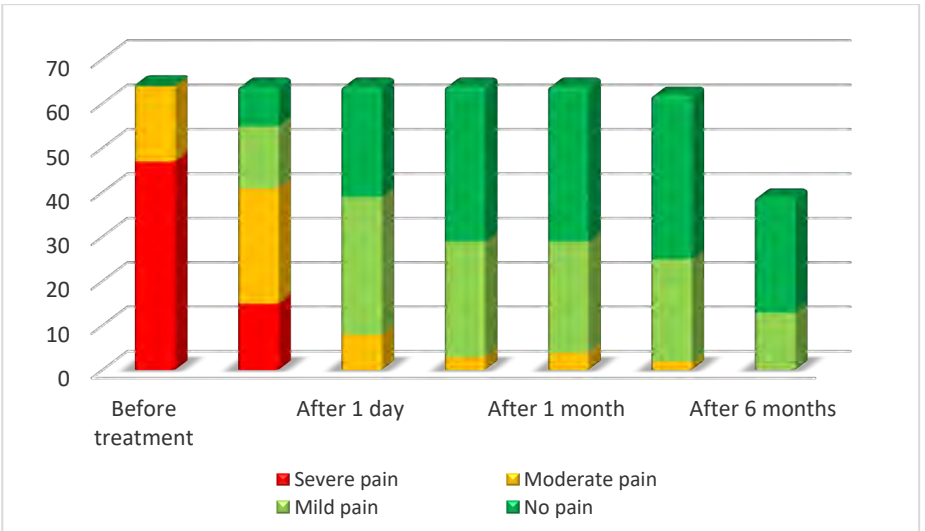


Figure 3. Changes in level of pain pre- and post- treatment.

Measurements of peripapillary retinal vessel after acute primary angle closure by OCT Angiography

Pham Thi Ngoc Tien², Thuy Tien P¹, Vo Thi Hoang Lan²

¹Ho Chi Minh City Eye Hospital, Ho Chi Minh City, Viet Nam, ²University of Medicine and Pharmacy at Ho Chi Minh City, Ho Chi Minh City, Vietnam

Introduction

Studies in literature were proven that the perfusion of peripapillary retinal vessel decreased in glaucoma eyes. The aim of this study is to investigate whether the vessel density and flux index in APAC eyes were decreased after acute primary angle closure (APAC) or any relationship between indices and the IOP or attack period.

Methods

A cross-sectional study was implemented at Glaucoma Department, Eye Hospital HCMC in 2021. Eyes suffered APAC after controlled IOP by glaucoma medicines were evaluated the difference of the density and flux index of vessels by optical coherence tomography angiography (OCTA); compared to the fellow eyes.

Results

Twenty-two eyes with unilateral APAC were enrolled in a study. The average attack period was 5 days (1-21 days). The IOP of these eyes were 41.6 ± 9.4 mmHg and 13.2 ± 4.8 mmHg at the presentation and at the imaging, respectively. There was statistically significant difference of peripapillary retinal vessel density between 42.9 ± 1.9 % of APAC eyes, and 45.8 ± 1.6 % of fellow ones ($p < 0.001$). However, no significant difference of peripapillary retinal vessel flux index was found between the attack and fellow eyes. Both indices were not correlated with either the IOP at presentation and at imaging, as well as attack period.

Conclusion

The peripapillary retinal vessel density of APAC eyes decreased after the acute attack even when the IOP was controlled. A lower retinal vessel density in APAC eyes was a noticeable sign to warn that these eyes might have had glaucoma progression and should be followed up in long-term.

References

1. Wang X., Jiang C., Kong X., et al. (2017), "Peripapillary retinal vessel density in eyes with acute primary angle closure: an optical coherence tomography angiography study", *Graefes Arch Clin Exp Ophthalmol*, 255(5), 1013-1018.
2. Moghimi S., SafiZadeh M., Fard M. A., et al. (2019), "Changes in Optic Nerve Head Vessel Density After Acute Primary Angle Closure Episode", *Invest Ophthalmol Vis Sci*, 60(2), 552-558.
3. Nie L., Xu J., Fu L., et al. (2021), "Changes in circumpapillary retinal vessel density after acute primary angle closure episode via OCT angiography", *Int Ophthalmol*, 41(7), 2389-2397.

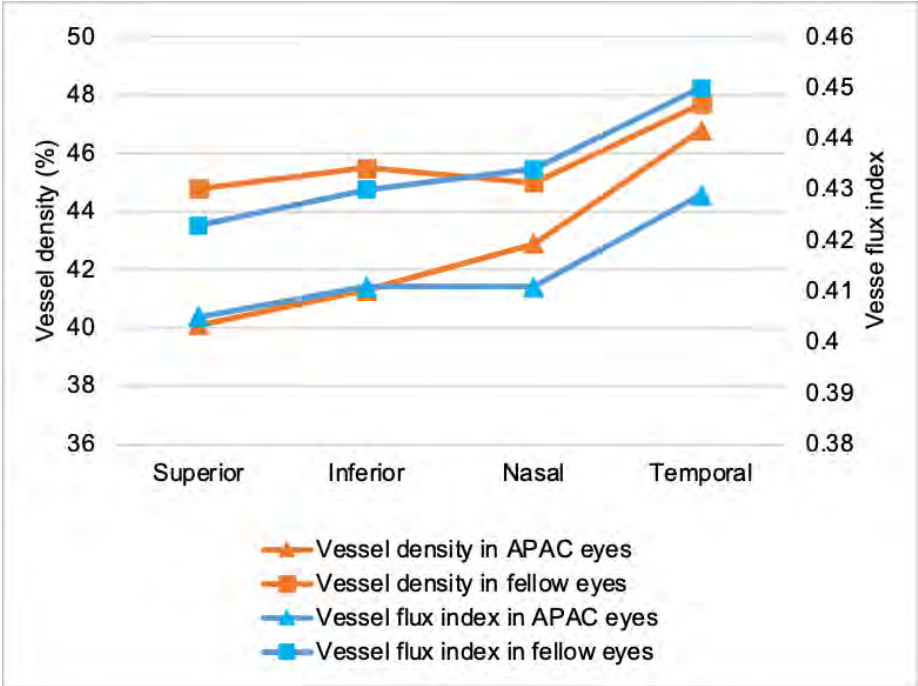


Figure 16: Values of peripapillary retinal vessel density and flux index in APAC and fellow eyes.

Association between Polymorphism in the Interleukin-18 and normal tension glaucoma

Wang C¹, Liang C¹

¹Taichung Veterans General Hospital, Taichung, Taiwan, China

Introduction

Recent laboratory evidence indicates that the inflammatory cytokine, interleukin-18 (IL-18), have adverse effects on normal tension glaucoma (NTG). Inheritance of the IL-18 (-607) polymorphism (the C allele), previously shown to increase IL-18 production, has been associated with an elevated risk of Alzheimer's disease. The neuronal injuries associated with Alzheimer's disease have a number of similarities with the optic nerve changes often seen with NTG. In this report we have explored the possible association between the IL-18 (-607) polymorphism and the development of NTG.

Methods

112 patients with NTG were recruited and compared with 117 healthy controls in Chinese population. Polymorphisms will be determined using sequence-specific primers (SSPs) and polymerase chain reaction (PCR). Patients and controls were genotyped for the C/A polymorphism at position -607 of the IL-18 gene promoter region.

Results

The frequency of the IL-18 (-607) C allele (61% vs. 50%, respectively; **p=0.02**) and were greater in NTG patients compared with controls. There is a higher risk of NTG associated with homozygosity for the IL-18 (-607) C allele (CC genotype) compared with the control population (CC genotype; 33% vs. 22%, respectively, **p=0.04**).

Conclusion

The IL-18 (-607) C allele polymorphism, previously shown to increase IL-18 gene expression, may be a risk factor in the development of NTG.

References

1. [Interleukin-18 produced by peripheral blood cells is increased in Alzheimer's disease and correlates with cognitive impairment](#). P Bossu et al. [Brain, Behavior, and Immunity](#). Volume 22, Issue 4, May 2008, Pages 487-492. doi: 10.1016/j.bbi.2007.10.001.
2. Interleukin-18 promoter polymorphisms and risk of late onset Alzheimer's disease. Jin-Tai Yu et al. [brain research](#) 2009 Feb 9;1253:169-75. doi: [10.1016/j.brainres.2008.11.083](#)
3. [Immune Responses in the Glaucomatous Retina: Regulation and Dynamics](#). Shestopalov VI et al. [Cells](#). 2021 Aug 3;10(8):1973. doi: 10.3390/cells10081973.

Table 1. Genotype and allele frequencies of IL-18 (-607)

	NTG N=112	Control N=117	Chi square	P-value
<u>IL-18 (-607)</u>				
Genotype				
C/C	37(33%)	26(22%)	6.22	0.04
C/A	62(55%)	65(56%)		
A/A	13(12%)	26(22%)		
Allele				
C	136(61%)	117(50%)	5.32	0.02
A	88(39%)	117(50%)		

NTG: normal tension glaucoma

Interleukin-1 α (-889) locus Polymorphism and serum IL-1 α levels related to Normal Tension Glaucoma Severity

Wang C¹

¹Taichung Veterans General Hospital, Taichung, Taiwan, China

Introduction

Factors other than elevated intraocular pressure are likely to have a role in the pathogenesis of glaucomatous optic neuropathy, particularly in individuals with normal tension glaucoma (NTG). Interleukin-1(IL-1), has been linked to the pathogenesis of glaucoma and may regulate RGC survival or death. The IL-1 α (-889) T allele has also been shown to increase the IL-1 α protein. We hypothesized that the IL-1 α (-889) polymorphism may be a genetic factor predisposing affected the severity of glaucoma. The aim of the present study is to evaluate IL-1 α polymorphism and serum IL-1 α levels as a potential risk factor related to the severity of NTG.

Methods

367 people with NTG in the Taiwanese population were enrolled. Patients were genotyped for the IL-1 α (-889) C/T polymorphism. Genomic DNA was amplified by a polymerase chain reaction, followed by the enzymatic restriction fragment length polymorphism technique. Serum IL-1 α levels was measured by ELISA. The associations between genotypes of IL-1 α (-889) C/T and the clinical parameters were calculated using a logistic regression.

Results

IL-1 α (-889) TT genotype in NTG patients was a significant association with larger C/D ratio , smaller RA and thinner RNFL ($p=0.04$) than IL-1 α (-889) CC patients. Serum IL-1 α levels were higher in advanced stages than in early-moderate stages. (6.76 ± 3.42 pg/ml v.s. 3.12 ± 2.53 pg/ml).

Conclusion

The IL-1 α (-889) TT genotype is associated with larger C/D ratio, smaller RA, and thinner RNFL than IL-1 α (-889) CC in NTG patients. IL-1 α (-889) C/T polymorphism and serum IL-1 α levels maybe associated with severity of NTG.

References

1. Association of Interleukin-1 gene clusters polymorphisms with primary open-angle glaucoma: a meta-analysis. Li J, Feng Y, Sung MS, Lee TH, Park SW. BMC Ophthalmol. 2017 Nov 28;17(1):218. doi: 10.1186/s12886-017-0616-y.
2. Multiplex cytokine analysis of aqueous humor in eyes with primary open-angle glaucoma, exfoliation glaucoma, and cataract. Takai Y, Tanito M, Ohira A. Invest Ophthalmol Vis Sci. 2012 Jan 25;53(1):241-7. doi: 10.1167/iovs.11-8434.

Table 1. Genotyp-Phenotype analysis of IL-1 α (-889)with NTG

NTG Phenotype	IL-1 α (-889)			P-value	Post hoc analysis*
	CC	CT	TT		
mean age (years)					
at diagnosis	42.1 \pm 9.5	43.7 \pm 8.9	42.7 \pm 9.9	0.32	
at inclusion	51.8 \pm 10.5	53.1 \pm 10.8	52.1 \pm 10.8	0.47	
CCT (u)	543.1 \pm 25.5	554.7 \pm 28.9	558.7 \pm 27.9	0.45	
IOP (mmHg)	16.1 \pm 3.5	16.7 \pm 2.8	16.9 \pm 2.4	0.18	
Serum IL-1 α (pg/ml)	4.61 \pm 3.42	4.98 \pm 3.32	6.98 \pm 3.42	0.051	
VF indices					
MD(dB)	-8.9 \pm 6.5	-9.1 \pm 7.5	-12.1 \pm 7.5	0.09	
PSD(dB)	6.6 \pm 2.	6.7 \pm .8	9.1 \pm 2.	0.06	
RNFL thickness(u)	87.6 \pm 22.8	88.1 \pm 21.7	70.1 \pm 21.7	0.04	TT < CC
Optic disc size (mm ²)	2.11 \pm 0.58	2.01 \pm 0.44	2.14 \pm 0.46	0.89	
Rim area (mm ²)	1.49 \pm 0.38	1.38 \pm 0.30	1.28 \pm 0.30	0.04	TT < CC
Cup/Disc (C/D) ratio	0.51 \pm 0.21	0.60 \pm 0.18	0.71 \pm 0.21	0.04	CC < TT
NTG: normal tension glaucoma; CCT: central corneal thickness					
IOP: intraocular pressure; VF:visual field; MD: mean deviation					
PSD: pattern standard deviation; RNFL: retinal nerve fiber layer					
*Comparison was performed using one-way analysis of variance with post hoc Scheffe's multiple comparison testing.					

Table 2. Genotype ,allele frequencies and serum levels of IL-1 α (-889) C/T in NTG, according to C/D ratio

	C/D 0.7-1.0	C/D 0.3-0.7	Odds ratio (95% CI)	P-value		
<u>IL-1α (-889)</u>						
<u>Genotype</u>						
C/C	107(59.1%)	133(71.5%)	1			
C/T	62(34.3%)	48(25.8%)	1.6(1.02~2.52)	0.04		
T/T	12(6.6%)	5(2.7%)	2.98(1.01~8.76)	0.04		
<u>Allele</u>						
C	276(76.2%)	314(84.4%)	1			
T	86(23.8%)	58(15.6%)	1.69(1.16~2.44)	0.006		
Serum IL-1 α (pg/ml)	6.76 \pm 3.42	3.12 \pm 2.53		0.05		
VF mean deviation	-16.9 \pm 5.5	-7.1 \pm 5.5		0.008		
VF PSD	11.9 \pm 3.5	5.1 \pm 2.5		0.01		
RNFL thickness (u)	60.6 \pm 24.9	89.1 \pm 24.8		0.009		
VF: visual field; PSD: pattern standard deviation; RNFL: retinal nerve fiber layer						

Prompt Primary Cyclophotocoagulation with Subsequent Aqueous Shunt as Needed for Neovascular Glaucoma with Synechial Angle Closure

Wang J¹, Qiu M¹

¹UChicago Medicine, Department of Ophthalmology and Visual Science, Chicago, United States

Introduction

In acute NVG, implanting an aqueous shunt into eyes with active anterior segment neovascularization increases bleeding-related complications. Prompt anti-VEGF rapidly regresses NV but is ineffective at lowering IOP when the angle is already synechially closed. This case series describes a single surgeon's experience utilizing prompt CPC with anti-VEGF and subsequent aqueous shunt as needed in NVG eyes with synechial angle closure, regardless of visual potential.

Methods

A retrospective chart review was performed for NVG patients with uncontrolled IOP, active NV, a synechially closed angle, no contraindications to anti-VEGF, CPC within 3 days of presentation, and at least 6 months of follow-up.

Results

Seven patients (3 male, 4 female, all African-American) with mean age 63.9 years were included. Underlying etiologies were PDR(N=3), CRVO(N=3), and chronic RD(N=1). All patients received intravitreal anti-VEGF on the day of presentation or within 3 days during CPC. Five patients did not require subsequent aqueous shunts through a mean follow-up of 14.8 months; most recent visual acuities ranged from 20/50 to LP, and IOPs ranged from 4-20mmHg on 0-3 IOP-lowering medications. Two patients requiring tubes had resolution of active anterior segment NV by the time of surgery. At most recent follow-up (26 and 7 months), visual acuities were 20/40 and 20/150 with normal IOP. No eyes developed uncontrolled inflammation, macular edema, or phthisis.

Conclusion

Prompt primary CPC within 3 days, with prior or concurrent anti-VEGF, is an effective strategy to immediately lower IOP in NVG eyes with active anterior segment NV and synechially closed angles, regardless of visual potential. If IOP becomes uncontrolled later, an aqueous shunt can be implanted in a controlled setting after active NV regression.

Table 1. Demographics, pre-operative clinical characteristics, and post-operative outcomes in NVG patients treated with prompt primary cyclophotocoagulation and as needed subsequent aqueous shunt

Age (yrs)	Sex	Race	Etiology	Presenting VA	Presenting IOP (mmHg)	Time btw presentation and Anti-VEGF #1	Time btw presentation and CPC (days)	IOP and # of medications within 1 week of CPC	# of anti-VEGF injections since presentation	# of PRP lasers since presentation	Time btw CPC and tube (wks)	IOP and # of medications prompting tube	BCVA at last follow-up	IOP, # of medications, and follow up duration
61	M	Black	Chronic RD	HM	36	0	3	23mmHg on 4 meds	1	0	—	—	HM	5mmHg on 0 meds at 18 months
68	F	Black	PDR	20/300	60	0	2	3mmHg on 0 meds	4	1	—	—	20/50	20mmHg on 0 meds at 7 months
68	F	Black	PDR	HM	38	3	3	16mmHg on 3 meds	1	1	—	—	LP	4 mmHg on 0 meds at 22 months
74	M	Black	CRVO	LP	55	0	0	6mmHg on 1 med	6	0	—	—	LP	4mmHg on 1 med at 21 months
68	F	Black	CRVO	HM	50	2	2	7mmHg on 4 meds	5	1	—	—	CF	11mmHg on 3 meds at 6 months
50	M	Black	PDR	HM	71	1	1	15mmHg on 0 meds	10	5	5 A	59 mmHg on 4 meds	20/40	23mmHg on 3 meds at 26 months
58	F	Black	CRVO	20/300	49	0	2	20mmHg on 0 meds	6	1	1 lb	27 mmHg on 0 meds	20/150	6mmHg on 0 meds at 7 months

IOP = intraocular pressure; VA = visual acuity; CPC = cyclophotocoagulation; anti-VEGF = anti-vascular endothelial growth factor; PRP = panretinal photocoagulation; BCVA = best corrected visual acuity; medications = IOP-lower medications

^A indicates Ahmed

^B indicates Baerveldt

Note: Both tubes were placed in the sulcus, with simultaneous phaco in the patient receiving the Ahmed to facilitate sulcus placement.

Visual field pattern of glaucoma patients in Yogyakarta: a one-year retrospective study

[Aufaa Shafira Widowati¹](#), Retno Ekantini¹, Tatang Talka Gani¹, Krisna Dwi Purnomo Jati¹

¹Department of Ophthalmology, Faculty of Medicine, Nursing, and Public Health, Universitas Gadjah Mada, Indonesia

Introduction

Glaucoma is defined as neuropathy of the optical nerve with visible optic disc cupping and a corresponding visual loss pattern. This study aims to collect and analyse the clinical characteristics, visual field parameters and patterns of glaucoma patients at a university hospital in 2021.

Methods

Data of glaucoma patients during 2021 are collected from the medical records, including their medical history, ophthalmological status, diagnosis, and HFA results. The diagnosis of glaucoma was done by glaucoma specialists in the ophthalmology outpatient clinic. Naïve and treated patients were included in this study.

Results

A total of 384 patients with glaucoma was identified during the study period (January-December 2021). 233 (60,68%) of the patients were male, with the average age of $44,9 \pm 19,2$ years. Mean intraocular pressure was $14,84 \pm 5,06$ mmHg. The most frequent subtype observed was primary open angle glaucoma (52,08%), normal tension glaucoma (24,12%), and juvenile open angle glaucoma (8,85%). 192 (50%) patients were found to have normal HFA results, 44 (11,46%) with generalized depression, and 40 (10,42%) with tunnel vision. In normal-tension and high-tension group, age was found to be negatively correlated with MD ($-0,161$ [p-value: 0,001] and $-0,228$ [p-value: 0,000]) and positively correlated with PSD ($0,081$ [p-value: 0,002] and $0,041$ [p-value: 0,000]).

Conclusion

Among the patients diagnosed with glaucoma, half of them presented with normal visual field pattern which may be accounted to the early diagnosis and treatment. Age was found to be significantly correlated with MD and PSD on both the normal-tension and high-tension group.

Reference

3. Yokoyama, Y., Maruyama, K., Konno, H. *et al.* Characteristics of patients with primary open angle glaucoma and normal tension glaucoma at a university hospital: a cross-sectional retrospective study. *BMC Res Notes* **8**, 360 (2015). <https://doi.org/10.1186/s13104-015-1339-x>

Table 1. Demographic profile of subjects

	Sex (%)		Age	IOP	UCVA	SEq	BCVA	MD	PSD
	M	F							
NTG	55 (59,1)	38 (41)	39,8 ± 16,3	13,1 ± 3,6	0,5 ± 0,3	-0,9 ± 2,1	0,8 ± 0,3	-6,8 ± 7,7	4,5 ± 4,1
Ocular Hypertension	4 (80)	1 (20)	39,4 ± 12	18,0 ± 2,3	0,5 ± 0,2	-0,2 ± 0,4	0,7 ± 0,2	-4,3 ± 4,5	2,8 ± 1,9
CACG	10 (90,9)	1 (9,1)	54,18 ± 17,2	11,1 ± 2,1	0,4 ± 0,2	-0,6 ± 2,0	0,6 ± 0,3	-12,4 ± 12,2	5,2 ± 2,9
POAG	116 (58)	84 (42)	49,8 ± 18,1	15,2 ± 4,8	0,4 ± 0,3	-0,8 ± 2,3	0,7 ± 0,3	-12,3 ± 11,6	5,0 ± 3,7
PACG	12 (70,6)	5 (29,4)	58,8 ± 8,4	16,5 ± 8,9	0,3 ± 0,3	0,23 ± 1,1	0,4 ± 0,3	-21,1 ± 11,5	6,2 ± 3,6
JOAG	21 (61,8)	13 (38,2)	21,3 ± 12,5	15,7 ± 4,5	0,6 ± 0,4	-1,7 ± 2,0	0,9 ± 0,2	-6,9 ± 8,9	4,3 ± 3,9
SACG	3 (60)	2 (40)	49,4 ± 19,0	11,9 ± 2,5	0,3 ± 0,3	0,0 ± 0,0	0,4 ± 0,4	-16,4 ± 7,7	7,0 ± 4,1
SOAG	12 (63,2)	7 (36,8)	42,16 ± 20,0	18,5 ± 6,8	0,4 ± 0,4	-0,9 ± 1,6	0,6 ± 0,4	-11,6 ± 11,1	4,4 ± 3,8
Total	233 (60,7)	151 (39,3)	44,87 ± 19,2	14,8 ± 5,1	0,4 ± 0,3	-0,8 ± 2,1	0,7 ± 0,3	-10,8 ± 11	4,8 ± 3,8

NTG: normotension glaucoma, CACG: chronic angle closure glaucoma, POAG: primary open angle glaucoma, PACG: primary angle closure glaucoma, JOAG:

juvenile open angle glaucoma, SACG: secondary angle closure glaucoma, SOAG: secondary open angle glaucoma

Table 2. Visual field pattern by diagnosis

	Normal	Advanced visual field loss (%)	Arcuate		Superior & Inferior	Superior & Nasal Step	Superior & Rim Artefact	Nasal Step		Generalized Depression	Rim Artefact	Tunnel Vision (%)	Central Defect (%)
			Superior	Inferior				Only	Rim Artefact				
NTG	57	1	8	4	7	0	0	3	0	2	7	3	1
CACG	4	0	1	1	0	0	0	1	0	4	0	0	0
Ocular Hypertension	4	0	0	1	0	0	0	0	0	0	0	0	0
POAG	90	2	9	9	18	1	1	6	3	27	6	28	0
PACG	3	0	0	1	1	0	0	0	0	6	0	6	0
JOAG	24	0	2	0	4	0	0	1	0	1	0	2	0
SACG	1	0	1	0	1	0	0	1	0	1	0	0	0
SOAG	9	0	0	0	3	0	0	2	1	3	0	1	0

NTG: normotension glaucoma, CACG: chronic angle closure glaucoma, POAG: primary open angle glaucoma, PACG: primary angle closure glaucoma, JOAG: juvenile open angle glaucoma, SACG: secondary angle closure glaucoma, SOAG: secondary open angle glaucoma

Table 3. Correlation of age and MD in normal-tension and high-tension groups

		Mean \pm SD	Correlation Coefficient	P-value
Normal-tension	MD	-6,84 \pm 7,70	-0,161	0,001
	Age	39,82 \pm 16,27		
High-tension	MD	-12,05 \pm 11,55	-0,228	0,000
	Age	46,48 \pm 19,73		

MD: mean deviation

Table 4. Correlation of age and PSD in normal-tension and high-tension groups

		Mean \pm SD	Correlation Coefficient	P-value
Normal-tension	PSD	4,50 \pm 4,12	0,081	0,002
	Age	39,82 \pm 16,27		
High-tension	PSD	4,93 \pm 3,70	0,041	0,000
	Age	46,48 \pm 19,73		

PSD: pattern standard deviation

The effect of intravitreal n-methyl-d-aspartate injection on caspase-3 expression in retinal ganglion cell

Widyarini A¹

¹Ophthalmology Department, Faculty Medicine Diponegoro University, Indonesia, Semarang, Indonesia

Introduction

Apoptosis of Retinal Ganglion Cell (RGC) associated with N-methyl-D-aspartate (NMDA)-mediated excitotoxicity, a common pathway for glaucomatous neuropathy. Glutamate activates NMDA receptors leading to intracellular Ca^{2+} excess and the caspase. The purpose of this study was to evaluate the effect of intravitreal NMDA injection on caspase-3 expression in RGC rats.

Methods

Experimental study of male Wistar rats were injected with intravitreal NMDA at doses of 80 nmol and 160 nmol for 8 hours, 24 hours and 72 hours compared with the control group. All groups were analyzed with immunohistochemistry based on the intensity and presentation of caspase-3 expression for statistically significant results at p value < 0.05 .

Results

Group NMDA 80 nmol and 160 nmol showed caspase-3 expression intensity in 8 hours compared to control. The percentage of staining, also has significantly difference between NMDA doses of 80 nmol, 160 nmol in 16 hours and 72 hours as compared to control. (p value $< 0,05$)

Conclusion

Intravitreal dose-dependent injection of NMDA caused caspase-3 expression in RGCs of Wistar mice. NMDA as a therapeutic target can be used to suppress RGC apoptosis.

References

1. Cheng WS, Lin IH, Feng KM, et al. Neuroprotective Effects of Exogenous Erythropoietin in Wistar Rats by Downregulating Apoptotic Factors to Attenuate NMDA-Mediated Retinal Ganglion Cells Death. PLoS One [Internet]. 2020.
2. Maekawa, S., Sato, K., Fujita, K. et al. The neuroprotective effect of hesperidin in NMDA-induced retinal injury acts by suppressing oxidative stress and excessive calpain activation. Sci Rep 7, 6885 (2017).

Comparison of the Efficacy and Safety Between Combined Trabeculectomy with Phacoemulsification and Trabeculectomy in Advanced Primary Glaucoma: 6 Months Follow Up

[Wiyogo W¹](#)

¹JEC Eye Hospital & Clinics, Jakarta, Indonesia

Introduction

To evaluate the efficacy and safety, after trabeculectomy compared with combined trabeculectomy-phacoemulsification in Indonesia eyes with late-advanced stage primary glaucoma.

Methods

A retrospective study was performed by reviewing existing medical records. Data collection included IOP, visual acuity, visual field, optic disc ratio, retinal nerve fiber layer thickness, and the use of IOP lowering medication preoperatively and up to 6 months post operatively. Complications, if any, were also noted

Results

Data from 55 eyes of 47 subjects which underwent trabeculectomy (group 1) were analyzed and compared to 47 eyes of 40 subjects which underwent combined trabeculectomy-phacoemulsification (group 2). Majority of the subjects were male in both groups with mean age of 62.60 ± 9.95 years.

Mean IOP (mmHg) in group 1 was 35.64 ± 12.35 at baseline and 13.18 ± 5.20 after mean follow up of 6 months, while in group 2 was 29.08 ± 11.39 at base line and 13.89 ± 4.17 at last follow up. IOP reductions of $\geq 20\%$ were achieved in 53/55 eyes (96.3%) in group 1 and 40/47 eyes (85.1%) in group 2. There was a significant difference in the mean IOP reduction in group 2 (54%) compared to group 1 (42%) ($p < 0.05$). Mean medication used in group 1 declined from 3.35 ± 1.25 medications to 0.76 ± 1.12 at last follow-up ($p < 0.0001$) while in group 2 declined from 3.91 ± 1.25 medications to 1.17 ± 1.19 at last follow-up ($p < 0.0001$). Mean IOP lowering medication reduction were 34% and 23% for group 2 and group 1, respectively, but

there was no significant difference between them ($p=0.110$). No vision-threatening complications were observed in both groups

Conclusions

Combined procedure of trabeculectomy-phacoemulsification provides better results in terms of IOP reduction and no wipe-out complication has been reported during follow-up.

References

1. Ahmadzadeh A, Kessel L, Subhi Y, Bach-Holm D. Comparative Efficacy of Phacotrabeculectomy versus Trabeculectomy with or without Later Phacoemulsification: A Systematic Review with Meta-Analyses. *J Ophthalmol*. 2021 Feb 13;2021:6682534. doi: 10.1155/2021/6682534. PMID: 33628478; PMCID: PMC7896844.
2. Lam D, Wechsler DZ. Five-Year Outcomes of Trabeculectomy and Phacotrabeculectomy. *Cureus*. 2021 Jan 27;13(1):e12950. doi: 10.7759/cureus.12950. PMID: 33659110; PMCID: PMC7920213.

The Efficacy and Safety of Trabeculectomy in Late Advanced Stage Primary Glaucoma : 6 Months Follow Up

Wiyogo W¹

¹JEC Eye Hospital & Clinics, Jakarta, Indonesia

Introduction

To evaluate the efficacy and safety, described in intraocular pressure (IOP) and vision-threatening complication, respectively, after trabeculectomy in adults with late-advanced stage primary glaucoma in Indonesia.

Methods

A retrospective study was performed by reviewing existing medical records. Data collection included IOP, visual acuity, visual field, optic disc ratio, retinal nerve fiber layer thickness, and the use of IOP lowering medication preoperatively and up to 6 months post operatively. Complications, if any, were also noted. Paired T tests were utilized to analyze the result.

Results

Data from 55 eyes of 47 subjects were analyzed. Majority of the subjects were male (65.9%/34.1%) with mean age of 56.45 ± 13.52 years and most had primary open angle glaucoma (53.2%). The mean visual field deviation (dB) was -24.33 ± 7.05 at baseline and -25.16 ± 6.52 post operatively. Mean IOP (mmHg) was 35.64 ± 12.35 at baseline and 13.18 ± 5.20 after mean follow up of 6 months. IOP reductions of $\geq 20\%$ were achieved in 53/55 eyes (96.3%) with mean IOP reduction of 37%. Mean medication use declined from 3.35 ± 1.25 medications per eye at baseline to 0.76 ± 1.12 at last follow-up ($p < 0.0001$); and mean reduction of IOP lowering medication was 22% after 6 months follow up. Thirty-five out of 55 eyes (64%) were medication-free at last follow-up. No vision-threatening complications were observed.

Conclusions

Trabeculectomy is a safe procedure to perform in late-advanced stage primary glaucoma with a significant decrease of IOP and reduction of IOP lowering medication. In most eyes, this procedure provides medication independence with statistically and clinically significant IOP reductions with no wipe-out complications has been reported.

References

1. Pantalon A, Feraru C, Tarcoveanu F, Chiselita D. Success of Primary Trabeculectomy in Advanced Open Angle Glaucoma. *Clin Ophthalmol*. 2021;15:2219-2229 <https://doi.org/10.2147/OPTH.S308228>
2. Elghonemy HM, Dewedar AS, Nader M, Shaban NH. Trabeculectomy outcomes for patients with advanced glaucoma. *J Med Sci Res* 2020;3:176-80. <http://jmsr.eg.net/text.asp?2020/3/3/176/297044>

Micropulse Laser Trabeculoplasty in Asian Patients

Leong M¹, Fang S¹, Gan E¹, Woo W¹

¹International Specialist Eye Centre (ISEC), Kuala Lumpur, Malaysia

Introduction

To report the efficacy of Micropulse Laser Trabeculoplasty (MLT) in Asian patients.

Methods

Patients with ocular hypertension (OHT) or open angle glaucoma (OAG) undergoing MLT between July 2020 and July 2021 at a single Malaysian Ophthalmology unit (International Specialist Eye Centre KL) were included in this retrospective study. Patients with a history of laser trabeculoplasty or glaucoma surgery were excluded.

360-degree MLT was performed with IQ 577nm™ yellow laser (Iridex Corp, USA) with settings at 1000mw, 15% duty cycle, 300 millisecond duration and 300 µm spot size.

Patients were seen at week 1, weeks 4-6 and between 6-9 months. Treatment success was defined as IOP reduction $\geq 20\%$ or $\geq 3\text{mmHg}$ from baseline¹.

Statistical analysis was performed using JASP v.0.16 (JASP Team 2021).

Results

66 eyes of 43 patients were included in the study.

Mean age was 60.5 (± 12.7) years, with a 1:1 male to female ratio. 72.1% were Chinese patients, with Japanese (14.0%), South Indian (11.6%) and South Korean (2.3%) patients also included.

Mean baseline IOP was 22.1mmHg with 1.97 drops used pre-treatment.

At 1 week, mean IOP was reduced by 23.7% from baseline (n=53, $p<0.001$). IOP reduction at 4-6 weeks was 23.1% (n=54, $p<0.001$) and 26.9% at 6-9 months (n=44, $p<0.001$). No IOP spikes were noted.

39 of 66 (59.1%) eyes achieved a reduction in IOP $\geq 20\%$ or $\geq 3\text{mmHg}$ from baseline at 6-9 months. Mean glaucoma drops reduced from 1.97 to 1.64 at 6-9 months ($p=0.002$).

10 of 66 (15.2%) eyes required further glaucoma intervention.

Conclusion

MLT is effective in reducing IOP and number of drops in Asian patients with OHT or OAG.

IOP reduction is noticeable from week 1 and sustained at 6-9 months. Our results are comparable with previous published data in a similar population².

References

1. Abramowitz B, Chadha N, Kouchouk A, Alhabshan R, Belyea DA, Lamba T. Selective laser trabeculoplasty vs micropulse laser trabeculoplasty in open-angle glaucoma. *Clin Ophthalmol (Auckland, NZ)*. 2018;12:1599–1604. doi:10.2147/OPTH.S1671029
2. Lee JW, Yau GS, Yick DW, Yuen CY. MicroPulse laser trabeculoplasty for the treatment of open-angle glaucoma. *Medicine (Baltimore)*. 2015;94(49):e2075. doi:10.1097/MD.00000000000002075

Crouzon's Syndrome: A rare case report

Woon T¹

¹Hospital Pakar Sultanah Fatimah, Muar, Malaysia

Introduction

Crouzon's Syndrome is a rare autosomal dominant disorder among craniosynostosis group with characteristic of craniofacial malformations and accounting for approximately 4.5 % of all cases. It is characterized by a triad of craniosynostosis, exophthalmos, and midface hypoplasia. Mutation of the fibroblast growth factor receptor-2 gene (FGFR-2) is responsible for the occurrence and resulting in premature closure of the suture lines. This paper reports the diagnosis of this rare syndrome in a 6 year old boy based on clinical and radiographical features. Prompt and timely management of the syndrome has enabled this patient to lead a normal life despite the syndrome.

Methods

A case report

Results

None

Conclusion

Crouzon's syndrome is a rare syndrome with characteristic facial features. Early diagnosis and optimal treatment should be given multidisciplinary to prevent late complications.

Keywords

Crouzon's syndrome, craniosynostosis, exophthalmos, maxillary hypoplasia

References

1. Cohen MM Jr. Craniosynostosis and syndromes with craniosynostosis: Incidence, genetics, penetrance, variability, and new syndrome updating. *Birth Defects Orig Artic Ser.* 1979;15:13–63.
2. Panigrahi I. Craniosynostosis genetics: The mystery unfolds. *Indian J Hum Genet.* 2011;17:48–53.
3. Reardon W, Winter RM, Rutland P, Pulleyn LJ, Jones BM, Malcolm S. Mutations in the fibroblast growth factor receptor 2 gene cause Crouzon syndrome. *Nat Genet.* 1994;8:98–103.
4. Cohen MM., Jr Craniosynostosis update 1987. *Am J Med Genet Suppl.* 1988;4:99–148.
5. Phupong V, Srichomthong C, Shotelersuk V. Prenatal exclusion of Crouzon syndrome by mutation analysis of FGFR2. *Southeast Asian J Trop Med Public Health.* 2004;35:977–9.

Orbital apex syndrome caused by invasive sino-orbital Aspergillosis: A case report

Woon T¹

¹Hospital Pakar Sultanah Fatimah, Muar, Muar, Malaysia

Introduction

Invasive orbital aspergillosis is a rare clinical entity in immunocompetent patients and often misdiagnosed. The ocular morbidity and mortality is avoided with timely treatment. We present the clinical features, treatment and outcome is a 67 year old male patient who is diagnosed for having orbital apex syndrome of the right apex of the orbit. CECT scan showed infiltrative radio-opacification of the right superior orbital fissure extend to orbital apex and orbit. There was bony erosion around right sphenoid and right posterior ethmoid. An endoscopy biopsy was performed and showed Aspergillosis spp. Thus, Intravenous, retrobulbar and Amphotericin B douching was administered on admission. The enhancing lesion was smaller after treatment. However, his condition worsened after he defaulted treatment for one month. MRI showed intracranial extension and emergency right orbital exenteration with endoscopic debridement was conducted. Unfortunately, he passed away after one week due to poor performance status.

Methods

A case report

Results

None

Conclusion

Invasive sino-orbital Aspergillosis with brain involvement is rare. Early detection and continuous prompt treatment should be introduced to prevent ocular morbidity and mortality.

Keywords

Orbital apex syndrome, aspergillosis, fungal infection

References

1. Saksham Nahar, Ajay Kumar Pillai, J. Arun Kumar, Neha Goyal, Santosh Kumar Singh: Orbital Invasive Aspergillosis - A Rare Fungal Infection of Eye
https://www.ijss-sn.com/uploads/2/0/1/5/20153321/case_report_3.pdf

Management of ocular hypertension following intravitreal dexamethasone implant (Ozurdex)

[Xiao J¹](#), Qiu M¹

¹University Of Chicago Medicine, Chicago, United States

Introduction

Corticosteroids are a mainstay therapy for various ocular diseases, including retinal vein occlusions (RVO) and diabetic macular edema (DME). However, one well-established complication is steroid-induced ocular hypertension (OHT), predisposing to glaucoma. Thus, active investigation exists regarding steroid type and method of administration. Ozurdex is a sustained-release intravitreal implant that delivers dexamethasone, a corticosteroid, into the posterior chamber over months. Several studies have identified increased OHT following implantation. Compared to older intravitreal corticosteroids, such as triamcinolone, Ozurdex-induced OHT may require less invasive management. Nevertheless, the long-term efficacy and management of Ozurdex-related complications are not well-documented, especially using minimally-invasive glaucoma surgical techniques. Here, we examine progression of OHT following Ozurdex implantation and characterize its management at a single tertiary care academic center.

Methods

Medical chart review following 109 intravitreal Ozurdex implantations at a tertiary care academic center from January 2014 – January 2022. After excluding eyes diagnosed with neovascular glaucoma or with concurrent intravitreal administration of other corticosteroids, 57 implants (19 patients, 23 eyes) were included for analysis.

Results

Ozurdex implants were indicated for diabetic macular edema (63.2%), retinal vein occlusion (35.1%), and uveitis (1.8%). Ten (43.5%) eyes received single implant, while 13 eyes (56.5%) received multiple implants. Medical drops were initiated

following eight (13%) implants to control OHT. Selective laser trabeculoplasty (SLT) was performed in two (3.5%) cases. Surgical procedures were utilized in five (8.8%) cases, specifically two (3.5%) instances with Kahook Dual Blade goniotomy and three (5.3%) instances with gonioscopy-assisted transluminal trabeculotomy.

Conclusion

Associated OHT following Ozurdex implantation can be managed with several modalities depending on patient preferences and individual situation. Historically, eyes refractory to medical therapy received trabeculectomy or aqueous shunt. Here, we demonstrate that starting with SLT or minimally-invasive angle surgery may prove effective and/or delay interventions traditionally associated with greater risks.

Using tropicamide instead of cyclopentolate for pupil dilation in cataract surgery reduces incidence of post-operative intraocular pressure rise

Xuan R^{1,2}, Ong K^{1,2,3,4,5}

¹Royal North Shore Hospital, St Leonards, Australia, ²Northern Clinical School, University of Sydney, Sydney, Australia, ³Chatswood Private Hospital, Chatswood, Australia, ⁴Sydney Adventist Hospital, Sydney, Australia, ⁵Save Sight Institute, University of Sydney, Sydney, Australia

Introduction

Tropicamide, cyclopentolate and phenylephrine are commonly used to pre-operatively dilate the pupil for cataract surgery. Some surgeons may prefer the use of all three while others prefer a combination of the two. The aim of the study was to compare the incidence of intraocular pressure (IOP) elevation post cataract surgery between using shorter-acting tropicamide or longer-acting cyclopentolate.

Method

This retrospective, consecutive audit was conducted at a tertiary care centre in Sydney, Australia from November 2019 to March 2021. The two regimens used by ophthalmic surgeons in the department were (A) phenylephrine 1% and cyclopentolate 2.5% or (B) phenylephrine and tropicamide 1%. Electronic medical records of 200 patients (Group A, n=100; Group B, n=100) were retrospectively accessed to record pre- and day 1 post-operative IOP of patients who had undergone uncomplicated cataract operations. Patients with a history of glaucoma were excluded from the study.

Results

The percentage of patients with a higher IOP on day 1 post-op was 46% (n=46) in Group A and 32% (n=32) in Group B. The mean post-operative IOP and mean IOP

rise of patients in group A was higher than in Group B (14.4 ± 1.2 vs 13.1 ± 4.9 mmHg, 0.93 ± 1.1 mmHg $p=0.086$ vs 0.93 ± 1.1 mmHg $p=0.086$ respectively) A higher rise in mean IOP was detected in the operated eyes of patients who received cyclopentolate (1.17 ± 1.1 mmHg, $p=0.038$ vs 0.51 ± 0.9 mmHg, $p=0.28$). A significant mean IOP elevation in patients with a clinically significant post-op IOP (IOP ≥ 21 mmHg, $n=13$) and significant IOP rise (rise ≥ 8 mmHg, $n=12$) was detected in Group A (8.5 ± 4.4 mmHg, $p=0.0012$; 8.1 ± 6.8 , $p=0.024$).

Conclusions

Prolonged mydriasis and cycloplegia with Cyclopentolate has a higher incidence of IOP rise at day 1 post-op compared to using Tropicamide. This may be of low clinical relevance in a healthy eye but glaucomatous eyes and patients with poor circulation may be compromised by post-op IOP rise.

Declaration

The content of this submission has been submitted for presentation at the Royal Australian and New Zealand College of Ophthalmology Congress 2022

Table 1. Comparison of mean pre- and post-operative intraocular pressure rise in patients.

Descriptive	Mean pre-op IOP (mmHg)	Mean post-op IOP (mmHg)	Mean difference (mmHg)	IOP P value
Group A				
Operated eye (n=100)	13.3 ± 0.8	14.4 ± 1.2	1.17 ± 1.1	0.038
Non-operated eye (n=100)	12.9 ± 0.8	13.2 ± 0.7	0.24 ± 0.6	0.42
Difference in mean IOP difference			0.93 ± 1.1	0.086
<i>Subgroup</i>				

IOP ≥ 21 mmHg (n=13)	16.3 \pm 3.5	25.2 \pm 4.3	8.5 \pm 4.4	0.0012
IOP rise ≥ 8 mmHg (n=12)	12.5 \pm 3.0	20.6 \pm 6.4	8.1 \pm 6.8	0.024

Group B

Operated eye (n=100)	13.6 \pm 0.8	13.1 \pm 4.9	-0.51 \pm 0.9	0.28
Non-operated eye (n=100)	13.0 \pm 4.1	12.6 \pm 3.9	-0.39 \pm 0.6	0.23

Difference in mean IOP difference			0.12 \pm 0.9	0.78
-----------------------------------	--	--	----------------	------

Subgroup

IOP ≥ 21 mmHg (n=9)	13.1 \pm 4.3	22.6 \pm 1.4	9.4 \pm 4.0	0.11
IOP rise ≥ 8 mmHg (n=6)	11.3 \pm 2.4	24.2 \pm 5.0	11.3 \pm 2.4	0.049

Values are mean \pm standard deviation. IOP = intraocular pressure.

Characteristics of the primary angle-closure disease of the Young

Yadav S¹, Shapkal S¹, Singh A¹, Gupta V¹, Gupta S¹

¹AIIMS, New Delhi, India

Introduction

Angle-closure glaucoma (ACG) is primarily a disease of the elderly and is rare in the young population. We present the differences in biometry and angle parameters between the primary angle closure glaucoma of the young (ACGy) and angle closure suspect of the young (ACSy)

Methods

Patients diagnosed with ACGy and ACSy at ≤ 40 years with no secondary causes, or ocular pathology like microspherophakia. Investigations (biometry, anterior segment oct (ASOCT) and ultrasound bio-microscopy) were done. Based on these imaging modalities, Plateau iris (PI), Pseudo plateau iris (PPI) and exaggerated lens vault (ErLv) were identified as the causes of ACGy and ACSy.

Results

Of 69 eyes with angle closure disease in young (ACDy), mean age of onset was 30.79 ± 5.90 years. 51 eyes were ACGy and 18 were ACSy. In ACGy, PI was found in 8(15.7%), PPI in 18(35.2%), and ErLv in 25(49%) eyes of which 10 had nanophthalmos. In ACSy, PI was found in 1(5.55%) eye, PPI in 6(33.33%), and the ErLv in 11(61.11%) eyes.

Comparison of ASOCT parameters showed that mean relative lens vault, Iridotrabecular contact index% and Iridotrabecular contact area were significantly higher($p < 0.05$) in ACGy vs ACSy, whereas angle parameters like mean angle opening distance500, trabecular-iris space area500, trabecular iris angle500 were significantly($p < 0.05$) smaller in ACGy vs ACSy. Other parameters like axial length and anterior chamber depth, had no significant difference($P > 0.05$)

Conclusion

ACDy involves a large proportion of eyes with Plateau iris and pseudoplateau iris. Development of glaucoma in predisposed eyes involve development of greater lens vault and angle narrowing over time.

References

1. Ritch R, Chang BM, Liebmann JM. Angle closure in younger patients. *Ophthalmology*. 2003 Oct;110(10):1880-9. doi: 10.1016/S0161-6420(03)00563-3. PMID: 14522758.

Bleb-related infection after primary trabeculectomy

Yang H^{1,2}, Liu C^{2,3}, Chi S², Ko Y^{2,3}, Chen M^{2,3}, Kuang T^{2,3}, Chang Y^{2,3}

¹Taipei Veterans General Hospital Yuanshan and Suao Branch, , Taiwan,

²Department of Ophthalmology, Taipei Veterans General Hospital, Taipei, Taiwan,

³School of Medicine, National Yang Ming Chiao Tung University, Taipei, Taiwan

Introduction

Patients who receive trabeculectomy carry a lifelong risk of bleb-related infection (BRI). Though it was believed that the introduction of intra-operative antimetabolite increased the rate of BRI, recent studies have shown a decreasing trend of infection incidence. Risk factors for BRI varied according to study design. Herein, we conducted the retrospective study to determine the incidence of and risk factors for BRI in patients who had received primary trabeculectomy augmented with mitomycin C.

Methods

We reviewed consecutive patients who had received primary trabeculectomy in Taipei Veterans General Hospital between 1993 and 2021. Demographic, clinical characteristics of patients before, during, and after surgery, the time interval between surgery and infection onset, clinical manifestations, and visual outcomes of patients with BRI were recorded. The cumulative incidence of BRI was estimated using the Kaplan–Meier method. A Cox proportional hazards model was used to explore factors associated with BRI.

Results

In total, 1663 eyes were postoperatively followed up for 94.6±65.2 months. The cumulative incidence of BRI was 1.86 per 1000 person-years. Among 24 (1.44%) BRI patients, 6 (0.36%) patients developed endophthalmitis. Most common chief complains were red eye and ocular pain. Wound manipulation, high myopia, and hyperlipidaemia were significantly associated with BRI in a multivariate analysis. In the subgroup of wound manipulation, wound manipulation for bleb at risk was

associated with a higher risk for BRI than wound manipulation for intraocular pressure control, hypotony and bleb leak. Compared with eyes with blebitis, the endophthalmitis eyes had a higher proportion of hyperlipidaemia.

Conclusion

Risk factors for BRI after trabeculectomy include wound manipulation, high myopia, and hyperlipidaemia. Considering myopia is increasingly prevalent throughout the world and is a risk factor for glaucoma, the lifelong risk of BRI after trabeculectomy in eyes with high myopia warrants the attention of ophthalmologists.

Prolapsed of eye globe following vigorous crying in Antley-Bixler syndrome child.

Yelumalai M¹, Yaakub A¹, Wan Hitam W¹

¹Department of Ophthalmology and Visual Science, School of Medical Sciences, Universiti Sains Malaysia, Kota Bharu, Malaysia

Introduction

Antley-Bixler syndrome (ABS) is a rare genetic disorder that can cause structural changes of the skull, bones of the face and other skeletal abnormalities. It is disorder with premature closure of cranial sutures. It is a rare genetic disorder which is an autosomal dominant and autosomal recessive inheritance which will results craniosynostosis. Antley-Bixler syndromic child has mid face hypoplasia, humeroradial synostosis, bowing of femora, bilateral eye proptosis, low-set or unusually formed ears, choanal atresia or stenosis and urogenital abnormalities.

Case report

We are reporting a 2-year-old baby boy with Antley- Bixler syndrome with SCN5A mutation. He has bilateral choanal stenosis, high arched palate, bifid uvulva, bilateral eye proptosis, bilateral ear canal atresia, mild ectopic anus, myelomeningocele with hydrocephalus, capillary hemangioma and congenital talipes equinovarus. He presented with left eye prolapsed from orbital cavity secondary to vigorous crying. Manual reposition of prolapsed eye into orbital cavity was successfully attempted under sedation. However patient's proptosis persisted as it was due to underlying craniosynostosis.

Keywords

Antley-Bixler syndrome, craniocytosis, proptosis

Trichomegaly of eyelashes secondary to Erlotinib

[Yelumalai M](#)¹, [Yaakub A](#)¹, [Ahmad Kasah N](#)², [Mohd Marzuki H](#)²

¹Department of Ophthalmology and Visual Science, School of Medical Sciences, Universiti Sains Malaysia, 16150 Kota Bharu, Malaysia, ²Department of Ophthalmology, Hospital Sultanah Nurzahirah, 20400 Kuala Terengganu, Malaysia

Introduction

Erlotinib is an inhibitor of the epidermal growth factor receptor (EGFR) tyrosine kinase that is used in the treatment of non-small cell lung cancer, pancreatic cancer, and several other types of malignancies. Cutaneous toxicities are common due to interference of epithelial growth factor receptor signalling in the skin, have been described in patient receiving EGFR inhibitors. Patients usually complain rash over face, chest and back or some might present with alopecia. Ocular side effects are rare.

Case report

We are reporting a case report of erlotinib induced trichomegaly in a 65-year-old Malay female who is suffering from metastatic adenocarcinoma of lung carcinoma. Patient started to notice coarse eyebrows and long eye lashes almost 1 year after initiation of treatment. The length of eyelashes is around 17mm. She was treated conservatively with frequent trimming of eyelashes and eyebrows. Patient still require erlotinib thus has been doing her frequent trimming to prevent ocular complication such as cornea abrasion. There is no any systemic side effects after seen so far in this patient.

Keywords

Trichomegaly, Epidermal growth factor receptor inhibitors, erlotinib

Clinical significance of checking episcleral venous fluid waves during gonioscopy-assisted transluminal trabeculotomy (GATT)

Zeng L¹

¹Chengdu First People's Hospital, Chengdu, China

Objective

To evaluate the clinical significance of checking episcleral venous fluid wave (EVFW) in gonioscopy-assisted transluminal trabeculotomy (GATT).

Design

Retrospective case series.

Participant

30 patients (45 eyes) with OAG in Chengdu First People's Hospital from August 2019 to August 2020.

Methods

The patient underwent gonioscopy-assisted transluminal trabeculotomy (GATT), the location and extent of episcleral venous fluid wave (EVFW) were examined and graded after intraoperative compression flushing of the anterior chamber angle, patients were followed up for 1 year. No anti-glaucoma drugs were used after surgery, and intraocular pressure (IOP) < 18 mmHg was completely successful; The use of less than two anti-glaucoma agents with IOP < 18 mmHg was considered conditional successful, while the control of intraocular pressure requiring three anti-glaucoma agents was considered unsuccessful.

Main indicators

EVFW, IOP, Anti-glaucoma drugs and postoperative complications.

Results

1.IOP:IOP ranged from 26-48mmHg, and the mean IOP was 35.38 ± 7.16 mmHg. One year after surgery, the mean IOP was 14.65 ± 3.18 , with significant difference before and after surgery ($P < 0.01$). The number of anti-glaucoma drugs: The mean medication before surgery was 2.8 ± 1.2 (2-4) drugs, with a median of 3; 1 year after surgery, the mean anti-glaucoma drugs was 0.6 ± 1.3 (0-3) drugs, with a median of 2; there was significant statistical difference before and after surgery ($P < 0.01$).

2.Success rate of surgery: The success rate was 93.33%, 66.67% of which were completely successful and did not need anti-glaucoma drugs, Conditions were successful in 26.67% and needed 1-2 anti-glaucoma drugs, while 6.66% of patients were unsuccessful and needed reoperation.

3.EVFW:EVFW of all cases was grade 2-4, and the percentages of grade 2, 3 and 4 were 33.33%, 40.00% and 26.67%, respectively. The distribution and percentage of EVFW were inferior (36%), nasal (28%), superior (20%), and temporal (16%). The EVFW of the fully successful patients was 3.4 ± 0.6 (3-4), and conditionally successful patients was 2.6 ± 1.0 (1-4). There was a statistical difference between the two ($P < 0.05$).

5.Complications: During the operation, aqueous humor disappeared in 2 eyes; Intraoperative aqueous fluid leakage in 2 eyes (4.44%), corneal retroelasticity detachment in 2 eyes (4.44%), postoperative anterior chamber haemorrhaphy in 16 eyes (35.56%), postoperative transient intraocular hypertension (IOP Spike) in 18 eyes (40%), no choroid detachment, endophthalmitis and other serious complications occurred.

Conclusion

During GATT operation, the anterior chamber angle examination of EVFW with pressure flushing can reduce the outflow resistance of aqueous aqueous solution and increase the effect of reducing IOP after operation. The range of EVFW is negatively correlated with postoperative IOP, and the larger the range of EVFW, the lower the intraocular pressure after operation. Therefore, EVFW may be a valuable prognostic indicator to determine the success of GATT.

Keywords

GATT EVFW OAG IH-IOP

Foundation:

Project of Science and Technology Department of Sichuan Province, No. 2021YFS0214.

MSJOC poster abstract presentations

Kikuchi Disease: A Differential Diagnosis of Refractory Preseptal Cellulitis.

Abd Rahman Z¹, Abdul Hamid H¹, Mohamad S²

¹Department of ophthalmology, Hospital Sultan Abd Halim, Sungai Petani, Malaysia, ²Department of Ophthalmology and Visual Science, School of Medical Sciences, Universiti Sains Malaysia, Kubang Kerian, Malaysia

Introduction

Kikuchi-Fujimoto disease is a benign necrotizing lymphadenitis, frequently manifests as cervical lymphadenopathy. Ocular involvement is rare, and recurrence is unusual but potentially blinding.

Method

Case report.

Result

A 24-year-old Malay lady presented with recurrent left eyelid swelling and redness associated with tender cervical lymphadenopathy. Initial treatment with oral antibiotics during her first presentation in 2015 was unsuccessful. Histological analysis of lymph node biopsy was consistent with the diagnosis of Kikuchi-Fujimoto disease. Oral steroids commenced and tapered off within 10 months as her symptoms had completely resolved. Unfortunately, she developed recurrent symptoms three years later. She was co-managed with a rheumatologist and put on hydroxychloroquine and oral steroids. Her symptoms subsided; thus the medications were off after 5 months. She was symptom-free for 2 years, until early this year when she presented again with recurrent symptoms of erythematous left eyelid fullness with cystic-like consistency. Multiple tender cervical lymph nodes were palpable. There was no eye pain, redness or diplopia. Her vision is 6/9 in both

eyes. No RAPD, proptosis nor ophthalmoplegia were observed. Anterior segment and fundus examination of both eyes were unremarkable. An urgent CECT-scan of the orbit revealed homogenously enhanced bilateral swollen lacrimal gland, with preseptal cellulitis features. She was treated for preseptal cellulitis secondary to dacryoadenitis, and was given oral Augmentin with no improvement. The eyelid swelling progressively worsens and the patient is at risk of orbital cellulitis, thus the diagnosis was promptly revised to recurrent Kikuchi-Fujimoto disease based on previous histological diagnosis. Oral Prednisolone 60 mg daily resumed which resulted in tremendous improvement of the eyelid swelling and resolution of cervical lymphadenopathy.

Conclusion

Kikuchi-Fujimoto disease should be considered in preseptal cellulitis cases which refractory to antibacterial therapy.

References

1. Chavis PS, Fallata A, Al-Hussein H, Clunie D, Huaman A. Lacrimal gland involvement in Kikuchi-Fujimoto disease. *Orbit*. 1998 Jan 1;17(2):113-7.
2. Lo KB, Papazoglou A, Chua L, Candelario N. Case report: kikuchi: the great mimicker. *F1000Research*. 2018;7.
3. Guerriero S, Ruggeri E, Piscitelli D, Pomes L. Kikuchi-Fujimoto disease: a rare case of orbital involvement. *Orbit*. 2012 Dec 1;31(6):420-2.

Tricky Demyelination, MS Or NMOSD. A case reports

[Alsagoff S¹](#)

¹Pusat Perubatan Universiti Kebangsaan Malaysia, Kajang, Malaysia

Introduction

This case report highlights the difficulties of differentiating between two common cause of demyelinating optic neuritis either due to multiple sclerosis (MS) or Neuromyelitis Optica spectrum disorder (NMOSD). Even though the initial management is similar, the definite treatment is different.

Methods

Case reports.

Results

A 38-year-old Chinese lady with recurrent sudden blurring of vision over the right eye. There are periocular pain, photophobia, headache and numbness over both hands. The left eye has history of similar attack. The right eye vision was 6/9 with reduce optic nerve function, while the left eye vision was 2/60 with positive relative afferent pupillary defect. Optic disc was pale bilaterally. Systemic finding is normal. Details investigations and neuroimaging was negative. Modified McDonald criteria label this patient as relapsing remitting MS while NMOSD diagnostic criteria fulfil the diagnosis of NMOSD. Her symptoms and vision improve after receiving one course of Intravenous methylprednisolone, later patient was started on steroid sparing agent as safer choice to control the disease.

Conclusion

In atypical cases, while following guidance from diagnostic criteria differentiation for MS and NMOSD can still be challenging, hence it is utmost important to tailor our management for each cases individually as it would determine the definite management and outcome for the patient.

Abbreviation

MS, multiple sclerosis, NMOSD, neuromyelitis Optica spectrum disorder,

Keyword

optic neuritis, MS, NMOSD,

Comparison of Visualization of Anterior Chamber and Intermediate Segment by UBM, OCT, and ArcScan

Bharwani S¹, Griffin J², Fang J¹, Sponsel W²

¹Medical University Of Silesia, Richmond, United States, ²WESMDPA Glaucoma Service, San Antonio, United States

Introduction

To perform comparative clinical evaluation of the efficacy of the ArcScan Insight100, an imaging system allowing simultaneous transverse longitudinal visualization of the anterior and intermediate segments of the eye, versus standard ultrasound biomicroscopy (UBM) and optical coherence tomography (OCT).

Methods

Pre- and post-operative images were taken of select patients to visualize the anterior chamber and intermediate segment using UBM, OCT, and ArcScan. Average imaging times were recorded and compared. The time required, image quality, and anatomic range of imaging techniques were compared.

Results

UBM imaging sessions averaged ~20min, including setup and downloading images, providing detailed dynamic focal information in all 12 meridians, but were unable to provide a continuous montage of relevant structures, only a disjunct collage of still images. UBM requires contact and compression of the globe that may distort internal anatomy. OCT sessions averaged ~15min with very high image quality of angle structures, but were of no use for imaging the intermediate segment. ArcScan sessions averaged ~12min, producing high resolution images of all relevant structures, but limited to 8 lateral and medial meridians.

Conclusion

ArcScan provided high-resolution panoramic images of the AC, CB, and anterior choroid without globe distortion. Such integrated high-resolution imagery is of significant value in surgical planning and postoperative monitoring, especially in patients with narrow angles, ocular trauma, cyclodialysis, supraciliary effusion, or anterior choroidal detachment associated with hypotony.

Perfluorocarbon heavy liquid as a short-term tamponade after vitrectomy for inferior rhegmatogenous retinal detachment: pearls and pitfalls

Cheng T¹, Bastion M¹

¹Universiti Kebangsaan Malaysia Medical Centre, Cheras, Malaysia

Introduction

Perfluorocarbon heavy liquid (PFCHL) is a tamponade agent that is used most commonly intraoperatively in pars plana vitrectomy (PPV). It can also be retained post-operatively for short-term tamponade after PPV. PFCHL is particularly useful for more complex cases of retinal detachment including giant retinal tears, inferior retinal tears, chronic rhegmatogenous retinal detachment (RRD), inferior RRD and proliferative vitreoretinopathy (PVR) due to its unique physical properties. However, it is not recommended as tamponade for long duration due to possible retinal toxicity.

Method

Case series

Results

We report three patients who were treated with vitrectomy and PFCHL insertion as short-term tamponade. Case 1 and 2 had inferior RRD, whereas case 3 was a combined PPV-keratoprosthesis procedure in exogenous endophthalmitis. The mean tamponade period was 11 days. Case 2 and 3 had final retinal attachments with improvement of vision, however, case 1 developed PVR and retinal redetachment requiring second vitrectomy. On the other hand, case 1 and 2 developed ocular hypertension, while another had hypotony with subsequent retinal redetachment. Case 1 with scleral-tunnel fixated intraocular lens had pupillary block glaucoma following PFCHL which required laser peripheral iridotomy. Case 2 developed mild ocular inflammation due to reaction to PFCHL which later on leads to posterior synechiae and retrolenticular precipitates, but fortunately resolved after heavy liquid removal.

Conclusion

PFCHL can be a useful post-operative tamponade agent in vitreoretinal surgeries, particularly for inferior retinal pathologies and aphakic patients undergoing combined PPV-keratoprosthesis with RRD. Close post-operative monitoring is crucial for the complications which can involve the anterior or posterior segment.

References

1. Bhurayanontachai, P., & Seepongphun, U. (2020). Outcomes of a postoperative perfluorocarbon liquid tamponade for complex retinal detachments: 12 years of experience in southern Thailand. *BMC Ophthalmology*, 20(1), 1–8. <https://doi.org/10.1186/s12886-020-01600-z>
2. Deobhakta, A., & Rosen, R. (2020). Retinal Tamponades: Current Uses and Future Technologies. *Current Ophthalmology Reports*, 8(3), 144–151. <https://doi.org/10.1007/s40135-020-00247-9>
3. Drury, B., & Bourke, R. D. (2011). Short-term intraocular tamponade with perfluorocarbon heavy liquid. *British Journal of Ophthalmology*, 95(5), 694–698. <https://doi.org/10.1136/bjo.2009.175216>
4. Eiger-Moscovich, M., Gershoni, A., Axer-Siegel, R., Weinberger, D., & Ehrlich, R. (2017). Short-Term Vitreoretinal Tamponade with Heavy Liquid Following Surgery for Giant Retinal Tear. *Current Eye Research*, 42(7), 1074–1078. <https://doi.org/10.1080/02713683.2016.1266664>
5. Georgalas, I., Ladas, I., Tservakis, I., Taliantzis, S., Gotzaridis, E., Papaconstantinou, D., & Koutsandrea, C. (2011). Perfluorocarbon liquids in vitreoretinal surgery: A review of applications and toxicity. *Cutaneous and Ocular Toxicology*, 30(4), 251–262. <https://doi.org/10.3109/15569527.2011.560915>
6. Heimann, H., Stappler, T., & Wong, D. (2008). Heavy tamponade 1: A review of indications, use, and complications. *Eye*, 22(10), 1342–1359. <https://doi.org/10.1038/eye.2008.61>

7. Rofail, M., & Lee, L. R. (2005). Perfluoro-n-octane as a postoperative vitreoretinal tamponade in the management of giant retinal tears. *Retina*, 25(7), 897–901. <https://doi.org/10.1097/00006982-200510000-00013>
8. Sigler, E. J., Randolph, J. C., Calzada, J. I., & Charles, S. (2013a). 25-gauge pars plana vitrectomy with medium-term postoperative perfluoro-n-octane tamponade for inferior retinal detachment. *Ophthalmic Surgery, Lasers & Imaging Retina*, 44(1), 34–40. <https://doi.org/10.3928/23258160-20121221-10>
9. Sirimaharaj, M., Balachandran, C., Chan, W. C., Hunyor, A. P., Chang, A. A., Gregory-Roberts, J., Hunyor, A. B., & Playfair, T. J. (2005). Vitrectomy with short term postoperative tamponade using perfluorocarbon liquid for giant retinal tears. *British Journal of Ophthalmology*, 89(9), 1176–1179. <https://doi.org/10.1136/bjo.2004.065409>
10. Yu, Q., Liu, K., Su, L., Xia, X., & Xu, X. (2014). Perfluorocarbon liquid: Its application in vitreoretinal surgery and related ocular inflammation. *BioMed Research International*, 2014. <https://doi.org/10.1155/2014/250323>

Normalization of intraocular pressure within 24 hours after discontinuation of prolonged used systemic steroid: Is it usual?

Leong Ching Yee¹, Gan Yuen Keat¹, Ainal Adlin Naffi¹, Norshamsiah Md Din¹, Mae-Lynn Catherine Bastion¹

¹Department of Ophthalmology, Faculty of Medicine, Universiti Kebangsaan Malaysia

Introduction

To report an unusual case of rapid normalization of intraocular pressure (IOP) within 24 hours after discontinuation of prolonged used systemic steroid.

Methods

Retrospective review of one case

Results

A 43-year-old Indonesian man with underlying hypertension and diabetes presented with right eye (RE) gradual blurring of vision, pain, haloes and headache for the preceding 3 months. He was taking traditional medication, “Seven Leaves Ginseng” for his chronic back pain, which contains dexamethasone every day for the past 5 years. Visual acuity of RE was 6/60 and left eye (LE) was 6/9 with RE positive relative afferent pupillary defect. RE cornea was hazy with injected conjunctiva. Gonioscopy showed bilateral open angles with IOP of 78 mmHg in RE and 56 mmHg in LE. RE optic disc was palish with CDR 0.6 and LE optic disc was normal. RE showed tunnel visual field with MD -26.95. Right SD-OCT RNFL showed thinning involving the superior and inferior quadrants. He was started on T. Acetazolamide 250mg QID and G. Timolol 0.5% BD OU. RE IOP reduced markedly to 8mmHg the next day. Acetazolamide was tapered off in a week, and Timolol was continued.

Conclusion

Steroid induced glaucoma is an iatrogenic and potentially reversible disease with prompt treatment. IOP can normalize rapidly within one day, once steroid is withheld and anti-glaucoma is administered. While elevated IOP has been reported to be permanent with steroid use of more than 18 months, rapid normalization of IOP is possible after steroid use for 5 years, as shown in this case.

The Art of Fixing a Ticking Time Bomb

[Chong-Su Tang A¹](#), [Yong G^{1,2}](#), [Teh S^{1,2}](#)

¹Department of Ophthalmology, Sarawak General Hospital, Kuching, Malaysia,

²Department of Ophthalmology, Selayang Hospital, Selayang, Malaysia

Introduction

Bleb leakage is one of the notorious complications of glaucoma filtration surgery. It can occur at any point of time after the surgery. Bleb leakage increases the risk of endophthalmitis and other sight-threatening conditions as sequelae of ocular hypotony. Hence, each leaking bleb should be managed promptly.

Methods

A 25-year-old lady with bilateral severe juvenile open-angle glaucoma was referred for right chronic bleb leakage one year after trabeculectomy. She has had a history of bilateral failed XEN implant with multiple needling with 5FU injections. The right eye was also treated for exogenous endophthalmitis. On presentation, both eye visions were hand movements. The IOP was 6mmHg bilaterally. Right eye bleb was large, highly elevated from 10 – 1 o'clock, avascular, thin wall, cystic with few leaking points. The right anterior chamber was deep, the optic disc was mild pallor with CDR 0.9. She also had a visually significant cataract in her right eye. Combined lens aspiration, intraocular lens implantation, and amniotic membrane transplantation were performed after non-surgical interventions were unsuccessful.

Results

Lens aspiration was performed first with low IOP maintained throughout the surgery. After that, a double-layer amniotic membrane transplantation technique overlying the leaking bleb was performed. Three months postoperatively, her right best-corrected vision was 6/30, IOP ranging 12-14mmHg and there was no bleb leakage.

Conclusion

Cataract surgery with a low setting is possible in a leaking, thin-wall bleb. Post-op inflammation and amniotic membrane transplantation have healed a long-standing leaking bleb.

References

1. Budenz DL, Barton K, Tseng SC. Amniotic membrane transplantation for repair of leaking glaucoma filtering blebs. *Am J Ophthalmol.* 2000 Nov;130(5):580-8.

Transepithelial corneal cross-linking with supplemental oxygen in keratoconus treatment – corneal stromal demarcation line and safety

Jessica CHOO, [Qian Hui](#)¹, LIM Li¹

¹Singapore National Eye Centre, Singapore

Introduction

To evaluate the corneal stromal demarcation line and safety of transepithelial corneal cross-linking (CXL) with supplemental oxygen in progressive keratoconus treatment.

Methods

This is a retrospective review of 25 patients with progressive keratoconus who underwent epithelial-on CXL with supplemental oxygen from December 2019 to February 2022. Outcomes measured include corneal stromal demarcation line depth, volume of cornea treated, endothelial cell count, best-corrected visual acuity, keratometric parameters and post-treatment adverse events.

Results

25 eyes of 25 patients were included and mean age was 28.3 years. Mean follow-up period was 11.5 ± 1.39 months. Pre-operatively, mean \pm standard deviation (SD) of K1, K2, Kmax and minimal corneal thickness were $45.9D \pm 3.79D$, $50.2D \pm 4.83D$, $57.5D \pm 6.98D$ and $482.3\mu m \pm 36.8\mu m$ respectively. There is no significant difference between pre- and post-treatment corneal topographic parameters. There was improvement in BCVA post-treatment. The mean post-treatment corneal stromal demarcation line depth was $367.3 \pm 89.8\mu m$. The volume of treated cornea including the central corneal epithelial thickness was $73.3 \pm 4.39\%$. There was no reduction in endothelial cell count (ECC) post-procedure (pre-treatment mean ECC \pm SD: 2695.4 ± 224.5 cells/mm², post-treatment ECC 2730.1 ± 252.0 cells/mm², p-value = 0.33). Post-treatment corneal haze was mild and seen in 8 patients post-operatively. One patient developed a non-visual axis involving stromal infiltrate that resolved with topical broad-spectrum anti-microbials.

Conclusion

Trans-epithelial CXL with supplemental oxygen for keratoconus treatment achieved comparable corneal stromal demarcation line depth comparable to that of conventional epithelial-off corneal cross-linking and had a similar safety profile.

Stargardt Disease - The Classical Findings

Chung L¹, Goh Y¹

¹Miri Hospital, Miri, Malaysia

Introduction

Stargardt disease is the most common juvenile macular dystrophy and a common cause of central vision loss in adults younger than 50 years of age. Majority cases of Stargardt disease are caused by autosomal recessive mutations.

Methods

Case report

Result

A 14-year-old female with no known medical illness presented to our center with progressive painless blurring of vision in both eyes over a period of one year. Upon ocular examination, best corrected visual acuity was 6/30 and the anterior segment was normal bilaterally. Fundus examination revealed the presence of pigmentary changes and yellowish flecks at the macula with fovea involvement. Optical coherence tomography (OCT) showed hyperreflective deposits noted at sub-retinal pigment epithelium. Fundus fluorescein angiography (FFA) showed dark choroid with hyperfluorescence at the macula corresponding to the yellowish flecks on fundoscopic examination. Diagnosis of Stargardt disease was made based on the clinical and imaging findings. Systemic examination was unremarkable. Patient has no family history of poor vision or blindness. She was subsequently referred to a low vision clinic and scheduled for regular follow-ups.

Conclusion

Stargardt disease is an incurable genetic disease, the earlier the presentation, the poorer the prognosis. At the moment only supportive measures are provided and once central vision is affected, the loss of visual acuity in these patients can be relatively rapid, over months to a few years, and then plateaus.

Keywords

Stargardt disease, macular dystrophy, dark choroid, progressive visual loss

Early Detection and Management of Traumatic Red Eye In Primary Care

[ELUMALAI T¹](#)

¹Kementerian Kesihatan Malaysia, Seremban, Malaysia

Introduction

Red eye is the most common ophthalmologic condition in the primary care setting with conjunctivitis being the most frequently diagnosed. However, traumatic red eye conditions such as conjunctival laceration are often missed due to inadequate detailed history taking and eye examination. Often such injuries are caused by blunt or penetrating trauma. Conjunctival injury can be the presenting sign of underlying intraocular trauma, thus recognizing the need for emergent referral to an ophthalmologist is the key in the primary care management of red eye.

Methods

Case report

Results

A 70 years old Chinese gentleman presented to the outpatient department complaining of right eye redness with eye discharge and pain for the past 2 weeks. He initially sought treatment at a private clinic and was given ointment chloramphenicol and discharged home. On further detailed history taking, he reported a history of cutting wood in his backyard subsequently a fragment of the wood particle flew into his right eye prior to his onset of symptoms. Upon examination, the conjunctiva was injected and a conjunctival lacerated wound measuring 1 mm noted located at the sclero-limbal junction. His vision was 6/12 in the right eye. Left eye was normal. The patient was immediately referred to the Ophthalmology Department.

Conclusion

Blunt ocular trauma is a relatively common presentation to the primary care practitioner. Primary care physician often effectively manage red eye, although knowing when to refer patients to an ophthalmologist is crucial. Careful evaluation with prompt diagnosis and initiation of treatment are essential to promote appropriate healing of conjunctiva.

References

1. [Macewen CJ. Eye injuries: a prospective survey of 5671 cases. Br J Ophthalmol 1989; 73:888.](#)
2. [Pokhrel PK, Loftus SA. Ocular emergencies. Am Fam Physician 2007; 76:829.](#)

A Comparison of Parity between Humphrey Visual Field and Olleyes Virtual Reality Perimetry

Fang J¹, Bharwani S¹, Griffin J², Le K³, Sponsel W²

¹Medical University Of Silesia, Morganville, United States, ²WESMDPA Glaucoma Service, San Antonio, United States, ³UTHSCSA, San Antonio, United States

Introduction

Visual field studies play a critical role in the diagnosis and monitoring of glaucoma patients. The purpose of this study is to determine parity between Humphrey Visual Field (HVF) perimetry and the Olleyes virtual reality platform (VRP).

Methods

Patients with stable, long-term HVF visual fields (horizontal dots for ≥ 5 consecutive visits on progression analysis) with normal, mild, moderate, and severe visual field loss were tested twice with VRP using proprietary software, the second of which was used for point-by-point comparison with the last available HVF.

Results

The prospective study analyzed 41 eyes of 22 people (19 binocular, 3 monocular), 9 normal, 9 mild, 10 moderate, & 13 severe. Linear correlations between HVF and VFP for glaucomatous eyes were: (y intercept (dB)/slope/R): Mild (1.4/1.1/0.64), Moderate (+1.6/0.9/0.67), Severe (+0.6/0.5/0.44).

Conclusion

Parity between the VRP and HVF was remarkably strong for mild and moderate glaucoma. Given its ease of use, space efficiency, and low cost, the VRP presents a viable alternative.

Cost of myopia correction: a systematic review

[Li Lian FOO^{1,2,3}](#), Carla LANCA², Chee Wai WONG^{1,2,3}, Daniel TING^{1,2,3}, Ecosse LAMOUREUX^{2,3}, Seang-Mei SAW^{2,3,4}, Marcus ANG^{1,2,3}

¹Singapore National Eye Centre, Singapore

²Singapore Eye Research Institute, Singapore

³Duke–NUS Medical School, National University of Singapore

⁴NUS Saw Swee Hock School of Public Health

Introduction

Myopia is one of the leading causes of visual impairment globally. Despite increasing prevalence and incidence, the associated cost of treatment remains unclear. Health care spending is a major concern in many countries and understanding the cost of myopia correction is the first step eluding to the overall cost of myopia treatment. As cost of treatment will reduce the burden of cost of illness, this will aid in future cost-benefit analysis and the allocation of healthcare resources, including considerations in integrating eye care (refractive correction with spectacles) into universal health coverage (UHC).

Methods

We performed a systematic review to determine the economic costs of myopia correction. However, there were few studies for direct comparison. Costs related to myopia correction were mainly direct with few indirect costs.

Results

Annual prevalence-based direct costs for myopia ranged from \$14-26 (USA), \$56 (Iran) and \$199 (Singapore) per capita, respectively (population: 274.63 million, 75.15 million and 3.79 million, respectively). Annually, the direct costs of contact lens were \$198.30-\$378.10 while spectacles and refractive surgeries were \$342.50 and \$19.10, respectively. This review provides an insight to the cost of myopia correction. Myopia costs are high from nation-wide perspectives because of the high prevalence of myopia, with contact lenses being the more expensive option.

Conclusion

Without further interventions, the burden of illness of myopia will increase substantially with the projected increase in prevalence worldwide. Future studies will be necessary to generate more homogenous cost data and provide a complete picture of the global economic cost of myopia.

Topical timolol maleate for periocular infantile capillary haemangioma

[Hussin I](#)¹, Tuan Jaafar T¹, Buang N¹, Ahmad Tajudin L²

¹Ophthalmology Clinic, Hospital Raja Perempuan Zainab II, Kota Bharu, Kelantan, Malaysia, Kota Bharu, Malaysia, ²Department of Ophthalmology and Visual Science, School of Medical Sciences, Universiti Sains Malaysia, Health Campus, Kubang Kerian, Kelantan, Malaysia, Kubang Kerian, Malaysia

Introduction

Capillary haemangioma is a common benign vascular tumour of childhood. Corticosteroids, alpha-interferon, laser therapy, embolization, immunomodulators, surgery, and systemic propranolol are among the treatment options. As amblyopia is the most common complication of capillary haemangioma of the eyelid in children, prompt treatment is indicated to prevent blindness.

Methods

Case report

Results

A 2-months old baby boy presented to the eye clinic with left eye periocular lesion presence since birth. His mother noticed that the lesion was increasing causing slight drooping of left upper eyelid. There was no history of trauma, seizure, or any systemic illness. His pre, intra and post-natal was uneventful. On eye examination, there was a large multiple raised redness skin lesion over the left upper eyelid involving lid margin and lateral canthus extending to the temporal region. Multiple telangiectatic vessels were seen on the lesion. Both eyes anterior segment and fundi were sound. The heart rate and systemic examination were normal. He was diagnosed with left periocular infantile capillary haemangioma and treated with topical timolol maleate 0.5% eyedrops twice daily on the lesion. The lesion regressed at 3 months and disappeared after 6 months post treatment. There was no untoward systemic or ophthalmic side effects.

Conclusion

Local treatment with topical maleate 0.5% on periocular infantile capillary haemangioma lesion is non-invasive, safe, and effective for young age group.

Various presentation of ocular tuberculosis in Hospital Duchess of Kent (HDOK), Sandakan

[Iskhandar I¹](#)

¹Hospital Duchess Of Kent, Sandakan, Malaysia, ²Hospital Tawau, Tawau, Malaysia

Introduction

Tuberculosis is and infectious caused by Mycobacterium tuberculosis. It is endemic in Malaysia. Typically, it affects the lungs, however it can also be presented as a disseminated disease or localised to a certain organ. This case report highlights the various presentation of ocular tuberculosis in HDOK.

Methods

Case reports of 2 patients

Results

There were 2 patients in this case report. Both were young with no comorbidities and stayed in inner district of Sabah. Patient was presented with left eye redness, pain and blurring of vision for 3 months. Examination revealed visual acuity of 6/24 with stromal haziness from 12-5 o'clock peripheral to central cornea. Another patient presented with bilateral eye redness, pain and blurring of vision for 1 month with visual acuity of hand movement. She had intense fibrinous anterior segment reaction, granulomatous uveitis, and multifocal exudative retinal detachment with optic disc oedema bilaterally. The first patient had positive purified protein derivatives test while the latter was negative. The second patient was treated as Vogt-Koyanagi-Harada syndrome and was given high dose steroid until development of choroidal granuloma which gave a clue to ocular tuberculosis. Both were treated with anti – tuberculosis (anti TB) and responded well to treatment.

Conclusion

Ocular tuberculosis is high on the list in patients presenting with unexplained posterior uveitis or panuveitis. It is a great mimicker of other conditions making diagnosis difficult. Access to immunological test for tuberculosis like Interferon Gamma Release Assay (IGRA) or TB Quantiferon helps in making quick and fast diagnosis thus commencement of treatment can be done early.

A Quagmire: Reactivation of Polypoidal Choroidal Vasculopathy Post Cataract Surgery

Jami W^{1,2}, Rashid F¹, Muhammad Azmi Khor N¹, Hassan S¹, Hashim H¹, Ismail S²

¹Department of Ophthalmology, Hospital Selayang, Selayang, Malaysia,

²Department of Ophthalmology and Visual Science, School of Medical Sciences, Universiti Sains Malaysia, Malaysia, Kubang Kerian, Malaysia

Introduction

Reactivation of polypoidal choroidal vasculopathy (PCV) can be due to multiple factors with cataract surgery being one of the rare cause. We report a case of reactivation of PCV post cataract surgery and discuss the underlying theories that may contribute to it.

Method

A case report.

Results

A 68 year old man presented with generalized, painless and progressively worsening bilateral eye (BE) blurring of vision for 6 months. He smokes 15 pack years. Upon examination, visual acuity (VA) of the right eye (RE) is hand movement and left eye (LE) is counting finger at 1 feet. Fundus examination of the RE reveals vitreous hemorrhage with no fundus view and LE shows submacular exudates and scarring. He was diagnosed with RE active PCV and underwent RE vitrectomy. Thereafter, he was planned for three monthly intravitreal anti vascular endothelial growth factor (IVT Anti VEGF) injections, but defaulted treatment.

The best corrected visual acuity (BCVA) obtained 10 months post RE vitrectomy is 6/24, ocular examination shows cataractous lens, drusen over the macula and a quiescent IPCV. Patient underwent an uneventful cataract surgery, 1 month post-operative BCVA is 6/12. However, 2 months post cataract surgery, RE VA deteriorates to 6/36 and fundus examination reveals submacular hemorrhage. He

was subsequently planned for monthly injections of IVT Anti VEGF for 5 months. His final BCVA is 6/36.

Conclusion

Although rare, reactivation of PCV post cataract surgery may cause a devastating reduction in visual acuity. Understanding the pathophysiology behind it may help surgeons to provide better surgical management and environment for these patients.

Poof and it Disappears! A Case of Vanishing Intraocular Foreign Body

Wardati Hanisah Jami^{1,2}, Fathin Nabilah Rashid¹, Noor Sarah Khor¹, Zabri Kamarudin¹, Shatriah Ismail²

¹Department of Ophthalmology, Hospital Selayang, Malaysia

²Department of Ophthalmology and Visual Science, School of Medical Sciences, Universiti Sains Malaysia, Malaysia

Introduction

A penetrating injury to the eye can result in deposition of foreign body in the eye structure. Multimodal imaging is paramount to ensuring a correct diagnosis and aid in management of IOFB.

Methods

A case report.

Results

A 76-year-old man was injured by a foreign body in his left eye as he was mowing the lawn. Primary toilet and suturing of the cornea laceration was done and initial computed tomography (CT) of the orbit revealed a hyperdense material within the anterior chamber (AC). He was referred to the vitreoretinal surgeon in our centre for surgical intervention. He underwent AC washout, intraocular foreign body (IOFB) search and intravitreal antibiotics. Intraoperatively, a puncture wound was found nasally at the iris and lens was dislocated posteriorly however, no foreign body was found. He was subsequently arranged for skull X-ray where no radio-opaque FB was seen, however B-scan shows suspicious FB inferiorly in the vitreous cavity. Patient underwent another CT orbit and a hyperdense material was seen in the vitreous cavity. He was planned for vitrectomy and IOFB removal once the cornea opacity subsides.

Conclusions

Understanding the detection limitations for each IOFB type and imaging modalities, as well as the possibility of IOFB to migrate from one structure to another, is critical in optimising ocular trauma patient therapy.

Sixth Cranial Nerve Palsy secondary to Indirect Carotid Cavernous Fistula in a patient with recent COVID-19 vaccination

Jayallan B¹, Wan Zaidi W², Zakaria R³, Bastion M¹

¹Department of Ophthalmology Universiti Kebangsaan Malaysia Medical Centre (UKMMC), , ²Department of Neurology Universiti Kebangsaan Malaysia Medical Centre (UKMMC), ³Department of Radiology Universiti Kebangsaan Malaysia Medical Centre (UKMMC),

Introduction

Sixth cranial nerve palsy (SCNP) is a rare presenting feature of carotid cavernous fistula (CCF). It has also been attributed to a post-vaccination autoimmune reaction, for which steroids are indicated. CCF is a malformation of vascular communication between the internal carotid artery, external carotid artery and cavernous sinus, which is diagnosed radiologically and needs surgical intervention.

Case Presentation

A 46-year-old female presented with binocular double vision. She also complained of intermittent headache, tinnitus and facial swelling post-COVID 19 Comirnaty (BNT162b2) vaccination developed by Pfizer and BioNTech, given two days previously. Otherwise, no fever, nausea, vomiting, unilateral weakness or seizure. Best-corrected visual acuity was 6/6 OU. On examination, there was left limitation of levoversion, levelevation and levodepression. The anterior segment, intraocular pressure and fundus, including the optic nerve, were otherwise normal. Hess chart showed left 6th nerve palsy. MRA brain investigation revealed suspicion of left CCF. A cerebral angiogram performed revealed a left indirect CCF. The interventional radiologist did an embolization of the fistula. Two weeks post-procedure, diplopia resolved, and extraocular muscle movement was full.

Conclusion

Neuroimaging is advisable in patients who develop SCNP with no significant vasculopathy risk factors after COVID 19 vaccination to establish the cause of SCNP as not all are due to inflammation. Neuroimaging helps to exclude other life-threatening causes of the SCNP, such as CCF. SCNP responds well to surgical intervention, which leads to complete resolution of symptoms.

References

1. Margolin, E. Approach to patient with diplopia. *J Neurol Sci* 417, 117055 (2020).
2. Reyes-Capo, D.P., Stevens, S.M. & Cavuoto, K.M. Acute abducens nerve palsy following COVID-19 vaccination. *J AAPOS* (2021).
3. Sanders, S.K., Kawasaki, A. & Purvin, V.A. Long-term prognosis in patients with vasculopathic sixth nerve palsy. *Am J Ophthalmol* 134, 81-84 (2002).
4. Murchison, A.P., Gilbert, M.E. & Savino, P.J. Neuroimaging and acute ocular motor mononeuropathies: a prospective study. *Arch Ophthalmol* 129, 301-305 (2011).
5. Lieber, S. & Fernandez-Miranda, J.C. Anatomy of the Orbit. *J Neurol Surg B Skull Base* 81, 319-332 (2020).
6. Grumann, A.J., Boivin-Faure, L., Chapot, R., Adenis, J.P. & Robert, P.Y. Ophthalmologic outcome of direct and indirect carotid cavernous fistulas. *Int Ophthalmol* 32, 153-159 (2012).
7. Henderson, A.D. & Miller, N.R. Carotid-cavernous fistula: current concepts in aetiology, investigation, and management. *Eye (Lond)* 32, 164-172 (2018).
8. Woo, E.J., Winiecki, S.K. & Ou, A.C. Motor palsies of cranial nerves (excluding VII) after vaccination: reports to the US Vaccine Adverse Event Reporting System. *Hum Vaccin Immunother* 10, 301-305 (2014).
9. Xia, X. Detailed Dissection and Critical Evaluation of the Pfizer/BioNTech and Moderna mRNA Vaccines. *Vaccines (Basel)* 9(2021).
10. Barry, R.C., *et al.* Interventional treatment of carotid cavernous fistula. *J Clin Neurosci* 18, 1072-1079 (2011).

The Eye and The Ear – A Cogan’s Tale

[Kaur¹](#), Che-Hamzah J, Othman O

¹Hukm Ophthalmology Department, Cheras, Malaysia

Introduction

Cogan’s Syndrome (CS) is a relatively rare inflammatory disorder presenting with ocular and vestibuloauditory symptoms. It is commonly associated with sensorineural hearing loss (SNHL) and interstitial keratitis as well as generalised systemic inflammation. We report a rare case of Cogan’s Syndrome presenting with posterior uveitis and SNHL associated with *chlamydia pneumoniae* infection

Methods

Case Report

Results

A 51-year-old lady presented with fever, malaise, nausea, tinnitus and abdominal pain for 10 days. Initially, intravenous Rocephine was started for occult sepsis in the ward. On day 3 of admission, she complained of sudden onset of hearing loss, worsening tinnitus and generalised blurring of both eyes vision. Clinically, both vision was 6/6 with normal anterior segment examination. Posterior fundus examination showed multiple choroiditis lesion but absent of optic disc oedema. Auditory evaluation showed bilateral symmetrical mild to moderate SNHL. Systemic examination revealed hepatosplenomegaly. Blood investigations showed a raise in ESR, CRP, transaminases and positive for Anti-nuclear Antibody (ANA) and Chlamydia Pneumoniae IgG and IgM. Viral screening and Treponema VDRL was negative.

A clinical diagnosis of Cogan’s syndrome was made and patient was started on initial IV Methylprednisolone 1mg/kg/day and then slow tapered to oral Prednisolone. Improvement in visual symptoms with resolution of posterior uveitis was seen, however SNHL remained persistent.

Conclusion

Cogan's Syndrome is a clinical diagnosis. Atypical presentation needs a high index of suspicion particularly when ocular and cochleovestibular involvement is present. Treatment with systemic steroid is the treatment of choice

Parinaud Oculoglandular Syndrome in a white eye

Interpreted Kaur¹, Jemaima Che Hamzah¹, Wan Hazline Wan Abdul Halim¹, Yong Meng Hsien¹

¹Department of Ophthalmology, Faculty of Medicine, Universiti Kebangsaan Malaysia, Malaysia

Introduction

Parinaud oculoglandular syndrome (POGS) is a unilateral granulomatous follicular conjunctivitis associated with ipsilateral regional lymphadenopathy. It is infection related and can be caused by cat-scratch disease (CSD) due to *Bartonella henselae*. We are reporting a case of POGS presented with acute unilateral painless tearing in a white eye.

Methods

Case Report

Results

A 55-year-old lady presented with 3 weeks history of left eye persistent tearing. There was no eye pain, redness, discharge or itchiness. She had no ocular trauma and was treated initially as dry eye disease with no improvement. Further history revealed multiple episodes of cat scratch. Clinically her vision was normal with white bulbar conjunctiva, clear cornea and unremarkable intraocular examination bilaterally. Her eyelids were not swollen but eversion of the left upper eyelid revealed multiple granulomatous follicular swelling of palpebral conjunctiva. Multiple enlarged and tender lymph nodes palpable at the preauricular and submandibular regions. Diagnosis of POGS was made. She was treated with oral doxycycline 100mg BD and topical dexamethasone 0.1% QID. Patient responded well with improvement in both lymphadenopathy and conjunctival granuloma with resolved chief complaint- tearing.

Conclusion

POGS can present with painless tearing in a white eye. Risk identification from history, eyelid eversion and lymph nodes examinations should be carried out to aid in correct diagnosis and prompt treatment to ensure complete recovery.

Delayed-onset bilateral dacryocystocele with punctal agenesis: diagnosis and management

Koay J^{1,2}, Abdul Rahim A¹, Che Hamzah J²

¹Hospital Sultanah Bahiyah, Alor Setar, Malaysia, ²Universiti Kebangsaan Malaysia, Cheras, Malaysia

Introduction

Congenital dacryocystocele is an uncommon developmental failure leading to obstruction of nasolacrimal drainage (NLD) system. It usually manifests early after birth as a bluish mass near medial canthus.

Methods

Case report

Results

A 2-year-old Chinese male toddler initially presented with a persistent swelling at left medial canthal area for 2 months. The swelling measured 2x2cm with a firm consistency. It appeared inflamed but not tender with a positive transillumination test. Both upper and lower puncta were absent bilaterally. The magnetic resonance imaging of orbit showed a hypodense lesion with a well-defined margin at inferomedial aspect of left orbit which appeared as a cystic lesion arising from left nasolacrimal sac, suggestive of a left dacryocystocele. However, a year later, he developed a new swelling over right medial canthus for two weeks with similar manifestation as the left dacryocystocele. Right eye dacryocystocele, which was not evidenced in the previous imaging, emerged in a repeat scan. He underwent sequential bilateral endoscopic assisted dacryocystectomy. Intraoperatively, it revealed bilateral upper and lower puncta agenesis. There were no common canaliculi and nasolacrimal duct opening. Both lacrimal sac and NLD were dilated. Histopathology of the lacrimal sac and NLD mucosa showed fibrocollagenous tissue with columnar epithelial lining and lymphoid aggregates. This corresponds to a benign cyst with chronic inflammation.

Conclusion

Delayed-onset dacryocystocele results from obstruction of Rosenmüller and Hasner valves with late onset of glandular development. Subsequent accumulation of mucus in lacrimal sac therefore causes sac distension to form dacryocystocele.

Isolated abducens nerve palsy in a patient with COVID-19 infection

[Kwan Joo Ern K^{1,2}](#), Ker Hsin N¹, Jalaluddin J¹, Sonny Teo K²

¹Hospital Melaka, Melaka, Malaysia, ²Universiti Sains Malaysia, Kubang Kerian , Malaysia

Introduction

To report a case of an acute isolated abducens nerve palsy in a healthy young gentleman following SARS-CoV-2 infection.

Methods

We described a case of a 23-year-old gentleman who presented to us with sudden onset of diplopia for three days after testing positive with SARS-CoV 2 infection a week prior to his ocular symptom.

Results

The patient was diagnosed with right isolated abducens nerve palsy, with Hess test showing underaction of the right lateral rectus muscle and overaction of the left medial rectus muscle. He was initially given an outpatient follow up in a week. However, he returned five days later complaining of worsening diplopia and severe headache. Contrasted enhanced computer tomography (CECT) of the brain and orbit revealed no intracranial or intraorbital lesion. There was complete spontaneous recovery of the abducens palsy over six weeks.

Conclusion

Since the emergence of COVID-19, there have been a few reports describing neurological involvement of patients with COVID-19. Research suggested that COVID-19 infection can trigger an atypical immune response in some individuals, causing nerve damage such as neuropathy. As our patient had no pre-existing vascular risk factors, we postulate that his neurological presentation could have been viral-related. The aim of this case report is to raise awareness among clinicians regarding the possibility of post-infectious cranial nerve palsies

representing part of the neurologic spectrum of SARS-CoV 2 infection. Further case studies are necessary to support these findings.

The Importance of Multimodal Imaging (MMI) in Diagnosing Multiple Evanescent White Dot Syndrome (MEWDS)

Lai Y¹, Yap S¹, Hanisah Jami W¹, Sawri Rajan R¹, Lott P²

¹Hospital Selayang, Selayang, Malaysia, ²University of Malaya (UM), Kuala Lumpur, Malaysia

Introduction

MEWDS is a rare form of posterior uveitis, typically affecting young myopic females and presents as an acute, unilateral choriocapillaris with multifocal whitish dots throughout the retina. It is usually a self-limiting disease with full recovery expected within 7-10 weeks, unless complications like choroidal neovascularization develops.

Methods

Case series of MEWDS encountered in Hospital Selayang between 2010 to 2022.

Results

Four cases of MEWDS were encountered, with 3 female and 1 male (3:1). Mean age of presentation was 35.75 ± 5.25 years. All four patients had recent preceding viral infection, including 2 SARS-CoV-2 vaccination, 1 SARS-CoV-2 infection and 1 viral illness within 1 month prior to presentation. All had unilateral disease with presenting visual acuity ranging from 6/9 to 6/60. 2 patients were myopic (50%). 50% had anterior chamber activity. Fundus examination showed multiple yellow-white subretinal lesions (100%). Visible lesions were located around the disc (25%), throughout posterior pole (75%) and midperiphery (100%). Disc hyperemia (50%), mild vitritis (75%) and foveal granularity (75%) were present.

MMI included Humphrey Visual Field (HVF) which showed an enlarged blind spot (25%). SD-OCT demonstrated IS/OS ellipsoid zone disruption (100%), Blue-Light Autofluorescence (BL-FAF) showed hyperautofluorescence spots (100%). Fundus Fluorescein Angiography (FFA) showed hyperfluorescent lesions in a wreath-like pattern in the early to late phase and disc hyperfluorescence (100%). Indocyanine

green angiography (ICGA) showed patchy hypofluorescence in the late phase (100%).

Treatment was with either oral prednisolone (50%) or topical steroids (50%) depending on disease severity and the diagnosing clinician's discretion.

Conclusion

Many of the white dot syndromes have overlapping features with different disease mechanisms that makes diagnosis challenging. MEWDS is a primary inflammatory choriocapillaropathy which causes transient outer retinal ischemia. With the triad of SD-OCT, BL-FAF and ICGA, MMI has become a mainstay for diagnosis of MEWDS with a high degree of certainty.

References

1. Testi, I., Modugno, R.L. & Pavesio, C. Multimodal imaging supporting the pathophysiology of white dot syndromes. *J Ophthalm Inflamm Infect* **11**, 32 (2021). <https://doi.org/10.1186/s12348-021-00261-3>
2. Papasavvas, I., Mantovani, A., Tugal-Tutkun, I. et al. Multiple evanescent white dot syndrome (MEWDS): update on practical appraisal, diagnosis and clinicopathology; a review and an alternative comprehensive perspective. *J Ophthalm Inflamm Infect* **11**, 45 (2021). <https://doi.org/10.1186/s12348-021-00279-7>
3. Ramakrishnan MS, Patel AP, Melles R, Vora RA. Multiple Evanescent White Dot Syndrome: Findings from a Large Northern California Cohort. *Ophthalmol Retina*. 2021 Sep;5(9):850-854. doi: 10.1016/j.oret.2020.11.016. Epub 2020 Nov 30. PMID: 33271345.
4. Inagawa S, Onda M, Miyase T, Murase S, Murase H, Mochizuki K, Sakaguchi H. Multiple evanescent white dot syndrome following vaccination for COVID-19: a case report. *Medicine* 2022;101:2(e28582).
5. Takahashi, Yasuhiro, et al. "A Case of Multiple Evanescent White Dot Syndrome Treated By Steroid Pulse Therapy." *Osaka City Medical Journal*, vol. 52, no. 2, 2006, pp. 83-6.

6. Norooznezhad AH, Mohammadzadeh V, Kadivar S, Ghassemi F. Multiple Evanescent White Dot Syndrome: A Case Report and Experience with Corticosteroid Therapy. *Iran J Allergy Asthma Immunol.* 2020;19(S1):91-94.

Comparative analysis of the central, paracentral and peripheral corneal endothelium in Fuchs' Endothelial Corneal Dystrophy with CEM-530 specular microscope

Brian Lee Juin Hsien^{1,2}, Evan Wong¹, Marcus Ang^{1,3}

¹Singapore Eye Research Institute, Singapore National Eye Centre, Singapore

²Lee Kong Chian School of Medicine, Singapore

³Ophthalmology and Visual Sciences Academic Clinical Program, Duke-NUS Medical School, National University of Singapore, Singapore

Introduction

Fuchs endothelial corneal dystrophy (FECD) is the among the leading causes of decreased visual quality globally.^{1,2} Diagnosis is based on clinical history and slit-lamp findings of central cornea guttata.³ Current practice pattern only involves imaging a small area of the central corneal endothelium.⁵⁻⁸ However, comprehensive assessment of endothelial dysfunction beyond the central region is beneficial in guiding management.⁴ The Nidek CEM-530 specular microscope permits endothelial imaging up to 3.7mm from the corneal centre. In this pilot study, we compared image quality and measures of endothelial layer integrity between central and eccentric locations.

Methods

54 eyes of 27 FECD subjects were studied with the CEM-530 at the Singapore National Eye Centre. Images were captured at one central, eight paracentral (1.3mm diameter) and six peripheral (7.3mm diameter) points for each eye. Image quality grading was done by two independent assessors as described previously⁹ and analysed using Bland-Altman (BA) plot and Kappa coefficient. Image quality, endothelial cell density (ECD), coefficient of variant (CV), hexagonal cell (HEX) and corneal thickness (CT) were compared across the three regions using Mann-Whitney U test.

Results

The mean age of the cohort was 65.1 years (Table 1). BA plot (Figure 1) showed good agreement between assessors, with a weighted Kappa of 0.949 (95% CI: 0.935-0.963) (Table 2). Image quality was significantly better in the central ($p<0.0001$) and paracentral ($p<0.0001$) than peripheral region. ECD ($p=0.0091$; $p<0.0001$) and CT ($p=0.0012$; $p<0.0001$) were significantly higher in the peripheral compared to central and paracentral regions.

Conclusion

In FECD, image quality of the CEM-530 specular microscope was poorer in the peripheral compared to the central and paracentral regions. ECD and CT measurements were greater in the peripheral compared to the central and paracentral regions.

References

1. Li QJ, Ashraf MF, Shen D, et al. The role of apoptosis in the pathogenesis of Fuchs endothelial dystrophy of the cornea. *Archives of ophthalmology* 2001;119(11): 1597-1604.
2. Price MO, Mehta JS, Jurkunas UV, et al. Corneal endothelial dysfunction: Evolving understanding and treatment options. *Prog Retin Eye Res* 2021;82: 100904.
3. Chiou AG, Kaufman SC, Beuerman RW, et al. Confocal microscopy in cornea guttata and Fuchs' endothelial dystrophy. *British journal of ophthalmology* 1999;83(2): 185-189.
4. Fujimoto H, Maeda N, Soma T, et al. Quantitative regional differences in corneal endothelial abnormalities in the central and peripheral zones in Fuchs' endothelial corneal dystrophy. *Invest Ophthalmol Vis Sci* 2014;55(8): 5090-5098.
5. Aggarwal S, Cavalcanti BM, Regali L, et al. In Vivo Confocal Microscopy Shows Alterations in Nerve Density and Dendritiform Cell Density in Fuchs' Endothelial Corneal Dystrophy. *Am J Ophthalmol* 2018;196: 136-144.

6. McLaren JW, Bachman LA, Kane KM, et al. Objective assessment of the corneal endothelium in Fuchs' endothelial dystrophy. *Invest Ophthalmol Vis Sci* 2014;55(2): 1184-1190.
7. Eleiwa T, Elsayy A, Tolba M, et al. Diagnostic Performance of 3-Dimensional Thickness of the Endothelium-Descemet Complex in Fuchs' Endothelial Cell Corneal Dystrophy. *Ophthalmology* 2020;127(7): 874-887.
8. Ang M, Baskaran M, Werkmeister RM, et al. Anterior segment optical coherence tomography. *Prog Retin Eye Res* 2018;66: 132-156.
9. Huang J, Tepelus TC, Huang P. Specular microscopy image quality scale for endothelial cell density determination in donor cornea tissue. *Int J Eye Bank* 2017;5: 1-6.

Table 1. Demographics of 27 FECD patients.

Demographics	Number (%)
Gender	
Male	9 (33.3)
Female	18 (66.7)
Age (years) (mean)	65.1 (range= 48-81)
Ethnicity	
Chinese	24 (88.9)
Indian	1 (3.7)
Malay	2 (7.4)

Table 2. Kappa statistics of image quality grades of CEM-530 specular microscope between two independent assessors across the central, paracentral and peripheral regions.

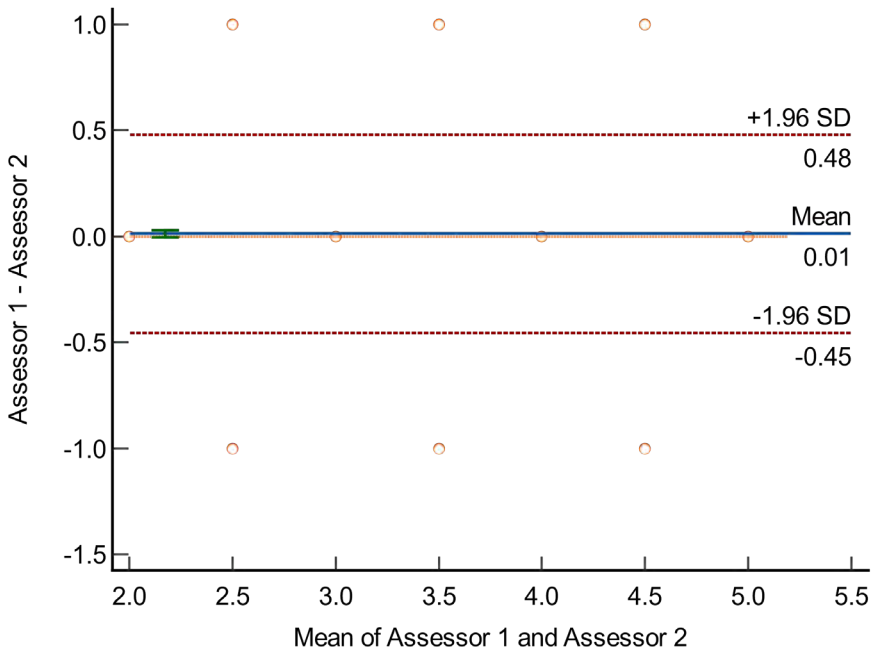
Assessor 2	Assessor 1					
	Grade 1	Grade 2	Grade 3	Grade 4	Grade 5	
Grade 1	0	0	0	0	0	0
Grade 2	0	424	5	0	0	429

						(53.0%)
Grade 3	0	14	158	8	0	180 (22.2%)
Grade 4	0	0	3	76	15	94 (11.6%)
Grade 5	0	0	0	1	106	107 (13.2%)
	0	438 (54.1%)	166 (20.5%)	85 (10.5%)	121 (14.9%)	810
Weighted Kappa	0.94911					
Standard error	0.00730					
95% CI	0.93479 to 0.96342					

Figure Legends

Figure 1. Bland-Altman Plot of the difference between assessors versus the mean of the two assessors image quality grades of the CEM-530 specular microscope across the central, paracentral and peripheral regions.

Figure 1.



Arithmetic mean	0.01235
95% CI	-0.004078 to 0.02877
P (H_0: Mean=0)	0.1405
Lower limit	-0.4544
95% CI	-0.4825 to -0.4263
Upper limit	0.4791
95% CI	0.4510 to 0.5072

Vibration and percussion induced crystalline lens subluxation and secondary angle closure glaucoma: A case series

Lim Joshua^{1*}, Claire Peterson Wong¹, Kiew Sieh Yean¹

¹Singapore National Eye Centre, Singapore

Introduction

Traumatic crystalline lens subluxation or dislocation have previously been described. Forces generated by ubiquitous objects, though seemingly innocuous can also precipitate zonulopathy and downstream sequela.

Methods

We describe two cases of secondary angle closure induced by crystalline lens subluxation and pupil block. These were precipitated by vibrational and percussive forces from a pneumatic drill and incorrect use of a massage gun.

Results

A 53 year-old Chinese male presented with redness and reduced vision in the right eye (OD). He denied a history of prior ocular trauma, however was noted to have used a pneumatic drill whilst at work. Presenting visual acuity (VA) in OD was 6/18; An asymmetrically shallow right anterior chamber with significant phacodonesis was noted on exam. Anterior chamber angles were closed in all quadrants on gonioscopy. The left eye (OS) was unremarkable. Intraocular pressure (IOP) of OD was 70mmHg. Ultrasound Biomicroscopy (UBM) of OD showed lax zonular attachments in all quadrants. He subsequently underwent phacoemulsification with placement of a 3-piece intraocular lens in the capsular bag.

A 60 year-old Chinese female presented with pain, redness and reduced vision in OD, following the use of a handheld massage gun on her face. Visual acuity in OD was counting fingers. A hazy cornea, and shallow anterior chamber with grade 2 iridocorneal touch was noted on exam. Gonioscopy was difficult to perform due to corneal haze. OS was unremarkable. IOP in OD was 79mmHg. UBM revealed 8 clock

hours of zonular loss. She subsequently underwent a trans pars plana vitrectomy, lensectomy and iris fixated intraocular lens implant.

Conclusion

This is the first case series describing secondary angle closure precipitated by vibration and percussive forces. These indirect or direct forces can induce zonular weakness or loss. Potential occupational health or consumer implications exist. Clear history, augmented by UBM analysis can reliably clinch the diagnosis.

An excellent visual outcome of traumatic optic neuropathy (TON) – A case report

LING D¹, Wong W¹, Lim T²

¹Sarawak General Hospital, Kuching, Malaysia, ²Hospital Sibul, Sibul, Malaysia

Introduction

TON can cause severe vision loss resulting from acute injury to the optic nerve either by direct or indirect trauma. We are reporting a case of excellent visual recovery of TON after removal of extraconal foreign body and high dose steroid.

Methods

Case Report

Results

A 23-year-old man who collided with the underside of a boat while surfacing from the sea. His left upper eyelid was lacerated approximately 3.5 cm and a piece of broken goggles pierced into the extraconal space above the eyeball. Post-trauma, he complained of blurred vision in his left eye and bleeding with pain at the wound site. His visual acuity (VA) in the affected eye was 3/60 with a positive relative afferent pupillary defect (RAPD) and moderately restricted extraocular movement superiorly and inferiorly. Examination of the anterior segment was unremarkable except for a subconjunctival haemorrhage. The fundus was normal, without swelling or haemorrhage. Urgent computed tomography (CT) of the brain and orbit revealed a foreign body that had entered the extraconal space, with fracture of the left orbital roof and medial wall, without retrobulbar collection or extraocular muscle entrapment. The foreign body was located above the eyeball and was pushing it downward. He underwent left eye removal of extraconal foreign body and left upper lid toilet and suturing. He also received high-dose systemic steroids. After completion of 12 doses of methylprednisolone, his VA improved to 6/9, while left eye RAPD remained positive (grade 1).

Conclusion

Timely removal of the associated foreign body and a high dose of corticosteroid may achieve a good visual outcome in TON as seen in this case.

Evaluation of Intraocular Pressure After Water Drinking Test in Patients with Unilateral Hemifacial Spasm

Jin Rong Low¹²³, Chee Wai Wong¹³⁴⁵⁶, Jing Liang Loo¹³⁵⁶⁷⁸, Dan Milea³⁵⁷⁸, Shamira A Perera¹²³⁵, Yi Fang Lee³⁹, Si Rui Ng¹²³, Mani Baskaran²³⁵, Monisha Esther Nongpiur²³⁵, Sharon Lee Choon Tow¹³⁵⁶⁷⁸

¹Department of Cataract and Comprehensive Ophthalmology, Singapore National Eye Centre, Singapore. ²Department of Glaucoma, Singapore National Eye Centre, Singapore. ³Singapore Eye Research Institute, Singapore, ⁴Department of Surgical Retina, Singapore National Eye Centre, Singapore, ⁵Ophthalmology and Visual Sciences Academic Clinical Program, Duke-NUS Medical School, Singapore, ⁶Department of Ophthalmology, National University of Singapore, Singapore, ⁷Department of Neuro-Ophthalmology, Singapore National Eye Centre, Singapore, ⁸Neuroscience and Behavioral Disorders Program, Duke-NUS Medical School, Singapore, ⁹Department of Training and Education, Singapore National Eye Centre, Singapore.

Introduction

The aim of the study is to examine the baseline intraocular pressure (IOP) and its changes after performing a water drinking test (WDT) in patients with unilateral hemifacial spasm (HFS).

Methods

In this prospective observational study, patients aged 21 years and above diagnosed with unilateral HFS were recruited from the Singapore National Eye Centre between January 2015 and August 2016. The unaffected eye of each patient served as a matched control. An interviewer-administered standardized questionnaire on HFS symptoms and ophthalmic examination was performed. Automated perimetry, optical coherence tomography (OCT) of the optic nerve head, color disc stereophotography and water drinking test (WDT) were done. The

primary outcome measure was the difference in IOP between eyes affected by HFS and fellow eyes at baseline and at 15, 30 and 45 minutes of the WDT.

Results

Fifty-four patients with unilateral HFS were included. Mean age was 59.8 ± 9.9 years (range, 37.0-84.0). Of these, 54% were female and 94% were Chinese. Mean baseline IOP was significantly higher in eyes with HFS (13.9 ± 3.1 mmHg) compared to fellow eyes (13.3 ± 2.8 mmHg) ($p=0.008$). There was no significant difference in absolute or percentage change in IOP from baseline between the 2 groups at 15, 30 and 45 minutes of the WDT. Mean vertical cup-disc ratio (VCDR) on clinical examination was significantly higher in eyes with HFS (0.5 ± 0.2) compared to fellow eyes (0.4 ± 0.2) ($p=0.02$). There was no significant difference between the groups for visual field parameters and mean retinal nerve fiber layer thickness on OCT.

Conclusion

Hemifacial spasm is associated with a small but significant difference in mean baseline IOP and VCDR between affected and fellow eyes. However, when eyes affected by HFS and fellow eyes were challenged with the WDT, both responded in similar ways.

References

1. Wilkins RH. Hemifacial spasm: a review. *Surg Neurol*. 1991;36 (4):251–277. doi:10.1016/0090-3019(91)90087-P
2. Killer HE, Rust O, Muller O, et al. Unilateral glaucomatous damage in a patient with hemifacial spasm. *Ophthalmologica*. 1999;213 (4):273–275. doi:10.1159/000027436
3. Lee MS, Harrison AR, Grossman DS, et al. Risk of glaucoma among patients with benign essential blepharospasm. *Ophthal Plast Reconstr Surg*. 2010;26(6):434–437. doi:10.1097/IOP.0b013e3181d3da43
4. Nicoletti AG, Zacharias LC, Susanna R Jr, et al. Patients with essential blepharospasm and glaucoma: case reports. *Arq Bras Oftalmol*. 2008;71(5):747–751. doi:10.1590/S0004-274920080005 00028

5. Erdogan C, Rengin Y, Ceyhun A, et al. Effect of hemifacial spasm on intraocular pressure measurement. J Ophthalmol. 2018. Article ID 3621215.

Conjunctiva malignant melanoma: A Case Series

Mad Isa M^{1,3}, Zakaria H², Alias R¹, Abdul Rahim A², Yaakub A³

¹Department of Ophthalmology, Hospital Sultan Abdul Halim, Sungai Petani, Malaysia, ²Department of Ophthalmology, Hospital Sultanah Bahiyah, Alor Setar, Malaysia, ³Department of Ophthalmology & Visual Sciences, School of Medical Sciences, Universiti Sains Malaysia, Kubang Kerian, Malaysia

Introduction

Conjunctival malignant melanoma is an unusual ocular malignancy with high morbidity and fatality incidence.

Method

Case series.

Results

Case 1: 50 years old lady presented with left eye progressive painless swelling for 7 months and noted fleshy growth extending from inferior conjunctiva covering visual axis. She underwent incisional biopsy and histopathological results showed conjunctiva malignant melanoma. Contrasted CT orbit showed left eye inferior conjunctival lesion extending to left lateral canthus/extraconal region. Left eye exenteration was performed, and histopathological examination showed nodular melanoma confined to the conjunctiva and cornea.

Case 2: 59 years old gentleman presented with right conjunctival painless progressive pigmented swelling for 5 months. The examination revealed diffuse pigmentation involving the plica semilunaris and part of caruncle. He underwent right eye incision biopsy. Histopathological examination showed malignant melanoma, thus right eye excisional biopsy of conjunctiva and debridement of cornea pigmented lesion with amniotic membrane graft was done.

Case 3: 83 years old gentleman presented with right painless lower conjunctiva pigmented lesions for 6 months. Examination revealed right eye pigmented raised lesion over lower lateral aspect of tarsal conjunctiva. Histopathological examinations show malignant acquired melanosis; superficially invasive, Stage IIA. Patient underwent right lower lid excisional biopsy and bilateral eyes conjunctiva biopsy. Histopathology examination for right lower tarsal conjunctiva and eyelid biopsy is superficially invasive melanoma (pT2a), and bilateral conjunctival biopsy is primary acquired melanosis.

Conclusion

It is rare but potentially devastating tumor that carries poor prognosis if prompt treatment is not done.

Klebsiella pneumoniae endophthalmitis: a case series

Mad Isa M^{1,2}, Alias R¹, Yaakub A²

¹Department of Ophthalmology, Hospital Sultan Abdul Halim, Sungai Petani, Malaysia, ²Department of Ophthalmology & Visual Sciences, School of Medical Sciences, Universiti Sains Malaysia, Kubang Kerian, Malaysia

Introduction

Klebsiella pneumoniae endophthalmitis carries devastating consequences as part of its invasive condition. Thus, to report 3 cases of endogenous endophthalmitis due to invasive *Klebsiella pneumoniae* in Hospital Sultan Abdul Halim.

Method

Case series.

Results

Case 1: 69 years old man with underlying diabetes mellitus presented with 2 days history of sudden blurred vision, pain, and redness of right eye. Right eye visual acuity was light perception, RAPD positive, anterior chamber cells 4+ with hypopyon mixed with blood. Right eye loculation demonstrated on B-scan and was treated as endogenous endophthalmitis. *Klebsiella pneumoniae* was reported over blood culture and vitreous tap.

Case 2: 58 years old man with underlying diabetes mellitus presented with painless right eyes blurring vision for 3 days. Right eye visual acuity was 6/60 with sluggish pupils. Conjunctiva injected, anterior chamber cells 3+ and no hypopyon seen. Funduscopy examination showed dense vitritis over the right eye. B-scan revealed loculation and was treated as endogenous endophthalmitis. The vitreous tap reported *Klebsiella pneumoniae*.

Case 3: 51 years old lady with underlying diabetes mellitus presented with sudden onset bilateral eyes blurring of vision and redness for 4 days associated with cough

and lethargy for 1 week. Bilateral eyes visual acuity was light perception with sluggish pupils. Both conjunctivae were injected, chemosis and hypopyon seen. Fundus showed bilateral eye dense vitritis, B-scan showed loculation, and was treated as bilateral eye endogenous endophthalmitis with community-acquired pneumonia. *Klebsiella pneumoniae* was reported over blood, sputum, and vitreous tap culture.

Conclusion

Klebsiella pneumoniae endophthalmitis is invasive and carries a poor prognosis if prompt treatment is not initiated.

A Rare case of Nodular Posterior Scleritis with presumed Ocular Tuberculosis

Maffar N^{1,2}

¹Hospital Sultanah Aminah, Johor Bahru, Johor Bahru, Malaysia, ²Universiti Sains Malaysia, Kubang Kerian, Kelantan, Kubang Kerian, Malaysia

Introduction

Posterior scleritis is a rare and sight-threatening condition potentially causing irreversible blindness. The presentation can be varied and often misdiagnosed. Diagnosis can be very challenging and requires proper ophthalmological assessment. Consequences of delayed treatment include permanent loss of vision.

Methods

Case Report

Results

A case of nodular posterior scleritis in a 35 years old lady who presented with left eye poor vision with recurrent painful intermittent redness for two weeks. Ophthalmic examinations reveal visual acuity of hand movement, left eye inferior half cornea has corneal opacity, with cells activity of 1+, inferior scleral thinning with uveal tissue hue and posterior synechiae. Fundus examination shows swollen optic disc, vitritis with inferior subretinal fluid and subretinal mass from optic disc and along inferior arcade.

ESR and CRP was raised with positive Mantoux test of 17mm. MRI of orbit shows there is nodularity and wall thickening of the posterior and inferior aspect of the globe, measuring 14x7.5mm, with enhancing lesion.

Patient was started on NSAID, anti-tuberculosis and systemic steroid. Her vision improved from hand movement to BCVA of 6/36.

Conclusion

The diagnosis of nodular posterior has to be one of differential diagnosis in patients with a subretinal or choroidal mass. Complete and thorough history and

clinical ophthalmological assessment is crucial to avoid underdiagnosed or misdiagnosed of this rare condition. This condition is usually curable with non-steroidal anti-inflammatory drugs and/or systemic steroids.

References

1. Ozkaya A, Alagoz C, Koc A, Ozkaya HM, Yazıcı AT. A case of nodular posterior scleritis mimicking choroidal mass. *Saudi Journal of Ophthalmology*. 2015;29(2):165-8.
2. Moreira-Neto C, Moreira Jr C, Tolentino D, Duker JS. Nodular posterior scleritis associated with presumed ocular tuberculosis: A multimodal imaging case report. *American Journal of Ophthalmology Case Reports*. 2019;16:100558.
3. Agrawal R, Lavric A, Restori M, Pavesio C, Sagoo MS. NODULAR POSTERIOR SCLERITIS: Clinico-Sonographic Characteristics and Proposed Diagnostic Criteria. *RETINA*. 2016;36(2):392-401.

Encephalocraniocutaneous lipomatosis - case report

Minakshisundaram D^{1,2}, Asiff N², Hamzah N², Samsudin A¹

¹Pusat Perubatan Universiti Malaya, Lembah pantai, Malaysia, ²Hospital Tunku Azizah, Kuala Lumpur, Malaysia

Introduction

Encephalocraniocutaneous lipomatosis (ECCL), or Haberland syndrome is a neurocutaneous disorder of the skin, eye and central nervous system.

Methods

Case report.

Results

A 3-month-old girl was referred to our centre for further management of a large left eye (LE) corneal dermoid. At birth, a small lesion was noted. Magnetic resonance imaging (MRI) around the first week of life showed an extraocular dermoid cyst measuring 1mm x 7mm, dysplasia of the left greater wing of sphenoid, closed lip schizencephaly of the left parietal lobe, and polymicrogyria. During examination under anaesthesia at our centre, we found the corneal dermoid had grown in size to 17mm x 16mm, with posterior embryotoxon, a hazy cornea and intraocular pressure of 26 mmHg. With the anterior segment dysgenesis and secondary glaucoma, we started Gutt Timo-Comod BD. Serial MRI imaging at 4 months of age revealed further enlargement of the dermoid, a new left retrobulbar mass, and multiple intracranial lipomas. A diagnosis of ECCL was made at this point, based on the MRI and clinical findings. A multidisciplinary meeting was held among ophthalmology, neurosurgery, radiology and otorhinolaryngology (ORL) teams, which concluded that surgical intervention such as tumour debulking might cause more harm than benefit. Hence, she was planned to undergo close monitoring with serial MRIs and only for surgical intervention, in the presence of airway compression or presence of any neurological deficits.

Conclusion

The ophthalmologist should be aware of the specific set of radiological and clinical findings in ECCL, as management of the condition would best be through a multidisciplinary approach.

References

1. Haberland C. Encephalocraniocutaneous Lipomatosis. *Arch Neurol.* 1970;22(2):144. doi:10.1001/archneur.1970.00480200050005
2. Moog U. Encephalocraniocutaneous lipomatosis. *J Med Genet.* 2009;46(11):721-729. doi:10.1136/jmg.2009.066068
3. Chandravanshi S. Encephalocraniocutaneous lipomatosis: A case report and review of the literature. *Indian J Ophthalmol.* 2014;62(5):622. doi:10.4103/0301-4738.133521
4. Naous A, Shatila A, Naja Z, Naja A, Rajab M. Encephalocraniocutaneous Lipomatosis. *Child Neurol Open.* 2015;2(1):2329048X1455329. doi:10.1177/2329048x14553297
5. Sharifi M, Namdari M. Encephalocraniocutaneous lipomatosis (Fishman syndrome): A rare neurocutaneous syndrome. *J Curr Ophthalmol.* 2016;28(3):155-158. doi:10.1016/j.joco.2016.06.004

Bilateral papilloedema as the first presenting feature of unilateral acoustic neuroma

Mohd Jaffar N¹, Zahari M², Kamaruddin H¹

¹Hospital Selayang, Selayang, Malaysia, ²University of Malaya, Kuala Lumpur, Malaysia

Introduction

Acoustic neuroma is a benign tumour derived from Schwann cells of the myelin sheath. The most common presenting symptoms in acoustic neuromas are unilateral hearing loss, tinnitus, vertigo, headaches, and facial numbness. Ophthalmic manifestations are much less common.

Methods

Case report

Results

A 49-year-old man presented to Eye Clinic with floaters and headache. He did not exhibit typical features such as hearing loss, tinnitus or vertigo. Fundus examination showed bilateral papilloedema. Neuroimaging demonstrated large left cerebellopontine angle tumour. Surgical resection and biopsy of the tumour later confirmed the diagnosis of acoustic neuroma.

Conclusion

Bilateral papilloedema as the first manifestation of acoustic neuroma is rare. Features of bilateral optic disc swelling in a relatively good visual acuity must always raise the suspicion of an intracranial pathology and appropriate imaging is essential.

References

1. Gal TJ, Shinn J, Huang B. Current epidemiology and management trends in acoustic neuroma. *Otolaryngol Head Neck Surg*. 2010 May;142(5):677-81.
2. van Meter WS, Younge BR, Harner SG. Ophthalmic manifestations of acoustic neurinoma. *Ophthalmology*. 1983 Aug;90(8):917-22.
3. Matos RJ, Gil PN, Pires JM, Lopes N. Advanced Vestibular Schwannoma: A Case of Optic Disc Oedema without Hydrocephalus. *Neuroophthalmology*. 2016 May 27;40(5):222-224.
4. Jefferis JM, Raoof N, Carroll T, Salvi SM. Optic nerve sheath fenestration in patients with visual failure associated with vestibular schwannoma. *Br J Neurosurg*. 2019 Aug;33(4):402-408.
5. Dunn LT. Raised intracranial pressure. *J Neurol Neurosurg Psychiatry*. 2002 Sep;73 Suppl 1(Suppl 1):i23-7.

Doctor COVID: A Natural Language Processing-based Artificial Intelligence Chatbot to Support Accurate Public Health Education in the Pandemic Era

Wei Yan NG^{1,2,3}, Lily Wei Yun YANG², Xiao Feng LEI⁴, Daniel Shu Wei TING^{1,2,3}

¹Singapore National Eye Centre, Singapore

²Singapore Eye Research Institute, Singapore

³Duke–NUS Medical School, National University of Singapore

⁴Agency for Science, Technology and Research, Institute of High Performance Computing, Singapore

Introduction

In a pandemic, accurate public health education is challenging due to factors including fear-driven misinformation and a surfeit of data, amongst others. Chatbots utilizing natural language processing (NLP), a type of conversational artificial intelligence (AI), have emerged as a promising solution which can internalize human language and respond to questions. In this study, we aimed to develop an NLP-based AI chatbot – Doctor Covid – to support public health education in the pandemic era.

Methods

In this study, domain knowledge and external authoritative websites were used to create the dataset. Each main question stem was subsequently expanded into more sub-questions to widen the training dataset. Standard British English, and consistent grammar and structure were adopted. Training and testing dataset was created with a 5:1 ratio. Three NLP models were utilized: the largest English transformer model (en_core_web_lg) from open-source spaCy; Bidirectional Encoder Representations from Transformers (BERT) model trained on our training dataset; and Ensemble model utilizing both features from SpaCy and BERT. Each test question was assessed with a similarity score at 0.9 threshold. The top and top 3 answers were assessed for accuracy.

Results

The training dataset involved 2703 questions, comprising 1290 local and 1413 global (47.7%:52.3%) questions, whereas the testing dataset involved 500 questions. The Ensemble Model achieved the best performance, with an overall and top 3 accuracy of 86.2% (92.0%:84.8%) and 94.4% (97.0%:93.8%) respectively. The Transformer model achieved an overall and top 3 accuracy of 71.0% (69.5%:77.0%) and 80.4% (79.0%:85.0%); whilst the BERT model achieved 85.2% (88.0%:84.5%) and 93.2% (95.0%:92.8%), respectively.

Conclusion

In our study, the best performing model was able to achieve a high degree of accuracy for both local and global dataset. It holds considerable promise as a healthcare chatbot for clinical implementation to meet the healthcare needs of the current pandemic.

Evaluating the impact of individual eyes on binocular function using activities of daily living tasks in patients with age-related macular degeneration

Claire L Peterson MD^{1-3*}, Lynn LY Tan BSc¹, Kai Ting Sim BSc¹, Lisa Ong¹, Tan Zhen Kiat¹, Tan Yan Wen OD⁴, Joy Heng OD⁴, Eva Fenwick,^{2,3} PhD, Ian YS Yeo MD¹⁻³, Wong Tien Yin MD¹⁻³, Gemmy Cheung MD¹⁻³, Ecosse Lamoureux^{2,3} PhD, Anna CS Tan MD¹⁻³

¹Singapore National Eye Centre, Singapore, ²Singapore Eye Research Centre, Singapore, ³Duke-NUS Medical School, Singapore, ⁴Singapore General Hospital, Singapore

Aim

To evaluate the impact of individual eyes on binocular function in patients with age-related macular degeneration (AMD).

Methods

Prospective case-controlled cohort study comparing visual function of 36 patients with visual impairment (BCVA \leq LogMAR0.4) in at least 1 eye from AMD with 36 healthy controls. Visual acuity, contrast sensitivity and 5 activities of daily living task tests (ADLTs) – 1)reading, 2)facial-expression recognition, 3)item-search task, 4)money-counting task and 5)drink-making – were assessed using monocular and binocular vision. Welch's T-test was used to determine significance in difference between means. Spearman correlation was used to test relationships between the better-seeing or worse-seeing eye and binocular function in both groups. R-Studio was used for analysis with p-values \leq 0.05 considered significant.

Results

In the AMD cohort, there was a strong correlation between the better-seeing eye and binocular function for speed of reading ($\rho=0.53, p<0.001$), money-counting ($\rho=0.32, p<0.05$), item-search task ($\rho=0.64, p<0.001$) and efficiency of drink-making ($\rho=0.52, p=0.001$). The worse-seeing eye had a strong correlation with binocular function for speed of drink-making ($\rho=0.91, p<0.001$) and a medium

correlation for identifying items correctly ($\rho=0.37, p=0.03$) and facial expression recognition ($\rho=0.44, p=0.02$). In the control group, both the better-seeing and worse-seeing eyes had strong correlations with most ADLTTs, such as speed of reading ($\rho>0.90, p<0.001$), drink-making ($\rho>0.84, p<0.001$), efficiency of money-counting ($\rho>0.83, p<0.001$) and identifying items correctly ($\rho=0.77, p<0.001$).

Conclusion

In AMD, the better-seeing eye has more impact on binocular function for ADLTTs that require finer vision while the worse-seeing eye has more impact on ADLTTs that rely on gross vision. Having a larger difference in visual acuity between eyes also impacts binocular function. Therefore, maintaining good vision in both the better-seeing and worse-seeing eye in AMD is important in order to achieve good overall binocular function.

[293]

Tables

Table 1: Baseline characteristics of persons with age-related macular degeneration (AMD) versus normal controls

Baseline demographics	AMD (N=36)	Controls (N=36)	P value *
Age (SD)	72.08 ±	65.19 ± 7.71	<0.001
Male (%)	7.55	55%	1.00
Chinese race (%)	52.5%	80.6%	0.10
	91.7%		
Unaided visual acuity (logMAR± SD)			
○ Worse eye vision	1.14 ± 0.54	0.25 ± 0.20	<0.001
○ Better eye vision	0.35 ± 0.23	0.13 ± 0.14	<0.001
○ Binocular vision	0.27 ± 0.17	0.09 ± 0.09	<0.001
Best-corrected visual acuity (logMAR ± SD)			
	0.95 ± 0.57	0.08 ± 0.09	<0.001
○ Worse eye vision	0.22 ± 0.20	0.01 ± 0.05	<0.001

○ Better eye vision	0.17 ± 0.15	0.00 ± 0.06	<0.001
○ Binocular vision			
Contrast sensitivity			
○ Worse eye vision	0.79 ± 0.50	1.58 ± 0.11	<0.001
○ Better eye vision	1.43 ± 0.26	1.60 ± 0.09	0.001
○ Binocular vision	1.49 ± 0.21	1.67 ± 0.04	<0.001

Worse eye and better eye vision defined based on best corrected visual acuity, *p-value calculated by Fischer exact probability tests for categorical parameters and student's t-test for quantitative variables

Table 2: Performance-based measurement of the activities of daily living tasks tests (ADLTT) in persons with age-related macular degeneration (AMD) versus normal controls adjusted for age*

ADLTT	AMD	Controls	P value**
1) Reading tests			
6. Speed (words/min)			
○ Worse eye vision	62.49	± 139.69	± <0.001
○ Better eye vision	47.14	36.10	0.20
○ Binocular vision	131.88	± 145.56	± 0.18
Correct words	42.96	35.76	
○ Worse eye vision	135.52	± 149.72	± 0.02
○ Better eye vision	46.81	37.63	0.25
○ Binocular vision			0.71
7.	142.43	± 153.78	±
	23.93	5.14	
	152.91	± 154.55	±
	4.92	6.05	
	152.66	± 153.57	±
	13.39	3.84	
2) Facial Expression#			
8. Mean number of expressions			

identified (max=5)	3.22 ± 0.83	3.44 ± 0.76	0.33
○ Worse eye vision	3.50 ± 0.71	3.50 ± 0.60	0.99
○ Better eye vision	3.75 ± 0.75	3.64 ± 0.81	0.58
○ Binocular vision			
9.			
3) Item search task ^			
10. Time taken to complete task (s±SD)			
○ Worse eye vision	11.56 ± 8.52	9.78 ± 5.39	0.35
○ Better eye vision	8.56 ± 4.43	8.33 ± 2.75	0.82
○ Binocular vision	7.10 ± 4.00	7.61 ± 4.12	0.59
Number of items identified correctly (max=4)	3.77 ± 0.45	3.76 ± 0.39	0.94
○ Worse eye vision	3.90 ± 0.21	3.84 ± 0.31	0.34
○ Better eye vision	3.84 ± 0.36	3.83 ± 0.32	0.87
○ Binocular vision			
11.			
4) Money counting task ^			
12. Time taken to complete task (s±SD)			
○ Worse eye vision	21.44 ± 6.46	± 3.51	<0.001
○ Better eye vision	16.18 ± 6.28	± 5.37	0.08
○ Binocular vision	9.43 ± 7.91	4.07 ± 1.56	<0.001
Efficiency of task test completion (max score =9)	8.59 ± 5.48		
		8.88 ± 0.37	<0.001
○ Worse eye vision	7.54 ± 1.83	8.97 ± 0.35	0.02
○ Better eye vision	8.61 ± 0.74	8.95 ± 0.18	0.26
○ Binocular vision	8.88 ± 0.26		
5) Drink making task ^			
13. Time taken to complete task (s±SD)			
○ Worse eye vision	54.19 ± 44.38	± 0.03	
○ Better eye vision	21.28 ± 12.07		0.11
○ Binocular vision	51.60 ± 44.35	± 0.16	
Efficiency of task test completion	20.89	12.88	

(max score =15)	48.02	±	40.98	±	0.06
○ Worse eye vision	24.14		12.88		0.96
○ Better eye vision					0.43
○ Binocular vision	14.23 ± 1.46		14.78 ± 0.28		
	14.71 ± 0.54		14.72 ± 1.10		
	14.93 ± 0.34		14.98 ± 0.08		

*ANCOVA used to adjust for impact of age on means

**p-value calculated by Welch's t-test for quantitative variables

Mean score taken over 3 attempts ^Mean values taken over 2 attempts

Table 3: Impact of difference of visual acuity between eyes on binocular function for ADLTs*

ADLT	AMD (One eye > 6/15, One eye ≤6/15) N=28	group Control group (BE > 6/15) N= 36	p- value**
1) Reading tests			
○ Speed (words/min)	143.3 ± 48.2	150.5 ±	0.52
○ Correct words	152.0 ± 15.2	37.6	0.59
		153.6 ± 3.8	
2) Facial Expression			
14. Mean number of expressions identified (max=5)	3.76 ± 0.79	3.66 ± 0.81	0.66
3) Item search task			
○ Time taken to complete task (s±SD)	8.91± 4.07 3.80 ± 0.40	87.47 ± 4.13	0.61 0.65
○ Number of items identified correctly (max=4)		3.84 ± 0.32	
4) Money counting task			
○ Time taken to complete task (s±SD)	6.84 ± 3.66 8.94 ± 0.23	4.04 ± 1.57 8.96 ± 0.19	<0.001 0.73
○ Efficiency of task test completion (max score =9)			
5) Drink making task			
○ Time taken to complete task (s±SD)	48.1 ± 25.6 14.9 ± 0.4	40.2 ± 12.9 15.0 ± 0.4	0.14 0.33
○ Efficiency of task test completion (max score =15)			

*ANCOVA used to adjust for impact of age on means. Values for Control group differ from Table 1 due impact of the difference in sample size of the AMD group on ANCOVA analysis.

**Welch's T-test

Table 4: Spearman correlation of Monocular VS Binocular Function for ADLTT S

Parameter	AMD (rho)	p- value	Controls (rho)	p- value
Best Corrected Visual Acuity				
○ Worse eye vision	-0.12	0.48	0.62	<0.001
○ Better eye vision	0.82	<0.001	0.88	<0.001
Contrast Sensitivity				
○ Worse eye vision	0.37	0.03	0.62	<0.001
○ Better eye vision	0.73	<0.001	0.61	<0.001
ADLTT				
1) Reading tests				
15. Speed (words/min)				
○ Worse eye vision	0.11	0.60	0.91	<0.001
○ Better eye vision	0.53	<0.001	0.90	<0.001
Correct words				
○ Worse eye vision	-0.05	0.83	0.31	0.08
○ Better eye vision	0.22	0.16	0.14	0.44
16.				
2) Facial Expression				
17. Mean number of expressions identified (max=5)				
○ Worse eye vision	0.44	0.02	0.47	0.006
○ Better eye vision	0.41	0.009	0.34	0.06
3) Item search task				
18. Time taken to complete task (s±SD)	0.46	0.004	0.23	0.21
○ Worse eye vision	0.64	<0.001	0.69	<0.001
○ Better eye vision				
Number of items identified correctly (max=4)	0.37	0.03	0.77	<0.001
○ Worse eye vision	0.21	0.20	0.77	<0.001

○ Better eye vision				
19.				
4) Money counting task				
20. Time taken to complete task				
(s±SD)	0.06	0.73	0.78	<0.001
○ Worse eye vision	0.32	0.045	0.42	0.02
○ Better eye vision				
	0.03	0.87	0.83	<0.001
Efficiency of task test	0.03	0.86	0.89	<0.001
completion (max score =9)				
○ Worse eye vision				
○ Better eye vision				
21.				
5) Drink Making task				
22. Time taken to complete task				
(s±SD)	0.91	<0.001	0.87	<0.001
○ Worse eye vision	0.85	<0.001	0.84	<0.001
○ Better eye vision				
Efficiency of task test				
completion (max score =15)	0.36	0.04	-0.08	0.66
○ Worse eye vision	0.52	0.001	-0.05	0.78
○ Better eye vision				
23.				

A Rare Complication of Herpes Zoster Ophthalmicus

Phang D^{1,2}, Ettikan J², Abdul Aziz H², Vendargon F², Sonny Teo K¹

¹Department of Ophthalmology and Visual Science, School of Medical Sciences, Universiti Sains Malaysia, 16150 Kubang Kerian, Malaysia, ²Department of Ophthalmology, Hospital Sultanah Aminah, 80000 Johor Bharu,, Malaysia

Introduction

Retrobulbar optic neuritis is a rare complication of herpes zoster infection. It usually presents with progressive vision loss.

Methods

Case report

Results

We herein report a case of herpes zoster infection in an immunocompromised patient who developed retrobulbar optic neuritis. Patient presented with left progressive blurring of vision of 1 week duration. On examination, visual acuity of the left eye was hand movement with reduced optic nerve function test. Fundus examination was normal.

Blood investigation was done to rule out infective causes and revealed Human immunodeficiency virus (HIV) positive. Other blood investigations were unremarkable. Magnetic resonance imaging showed features of hyperintense of intraorbital segment of optic nerve on T2 weighted image.

He received 2 weeks of intravenous acyclovir and switched to oral route for 1 month. After the completion of treatment, visual acuity was counting fingers.

Conclusion

Herpes zoster retrobulbar optic neuritis is a sight threatening infection. Infection screening should be done

Case series of children with rare ocular complications associated with Rabson-Mendenhall Syndrome

Stanley Poh^{1,2}, Gavin Tan^{1,2,3}

¹Singapore National Eye Centre, Singapore

²Ophthalmology and Visual Sciences Academic Clinical Program, Duke-NUS, Singapore

³Singapore Eye Research Institute, Singapore

Introduction

Rabson-Mendenhall syndrome (RMS) is a rare genetic disease characterized by severe insulin resistance caused by insulin-receptor gene defect.¹ Ocular associations are not well described. One case report described a teenage girl with unilateral neovascular glaucoma and tractional retinal detachment secondary to RMS.²

Methods

We report a case series of 3 children belonging to the same family, two of which are non-identical twins, who presented with severe diabetic retinopathy and maculopathy.

Results

All three siblings had compound heterozygous mutation in the insulin receptor gene. The older sister presented at age 13 with bilateral optic disc swelling secondary to diabetic papillopathy and severe diabetic macular oedema (Figure 1). Her disease improved with bilateral anti-vascular endothelial growth factor (anti-VEGF) treatment with significant improvement in vision. The younger pair of twins were aged 14 at time of presentation. First twin had proliferative diabetic retinopathy (PDR), diabetic papillopathy and exudative-type neurosensory retinal detachment in both eyes. She is still undergoing a course of anti-VEGF therapy and have seen some improvement in vision. Second twin presented with acute red eye with subacute visual loss. She had bilateral PDR and left neovascular glaucoma

(NVG). She received anti-VEGF therapy and pan-retinal photocoagulation. In view of dense vitreous haemorrhage limiting examination and treatment, she eventually underwent left eye vitrectomy, endolaser and silicon oil surgery.

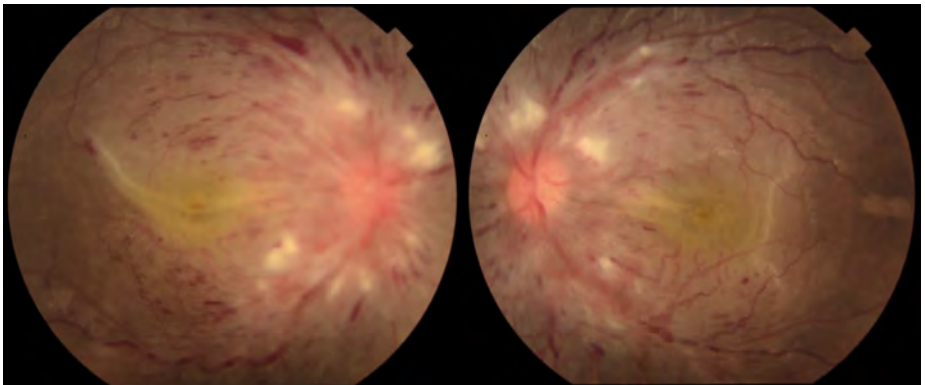
Conclusion

RBS can have severe diabetic related eye disease at presentation with exudative retinal detachment and diabetic papillopathy mimicking papilloedema. In the absence of NVG, they can do well with early intensive and sustained anti-VEGF treatment. Children with RMS should have annual retinal screening initiated to prevent irreversible visual loss.

References

1. Hassan I, Altaf H, Yaseen A. Rabson-Mendenhall Syndrome. Indian J Dermatol. 2014;59(6):633.
2. Kumar K, Kohli P, Kumar G. Rare Ocular Complication in a Patient with Rabson-Mendenhall Syndrome. Indian J Pediatr. 2021 Feb 1;88(2):192–192.

Figure 1



PRESsure to the brain, sinister to the eyes

Ponnaiah P¹, Mansor A¹, Muhammad Nordin M¹, Buandasan K¹

¹Hospital Sultanah Nora Ismail, Batu Pahat, Malaysia

Introduction

Posterior Reversible Encephalopathy Syndrome (PRES) is a severe, rare and reversible clinicoradiological syndrome characterised by headache, seizures, altered mental status and visual loss. White matter vasogenic oedema affecting parieto-occipital lobes is seen on brain imaging. PRES is commonly associated with acute hypertension.

Method

Case report

Results

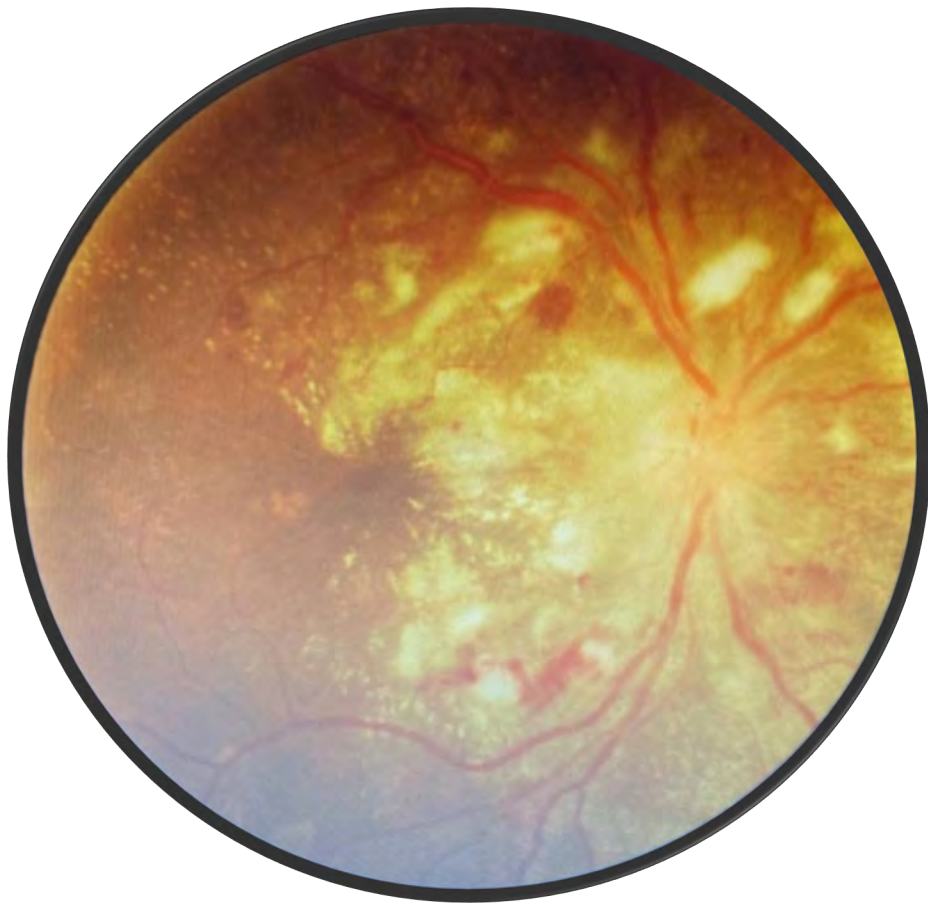
A 22years old, male with underlying hypertension presented with sudden onset bilateral blurring of vision, headache and body weakness. There was no history of fever, seizures, loss of consciousness or high risk behaviour. His blood pressure was 199/124mmHg. Other systemic examinations were normal. Visual acuity of left eye was counting finger and right eye 6/60. Anterior segment was normal with no relative afferent pupillary defect. Dilated fundoscopy showed optic disc swelling, inferior exudative retinal detachment, massive exudation at posterior pole, peripapillary splinter haemorrhages, cotton wool spots, and macula star bilaterally. Full blood count, renal profile, infective and autoimmune screening, cerebrospinal fluid analysis were unremarkable. Computed tomography of brain showed left parieto-occipital ill defined hypodensity suggestive of PRES. His blood pressure was normalised with oral antihypertensives. During the next three weeks, visual acuity improved to 6/24 over left eye and 6/18 over right eye. Fundoscopy showed similar findings as initial assessment with presence of Elschnig spots. However, patient defaulted follow ups.

Conclusion

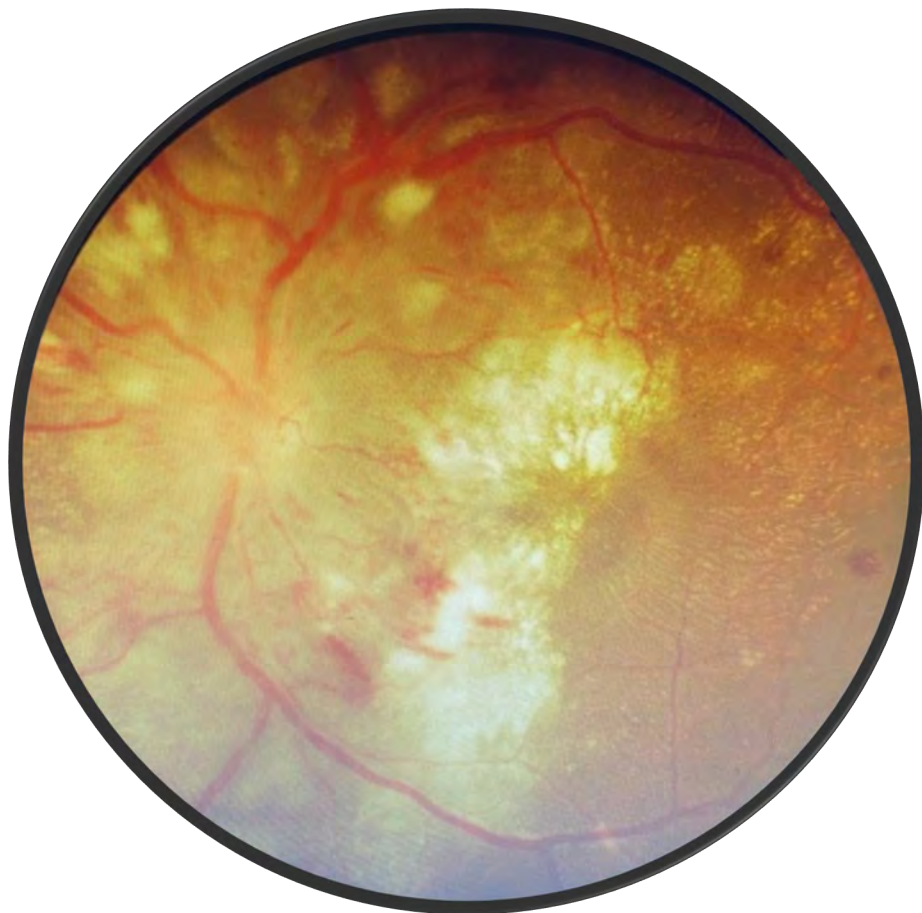
PRES is reversible with early diagnosis and treatment. Delay in treatment may cause irreversible neurological damage and even death. A high index of suspicion and prompt treatment can reduce morbidity and mortality in PRES.

References

1. Fischer M, Schmutzhard E. Posterior reversible encephalopathy syndrome. *Journal of Neurology*. 2017 Aug;264(8):1608-16.
2. Chou MC, Lee CY, Chao SC. Temporary visual loss due to posterior reversible encephalopathy syndrome in the case of an end-stage renal disease patient. *Neuro-ophthalmology*. 2018 Jan 2;42(1):35-9.
3. Mohanty G, Sridivya C. Posterior reversible encephalopathy syndrome [PRES]- A rare and reversible cause of vision loss. *IJAR*. 2020;6(5):66-8.
4. Guerriero S, Ciracì L, Centoducati T, Pignatelli F, Lamargese V, Salvati A, Dicuonzo F. Bilateral visual loss as presenting symptom of posterior reversible encephalopathy syndrome in a patient with HIV/tuberculosis coinfection: a case report. *Case Reports in Ophthalmological Medicine*. 2012 Jan 1;2012.
5. Hinduja A. Posterior reversible encephalopathy syndrome: clinical features and outcome. *Frontiers in neurology*. 2020 Feb 14;11:71.



17A



1B

Figure 1(A) & (B): Bilateral funduscopy showing optic disc swelling, massive exudation and peripapillary splinter haemorrhages.

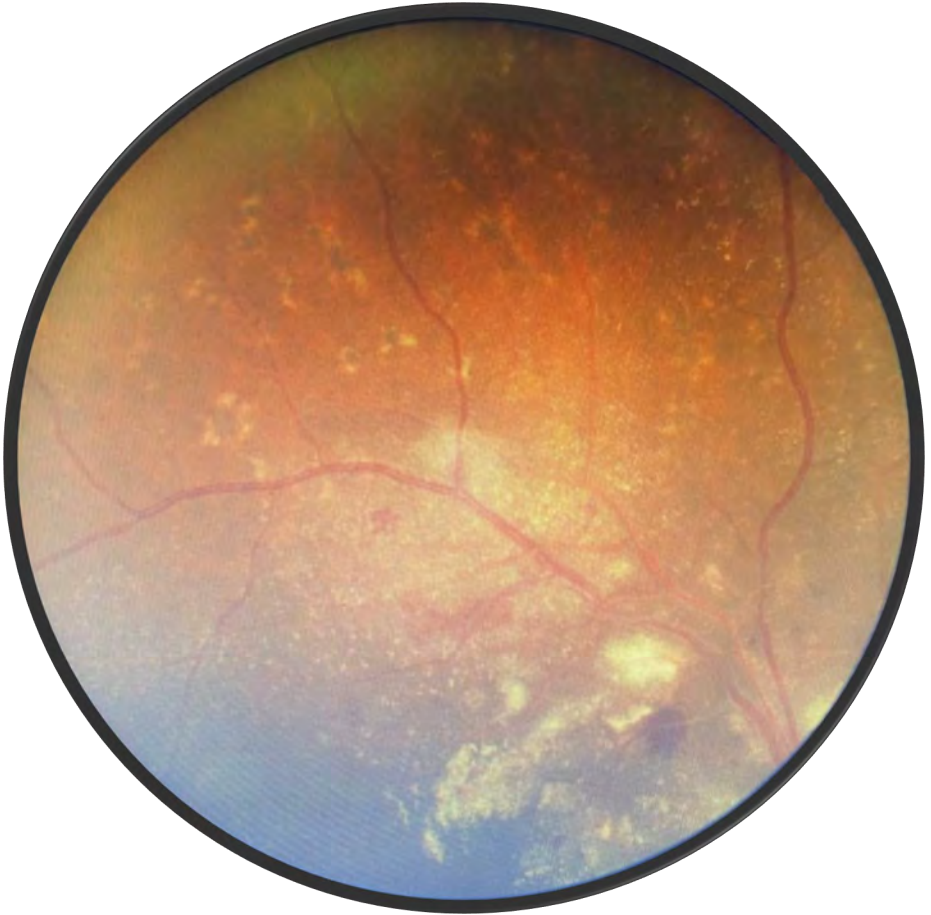


Figure 2: Fundoscopy showing Elschnig spots at periphery

Eyelid Tumours in Northern Malaysia: A Five-Year Review

Qi Xian ^{t1,2}, Chew-Ean T¹, Abdul Rahim A¹, Nasaruddin R²

¹Hospital Sultanah Bahiyah, Alor Setar, Malaysia, ²Hospital Universiti Kebangsaan Malaysia, Cheras, Malaysia

Introduction

The majority of eyelid tumours are benign in nature and constitute 82%-98% of all eyelid tumours. This study aimed to explore the prevalence and frequency of histopathological diagnoses of eyelid tumours encountered in Hospital Sultanah Bahiyah (HSB), Malaysia, from 2016 to 2020.

Methods

This study is a case series of 136 patients with eyelid tumours who underwent eyelid biopsy.

Result

Twenty-three (17%) patients were below 18 years old, 64 (47%) patients were between 19 and 64 years old and 49 (36%) patients were more than 65 years old. The mean age in this study was 47.9 ± 25.4 years. The most common benign eyelid tumours were dermoid cyst (31, 22.8%), melanocytic nevus (19, 14%), granuloma (17, 12.5%), squamous cell papilloma (13, 9.6%) and epidermal cyst (12, 8.8%). Most of the benign eyelid tumours occurred at the upper lids (79.8%), and most of the malignant eyelid tumours occurred at the lower lids (81.8%). The most common malignant eyelid tumours were basal cell carcinoma (BCC) (6, 14.3%), followed by malignant lymphoma (3, 6.1%) and sebaceous gland carcinoma (2, 4.1%). All malignant lymphomas were primary lymphoma. Five were extranodal marginal zone lymphoma of mucosa-associated lymphoid tissue (MALT), and one was follicular lymphoma. All cases with benign and malignant tumours required only a single surgery for excision, and none of the cases had a recurrence.

Conclusion

There were limited references to the epidemiology of histopathological diagnoses of eyelid tumours in Malaysia. Although benign lesions comprise the majority of eyelid tumours, it is essential to delineate between benign and malignant eyelid tumours.

Orbital Tumours in Northern Malaysia: A five year review

[Qi Xian T^{1,2}](#), Chew Ean T¹, Abdul Rahim A¹, Nasaruddin R²

¹Hospital Sultanah Bahiyah, Alor Setar, Malaysia, ²Hospital Universiti Kebangsaan Malaysia, Cheras, Malaysia

Introduction

This study was conducted to examine demographic statistics and histopathological diagnoses of orbital biopsies cases referred to the Oculoplastic subspecialty of the Ophthalmology department in Hospital Sultanah Bahiyah, Kedah, from 2016 to 2020.

Method

This study is a case series of 28 patients who underwent orbital biopsy.

Results

A total of 34 orbital biopsies from 28 patients were recorded. The mean age was 48.3 ± 19.1 years old. 22 (78.4%) cases manifested unilaterally and six (21.4%) manifested bilaterally. The commonest presentations were orbital mass (36.6%) and proptosis (24.4%). The mean duration of the presentation was 16.2 ± 19.5 months. Fourteen (50.0%) patients underwent orbital biopsy within six months of symptoms. 52.8% of the tumours are situated at supero-temporal region of the orbit. 53.0% (18) situated in extraconal space of orbit. Out of all, 23 (67.6%) cases were benign and 11 (32.4%) cases were malignant. All were primary in origin (100%). The commonest orbital tumours reported were malignant lymphoma (29.4%), reactive lymphoid hyperplasia (14.7%), non-caseating granulomatous inflammation (11.8%), non-granulomatous inflammation (5.9%) and cavernous haemangioma (5.9%). Of all 10 malignant lymphomas from eight patients (two were bilateral eyes) were all mucosa-associated lymphoid tissue (MALT) of primary non-Hodgkin lymphomas. None of the cases were reported to be metastasis from the systemic spread.

Conclusion

Malignant tumours are more common in the elder age group especially malignant lymphoma which is in contrast to Caucasian populations. Understanding the relative incidence of these various orbital tumours is essential to patient evaluation and management.

Rare Ocular Manifestation of COVID-19 Infection

[Saihani S¹](#), Md Said H¹

¹Tengku Ampuan Rahimah Hospital, Klang, Malaysia

Introduction

The first case of COVID-19 in Malaysia has been reported in January 2020 and since then, the disease has been causing significant mortality and morbidity. Other than the usual presentations of fever and respiratory symptoms, there are also reported cases of neurological and ocular manifestations of COVID-19.

We report a case of wall-eyed bilateral internuclear ophthalmoplegia (WEBINO) secondary to subacute brainstem infarct following COVID-19 infection in an otherwise healthy individual.

Methods

A case report

Results

A 55 year old Malay lady, previously without comorbidity, was diagnosed as COVID-19 Category 4. She was presented to emergency department at day 5 of infection complaining of sudden onset of horizontal diplopia for 3 days associated with an outward deviation of the right eye, dizziness and walking imbalance. On examination there were adduction deficit involving both eyes with contralateral nystagmus on abduction of both eyes.

Patient has been co-managed by medical, neuromedical and ophthalmology team. MRI brain was reported as subacute brainstem infarct. Other investigations done to rule out demyelinating or autoimmune disease or underlying infections were negative. During the course of admission, patient was treated with intravenous favipiravir, intravenous corticosteroid and prophylactic antibiotic cover. She was started on anticoagulant and statin.

We noted significant improvement of her ocular conditions after 1 month.

Conclusion

Ocular and neurological manifestations of COVID-19 have been recognized as significant causes of morbidity that can affect patients' quality of life. These complications remained to be a challenge and need to be addressed and recognized early by the attending clinicians. Although WEBINO is a rare ocular manifestation of COVID-19 infection, multidisciplinary management is essential in treating the patients.

Better Late than Never, Delayed Diagnosis of Orbital Schwannoma: A Case Report

Samsu S¹, Goh Y¹, Hanafi H²

¹Miri Hospital, Miri, Malaysia, ²Queen Elizabeth Hospital, Kota Kinabalu, Malaysia

Introduction

Orbital schwannoma is a rare benign orbital tumor originating from the Schwann cells. Depending on the tumour size, the clinical presentation varies, ranging from asymptomatic to sight threatening complications.

Methods

Case report.

Results

A 57-year-old gentleman first presented with left eye proptosis in 2003 and was diagnosed with left nonspecific orbital inflammation (NSOI) in a tertiary hospital. He was managed conservatively and defaulted follow-up. His proptosis progressively worsened over the years causing significant globe displacement, limited extraocular movements and visual impairment, which prompted him to seek for medical attention in our centre. Systemic examination was unremarkable. Radiological imaging revealed a retrobulbar mass with optic nerve encasement, globe displacement, and local mass effect. Intraorbital excision biopsy of the tumour confirmed the diagnosis of orbital schwannoma. Blood investigation including tumour markers was normal. Two months post-operatively, his visual function and cosmetic appearance improved.

Conclusion

Orbital schwannoma should be considered as one of the differential diagnosis in slow growing orbital mass. Early assessment of orbital tumours through radiological imaging with corresponding histopathological evaluation and prompt management is warranted to prevent complications.

Keywords

orbital schwannoma, tumour, proptosis, optic neuropathy

A Case of Bilateral Acute Anterior Uveitis Post Covid-19 Vaccine

Siow S¹

¹Hospital Sultanah Aminah Johor Bahru, Kota Tinggi, Malaysia

Introduction

The coronavirus disease 19 (Covid-19) pandemic hit the world like a storm and to alleviate a public health crisis, several vaccines were developed and approved for inoculation in Malaysia. Side effects of mass immunisation including ocular inflammation have been reported amidst growing public concerns with respect to the safety profile of vaccines. We thus present a case of bilateral acute anterior uveitis after two doses of Oxford AstraZeneca Vaccine.

Methods

Case report

Results

A 56-year-old lady with no known medical illness presented to Hospital Sultanah Aminah ophthalmology department with decrease in bilateral vision ten days after receiving the second dose of her Oxford AstraZeneca Vaccine (ChAdOx1 nCoV-19). On examination, her best corrected vision was 6/12 respectively. There were 3+ anterior chamber cells in both eyes without posterior involvement. A diagnosis of bilateral acute anterior uveitis was made. A panel of autoimmune and infective screenings were sent and returned negative. Her symptoms completely resolved after a 3-months course of topical steroids.

Conclusion

Ocular inflammation may occur after vaccination, but findings based on this case report demonstrated topical steroids are effective in managing acute anterior uveitis.

References

1. Ilaria Testi et al. Ocular inflammatory events following Covid-19 vaccination: a multinational case series *Journal of Ophthalmic Inflammation and Infection* 2022;12:4
2. LJ Pan et al. Bilateral uveitis after inoculation with COVID-19 vaccine. *International Journal of Infectious Disease* 2021;12:116-118
3. Manal A. Alhamazani et al. A Case of Recurrent Acute Anterior Uveitis After the Administration of COVID-19 Vaccine. *Cureus* 2022
4. XL Ng et al. The Eye of the Storm: COVID-19 Vaccination and the Eye. *Ophthalmology and Therapy* 2022;11:81-100
5. Elena Bolletta et al. Uveitis and Other Ocular Complications following COVID-19 Vaccination *J. Clin. Med.* 2021;10:5960.

Coats' disease or retinoblastoma: A computed tomography dilemma

Soh W¹, Low Z², Chan L², Bahari N², Rahmat J²

¹Sarawak General Hospital, Kuching, Malaysia, ²Hospital Kuala Lumpur, Kuala Lumpur, Malaysia

Introduction

Coats' disease (CD) is a great mimicker of retinoblastoma in both clinical presentation and radiological findings, which lead to diagnostic challenge.

Methods

Case report.

Results

A 7-year-old boy was referred for opinion on imaging features of retinoblastoma. He complained of left eye (LE) leukocoria and exotropia (XT) since 3 years old. He did not seek treatment until a month ago when he complained of LE blurring of vision. There was no past medical history or family history of malignancy. On examination, vision was 6/9 for right eye (RE) and counting fingers for LE. Ocular alignment showed 15-degree XT in the LE. A LE xanthocoria was present. Otherwise, both eyes anterior segment examination was unremarkable. RE posterior segment was normal. LE posterior segment showed a spheroidal macular lesion 1 disc in diameter with surrounding massive subretinal exudation. The area of macula adjacent to the lesion was thickened. Temporal peripheral retina showed telangiectasia and subretinal exudation. Computed tomography showed an enhancing soft tissue lesion in the LE macula with a small foci of calcification within, suggestive of retinoblastoma. Based on the patient's history and examination of fundus, a diagnosis of CD was established. He underwent laser photocoagulation in the areas of telangiectatic vessels and peripheral retina temporally, combined with intravitreal injection of ranibizumab and orbital floor triamcinolone injection.

Conclusion

The diagnosis of CD is primarily based on a detailed history, thorough clinical examination and ancillary tests. Although, CD and retinoblastoma can have overlapping imaging features, which makes diagnosis difficult, a confident diagnosis of CD was made from the thorough clinical ophthalmic evaluation.

Telecare: replacing the one-week post-operative clinic visit with a phone call for phacoemulsification cataract surgery

Shayne S Tan¹, Jane S Lim¹ Merrelynn Hong¹, Alvin WJ Teo¹, Yi Fang Lee¹, Tin Aung¹, Daniel SW Ting¹, Rahat Husain^{*1}

1. Singapore National Eye Centre

Introduction

Assessing the safety of replacing the post-operative week (POW) 1 clinic visit with a nurse-led telephone call, after uncomplicated phacoemulsification cataract surgery, by studying the incidence of complications and unexpected management changes (UMCs).

Methods

Retrospective review of cases between June 2015 to June 2021 was performed. Patients received a phone call at POW1, and a post-operative month (POM) 1 clinic visit. The main outcome measure was the incidence of UMCs within POM1. The symptoms and reasons for unscheduled patient-initiated visits, additional procedures, and post-operative visual acuity (VA) worse than 6/12 were also collected.

Results

32500 cases were recruited, with 1905 (5.8%) having a UMC within POM1. 1134 (3.5%) had unscheduled visits, 34 (0.1%) required additional procedures, 5 (0.02%) developed retinal detachment, and only 1 had endophthalmitis (0.003%). The most common complaints for unscheduled visits were pain (35.2%), redness (22.0%), and blurring of vision (17.6%). The most common indication for additional surgical procedures was retained lens material (30.4%), followed by Descemet membrane detachment and malrotation of toric lenses (13.0% each). VA was worse than 6/12 in 6.7%, commonly due to pre-existing ocular conditions unrelated to cataract surgery.

Conclusion

Only 5.8% of patients who underwent uncomplicated phacoemulsification cataract surgery with a telephone consult at POW1 had UMCs, with significant adverse events being extremely rare. This suggests that the POW1 visit can be safely replaced with a telephone consult.

References

1. Westborg I, Monestam E. Follow-Up After Cataract Surgery - Comparison of the Practice in Two Institutions with the Aim of Optimize the Routine. *Clin Ophthalmol.* 2020;14:1847-1854.
2. Eloranta H, Falck A. Is an ophthalmic check-up needed after uneventful cataract surgery? A large retrospective comparative cohort study of Finnish patients. *Acta Ophthalmol.* 2017;95(7):665-670.
3. Borkar DS, Lains I, Eton EA, et al. Incidence of Management Changes at the Postoperative Week 1 Visit after Cataract Surgery: Results from the Perioperative Care for IntraOcular Lens Study. *Am J Ophthalmol.* 2019;199:94-100.
4. Bouaziz M, Schlesinger M, Kang JJ, Kim G. Incidence of postoperative week 1 management changes after resident-performed phacoemulsification cataract surgery. *BMC Ophthalmology.* 2022;22(1):15.

Tables

Table 1: Incidence of UMCs after POD1 to POM1, and the post-operative VA

	N (%)= 32500 (from June 2016 onwards)
Retinal break requiring retinopexy	32 (0.1)
Retinal detachment requiring surgical repair	5 (0.02)
Initiation of anti-inflammatory drops at POM1	712 (2.2)
Endophthalmitis	1 (0.003)
Unscheduled corrective surgical procedures	34 (0.1)
Raised IOP (>24mmhg) at POM1 visit (from 2019 onwards)	63 (0.5)*
Patient-initiated visit to outpatient clinic or emergency department "walk-in"	1134 (3.5)
Telephone advice from nurse at POW1 to return to outpatient clinic or emergency department	8 (0.02)
Overall UMC rate (unique to each patient)	1905(5.8)
VA worse than 6/12 (to take POD2 to POM6 group) (from 2019 onwards)	864 (6.7) **

* denominator excluded those with no IOP recorded and before 2019

** denominator excluded those with no VA recorded and before 2019

Table 2: Symptoms for walk-ins before POM1 (10% sample from 2019 onwards)

Symptom	No. of symptoms, n=91 (%)*
Pain	32 (35.2)
Redness	20 (22.0)
BOV	16 (17.6)
Floaters/floaters	10 (11.0)
Visual disturbances	1 (1.1)
Others	10 (11.0)
Not recorded	2 (2.2)

*One patient can have more than 1 symptom; total no. of patients = 62

Table 3: Reasons for walk-ins before POM1 (10% sample from 2019 onwards)

Total		N=74 (%) *
Cornea		
	Eye drop toxicity	19 (25.7)
	Dry eyes	5 (6.7)
	Corneal oedema	4 (5.4)
	Subconjunctival haemorrhage	2 (2.7)
	Conjunctivitis	2 (2.7)
	Poor ocular surface	2 (2.7)
Uveitis		7 (9.5)
Retina		
	Posterior vitreous detachment	6 (8.1)
	Epiretinal membrane	1 (1.4)
	Macular scar	1 (1.4)
	Irvine-Gass syndrome	1 (1.4)
Eyelids		
	Blepharitis	4 (5.4)
	Chalazion/styes	1 (1.4)
Anxiety (normal examination)		8 (10.8)
Refractive error		1 (1.4)
Not recorded		1 (1.4)
Endophthalmitis		1 (1.4)
Others		8 (10.8)

* One patient can have more than 1 reason for a walk-in visit; total no. of reasons = 74

Table 4: Reasons for post-operative unscheduled surgery (10% sample from 2019 onwards)

Total		N=23 (%)
Related to cataract operation		
	IOL-related	
	Malrotation of toric IOL	3 (13.0)
	Refractive surprise	3 (13.0)
	Haptic in anterior chamber	1 (4.3)
	Retained lens fragment/soft lens matter	7 (30.4)
	Cornea	
	Descemet membrane detachment	3 (13.0)
	Corneal decompensation requiring a Descemet Membrane Endothelial Keratoplasty (DMEK)	1 (4.3)
	Post-op endophthalmitis	1 (4.3)
	Others (Eyelash in anterior chamber)	1 (4.3)
Not related to cataract operation		
	Proliferative diabetic retinopathy with vitreous haemorrhage	2 (8.7)
	Epiretinal membrane	1 (4.3)

Table 5: Reasons for post-operative VA worse than 6/12 (10% sample from 2019 onwards)

Total		N=119 (%)
Cornea		
	Corneal oedema	6 (5.04)
	Poor ocular surface	4 (3.36)
	Pre-existing corneal scars	3 (2.52)
	Eye-drop toxicity	1 (0.84)
	Infective keratitis	1 (0.84)
Uveitis		5 (4.20)
Retina		
	Age related macular degeneration	20 (16.8)
	Epiretinal membrane	13 (10.92)
	Macular scar	13 (10.92)
	Diabetic macular oedema	6 (5.04)
	Irvine-Gass syndrome	6 (5.04)
	Retinal vein occlusions	3 (2.52)
	Macular hole	3 (2.52)
Refractive error*		11 (9.24)
Not recorded		5 (4.20)
Posterior capsular opacification		2 (1.68)
Pre-existing glaucoma		3 (2.52)
Others		14 (11.76)

* Cases were classified as refractive error if manifest refraction was not performed at the defined cut-off visit as detailed in our methodology, but was performed for the subsequent visit and patients were refracted to better than 6/12

Metabolomics in Corneal diseases

[Alvin Teo Wei Jun](#)¹, Yu-Chi Liu^{1,2}

¹Department of Cornea and External Eye Disease, Singapore National Eye Centre, Singapore 168751, Singapore.

²Cornea and Refractive Surgery Group, Singapore Eye Research Institute, Singapore 169856, Singapore.

Introduction

The metabolome is the collection of all metabolites in a biological system and reflects cellular activity. There is a growing number of metabolomics applications aiming to identify biomarkers for diagnosis, therapy guidance and treatment response in ophthalmology. It allows insight into ocular diseases including corneal diseases. Literature was reviewed.

Methods

Four international databases (Web of Science, PubMed, Scopus, and Google Scholar) were searched. Key words “metabolomics”, “cornea”, “nuclear magnetic resonance spectroscopy”, “mass spectrometry” were used. The study followed PRISMA guidelines.

Results

Metabolomic profiles were investigated in dry eye, keratoconus, contact lens users, refractive surgery and diabetic keratopathy.

Rat studies found that glycerophospholipid metabolism was altered in the central cornea and aqueous humour of dry eyes¹. The glycerophospholipid pathway is essential for cell membrane dynamics and play a role in mediators of signal transduction. Betaine, found in increased levels, is capable of stabilizing cell volume and inhibit apoptosis, showing possibly an early cytoprotective mechanism against dry eye.

Contact lens users had 11 biomarkers identified which participate in energy metabolism and lipid metabolism. The energy metabolism was disturbed. Anti-

inflammatory factor neuroprotection D1 was reduced and inflammatory factors like arachidonic acid were upregulated².

Lenticule samples were obtained from small incision lenticule extraction. Findings suggest that there is a higher concentration of inflammation related metabolites and lower antioxidants in older patients, Influencing the rates of corneal wound healing³.

Keratoconic corneas had elevated levels of lactate with upregulation of lactate/pyruvate ratios, along with a decrease in reduced and oxidised glutathione ratios when compared with healthy corneas. All these indicate that these corneas undergo significant oxidative stress.

Kynurenic acid has antioxidant properties. In Type 1 Diabetes, there was an upregulation of xanthurenic acid and kynurenic acid in corneal stroma, suggesting dysregulation of kynurenine metabolism⁴.

Conclusion

Metabolomics allows for greater understanding of corneal diseases, allowing for targeted solutions to alleviate disease.

References

1. Chen X, et al. In situ metabolic profile and spatial distribution of ocular tissues: New insights into dry eye disease. *Ocul Surf.* 2022;24:51-63.
2. Panaser A, et al. Evidence of lipid degradation during overnight contact lens wear: gas chromatography mass spectrometry as the diagnostic tool. *Invest Ophthalmol Vis Sci.* 2014;55(3):1797-1804.
3. Li M, et al. Age-related differences in corneal nerve regeneration after SMILE and the mechanism revealed by metabolomics. *Exp Eye Res.* 2021;209:108665.
4. Priyadarsini S, et al. Complete metabolome and lipidome analysis reveals novel biomarkers in the human diabetic corneal stroma. *Exp Eye Res.* 2016;153:90-100.

"White Scarf Covering My Eye"

[Teo Y^{1,2}](#), Yeoh S¹, Juliana J¹, Zunaina E², Hemlata K³

¹Hospital Melaka, Melaka, Malaysia, ²Universiti Sains Malaysia, Kubang Kerian, Malaysia, ³Hospital Kuala Lumpur, Kuala Lumpur, Malaysia

Introduction

To report a case of right eye Conjunctival Intraepithelial Neoplasm (CIN 3)

Methods

Case report

Results

A 65-years-old Malay lady with diabetes mellitus presented with small whitish lesion over her right eye. It had progressively increased in size for 1year. Her best corrected visual acuity in her right eye (OD) was 6/36 and 6/12 in her left eye (OS). Anterior segment examination of her right eye (OD) showed conjunctival lesion over cornea from 9-3 o'clock measuring 4x7mm with presence of feeding vessels. Posterior segment examination was unremarkable. Other ocular examinations were normal. During the subsequent follow up after 3months, there was a significant increase in the size of conjunctival lesions, obscuring her vision partially. Excisional biopsy for the conjunctival lesion was done. Histopathological examination showed dysplastic squamoid epithelial cells involving two third to near full thickness of the epithelial layer and exhibit moderately pleomorphic, hyperchromatic nuclei with abundant eosinophilic cytoplasm suggesting of Conjunctival Intraepithelial Neoplasm (CIN 3).

Conclusion

CIN's clinical presentations can be varied, including gelatinous, leukoplakic, or papilliform. In view of malignant potential, these lesions must be differentiated carefully and treated accordingly. Histopathological examination is needed for a definite diagnosis.

Descemet Stripping Endothelial Keratoplasty versus Penetrating Keratoplasty in Bullous Keratopathy: A 2-years analysis in graft survival and outcomes in Hospital Kuala Lumpur

Wai Y¹, Pee X², Lai Y¹, Alias R¹

¹Hospital Kuala Lumpur, Malaysia, ²Sarawak General Hospital, Kuching, Malaysia

Introduction

To compare the 2-years graft survival and outcomes of Descemet stripping endothelial keratoplasty (DSEK) and penetrating keratoplasty (PK) for the treatment of bullous keratopathy (BK).

Methods

This is a retrospective study, BK patients who underwent DSEK or PK from 2015 to 2019 in Hospital Kuala Lumpur with a minimal post-operative follow-up of 2 years. Outcome measures included best-corrected visual acuity (BCVA), graft survival and complications. A total of 26 DSEK cases and 32 PK cases were included.

Results

At 2 years, graft survival rates were quite similar in 2 groups (DSEK 80.8% vs PK 75%, $p=0.765$). The mean follow-up period was 35.2 months in DSEK and 31.4 months for PK ($p=0.465$). The cumulative survival rates were slightly higher in the DSEK group (DSEK 73.1% vs PK 53.1%, $p=0.119$), but the result was not statistically significant. Post-operative complications were associated with higher graft failure in both groups ($p=0.02$). DSEK group has better post-operative BCVA (LogMAR DSEK 0.42 vs PK 0.83, $p=0.002$).

Conclusion

Similar graft survival rates were observed with both corneal transplant techniques in 2 years among Malaysian patients with bullous keratopathy. Post-operative

complication can cause higher risk of graft failure. DSEK produced better post-operative BCVA compared to PK.

Rare Presentation of Right Hemispheric Hemorrhage with Bilateral Ptosis and Bilateral Upgaze Palsy

Wong K¹, Yong M¹, Mohd Khialdin S¹, Wan Abdul Halim W¹

¹Universiti Kebangsaan Malaysia, Cheras, Malaysia

Introduction

Upgaze palsy with bilateral ptosis can be challenging in anatomical localization due to various pathways for the respective function. It can also be overlooked in unilateral stroke due to the lack of laterality in ophthalmic manifestations. We are reporting a case of bilateral ptosis and upgaze palsy secondary to unilateral hemispheric hemorrhage.

Method

Case report.

Case report

A 46-year-old gentleman presented with left-sided hemiplegia due to acute hemorrhagic stroke secondary to hypertensive emergency. He was referred for his concurrent bilateral ptosis and bilateral upgaze palsy. His Glasgow coma score was full. His visual acuity, pupil size and pupil reflexes were normal. His ocular motility was full, except limited bilateral upgaze. Bilateral mild ptosis was noted without fatiguability. Computer tomography of brain revealed acute extensive intraparenchymal hemorrhage involving right basal ganglia, frontal and temporal lobes. There was intraventricular extension into third ventricle and subarachnoid extension to Sylvian fissure with obstructive hydrocephalus. Emergency right craniotomy and clot evacuation was performed with subsequently resolved hydrocephalus. However, bilateral ptosis and upgaze palsy persisted. In the absence of lesion in brainstem and vertical gaze centre, bilateral ptosis and upgaze palsy can be caused by (1) involvement of upgaze fibers that cross at level of posterior commissure which is in proximity with third ventricle, (2) possible lateralization of levator palpebrae superioris function in unilateral, non-dominant

hemisphere as variant in normal individuals. Concurrent bilateral ptosis can be associated with bilateral hypotropia because of fascial attachments between levator palpebrae superioris and superior rectus.

Conclusion

Acute bilateral ptosis and upgaze palsy suggest possibility of unilateral hemispheric hemorrhage with intraventricular extension, despite absence of direct involvement of brainstem or vertical gaze centre.

Opacification of two piggyback hydrophilic acrylic sulcus intraocular lens (IOL) despite clear hydrophobic acrylic intracapsular IOL after vitrectomy with gas

Yap Guan Hui², Rachel S Chong ^{1,2,3,4}, Debra Q Y Quek ^{2,3}, Anita S Chan ^{2,3}, Steve K Seah⁵, Shamira A Perera^{2,3}

¹Genome Institute of Singapore, Agency for Science Technology and Research, Singapore

²Singapore National Eye Centre, Singapore

³Singapore Eye Research Institute, Singapore

⁴Duke-NUS Medical School, Singapore

⁵Steve Seah Eye Centre, Singapore

Introduction

We report two cases of opacified piggyback hydrophilic acrylic sulcus IOL despite uninvolved hydrophobic acrylic intracapsular IOL following trans pars plana vitrectomy with gas.

Methods

Case series of 2 patients, with explanted IOLs examined under transmission electron microscopy and light microscopy with Von Kossa stain.

Results

Patient 1: 62 year-old lady who underwent left phacoemulsification with implantation of SN60T3 hydrophobic acrylic toric IOL (Alcon, Fort Worth, TX) and Sulcoflex 653F sulcus hydrophilic acrylic multifocal lens (Rayner, Brighton, UK).

Patient 2: 50 year-old lady who underwent right phacoemulsification with implantation of T-flex Aspheric 623T hydrophobic acrylic toric IOL (Rayner, Brighton, UK) with Sulcoflex 653F sulcus multifocal lens (Rayner, Brighton, UK).

Both patients had rhegmatogenous retinal detachment 5 years later, and underwent uneventful TPPV, scleral buckle, and intravitreal C_3F_8 (patient 1) and C_2F_6 (patient 2). 2 years post TPPV, both had gradual blurring of vision with diffuse opacification of the sulcus IOL and clear intracapsular IOL. Identical IOL models in their fellow eye remained clear.

In both, sulcus IOLs were explanted. Transmission electron microscopy and light microscopy with Von Kossa (both patients) and Toluidine blue (Patient 2) staining of explanted hydrophilic sulcus IOLs and showed multiple calcific granular deposits beneath the anterior surface of the lens.

Conclusion

Hydrophobic material seems a better choice for patients requiring procedures involving intraocular gas. Patients with hydrophilic acrylic lenses due to undergo these procedures should be counselled on possibility of IOL opacification, necessitating surgery to restore vision.

References

1. Yildirim TM, Auffarth GU, Labuz G et al. Material analysis and optical quality assessment of opacified hydrophilic acrylic intraocular lenses after pars plana vitrectomy. *Am J Ophthalmol*. 2018;193:10-19.
2. Park DI, Ha SW, Park SB, Lew H. Hydrophilic acrylic intraocular lens optic opacification in a diabetic patient. *Jpn J Ophthalmol*. 2011;55:595-9.
3. Timur M, Yildirim, Ramin Khoramnia, Sonja K. Schickhardt, Donald J. Munro, Patrick R. Merz, Hyeck-Soo Son, Ingo Lieberwirth, Gerd U. Auffarth, Variation in intraocular lens calcification under different environmental conditions in eyes with supplementary sulcus-supported lenses, *American Journal of Ophthalmology Case Reports*, Volume 19,2020,100797,ISSN 2451-9936

4. Maclean KD, Apel A, Wilson J, Werner L. Calcification of hydrophilic acrylic intraocular lenses associated with intracameral air injection following DMEK. *J Cataract Refract Surg.* 2015;41:1310-
5. Giers BC, Tandogan T, Auffarth G et al. Hydrophilic intraocular lens opacification after posterior lamellar keratoplasty – a material analysis with special reference to optical quality assessment. *BMC Ophthalmol.* 2017;17(1):150.
6. Gartaganis SP, Prahs P, Lazari ED et al. Calcification of hydrophilic acrylic intraocular lenses with a hydrophobic surface: laboratory analysis of 6 cases. *Am J Ophthalmol.* 2016;168:68-77.

Myelin Oligodendrocyte Glycoprotein Antibody–Associated Optic Neuritis in COVID-19 patient

Zaini M¹, Mohd Zain A¹, Gan Y¹, Md Din N¹

¹National University of Malaysia Medical Centre, Bandar Sri Permaisuri, Malaysia

Introduction

SARS-CoV-2 viral infection has led to manifestation of multisystemic symptoms include respiratory, gastrointestinal, neurological, cardiac and ophthalmic involvement. We would like to report a case of myelin oligodendrocyte glycoprotein (MOG) related optic neuritis in SARS-CoV-2 (COVID-19) patient.

Methods

Case Report

Results

A 36-year-old Malay gentleman with underlying hypertension presented with the first episode of both eyes progressively worsening blurring of vision for one week associated with retrobulbar pain. There were no other neurological symptoms. He had a history of fever 1 week prior to eye symptoms where he was tested positive for COVID-19. The patient received COVID-19 vaccines booster a month prior to the disease onset. On examination, his vision was hand motion OD and 6/18 OS. RAPD was present on the right eye with optic nerve dysfunction. Anterior segments were unremarkable. Fundus examination showed bilateral optic disc swelling. MRI revealed multifocal hyperintense subcortical white matter lesions. Optic nerves appeared normal with no enhancement seen. Blood investigation showed positive serum myelin oligodendrocyte glycoprotein (MOG) antibody. Intravenous methylprednisolone was commenced followed by oral prednisolone where his vision and ocular symptoms were markedly improved. The oral prednisolone was tapered with the addition of azathioprine. At one month, the disease is stable with no recurrence.

Conclusion

Optic neuritis can be one of the presentations in COVID-19 infection. MOG IgG antibody-mediated optic neuritis is possible to occur concurrently with COVID-19 infection. MOG antibody testing is important for diagnosis as MOG-related disease is associated with frequent recurrence and thus requires long-term immunosuppressant

References

1. S. Zhou, E. C. Jones-Lopez, D. J. Soneji, C. J. Azevedo, and V. R. Patel, "Myelin Oligodendrocyte Glycoprotein Antibody-Associated Optic Neuritis and Myelitis in COVID-19," *Journal of Neuro-Ophthalmology*, vol. 40, no. 3, pp. 398–402, Sep. 2020
2. M. A. Azab, S. F. Hasaneen, H. Hanifa, and A. Y. Azzam, "Optic neuritis post-COVID-19 infection. A case report with meta-analysis," *Interdisciplinary Neurosurgery*, vol. 26, p. 101320, Dec. 2021.
3. Gold DM, Galetta SL, Neuro-Ophthalmologic Complications of Coronavirus Disease 2019 (COVID-19), *Neuroscience Letters* (2020).

Hypertensive choroidopathy in a teenage girl

Zohari Z^{1,2}, Eyat J¹, Ngoo Q^{1,2}, Zunaina E²

¹Ophthalmology Clinic, Hospital Raja Perempuan Zainab II, 15990, Kota Bharu, Malaysia, ²Department of Ophthalmology and Visual Science, School of Medical Sciences, Universiti Sains Malaysia, 16150, Kubang Kerian, Malaysia

Introduction

Malignant hypertension causes acute damage to the brain, eyes, and kidneys. Hypertensive choroidopathy is rare and often seen in younger patients who have acute elevations in blood pressure.

Method

Case Report

Results

A 14-year-old Malay girl with history of uncontrolled hypertension for one year, complicated with end-stage renal failure and anemia, presented to the emergency department with sudden onset of seizure. It was preceded with painless progressive blurring of vision in both eyes for 4 months and headache for 2 days. Her visual acuity was counting fingers in the right eye and hand movement in the left eye. Both fundi showed features of hypertensive choroidopathy with bilateral disc swelling with extensive hard exudates surrounding the optic disc, macular edema, macular stars, Elschnig spots and Siegrist streaks. Systemic blood pressure was 180/144 mmHg during admission. Computed tomography scan of the brain showed presence of multiple white matter hypodensity which represents features of posterior reversible encephalopathy syndrome (PRES). Six weeks later, the blood pressure was stabilized with antihypertensive medication and the visual acuity has improved to 6/60 in both eyes. However, the fundus finding was still the same in both eyes.

Conclusion

Hypertensive choroidopathy is usually the sign of an acute, dramatic increase in systemic blood pressure in a young person. It is important to co-manage with the physician to achieve the target blood pressure to prevent visual threatening complications.

Oxygen blinded my eyes

Zohari Z¹, Chan L², Rahmat J², Zunaina E³

¹Ophthalmology Clinic, Hospital Raja Perempuan Zainab II, 15990, Kota Bharu, Malaysia, ²Ophthalmology Clinic, Hospital Kuala Lumpur, 50586, Kuala Lumpur, Malaysia, ³Department of Ophthalmology and Visual Sciences, School of Medical Sciences, Universiti Sains Malaysia, 16150, Kubang Kerian, Malaysia

Introduction

Aggressive posterior retinopathy of prematurity (APROP) is a subtype of retinopathy of prematurity (ROP) with aggressive behavior, occurs in very premature infants. We report a case of APROP in a heavier and more mature preterm baby who was resuscitated with supplemental unblended oxygen.

Methods

Case Report

Results

A premature baby boy was born at 31 weeks of gestation age (GA) with birth weight of 1500 grams in a rural hospital. He was intubated at birth due to respiratory distress syndrome. With limited mechanical ventilation support at the hospital and unavailable beds at the neonatal intensive care unit (NICU) in the nearest tertiary hospital, he received unmonitored supplemental unblended oxygen for five days. Subsequently, he was transferred to NICU and ventilated for 8 days before weaning off to room air. ROP screening at 36 weeks GA showed features of stage 4a ROP in both eyes (BE). The right eye showed extensive extrafoveal retinal detachment and the left eye showed subtotal retinal detachment with florid vessels, thus BE were diagnosed with APROP. Despite receiving few laser photocoagulations, BE progressed to stage 5 ROP at 43 weeks GA. Lensectomy, vitrectomy, and retinal detachment surgery were performed in BE. At one year follow-up, there was complete retina re-detachment with vision of light perception.

Conclusion

APROP is a rapidly progressive severe form of ROP. High flow of unmonitored oxygen supply could lead to severe ROP. Thus, an earlier ROP screening may be of value in this group of infants.

Asian Journal of OPHTHALMOLOGY

www.asianjo.com
www.kuglerpublications.com

KUGLER
PUBLICATIONS